Amyloidosis 47

Richard W. Groves

INTRODUCTION

Amyloidosis is not a single disease; rather, the term is used to refer to several diseases that share the common feature of abnormal extracellular deposition of amyloid, a fibrillar proteinaceous material, within tissues. Deposits of amyloid can be seen in a range of clinical disorders, from plasma cell dyscrasias and Alzheimer disease to familial polyneuropathies and primary cutaneous lichen amyloidosis.

Amyloid itself is not a single chemically distinct substance, and several types of amyloid have been described. However, regardless of the source, pathogenetic mechanisms, or underlying disease, amyloid material shares certain common tinctorial and physico-chemical properties, e.g. the cross-β-pleated sheet configuration[1].

The two clinical settings in which dermatologists are likely to encounter amyloidoses are: (1) the more common primary cutaneous forms of amyloidosis; and (2) the less common systemic amyloidosis with cutaneous manifestations (Fig. 47.1).

History

Virchow, in 1854, introduced the term "amyloid"[2]. He believed that the substance resembled starch or cellulose because, like starch, it turned blue when stained with iodine followed by dilute sulfuric acid. In 1928, Gutmann first described a patient with clinical features of lichen amyloidosis, while Freudenthal, in 1930, introduced the term "lichen amyloidosus"[3].

Epidemiology

The precise epidemiology of systemic amyloidosis is not known, as the disease is often underdiagnosed or misdiagnosed[4]. In the US, the incidence of primary systemic amyloidosis is estimated to be ~1300 to 3200 new cases per year[4]; an increase in detection will likely accompany more widespread use of the assay for serum free light chains. Since 1980, there has been a marked decline in the incidence of symptomatic rheumatoid arthritis-associated secondary systemic amyloidosis due to better control of the inflammatory response[5,6].

Primary cutaneous amyloidosis is commonly observed in Southeast Asian countries, including Singapore, Taiwan, and Thailand[7]. Lichen amyloidosis in particular appears to be more prevalent in those of Chinese descent. Macular amyloidosis is frequently seen in Central and South American countries, especially those close to the equator[8]. In general, macular and lichen amyloidosis occur more often in individuals with skin phototypes III and IV.

Classification

Amyloidosis can be classified clinically into systemic (generalized) forms, with involvement of several organ systems, and organ-limited (localized) forms, in which deposits are limited to a single organ such as the skin (Table 47.1). In the localized forms, amyloid deposition occurs at or near the site of synthesis, while in the systemic forms the precursors are secreted into the circulation, followed by amyloid deposition at distant sites[9]. Amyloidosis can also be classified according to its constituent precursor protein (Table 47.2; see next section).

Pathogenesis

The major component of amyloid is the fibril protein; the minor components are amyloid P component, glycosaminoglycans, and apoE lipoprotein. Amyloid P is a glycoprotein derived from serum amyloid P protein (SAP) and it has a specific calcium-dependent binding affinity for amyloid. Over 40 distinct forms of amyloid fibril proteins and their precursors have been identified[9a], including: AL (amyloid light chains), containing immunoglobulin light chains; AA (amyloid-associated), composed of an acute phase protein synthesized by the liver; Aβ amyloid, found in cerebral lesions of Alzheimer disease; and ATTR (transthyretin-associated), found in some forms of familial amyloidosis (mutated) and senile systemic amyloidosis (wild-type)[9]. Each condition is associated with a specific precursor protein (see Table 47.2)[10]; these amyloid precursors are initially soluble proteins that undergo changes leading to aggregation, polymerization, fibril formation, and, finally, extracellular tissue deposition as insoluble amyloid.

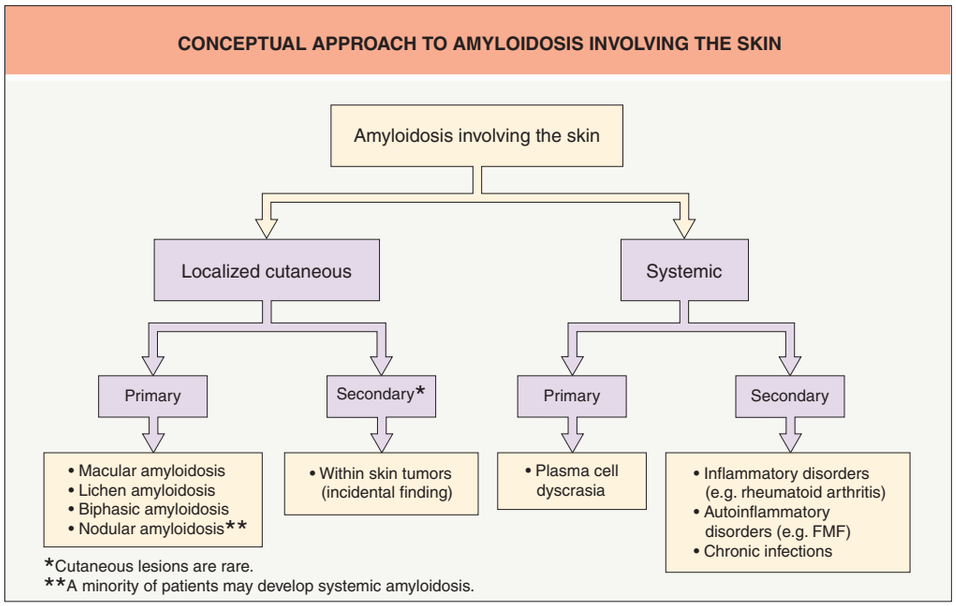

Fig. 47.1 Conceptual approach to amyloidosis involving the skin. FMF, familial Mediterranean fever.

Downloaded for Anonymous User (n/a) at Egyptian Knowledge Bank from ClinicalKey.com by Elsevier on March 10, 2024. For personal use only. No other uses without permission. Copyright ©2024. Elsevier Inc. All rights reserved.

CLINICAL CLASSIFICATION OF AMYLOIDOSIS
Organ-limited (localized) amyloidosis
Cutaneous • Primary: macular, lichen, biphasic, dyschromic, nodular • Secondary: incidental finding within various skin tumors (e.g. seborrheic keratoses, basal cell carcinomas, dermatofibromas, intradermal melanocytic nevi, adnexal tumors, Bowen disease, porokeratosis); following PUVA therapy Endocrine • Medullary carcinoma of the thyroid, insulinoma, type 2 diabetes Cerebral • Alzheimer disease
Systemic amyloidosis
Primary systemic amyloidosis (AL ≫ AH amyloid protein) • Plasma cell dyscrasias (more common) • Multiple myeloma-associated Secondary systemic amyloidosis (reactive; AA amyloid protein) • Chronic inflammation (e.g. rheumatoid arthritis, hidradenitis suppurativa) • Chronic infection (e.g. tuberculosis, Hansen disease [leprosy]) ATTR amyloidosis (transthyretin amyloid protein*) • Familial amyloid polyneuropathy (*TTR* mutations) • Familial amyloid cardiomyopathy/ATTR-CM (*TTR* mutations) • Wild-type ATTR amyloidosis (ATTRwt)/senile systemic amyloidosis/senile cardiac amyloidosis • ALect2 amyloidosis (leukocyte chemotactic factor 2) See Table 47.2 for additional forms
*Transthyretin is a serum transport protein for thyroxine and retinol-binding protein that is produced in the liver, choroid plexus and eye[9].

Table 47.1 Clinical classification of amyloidosis.

The process by which this transformation takes place differs amongst the various types of amyloidoses. In primary systemic amyloidosis, substitution of amino acids at specific positions within the variable region of the immunoglobulin light chain potentially destabilizes these chains thereby increasing the likelihood of their conversion to amyloid fibrils. Similarly, mutations in the transthyretin gene have been shown to alter the stability of the transthyretin protein and increase its baseline mild amyloidogenicity[1,4]. The accumulation of these relatively inert amyloid fibrils within vital organs leads to functional impairment.

The precise pathogenesis of primary cutaneous amyloidosis is not yet fully understood. Prolonged friction, genetic predisposition (e.g. *OSMR*, *IL31RA*), and environmental factors have all been implicated as possible etiologies. The precursor protein involved has not been fully characterized; however, for the macular and lichenoid variants of primary cutaneous amyloidosis it is thought to be keratinocyte-derived. This has been supported by ultrastructural studies demonstrating transitional forms between viable keratinocytes and amyloid, as well as by positive reactions with monoclonal antibodies directed against basal layer keratins[11]. The fibrillar theory proposes that keratinocyte tonofilaments undergo degeneration and pass into the dermis, where they are presumably modified by histiocytes and fibroblasts into amyloid material. An alternative theory suggests that the material is produced at the epidermo-dermal interface, with precursor proteins being secreted by basal keratinocytes. This hypothesis has been supported by ultrastructural findings and demonstration of basement membrane antigens such as type IV collagen and laminin within amyloid deposits[11]. Although these cutaneous amyloid deposits stain positively with anti-human antibodies directed against IgG, IgM and IgA, this staining is thought to be the result of nonspecific immunoglobulin absorption as opposed to an immunoglobulin being the putative precursor protein. Apolipoprotein E4, galectin-7, and actin have also been shown to be associated with primary cutaneous amyloid deposits and may be synthesized locally by keratinocytes[12,13]. Small fiber neuropathy has been observed in primary cutaneous amyloidosis and may be related to the associated pruritus[14].

In nodular amyloidosis there is no specific staining with antikeratin antibodies, but rather the amyloid deposits are composed of immunoglobulin light chains, suggesting plasma cell derivation akin to the cutaneous lesions of primary systemic amyloidosis. Thus, its origin is very different from that of either macular or lichen amyloidosis[11]. Presumably, there is local cutaneous production of light chains in nodular amyloidosis, whereas in primary systemic amyloidosis with skin involvement, the light chains are derived from the systemic circulation.

CHEMICAL CLASSIFICATION OF AMYLOIDOSES		
Precursor protein	**Amyloid protein**	**Clinical syndrome**
Aβ precursor protein (AβPP)	Aβ	Alzheimer disease, aging
(Apo) serum AA*	AA	Secondary systemic amyloidosis (see Table 47.1), autoinflammatory syndromes (e.g. familial Mediterranean fever, Muckle–Wells syndrome, TRAPS; see Table 45.2)
Apolipoprotein AI	AApoAI	Hereditary apolipoprotein AI-associated amyloidosis; distribution of organ involvement, including skin, related to location of mutation
Apolipoprotein AII	AApoAII	Familial renal amyloidosis
β_2-microglobulin	Aβ_2M	Chronic hemodialysis
Calcitonin	ACal	Medullary carcinoma of the thyroid
Cystatin C	ACys	Hereditary cystatin C amyloid angiopathy†
Gelsolin	AGel	Familial amyloidosis, Finnish type
Immunoglobulin heavy chain (very rare)‡	AH	Primary systemic amyloidosis
Keratin	AKer	Primary (localized) cutaneous amyloidosis
Immunoglobulin light chain	AL	Primary systemic amyloidosis (associated with plasma cell dyscrasia¶ ≫ multiple myeloma), primary cutaneous nodular amyloidosis
Medications: insulin enfurvitide anakinra GLP-1 receptor agonist	 AIns Enf IL1RAP GLP1	At sites of injections, firm nodules or in abdominal fat of normally appearing skin (AGLP1)
Leukocyte chemotactic factor 2	ALect2	Progressive renal insufficiency and hepatic involvement; favors Mexican-Americans
Transthyretin	ATTR	ATTR amyloidosis: (1) familial amyloid polyneuropathy (*TTR* mutations); (2) familial amyloid cardiomyopathy (*TTR* mutations); and (3) wild-type ATTR amyloidosis/senile systemic amyloidosis/senile cardiac amyloidosis
Corneodesmosin	ACor	Hypotrichosis simplex of the scalp

*Amyloid-associated protein synthesized by the liver.
†Detection of deposits within clinically normal skin allows diagnosis prior to clinical symptoms (cerebral hemorrhage).
‡More commonly, heavy chains produce a non-amyloid type deposit termed heavy chain deposition disease which is sometimes associated with acquired cutis laxa.
¶Monoclonal gammopathy; progression depends upon risk factors (e.g. non-IgG paraprotein).

Table 47.2 Chemical classification of amyloidoses. Except for Aβ, AApoAII, ACal and ALect2 (light shade), there are reports of amyloid deposits in involved or clinically uninvolved skin and/or oral mucosa. Although >40 types of amyloid have been characterized[9a], to date there are no reports of associated cutaneous lesions in types not listed in the table. GLP, glucagon-like peptide; IL1RAP, interleukin-1 receptor antagonist protein; TRAPS, TNF receptor-associated periodic syndrome. *Adapted from Sipe JD, Benson MD, Buxbaum JN, et al. Amyloid fibril protein nomenclature: 2010 recommendations from the nomenclature committee of the International Society of Amyloidosis. Amyloid 2010;17:101–4.*

Amyloid Properties

In H&E-stained sections, amyloid appears as amorphous, eosinophilic fissured masses (Figs. 47.2, 47.3A & Table 47.3). With a Congo red stain, amyloid has an orange–red color on routine light microscopy, whereas under polarized light it exhibits green birefringence (Fig. 47.3B). Other special stains that can be used to detect amyloid deposits include crystal violet, methyl violet, periodic acid Schiff (PAS), Sirius red, pagoda red, Dylon stain, and Thioflavin T (Fig. 47.3C)[15]. AA (but not AL) amyloid loses its affinity for Congo red after exposure to potassium permanganate.

Downloaded for Anonymous User (n/a) at Egyptian Knowledge Bank from ClinicalKey.com by Elsevier on March 10, 2024. For personal use only. No other uses without permission. Copyright ©2024. Elsevier Inc. All rights reserved.

By electron microscopy, amyloid appears as 7 to 10 nm wide, non-branching, non-anastomosing fibrils (see Fig. 47.2). X-ray crystallography and infrared spectroscopy reveal a characteristic cross-β-pleated sheet conformation. These findings are identical in all types of amyloid, regardless of clinical setting or chemical composition[15]. The cross-β-pleated sheet structure of amyloid is believed to be responsible for its staining and birefringence with Congo red stain.

Immunohistochemical stains utilizing antibodies directed against the amyloid fibril proteins (e.g. immunoglobulin γ light chain, transthyretin, keratin, AA protein) can help to differentiate between the types of amyloid (Fig. 47.3D). However, these immunohistochemical stains have limitations. For precise protein identification, including AL, ATTR and Alect2, liquid chromatography–tandem mass spectrometry (LC-MS/MS) is performed on formalin-fixed, paraffin-embedded sections or subcutaneous fat fine needle aspirates (see Table 47.2)[16,17]. Laser capture technology can be used to obtain the sample for testing.

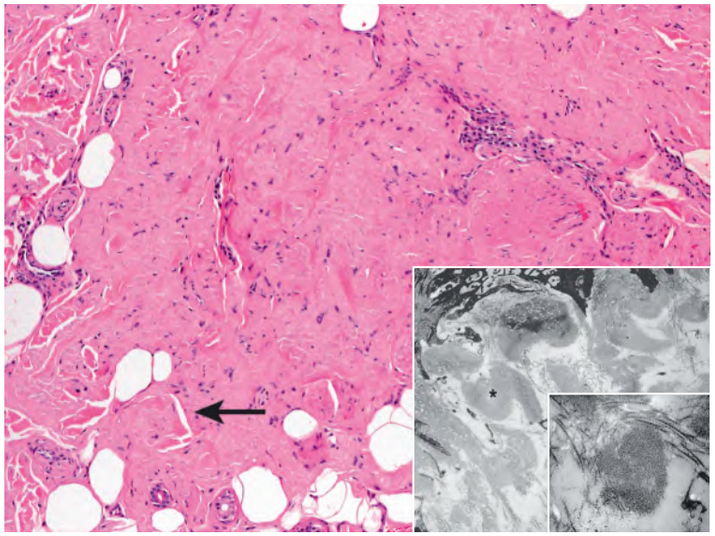

Fig. 47.2 Histologic features of amyloid deposits within the skin. In this example of nodular amyloidosis, the dermal deposits are eosinophilic, amorphous and contain fissures (arrow). By electron microscopy, there are clusters of filamentous deposits (*) and 7–10 nm non-branching fibrils (inset). *Courtesy Lorenzo Cerroni, MD and St John's Institute of Dermatology.*

HISTOPATHOLOGIC FEATURES OF AMYLOID DEPOSITS
• Homogeneous, hyaline, eosinophilic deposits in H&E-stained sections (Figs. 47.2 & 47.3A)
• Crystal violet metachromasia
• Positive staining with alkaline Congo red
• Apple-green birefringence under polarized light after Congo red staining; also dichroic (Fig. 47.3B)
• Fibrillar structure on electron microscopy (Fig. 47.2)
• Stains brightly by ultraviolet fluorescence microscopy after Thioflavin T staining (Fig. 47.3C)
• Staining with antibodies to amyloid P component
• Staining with antibodies directed against specific precursors (e.g. keratin [Fig. 47.3D])

Table 47.3 Histopathologic features of amyloid deposits[2].

PRIMARY LOCALIZED CUTANEOUS AMYLOIDOSIS

Primary cutaneous amyloidosis is associated with the deposition of amyloid in the skin but not internal organs (see Table 47.1). The most common variants are macular amyloidosis, lichen amyloidosis, and biphasic amyloidosis.

Clinical Features – Macular, Lichenoid, Biphasic, and Dyschromic Amyloidosis

Although primary cutaneous amyloidosis is classically divided into macular (macular amyloidosis), papular (lichen amyloidosis), and nodular (nodular amyloidosis) forms, the first two entities actually represent the ends of a clinical spectrum. In some patients and even some lesions both macular and papular forms can be present, termed "biphasic amyloidosis"[18,19]. Primary cutaneous amyloidosis can have a profound effect on quality of life due to the associated pruritus and visual appearance of the skin lesions[20].

Macular amyloidosis is often pruritic but it may be asymptomatic. The lesions of macular amyloidosis are hyperpigmented, either in a confluent or rippled pattern (Fig. 47.4A). The latter can be best appreciated by stretching the skin. The most common site of involvement is the upper back, especially over the scapular area, followed by the extensor surfaces of the extremities. A linear or even nevoid pattern may be seen (Fig. 47.4B). Macular amyloidosis usually presents in early adulthood, and women may be affected more often than men[15,21]. In biphasic amyloidosis, fine papular lesions are superimposed upon a background of hyperpigmentation.

The term "friction amyloidosis" has been used to describe a subgroup of patients in whom local friction from nylon brushes, towels, and other rough materials contributes to the production of macular and lichenoid lesions. There is also significant clinical overlap between macular amyloidosis and the pigmented form of notalgia paresthetica, where pruritus of the scapular areas leads to rubbing and scratching (see Ch. 6).

Lichen amyloidosis is the most common form of primary cutaneous amyloidosis and usually presents as persistent, pruritic plaques on the shins or other extensor surfaces, e.g. anterior thighs or forearms (Fig. 47.5)[10,18]. Initial lesions are discrete, firm, scaly, skin-colored or hyperpigmented papules, which later coalesce into plaques that often have a rippled or ridged pattern. At the onset, lesions are usually unilateral, but over time a bilateral symmetric distribution pattern can develop[18].

Primary cutaneous amyloidosis manifesting as pigmentation and lichenification of the anal and sacral regions has been described as an ano-sacral variant, but these patients often have lichen amyloidosis

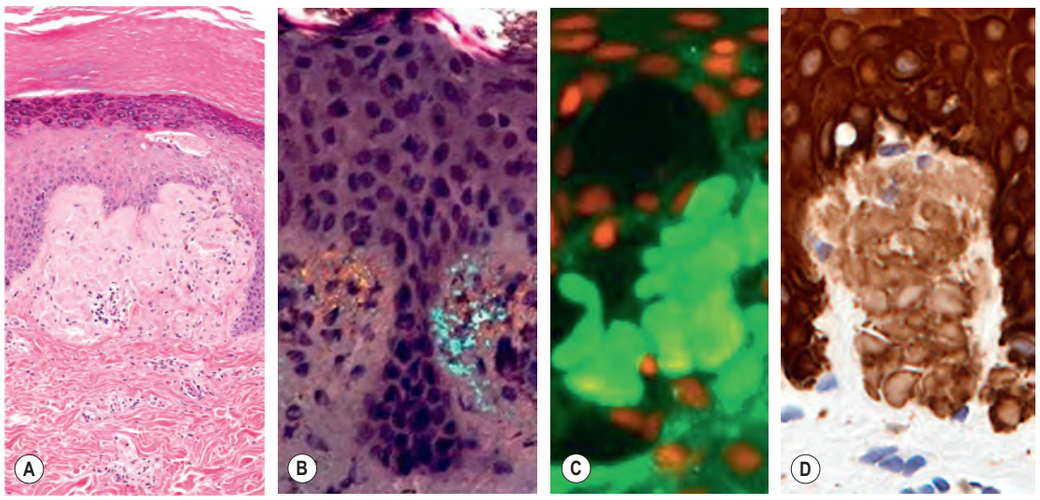

Fig. 47.3 Use of special stains to identify amyloid deposits within the papillary dermis in lichen amyloidosis. A In hematoxylin & eosin-stained sections, amyloid deposits, admixed with melanophages, are seen within the papillary dermis in addition to compact orthohyperkeratosis and acanthosis. **B** With Congo red stain, there is characteristic green birefringence with polarized light; the color can vary from yellow–green to blue–green. **C** With Thioflavin T stain, amyloid deposits stain brightly with ultraviolet fluorescence microscopy. **D** Positive immunohistochemical stain for keratin (MNF 116, broad-spectrum anti-keratin antibody). *A, Courtesy Lorenzo Cerroni, MD; B,C, Courtesy St John's Institute of Dermatology; D, Courtesy Jennifer McNiff, MD.*

Downloaded for Anonymous User (n/a) at Egyptian Knowledge Bank from ClinicalKey.com by Elsevier on March 10, 2024. For personal use only. No other uses without permission. Copyright ©2024. Elsevier Inc. All rights reserved.

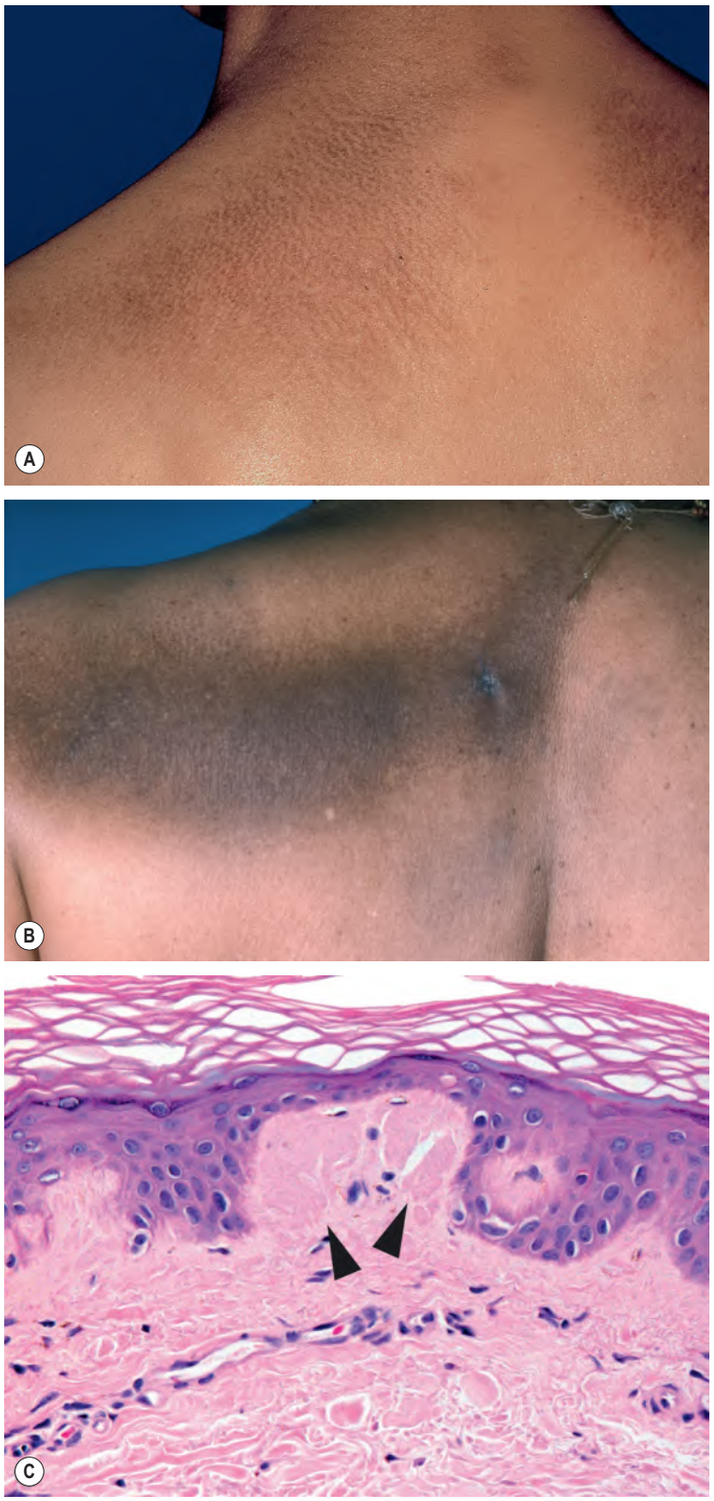

Fig. 47.4 Macular amyloidosis. A Characteristic rippled hyperpigmentation of macular amyloidosis. **B** Occasionally a linear accentuation is seen. Scattered papules can also be seen in both patients. **C** Histologically, deposits of amyloid within the dermal papillae (arrowheads) as well as melanophages within the papillary dermis; note the characteristic fissure in the amyloid deposit. These deposits may be subtle. *C, Courtesy Lorenzo Cerroni, MD.*

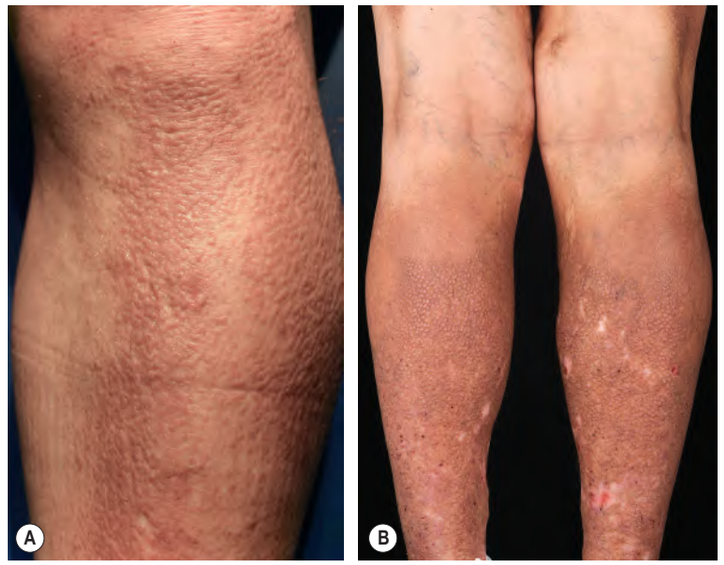

Fig. 47.5 Lichen amyloidosis. A Multiple monomorphous papules on the shin; the rippled appearance is most obvious laterally. **B** Numerous small monomorphous papules on the calves admixed with focal hemorrhagic crusts from scratching and hypopigmented scars. *B, Courtesy Lorenzo Cerroni, MD.*

Fig. 47.6 Primary cutaneous amyloidosis in a patient with systemic sclerosis. Note the numerous papules, some of which are in a grid-like array.

or biphasic amyloidosis elsewhere[18,19]. Bullous lesions have also been described in the setting of lichen amyloidosis, but they are more commonly associated with systemic amyloidosis.

Macular and/or lichen amyloidosis has also been described in association with autoimmune connective tissue disorders (e.g. systemic sclerosis [Fig. 47.6], systemic lupus erythematosus, dermatomyositis), and primary biliary cirrhosis[15]. One patient was observed to have sparing of lichen amyloidosis lesions in areas with higher cutaneous temperatures (such as along the course of large superficial veins), suggesting that amyloid fibril formation may be a temperature-dependent process *in vivo*[22].

Familial primary cutaneous amyloidosis syndromes

A number of genetic disorders have been identified that predispose to the development of primary localized cutaneous amyloidosis (PLCA).

IL-31 receptor-associated amyloidosis (PLCA1 and PLCA2)

Several families with primary localized cutaneous amyloidosis have been shown to have pathogenic variants in the genes that encode either the β subunit of the oncostatin M receptor (OSMR; PLCA1)[23] or the α subunit of the interleukin (IL)-31 receptor (IL-31RA; PLCA2)[24]. However, the protein product of *OSMR* serves as the β subunit of two receptors – not just OSMR but also IL-31R; this subunit then combines with IL-31RA to form the IL-31 receptor[25]. Of note, IL-31 has been shown to be of importance in pruritic skin conditions (e.g. dermatitis, prurigo nodularis), and nemolizumab, an anti-IL-31RA antibody, reduced pruritus in patients with atopic dermatitis[26]. In these families with primary localized cutaneous amyloidosis, IL-31 signalling may also be influenced by monocyte chemoattractant protein 1 (MCP-1)[27].

Downloaded for Anonymous User (n/a) at Egyptian Knowledge Bank from ClinicalKey.com by Elsevier on March 10, 2024. For personal use only. No other uses without permission. Copyright ©2024. Elsevier Inc. All rights reserved.

Dyschromic amyloidosis (PLCA3)

Dyschromic amyloidosis, also referred to as primary localized cutaneous amyloidosis 3 (PLCA3), is an unusual variant in which a guttate leukoderma is superimposed upon a background of hyperpigmentation and admixed with characteristic lesions of macular and lichen amyloidosis (see Fig. 67.27). Homozygous and compound heterozygous mutations in *GPNMB*, which encodes glycoprotein nonmetastatic melanoma protein b, have been detected in patients with dyschromic amyloidosis[28].

Sipple syndrome or multiple endocrine neoplasia (MEN) type 2A

Sipple syndrome is an autosomal dominant disorder with the triad of medullary carcinoma of the thyroid, pheochromocytomas, and hyperparathyroidism (see Ch. 63). Increased serum levels of calcitonin are a reflection of hyperplasia or carcinoma of the parafollicular calcitonin-producing C cells of the thyroid. Multiple endocrine neoplasia (MEN) type 2A is associated with pruritic areas of hyperpigmentation on the upper back. The lesions have been described as notalgia paresthetica, macular amyloidosis, and lichen amyloidosis. The unusual aspect is the early age of onset, often before the age of 10 years. Recognition of this skin sign of systemic disease can lead to prophylactic thyroidectomy once the diagnosis is established[29]. A study of 10 families with MEN 2A found an incidence of lichen amyloidosis of 36%; moreover, all those with cutaneous amyloidosis had a specific pathogenic variant in codon 634 of the *RET* proto-oncogene[30].

X-linked reticulate pigmentary disorder (Partington amyloidosis)

Partington and colleagues described a family with an X-linked disease in which adult women had linear streaks of hyperpigmentation and male patients manifested reticulated, mottled brown skin pigmentation, which on biopsy demonstrated dermal deposits of amyloid (in adults but not children). In women, involvement was limited to the skin, but in male patients, recurrent respiratory infections, corneal dystrophy, and photophobia were seen (see Ch. 67). As in macular amyloidosis, the amyloid deposits are keratin-positive and absent in other tissues[31]. Pathogenic variants in *POLA1* on chromosome Xp22, which encodes the catalytic subunit of DNA polymerase α1, have been detected in several families. This was associated with an activation of proinflammatory genes (e.g. NF-κB) and an increased type I interferon profile.

Other associated disorders

Primary cutaneous amyloidosis has also been reported in association with pachyonychia congenita, dyskeratosis congenita, and familial palmoplantar keratoderma[15]. At sites of injection of several medications, e.g. insulin, cutaneous amyloid deposits can develop (see Table 47.2)

Clinical Features – Nodular Amyloidosis

Nodular amyloidosis is rare, and presents as single or multiple waxy nodules or infiltrated plaques, most commonly on the trunk or extremities (Fig. 47.7A,B). Immunoglobulin γ light chains as well as β_2-microglobulin have been demonstrated within the deposits, and both are thought to be produced by plasma cells in the vicinity (Fig. 47.7D)[32]. In several patients with nodular amyloidosis, the cutaneous plasma cells had monoclonal restriction of their immunoglobulin light chains as determined by immunohistochemistry or *in situ* hybridization; examination of the bone marrow in one patient showed no evidence of a clonal plasma cell proliferation[33,34]. Of note, there may be an association between Sjögren syndrome and nodular amyloidosis of the skin or lung[35]. It has been suggested that at least some cases of cutaneous nodular amyloidosis could represent a variant of primary cutaneous marginal zone lymphoproliferative disorder (lymphoma) with unusual histopathologic features, but a similar excellent prognosis (see Ch. 119)[36,37].

There are reports of the nodular variant progressing to systemic involvement, hence longitudinal evaluation is appropriate. However, recent observations suggest that this risk is ~7%, much less than the previously quoted 50%. Although 40% of patients in this long-term study had a paraproteinemia at presentation, the gammopathy remained static during the follow-up period and progression to systemic involvement was

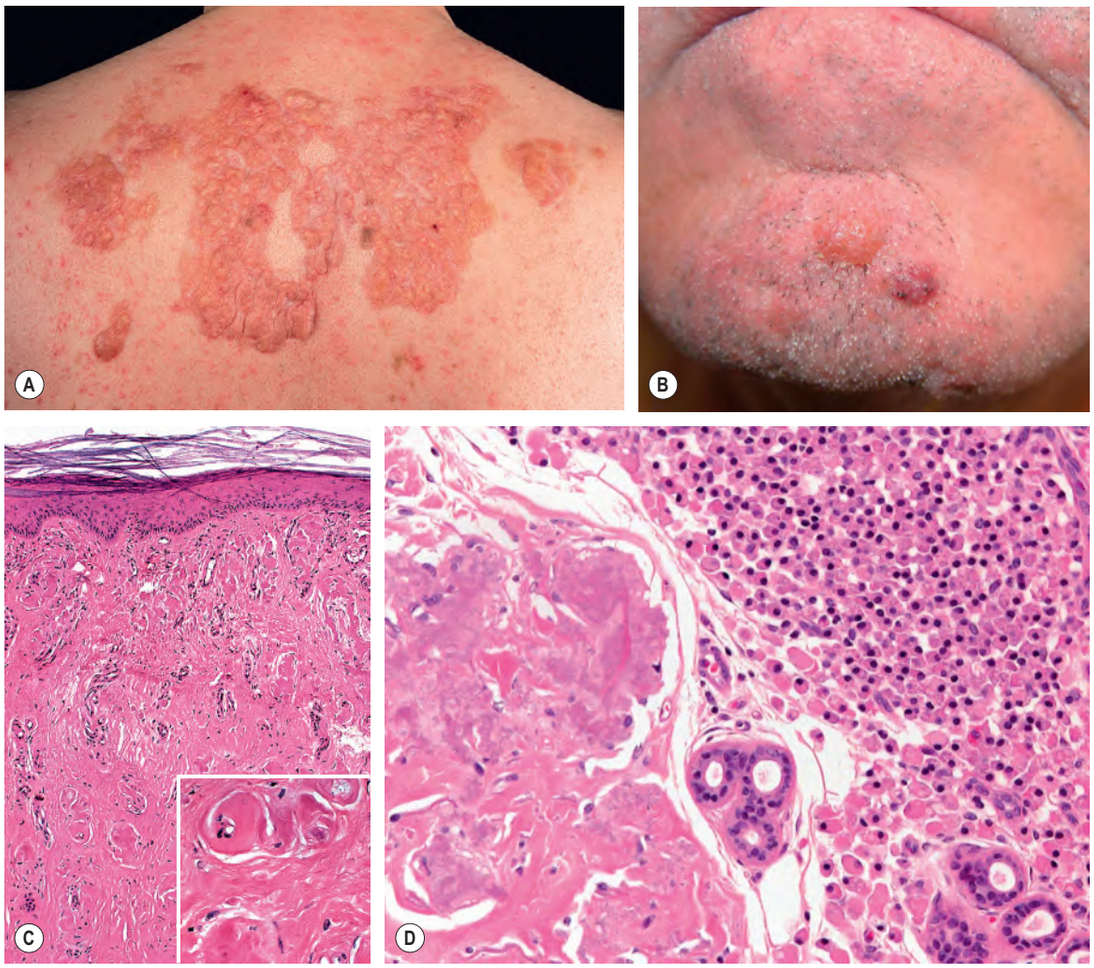

Fig. 47.7 Nodular amyloidosis. A, B Firm waxy plaques and nodules on the back and chin. The color can vary from skin-colored to pink–yellow to violaceous. **C** Histologically, there are extensive amyloid deposits within the dermis and around blood vessels. **D** An infiltrate of plasma cells can be seen in association with the amyloid deposits.
D, Courtesy Lorenzo Cerroni, MD.

Downloaded for Anonymous User (n/a) at Egyptian Knowledge Bank from ClinicalKey.com by Elsevier on March 10, 2024. For personal use only. No other uses without permission. Copyright ©2024. Elsevier Inc. All rights reserved.

observed in only 1 of 15 patients, 23 years after the initial presentation[38]. A similar study of 16 patients with nodular amyloidosis found a near equal sex distribution, with a tendency for an acral distribution. There was one patient who subsequently died from systemic amyloidosis[34].

Pathology

In macular and lichen amyloidosis, amyloid deposits are restricted to the upper dermis, particularly the papillary dermis (Fig. 47.4C). In lichen amyloidosis, the deposits may expand the papillae and displace the elongated rete ridges laterally. The overlying epidermis often has features of chronic rubbing, e.g. acanthosis, compact orthohyperkeratosis (see Fig. 47.3A). Melanophages and a sparse perivascular lymphohistiocytic infiltrate can be seen in both forms. Although antikeratin antibodies (e.g. MNF 116) may be useful in confirming the keratin origin of the amyloid deposits in these two forms of primary cutaneous amyloidosis, they are seldom required (see Fig. 47.3D).

In contrast, in the nodular variant, the dermis, subcutis, and blood vessel walls are diffusely infiltrated with amyloid (Fig. 47.7C). A perivascular infiltrate of plasma cells is nearly universally present, but in most cases is inconspicuous (see Fig. 47.7D)[38]. Immunostaining for light chain deposition can aid in the diagnosis of nodular amyloidosis. As noted previously, these plasma cells are usually monoclonal, and it has been recently suggested that a number of cases of primary cutaneous nodular amyloidosis ("nodular amyloidoma") may represent a peculiar variant of cutaneous marginal zone lymphoproliferative disorder (lymphoma)[36,37].

Differential Diagnosis

The diagnosis of primary cutaneous amyloidosis is based on clinical morphology and histologic demonstration of amyloid deposits within the skin (see Table 47.3).

There is significant overlap in the appearance of *macular amyloidosis* and notalgia paresthetica. The latter is also seen on the upper back and can have rippled hyperpigmentation. Histologically, the early stages of notalgia paresthetica contain scattered necrotic keratinocytes and a few melanophages but no amyloid deposits. However, later on, even within the same lesion, deposits can appear. When macular amyloidosis is more diffuse or confluent, it must be distinguished from postinflammatory hyperpigmentation. Other entities in the differential diagnosis may include pityriasis versicolor, atrophic lichen planus (LP), erythema dyschromicum perstans (ashy dermatosis), and drug-induced pigmentation.

The primary differential diagnosis for *lichen amyloidosis* includes lichen simplex chronicus (LSC) and hypertrophic LP. Both are characterized by chronic pruritic plaques, often on the shins and, histologically, exhibit hyperkeratosis, acanthosis, and a mild to moderate lymphohistiocytic inflammatory infiltrate but no amyloid deposits. In LSC, lichenification is often prominent, while hypertrophic LP lesions may have a violaceous hue and, on histologic examination, a lichenoid infiltrate with vacuolar degeneration. Other entities that may be considered in the clinical differential diagnosis include papular mucinosis, pretibial myxedema, prurigo simplex/nodularis, pemphigoid nodularis, lichen ruber moniliformis, and epidermolysis bullosa pruriginosa.

Nodular amyloidosis may resemble the cutaneous lesions of primary systemic amyloidosis and the latter should be excluded. The clinical differential diagnosis also includes other nodular lesions (e.g. cutaneous lymphoid hyperplasia, sarcoidosis, colloid milium), all of which have rather distinctive histopathologic features and therefore can be easily differentiated.

Treatment

No treatment modalities described to date have proven to be curative or uniformly effective in patients with *macular or lichen amyloidosis* (Table 47.4)[39]. Treatment must be directed at breaking the itch–scratch–itch cycle usually present in these patients. Chronic friction, scratching, and rubbing can serve as possible precipitating or aggravating factors and patients should be advised of this. Potent topical corticosteroids are useful to some extent, especially in mild cases, and application under occlusion or in combination with a mild keratolytic agent such as salicylic acid (particularly in lichen amyloidosis) may have added benefit. The involved sites can be protected from scratching by applying occlusive dressings such as hydrocolloids or gauze wraps impregnated with zinc oxide for a period of weeks to months, but recurrence rates may be high. Based upon case reports, topical calcineurin inhibitors may play an adjunctive role, and more recently, dupilumab was observed to be an effective treatment for lichen amyloidosis[40]. Whether nemolizumab, the anti-IL-31RA antibody, will lead to improvement remains to be determined.

TREATMENT OF MACULAR AND LICHEN AMYLOIDOSIS	Rx
Potent topical corticosteroids, including under occlusion (2)	
Topical calcineurin inhibitors (3)	
Intralesional corticosteroids (3)	
Occlusive dressings (e.g. hydrocolloid) or wraps (e.g. zinc oxide-impregnated) (3)	
UVB phototherapy (2)	
PUVA phototherapy (2)	
Systemic retinoids (2)	
Dermabrasion (2)	
CO_2 laser therapy (2)	
Low-dose cyclophosphamide (3)	
Cyclosporin (3)	
Dupilumab (3)	
Thalidomide (3)	

Table 47.4 Treatment of macular and lichen amyloidosis. Key to evidence-based support: (1) prospective controlled trial; (2) retrospective study or large case series; (3) small case series or individual case reports. PUVA, psoralen plus UVA; UVB, ultraviolet B.

In a study that compared the efficacy of topical corticosteroids versus either UVB or topical PUVA phototherapy for the treatment of lichen amyloidosis, there was greater improvement in the pruritus and roughness scores on the sides treated with either form of phototherapy, with PUVA being marginally better in reducing pruritus[41]. Dermabrasion was shown to be beneficial in lichen amyloidosis involving the limbs with the effects lasting at least five years: the epidermis and part of the papillary dermis along with some of the amyloid was removed, permitting re-epithelialization to occur from the adnexal structures[42]. CO_2 or erbium:YAG laser therapy may also be of benefit in some patients with macular and lichen amyloidosis[43,44].

Retinoids including acitretin[45] and alitretinoin[46] have been reported to improve pruritus and result in flattening of lesions, with some clearance of the associated hyperpigmentation[45]. In a preliminary study, low-dose cyclophosphamide (50 mg daily) was effective in reducing pruritus and papules in lichen amyloidosis[47]. However, the side effects of these systemic medications (see Chs. 126 & 130) must be weighed against the possible benefits.

Surgical excision, cryotherapy, electrodesiccation, and CO_2 laser can be used to treat *nodular amyloidosis*, but local recurrences are common[42]. Rarely, the local recurrence lacks amyloid deposits and has the histopathologic features of a conventional primary cutaneous marginal zone lymphoma[36]. There are scattered reports of the use of cyclophosphamide (see above)[47].

SECONDARY CUTANEOUS AMYLOIDOSIS

Secondary cutaneous amyloidosis refers to amyloid deposits that are inapparent clinically but can be detected histopathologically within skin lesions, most commonly in seborrheic keratoses and basal cell carcinomas and occasionally in dermatofibromas, intradermal melanocytic nevi, pilomatricomas, trichoepitheliomas, sweat gland tumors, Bowen disease, and porokeratosis[15]. In these settings, the amyloid deposits represent a histologic epiphenomenon without obvious clinical implications. Secondary cutaneous amyloidosis has also been reported following PUVA therapy.

Hypotrichosis simplex of the scalp 1/hypotrichosis 2 (HYPT2) is an uncommon autosomal dominant disorder and is perhaps best regarded as a particular form of secondary cutaneous amyloidosis. Patients have normal hair at birth, but progressively lose most scalp hair by the third decade. Eyebrows, beard and axillary hair, nails, and teeth develop normally. Pathogenic variants in the gene that encodes corneodesmosin, a glycoprotein expressed in the epidermis and inner root sheath, lead to truncated corneodesmosin proteins. The latter accumulate as amorphous amyloid deposits around hair follicles and in the papillary dermis[48].

Downloaded for Anonymous User (n/a) at Egyptian Knowledge Bank from ClinicalKey.com by Elsevier on March 10, 2024. For personal use only. No other uses without permission. Copyright ©2024. Elsevier Inc. All rights reserved.

SYSTEMIC AMYLOIDOSIS

Primary Systemic Amyloidosis

Multiple forms of systemic amyloidosis have been identified, but skin involvement is variable[49]. The following discussion focuses on those in which the skin is a major target.

AL amyloidosis

AL amyloidosis is a life-threatening manifestation of an underlying plasma cell dyscrasia, although patients usually do not fulfill the criteria for multiple myeloma (e.g. hypercalcemia, osteolytic lesions; see Ch. 119). The fibrils are composed of AL protein, which consists of immunoglobulin light chains, usually λ-type (75%–80%).

Clinical features

AL amyloidosis is associated with a wide spectrum of organ involvement. The presenting symptoms are varied and nonspecific, such as fatigue, weight loss, paresthesias, dyspnea, and syncopal attacks due to orthostatic hypotension[4,50]. As a result, there is often difficulty and delay in diagnosis.

In the oral cavity, amyloid deposits appear as rubbery swellings or an infiltration of the mucosa (Fig. 47.8A). An associated hemorrhagic component is frequently seen. The tongue can be uniformly enlarged and firm (Fig. 47.8B), or it may have hemorrhagic papules, plaques, and blisters on its surface; the latter may vary from translucent to yellow–brown in color. Xerostomia can result from infiltration of the salivary glands.

Following minor trauma, petechiae, purpura, and ecchymoses are often observed, especially on the eyelids and neck and in the axillae and anogenital region (due to amyloid infiltration of vessel walls; Fig. 47.9). Characteristically, periorbital purpura (the "raccoon eyes" sign) may be precipitated by coughing, the Valsalva maneuver, or proctoscopy for a rectal biopsy, as well as after pinching or rubbing the skin (pinch purpura). Even removal of adhesive tape can lead to purpura.

Clinically evident skin involvement occurs in ~25% of individuals with AL amyloidosis. Skin infiltration by amyloid presents as waxy, translucent, or purpuric papules (Fig. 47.8D,E & 47.10), nodules, and plaques that resemble nodular amyloidosis. A smooth, erythematous, waxy infiltration with scattered superimposed papules can appear on the palms and volar aspect of the fingertips (Fig. 47.8C). Smooth, skin-colored papules, a few millimeters in diameter, may be seen on the face, neck, and scalp and in the anogenital region.

Fig. 47.8 Range of mucocutaneous findings in primary systemic AL amyloidosis. A Intraoral rubbery swellings (arrows). **B** Macroglossia with irregular thickening of the tongue. **C** Waxy infiltration of the palm and volar aspects of the fingers. **D, E** Multiple waxy, translucent papules on the breast, central chest, and upper abdomen; several of the lesions are purpuric. *Courtesy Lorenzo Cerroni, MD.*

Downloaded for Anonymous User (n/a) at Egyptian Knowledge Bank from ClinicalKey.com by Elsevier on March 10, 2024. For personal use only. No other uses without permission. Copyright ©2024. Elsevier Inc. All rights reserved.

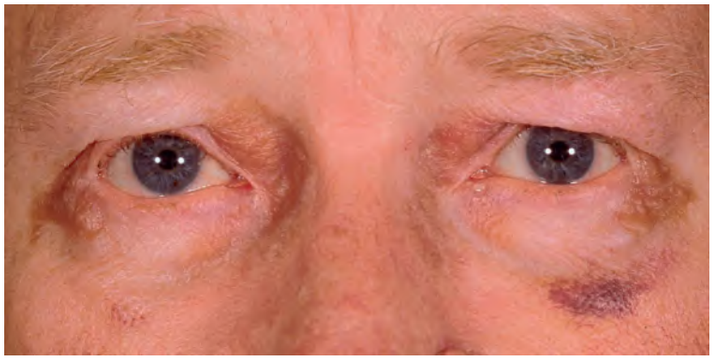

Fig. 47.9 Primary systemic AL amyloidosis. Purpura and yellow–brown plaques in a periorbital distribution. *Courtesy Joyce Rico, MD.*

Fig. 47.10 Primary systemic AL amyloidosis. A Numerous waxy translucent facial papules. Some have a yellow to yellow–brown color. **B** Some of the waxy papules have become purpuric, but this can be more difficult to appreciate because of the pigmentation of the skin (compare to Fig. 47.9). The periorbital region is a characteristic site of involvement. *A, Courtesy Jean L. Bolognia, MD; B, Courtesy Judit Stenn, MD.*

Less often, diffuse cutaneous infiltration can result in an infiltrated sclerodermoid appearance or cause the scalp skin to be thrown into folds resembling cutis verticis gyrata with associated alopecia. Bullous lesions, especially hemorrhagic blisters resembling those of porphyria cutanea tarda and epidermolysis bullosa acquisita, may be the initial sign of the disease. In addition, nail dystrophy can occur and may resemble lichen planus, with longitudinal ridging and thinning; histologically, amyloid deposits are found around blood vessels and in the dermis of the nail bed and matrix. Rarely, patients also have evidence of acquired acral cutis laxa. The presence of macroglossia together with carpal tunnel syndrome is a classic presentation and should trigger an investigation for amyloidosis.

Other signs and symptoms of AL amyloidosis depend upon the organs involved. Renal involvement manifests as proteinuria (albuminuria) which leads to hypoalbuminemia and edema, i.e. nephrotic syndrome. Cardiac involvement may eventually lead to a restrictive cardiomyopathy and congestive heart failure, but with a preserved ejection fraction. This results in dyspnea, hepatomegaly, and bilateral lower extremity as well as presacral edema. Autonomic and sensory neuropathies are common. Sensory involvement is usually bilateral and symmetrical, while autonomic involvement can result in postural hypotension, impotence, and disturbances in gastrointestinal motility (e.g. gastroparesis). Hepatomegaly due to amyloid infiltration or congestive heart failure may be present.

In up to 80%–90% of patients with AL amyloidosis, amyloid deposits can be demonstrated in random rectal mucosal biopsies or in abdominal subcutaneous fat aspirates; the latter is preferred because of the potential risk for bleeding with the former. Gingival or tongue biopsies may also be obtained to demonstrate the presence of amyloid, but in the absence of involvement clinically, they are less sensitive. In addition, bone marrow biopsies are examined for the presence of amyloid deposits. Based upon the finding that all of these amyloid deposits contain amyloid P (which is derived from serum amyloid protein [SAP]), SAP scintigraphy is also employed, primarily outside the US. It utilizes radioiodine-labeled SAP and is a sensitive, non-invasive method for locating amyloid deposits and monitoring disease. A more practical method for assessing response to therapy is measurement of serum free light chains.

The approach to a patient with suspected or confirmed AL amyloidosis is outlined in Fig. 47.11.

Pathology

In AL amyloidosis, cutaneous lesions are characterized by amyloid deposits in the dermis and subcutis. Amyloid is also often found around sweat glands and within blood vessel walls (Fig. 47.12). Rarely, an infiltrate of amyloid-producing monoclonal plasma cells can be found adjacent to the amyloid deposits. An unusual pattern of amyloid deposition around elastic fibers, in which the fibers appear coated with a thick mantle of amyloid-staining material, is occasionally seen and has been termed *amyloid elastosis*. The latter is rarely observed in primary cutaneous amyloidosis.

Differential diagnosis

The differential diagnosis of the waxy papules includes papular mucinosis, nodular amyloidosis, and lipoid proteinosis, and when the lesions are primarily on the face, they can be confused with adnexal tumors (see Ch. 111). Conditions in the sclerodermoid differential diagnosis (see Table 43.7) need to be considered when there is diffuse infiltration of the skin.

Treatment

Without therapy, the prognosis for AL amyloidosis is poor: median survival is ~13 months[50], especially if there is cardiac involvement. Treatment strategies have paralleled those for multiple myeloma, including melphalan and systemic corticosteroids[4,51,52]. The current FDA-approved treatment regimen for AL amyloidosis is the combination of cyclophosphamide, bortezomib, and dexamethasone (CyborD) plus daratumumab (anti-CD38 antibody). If the patient is younger and has minimal cardiac involvement, high-dose melphalan followed by autologous hematopoietic stem cell transplantation is a potentially curative therapeutic option. In one study with an 8-year follow-up period, a complete hematologic response was observed in 40% of transplanted patients and was associated with a prolonged survival. A survival benefit and clinical improvement in organ function was also seen in those who did not achieve a complete hematologic response[53].

Supportive measures are administered according to the organs affected and the consequent manifestations. Nephrotic syndrome and congestive heart failure require diuretic therapy and treatment of associated arrhythmias. Neuropathy and gastrointestinal involvement are treated symptomatically.

Secondary Systemic Amyloidosis (AA Amyloidosis)

Secondary systemic amyloidosis occurs as a complication of severe chronic inflammatory diseases of an infectious or non-infectious nature, such as tuberculosis, lepromatous leprosy, rheumatoid arthritis, and ankylosing spondylitis. It has also been observed in patients with hidradenitis suppurativa, dystrophic epidermolysis bullosa, generalized psoriasis, chronic pustular psoriasis, systemic sclerosis, dermatomyositis, autoinflammatory syndromes such as familial Mediterranean fever and Muckle–Wells syndrome, and systemic lupus erythematosus. Secondary systemic amyloidosis is characterized by the deposition of a distinctive non-immunoglobulin protein designated AA (amyloid A protein). The precursor is an acute phase protein which is synthesized by the liver and appears to have a regulatory function in lipoprotein metabolism during inflammation. AA amyloidosis usually affects the kidneys, liver, spleen, adrenals, and heart. Cutaneous lesions due to amyloid deposits are rarely seen in this type of amyloidosis, although amyloid can be detected within aspirates of subcutaneous fat[15].

Successful treatment of the underlying infectious or inflammatory disease may halt the progression of the reactive amyloidosis. For example, the use of systemic immunomodulators ("biologic agents") such as TNF inhibitors in patients with rheumatoid arthritis or ankylosing spondylitis and secondary amyloidosis has been shown to be clinically beneficial, resulting in a significant reduction in acute phase reactants and proteinuria[54]. A controlled clinical study found

Downloaded for Anonymous User (n/a) at Egyptian Knowledge Bank from ClinicalKey.com by Elsevier on March 10, 2024. For personal use only. No other uses without permission. Copyright ©2024. Elsevier Inc. All rights reserved.

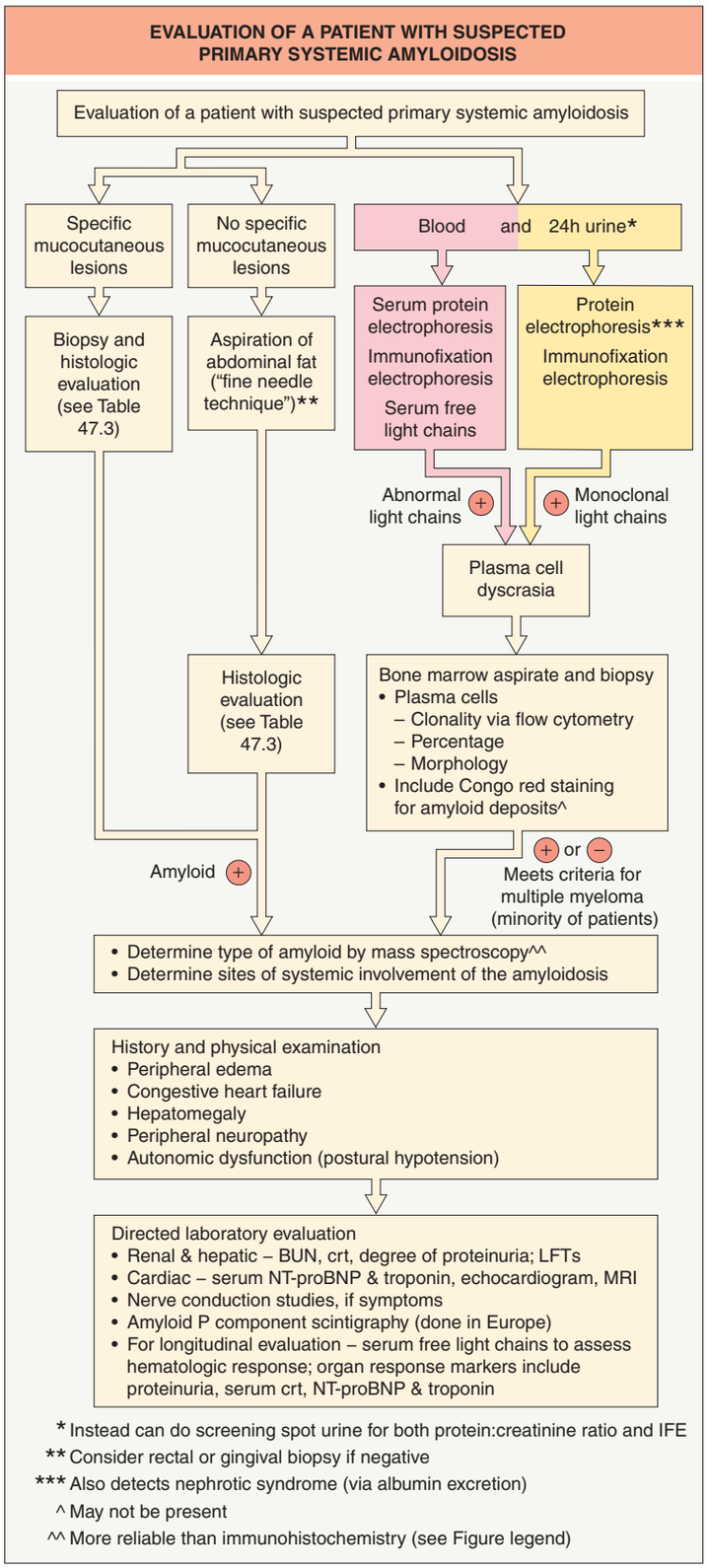

Fig. 47.11 Evaluation of a patient with suspected primary systemic AL amyloidosis. Because the amyloid is formed from immunoglobulin light chains, an abnormality of free light chains in the blood or urine (e.g. increased concentration or abnormal ratio in the blood, positive immunofixation electrophoresis [IFE] of the urine) is required for diagnosis. Mass spectroscopy has become more routine given the potential for misdiagnosis of older patients with wild-type ATTR deposits in the heart or ALect2 deposits in the kidney and liver in the setting of a monoclonal gammopathy of unknown significance. A positive cardiac pyrophosphate scan points to the diagnosis of ATTR amyloidosis. BUN, blood urea nitrogen; crt, creatinine; LFTs, liver function tests; NT-proBNP, N-terminal pro-brain natriuretic peptide.

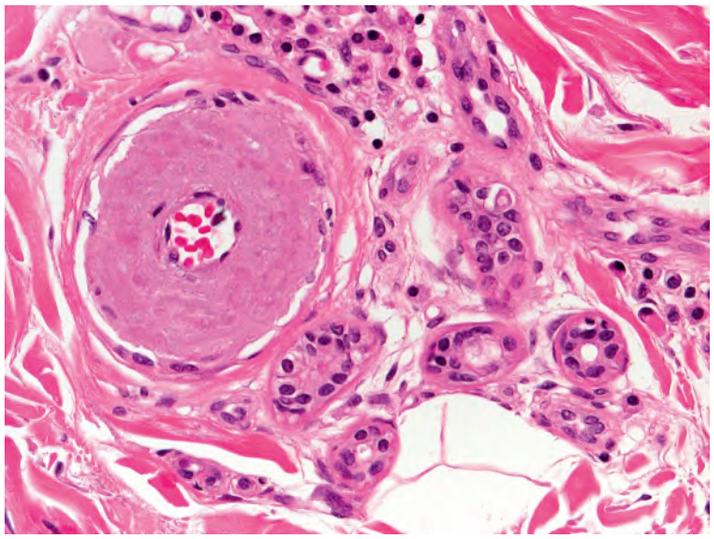

Fig. 47.12 Primary systemic AL amyloidosis – histopathologic features. Amyloid deposits are seen in a perivascular location. *Courtesy Lorenzo Cerroni, MD.*

that eprodisate may slow the loss of renal function in AA amyloidosis. Interestingly, this oral drug acts by changing the conformational configuration of the amyloid protein, rather than by affecting its production[55].

Hemodialysis-Associated Amyloidosis (Aβ_2M Amyloidosis)

Hemodialysis-associated amyloidosis results from decreased excretion of β_2-microglobulin and is seen in patients receiving long-term hemodialysis for renal failure. Because β_2-microglobulin is not readily filtered through dialysis membranes, it is retained within the circulation and has a tendency to deposit in synovial membranes. Thus, the predominant manifestations are musculoskeletal, including carpal tunnel syndrome, bone cysts, and a destructive spondylo-arthropathy[4]. Occasionally, skin lesions have been observed, usually as subcutaneous nodules[56,57]. With improvement in dialysis membranes, the incidence has declined.

INHERITED AMYLOIDOSES

The genetic bases of primary localized cutaneous amyloidosis have been previously discussed (see above). Additional inherited forms of amyloidosis are listed in Tables 47.1 and 47.2, including those associated with autoinflammatory disorders (see Ch. 45).

Familial Amyloidosis, Finnish Type (AGel Amyloidosis)

Patients with the rare Finnish type of familial amyloidosis, which is due to variants in the gene that encodes gelsolin[58], present with a characteristic triad of corneal lattice dystrophy, cranial neuropathies, and skin findings including cutis laxa-like changes and skin fragility[59]. Interestingly, despite the multisystem nature of the condition, life expectancy does not seem to be affected[60].

Transthyretin Amyloidosis (ATTRwt/ATTRv Amyloidosis)

There are two forms of transthyretin amyloidosis: (1) ATTRwt which results from deposition of wild-type transthyretin in cardiac tissue and predominantly affects the elderly; and (2) ATTRv (variant transthyretin amyloidosis) that is due to mutations in the transthyretin gene and presents with either neurologic or cardiac dysfunction. The latter represents the commonest inherited form of systemic amyloidosis. The skin is only rarely involved[61], although cutaneous amyloid deposition occurs early in the disease and thus abdominal fat pad biopsy can be helpful in diagnosis.

Downloaded for Anonymous User (n/a) at Egyptian Knowledge Bank from ClinicalKey.com by Elsevier on March 10, 2024. For personal use only. No other uses without permission. Copyright ©2024. Elsevier Inc. All rights reserved.

Orthotopic liver transplantation represents a therapeutic option for hereditary ATTR amyloidosis[38] and tafamidis meglumine is FDA-approved for treatment of wild-type or hereditary ATTR cardiomyopathy[62]. Tafamidis binds selectively to transthyretin and slows monomer formation, misfolding, and amyloidogenesis. Patisiran, a small interfering RNA (siRNA), and inotersen, an antisense oligonucleotide, are approved therapies for hereditary ATTR polyneuropathy. A preliminary clinical trial utilized gene-editing CRISPR-Cas9 technology to target and significantly reduce production of misshapen transthyretin by the liver.

APPENDIX

Tandem mass spectrometry (TM/TM) for precise identification of an amyloid protein: Mayo Clinic Medical Laboratories, Rochester, MN, USA, and University of Tennessee Health Science Center, Knoxville, TN, USA.

Additional figures available in our eBook (see inside front cover for access code).

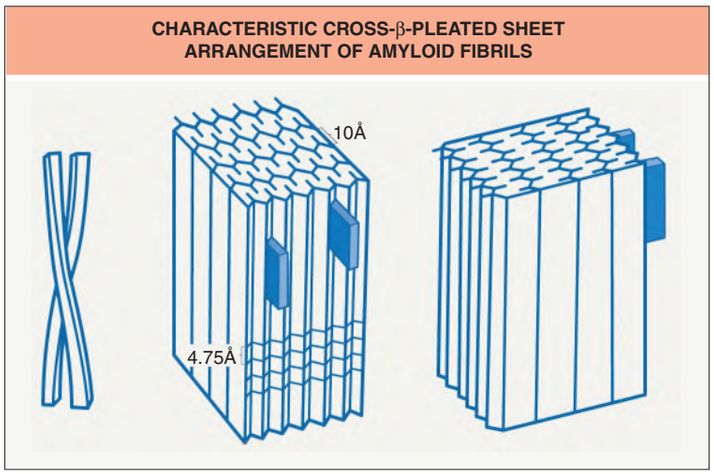

eFig. 47.1 Characteristic cross-β-pleated sheet arrangement of amyloid fibrils – schematic representation of findings seen by X-ray crystallography. There is an antiparallel configuration of paired filaments, and sites of binding of the planar Congo red dye are indicated by the solid blue blocks. *Adapted from Cooper JH. Selective amyloid staining as a function of amyloid composition and structure: histochemical analysis of the alkaline Congo red, standardized toluidine blue, and iodine methods. Lab Invest. 1974;31:232–8.*

eFig. 47.2 Lichen amyloidosis. Hyperpigmented thin papules in a parallel linear array. Note the admixed hemorrhagic crusts from scratching.

eFig. 47.3 Lichen amyloidosis. Keratotic hyperpigmented papules on the forearm, many of which are in a linear array. *Courtesy M. Joyce Rico, MD.*

eFig. 47.4 Lichen amyloidosis. Keratotic, hyperpigmented plaques on the legs. Inset: Closer view of individual keratotic papules. *Courtesy St John's Institute of Dermatology.*

eFig. 47.5 Lichen amyloidosis. Numerous small papules in linear arrays in addition to hyperpigmentation on the extensor surfaces of the arms. *Courtesy Jeffrey P. Callen, MD.*

Downloaded for Anonymous User (n/a) at Egyptian Knowledge Bank from ClinicalKey.com by Elsevier on March 10, 2024. For personal use only. No other uses without permission. Copyright ©2024. Elsevier Inc. All rights reserved.

eFig. 47.6 Dyschromic amyloidosis cutis. An admixture of reticulated hyperpigmentation and guttate hypopigmentation is seen. *Courtesy Seth J. Orlow, MD.*

eFig. 47.7 Nodular amyloidosis. Firm plaques and nodules on the plantar surfaces.

eFig. 47.8 Nodular amyloidosis. Multiple firm papules on the plantar surface.

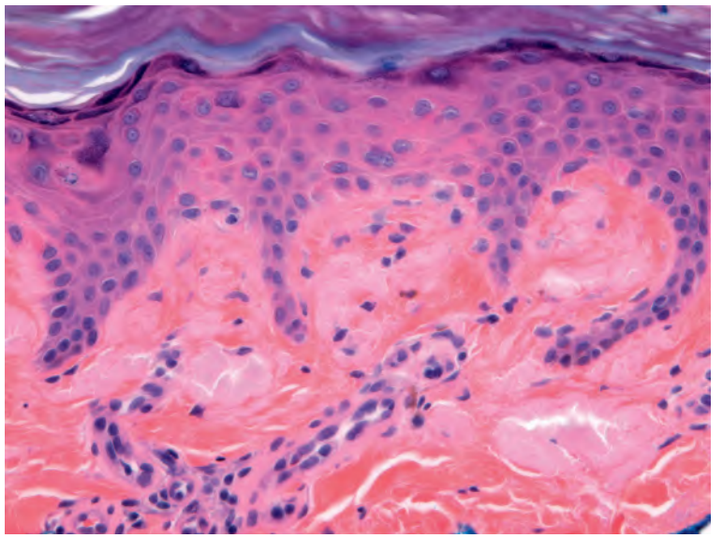

eFig. 47.9 Macular amyloidosis – histopathologic features. Deposits of amyloid within the dermal papillae and papillary dermis; note the characteristic fissure in the amyloid deposit. *Courtesy Jennifer McNiff, MD.*

eFig. 47.10 Primary systemic AL amyloidosis. A Macroglossia with dental impressions on the tongue. **B** Papulonodules of the tongue; some are purpuric while others are translucent with a yellowish hue. *B, Courtesy Dennis Cooper, MD.*

eFig. 47.11 Anakinra amyloidosis in a patient with NOMID (neonatal-onset multisystem inflammatory disease). A mass at the site of injection. *Courtesy Edward Cowen, MD.*

Downloaded for Anonymous User (n/a) at Egyptian Knowledge Bank from ClinicalKey.com by Elsevier on March 10, 2024. For personal use only. No other uses without permission. Copyright ©2024. Elsevier Inc. All rights reserved.