Dermatomyositis 42

Ruth Ann Vleugels and Joseph L. Jorizzo

Synonyms: ▪ Dermatomyositis ▪ Idiopathic inflammatory myopathies ▪ Idiopathic inflammatory dermatomyopathies

Key features

- Autoimmune connective tissue disease of uncertain etiology with both juvenile and adult forms
- Clinical and laboratory signs of proximal extensor inflammatory myopathy
- Distinctive, photodistributed, pink–violet poikiloderma favoring the scalp, periocular region, and extensor surfaces, in addition to distinctive nail-fold changes and pink–violet papules overlying the knuckles
- Histopathologic evidence of interface dermatitis plus mucin deposition in skin biopsy specimens and lymphocytic myositis in biopsy specimens from affected muscle
- When myositis is present, therapy includes systemic corticosteroids and steroid-sparing immunosuppressive and immunomodulatory drugs, with the prognosis being very good, except for those individuals with refractory myositis, systemic involvement, or an associated advanced malignancy
- Management of cutaneous dermatomyositis via skin-directed therapies can be challenging and is directed by disease severity

INTRODUCTION

Along with polymyositis and inclusion body myositis, dermatomyositis is classified as one of the idiopathic inflammatory myopathies. Dermatomyositis is a disease of presumed autoimmune pathogenesis that presents with a symmetric, proximal, extensor inflammatory myopathy and a characteristic cutaneous eruption. Previously, polymyositis was thought to represent the same disease process but limited to the muscles; however, there is robust evidence that the pathogenetic mechanisms of polymyositis and dermatomyositis differ significantly. In polymyositis, clonally expanded, autoreactive $CD8^+$ T cells invade myocytes expressing MHC class I antigens and cause necrosis via the perforin pathway. In contrast, there are data to support the theory that autoantigens activate a humoral immune process in dermatomyositis, in which complement is deposited in capillaries causing capillary necrosis and ischemia[1]. Because an appreciation of these pathogenetic differences occurred relatively recently, previous studies often pooled cases of dermatomyositis and polymyositis, making interpretation of their data challenging.

Dermatomyositis is characterized by a bimodal age distribution, with both adult and juvenile forms, and up to one-quarter of patients in the adult group having an associated malignancy. Patients with juvenile dermatomyositis do not have an increased risk of malignancy, but do have an increased incidence of calcinosis cutis and associated small vessel vasculitis. There is a subset of patients in whom the cutaneous manifestations of dermatomyositis exist without objective evidence of muscle inflammation, referred to as amyopathic dermatomyositis, and formerly known as dermatomyositis sine myositis. For dermatologists, establishing the diagnosis of dermatomyositis is important because it is a serious, treatable, multisystem disease that has a different prognosis and treatment approach from lupus erythematosus (LE). The malignancy association in adults provides the dermatologist with an opportunity to assist medical colleagues in detecting the tumor at an early stage because the skin disease often precedes the onset of symptoms related to the malignancy.

HISTORY

Dermatomyositis has been recognized as a clinical entity for more than 100 years. Although the first adult patients with dermatomyositis and malignancy were described early in the twentieth century, a causal association was not suggested until the 1940s. A major step forward in the understanding of this disorder occurred in 1975, when Bohan and Peter proposed generally accepted clinical diagnostic criteria[2,3]. Over the past two decades, it has become more widely accepted that a subset of patients has skin-limited disease (i.e. amyopathic dermatomyositis). For this reason, Sontheimer[4] proposed a revised classification of the idiopathic inflammatory myopathies that includes amyopathic forms of dermatomyositis, with muscle involvement no longer required for a definitive diagnosis (Table 42.1)[5]. Based upon epidemiologic studies, an estimated 20% of dermatomyositis patients have clinically amyopathic disease[6].

EPIDEMIOLOGY

Dermatomyositis is a relatively rare disease that occurs throughout the world. In adults, dermatomyositis affects women two to three times more often than men. The incidence of dermatomyositis ranges from 2 to 9 per million amongst various populations[6–8] and seems to be increasing, although this may simply be a result of increased detection, as well as better diagnosis and reporting. Table 42.2 summarizes the demographic findings from five series of patients with dermatomyositis[6,9–11,11a].

PATHOGENESIS

Dermatomyositis is believed to result from an immune-mediated process triggered by "outside" factors (e.g. malignancy, drugs, infectious agents)

REVISED CLASSIFICATION SYSTEM FOR THE IDIOPATHIC INFLAMMATORY DERMATOMYOPATHIES
Dermatomyositis (DM)
Adult-onset
Classic DM
Classic DM with malignancy
Classic DM as part of an overlapping connective tissue disorder
Clinically amyopathic DM*
Amyopathic DM
Hypomyopathic DM
Juvenile-onset
Classic DM
Clinically amyopathic DM*
Amyopathic DM
Hypomyopathic DM
Polymyositis
Isolated polymyositis
Polymyositis as part of an overlapping connective tissue disorder
Inclusion body myositis
*Both adult-onset and juvenile-onset amyopathic DM and hypomyopathic DM can be further subcategorized as "provisional" and "confirmed" when patients have biopsy-confirmed hallmark cutaneous manifestations of DM without muscle weakness and with normal muscle enzymes for ≥6 months (provisional) or 24 months (confirmed).

Table 42.1 Revised classification system for the idiopathic inflammatory dermatomyopathies. This classification scheme recognizes, with equal weighting, the cutaneous and muscle manifestations of this group of disorders. *Adapted from Sontheimer RD. Would a new name hasten the acceptance of amyopathic dermatomyositis (dermatomyositis sine myositis) as a distinctive subset within the idiopathic inflammatory dermatomyopathies spectrum of clinical illness? J Am Acad Dermatol 2002;46:626–36.*

Downloaded for Anonymous User (n/a) at Egyptian Knowledge Bank from ClinicalKey.com by Elsevier on March 10, 2024. For personal use only. No other uses without permission. Copyright ©2024. Elsevier Inc. All rights reserved.

CLINICAL SUBTYPES OF DERMATOMYOSITIS – DEMOGRAPHICS AND ASSOCIATED FINDINGS						
	Clinical subtype					
	Adult-onset classic dermatomyositis[6,11a]		Adult-onset clinically amyopathic dermatomyositis[9,11a]		Juvenile-onset classic dermatomyositis[10]	Juvenile-onset clinically amyopathic dermatomyositis[11]
No. of patients	20	142	291	59	120	38
Mean age (years)	51.9	51	50	53	7.7	10.5
Malignancy detected	6/20 (30%)	14/142 (9.9%)	41/291 (14%)	1/59 (1.7%)	0/120 (0%)	0/38 (0%)
Sex ratio (F:M)	3:1	4.9:1	3:1	28.5:1	2.2:1	3:2

Table 42.2 Clinical subtypes of dermatomyositis – demographics and associated findings.

in genetically predisposed individuals. Table 42.3 illustrates some of the evidence that supports this theory[12–37]. Serum anti-nuclear autoantibodies are often present, as are other myositis-specific or myositis-associated autoantibodies, as summarized in Table 42.4[29,37–39]. The anti-synthetase antibodies are directed against cytoplasmic antigens; therefore the anti-nuclear antibody test may be negative. Patients with anti-synthetase antibodies often have overlap syndromes. The term anti-synthetase syndrome has been coined to refer to patients with these autoantibodies, fever, erosive polyarthritis, "mechanic's hands", Raynaud phenomenon, and interstitial lung disease[43].

CLINICAL FEATURES

Cutaneous Disease

The features that are classically considered pathognomonic for dermatomyositis include the heliotrope sign and Gottron papules (Fig. 42.1). The former is characterized by a pink–violet color, primarily of the eyelids and periorbital skin, which may have associated edema (Fig. 42.2). The heliotrope sign can be quite subtle, with only mild erythema of the eyelid margins, and it may wax and wane in intensity. Some patients will have more widespread facial erythema (see Fig. 42.2B,C) or midfacial erythema that tends to involve the nasolabial folds (Fig. 42.3).

The cutaneous lesions of dermatomyositis are accentuated on extensor surfaces, including the elbows, knees, metacarpophalangeal joints, and both the proximal and distal interphalangeal joints (knuckles; Fig. 42.4A). When papules on the knuckles develop a secondary lichenoid quality, they are termed *Gottron papules* (Fig. 42.4B,C); involvement of the elbows and/or knees is known as *Gottron sign* (Fig. 42.5).

A critical diagnostic feature of the cutaneous eruption of dermatomyositis is poikiloderma. This feature may occur both in patients with dermatomyositis, where it is frequently characterized by a pink–violet color, and in patients with lupus erythematosus, where the poikiloderma is typically more red in color. However, in patients with skin phototypes I and II, the hue of the poikiloderma of dermatomyositis may be pink–red rather than truly violet (Fig. 42.6A). Photodistributed poikiloderma is very characteristic of dermatomyositis, often involving the upper chest (*V-neck sign*) and the upper back (*shawl sign*). Poikiloderma can also affect photoprotected areas, such as the lateral thigh, referred to as the *holster sign* (Fig. 42.6B,C). If the clinician misses the poikiloderma, the eruption of dermatomyositis may occasionally be misdiagnosed as psoriasis, especially when there are well-defined plaques on the elbows and knees with fine silvery scale.

The cutaneous lesions of dermatomyositis are often intensely pruritic (Fig. 42.7), and this can significantly affect patients' quality of life[44]. IL-31 may play a role as it does in other pruritic disorders. Of note, pruritus is a feature that can occasionally help to distinguish dermatomyositis from LE.

An additional clinical clue to the diagnosis of dermatomyositis is nail-fold changes. Cuticular dystrophy (i.e. "ragged" cuticles and cuticular hypertrophy) is quite characteristic, as are nail-fold telangiectasias in which dilated capillary loops alternate with capillary dropout (Fig. 42.8). If the photodistribution and nail-fold changes are missed, the eruption may be misdiagnosed as other conditions characterized by poikiloderma, such as cutaneous T cell lymphoma. Often, the dermatologist correctly notices the photodistribution but considers the diagnosis of photodrug eruption or lupus erythematosus rather than dermatomyositis.

Calcinosis cutis is more prevalent in juvenile dermatomyositis, affecting 25%–70% of pediatric patients[7,45], and it is usually associated

PATHOGENESIS OF DERMATOMYOSITIS
Genetics[12–14]

• Monozygotic twins affected
• Associated human leukocyte antigens (HLA)
  • HLA-DR3 and -B8 (juvenile dermatomyositis)
  • HLA-DR52 (patients with anti-Jo-1 antibodies)
  • HLA-DR7 and -DRw53 (patients with anti-Mi-2 antibodies)
  • HLA-B14 and -B40 (adults with dermatomyositis overlap)
  • HLA-DRB1*15021 (Japanese with juvenile dermatomyositis)
• TNF-α 308 A allele polymorphism

Cellular immunity/apoptosis[15–21]
• Histopathologic findings in skin and muscle ($CD8^+$ lymphocytes) • Lymphocyte-mediated experimental myositis in mice • Increased Ki-67 and p53 expression in keratinocytes after UVB irradiation • Increased CD40 expression on muscle cells • Decreased circulating CD54 (ICAM-1)-positive lymphocytes • Dysregulaion of type 1 interferons • Fas ligand on T cells and Fas receptor on muscle cells • MHC class I overexpressed in affected muscle tissues • Elevated expression of COX-1, COX-2, and 5-LOX mRNA in affected muscle tissues
Humoral immunity[22,24,31,34]
• Association with autoimmune diseases (Hashimoto thyroiditis, Graves disease, myasthenia gravis, type I diabetes mellitus, primary biliary cirrhosis, dermatitis herpetiformis, vitiligo, and other autoimmune connective tissue diseases) • Myositis-specific autoantibodies (see Table 42.4) • Upregulation of interferon pathway and complement activation • Endomysial deposition of activated complement fragments (C5b–C9)
Infectious precipitants[23,24]
• Seasonal variation • Picornavirus substrate for aminoacyl-tRNA synthetases • *Escherichia coli*, muscle protein, and a capsid protein of a picornavirus that induces mouse myositis all have some homology in amino acid sequences with Jo-1 • Echovirus infection in patients with hypogammaglobulinemia • Coxsackievirus-9 myositis
Drug and vaccine precipitants[25,26,35–37]
• Hydroxyurea, lipid-lowering drugs (statins > gemfibrozil), TNF inhibitors, checkpoint inhibitors (e.g. nivolumab, ipilimumab), nonsteroidal anti-inflammatory drugs, immunostimulatory herbal supplements (e.g. *Spirulina*, IsaLean®), MAP kinase inhibitors, trastuzumab, taxanes, capecitabine, cyclophosphamide, BCG and SARS-CoV-2 vaccines, D-penicillamine; to date single case reports of alfuzosin (α-antagonist for BPH), articaine, etoposide, interferon-α-2b, ipecac (repeated exposures), omeprazole, phenytoin, sulfacetamide sodium ophthalmic drops, tegafur, terbinafine, zoledronic acid
Malignancy association (adults)[27–30]
• Anti-transcription intermediary factor 1-γ (TIF1-γ) antibodies, e.g. risk ratio = 5 in Chinese • Anti-nuclear matrix protein (NXP-2) antibodies, particularly in men • In one study, at least 80% of patients with cancer-associated dermatomyositis had antibodies against either TIF1-γ or NXP-2

Table 42.3 Pathogenesis of dermatomyositis. Other environmental triggers such as ultraviolet radiation may play a role (e.g. correlation between rate of dermatomyositis with anti-Mi-2 antibodies and proximity to the equator). BCG, Bacillus Calmette–Guérin; BPH, benign prostatic hyperplasia; ICAM, intercellular adhesion molecule; MAP, mitogen-activated protein; TNF, tumor necrosis factor.

Downloaded for Anonymous User (n/a) at Egyptian Knowledge Bank from ClinicalKey.com by Elsevier on March 10, 2024. For personal use only. No other uses without permission. Copyright ©2024. Elsevier Inc. All rights reserved.

SERUM AUTOANTIBODIES IN ADULT AND JUVENILE DERMATOMYOSITIS				
Autoantibodies	**Target antigen function**	**Clinical phenotype**	**Autoantibody frequency, %**	
			Adult DM	**Juvenile DM**
Anti-aminoacyl-tRNA synthetases (e.g. anti-Jo-1 [histidyl], anti-PL-7 [threonyl]; see Ch. 40)	Intracytoplasmic protein synthesis	Anti-synthetase syndrome (myositis, mechanic's hands, erosive polyarthritis, fever, Raynaud phenomenon, high frequency of interstitial lung disease)	up to 20	1–3
Anti-SRP	Protein translocation	Acute-onset necrotizing myopathy (severe weakness, high CK); may be refractory to treatment	5	<1
Anti-Mi-2	Helicase – transcription	Adult DM and juvenile DM (hallmark is cutaneous disease, milder muscle disease with good response to treatment)	15	<10
Anti-TIF1-γ (p155)	Cell proliferation, apoptosis, innate immunity	Cancer-associated myositis in adult DM; extensive cutaneous disease in adult DM and juvenile DM; palmar hyperkeratotic papules, psoriasiform lesions, red-on-white telangiectatic patches, ovoid palatal patch	20–40	~25
Anti-NXP-2 (p140)	Nuclear transcription, RNA metabolism	Cancer-associated myositis in adult DM (particularly in men); adult and juvenile DM with calcinosis; prominent muscle involvement with myalgias, peripheral edema, dysphagia, mild skin disease	10–20	~25
Anti-SAE	Post-translational modification	Adult DM; may present with clinically amyopathic DM	5	NA
Anti-MDA5 (CADM-140)	Innate immunity	Cutaneous ulcerations – periungual region and overlying Gottron papules and/or Gottron sign, tender palmar macules and papules that favor palmar and fingertip creases, oral ulcerations, prominent non-scarring alopecia, arthritis; clinically amyopathic DM; interstitial lung disease including a rapidly progressive form (often considered a dermato-pulmonary syndrome)	5–20	NA

Table 42.4 Serum autoantibodies in adult and juvenile dermatomyositis (DM). The autoantigen CADM-140 was subsequently found to be identical to two previously identified gene products, interferon induced with helicase C domain protein 1 (IFIH1) and melanoma differentiation-associated gene 5 (MDA5). amyo, amyopathic; CADM-140, clinically amyopathic dermatomyositis antibody, 140 kD; CK, creatine kinase; NA, not applicable; NXP-2, nuclear matrix protein-2; SAE, small ubiquitin-like modifier activating enzyme; SRP, signal recognition particle; TIF1-γ (transcription intermediary factor 1-γ). Note: Autoantibody frequencies vary depending on the ethnicity/population in which the study was conducted. Adapted from references 29, 39–42.

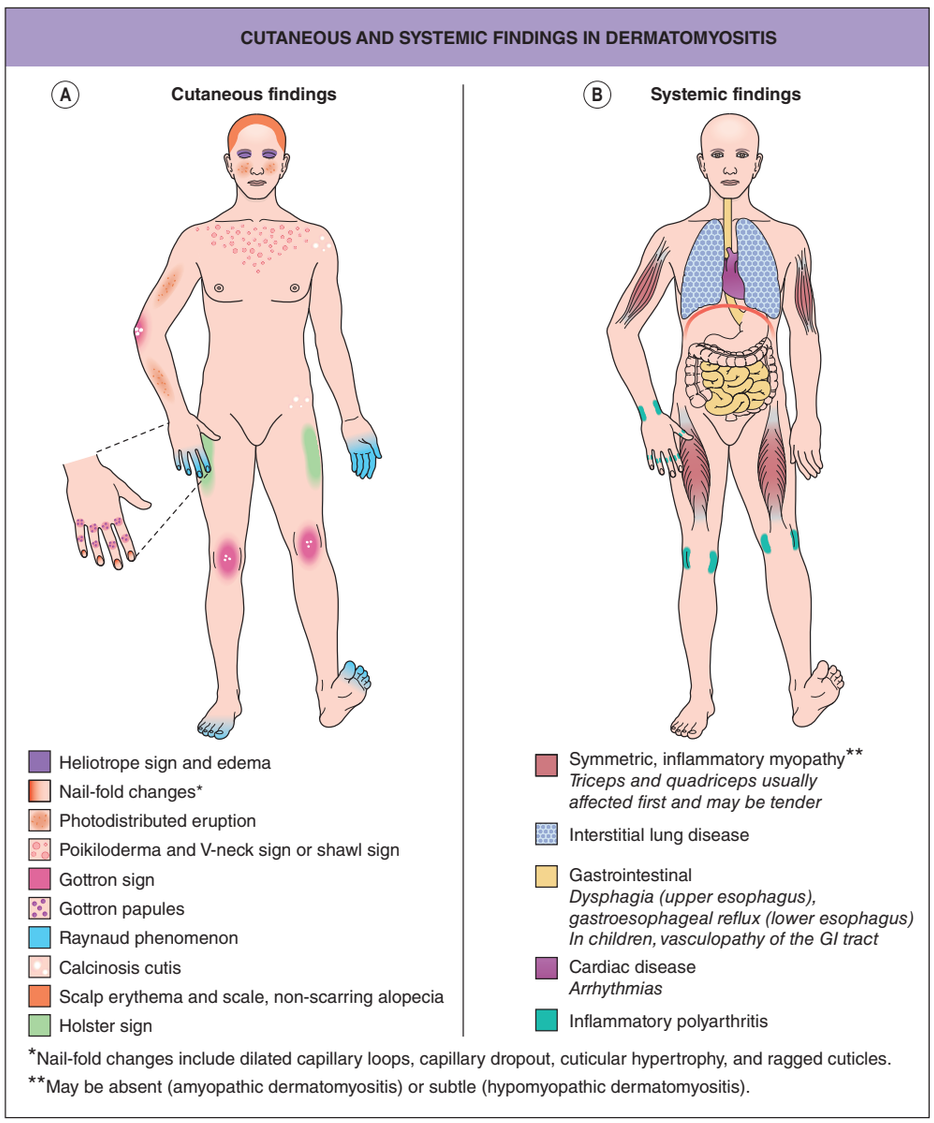

Fig. 42.1 Cutaneous and systemic findings in dermatomyositis. A Cutaneous. **B** Systemic.

Downloaded for Anonymous User (n/a) at Egyptian Knowledge Bank from ClinicalKey.com by Elsevier on March 10, 2024. For personal use only. No other uses without permission. Copyright ©2024. Elsevier Inc. All rights reserved.

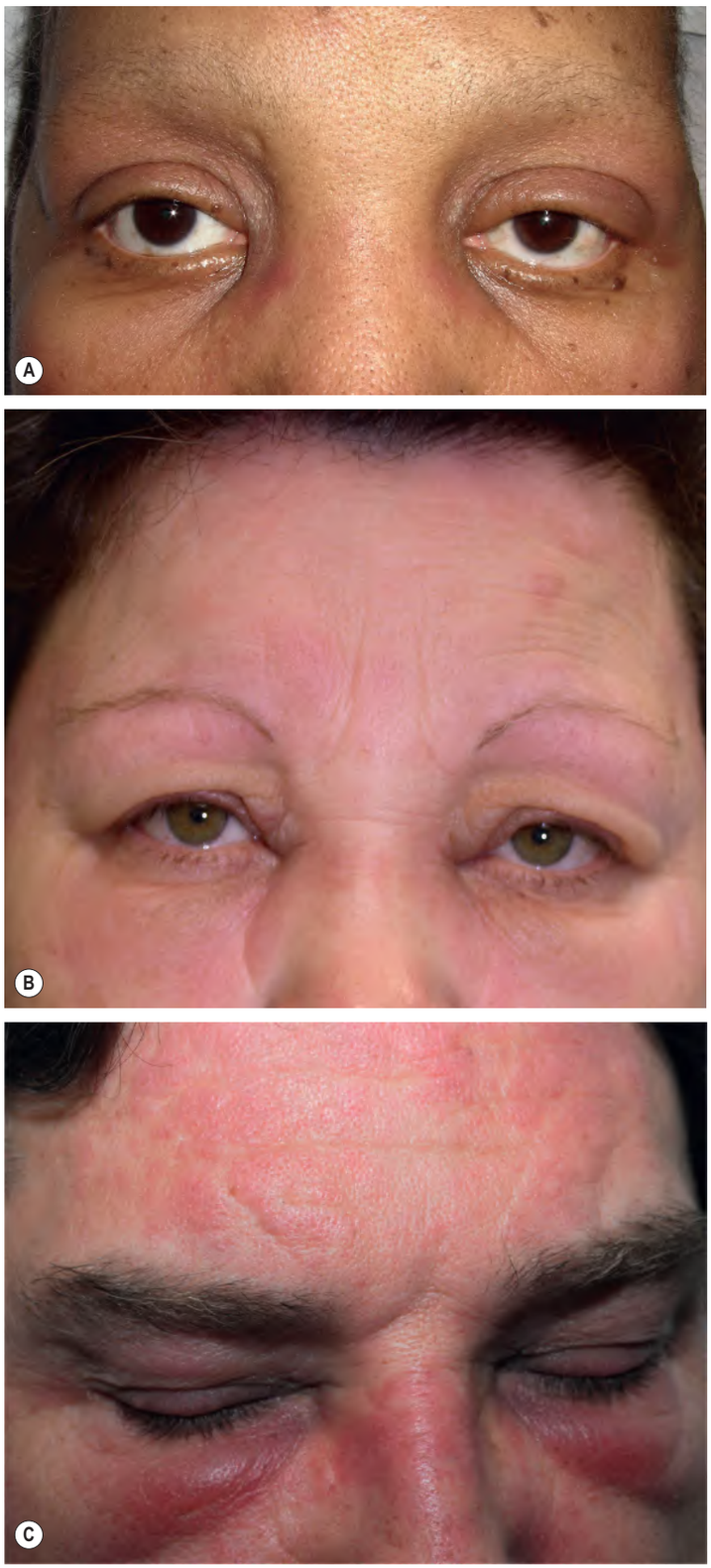

Fig. 42.2 Dermatomyositis – eyelid edema and heliotrope sign. **A** Inflammation of the upper eyelid can be more subtle in darkly pigmented skin; note involvement of the lateral nasal root and the cheeks. The eyebrow alopecia is due to chemotherapy. **B** The characteristic pink–violet color is seen with involvement of the hairline, lower forehead, upper eyelids, and cheeks; the edema is striking, especially of the upper eyelids and nasal root. **C** Heliotrope with marked lower eyelid edema. *B, Courtesy Jean L. Bolognia, MD; C, Courtesy Kalman Watsky, MD.*

Fig. 42.3 Dermatomyositis – marked facial involvement. Note the violaceous hue. Misdiagnoses include psoriasis, contact dermatitis, and if there is significant facial involvement as in this patient, acute cutaneous lupus erythematosus.

with a delay in diagnosis, a delay in the institution of systemic corticosteroids, and/or advanced, therapy-resistant disease. In addition to the skin, calcium deposits may develop within the deep fascia and intramuscular connective tissue. Calcinosis cutis presents as hard, irregular papules, plaques, or nodules that occasionally drain a chalky material (Fig. 42.9A). Lesions favor sites of trauma, such as the elbows and knees (Fig. 42.9B), but can occur anywhere and may be painful and interfere with function.

Additional cutaneous manifestations range from poikiloderma and scaling of the scalp (often accompanied by non-scarring alopecia) to centripetal flagellate erythema (Fig. 42.10A) to erosions and ulcerations (Fig. 42.10B; Table 42.5)[46–48]. "Mechanic's hands" can also be seen, more commonly in patients with anti-synthetase syndrome (Fig. 42.10C). Occasionally, especially in the setting of more severe disease, there can be edema of the extremities or even anasarca. Wong-type dermatomyositis is a variant that occurs more commonly in Asians in which the cutaneous findings mimic pityriasis rubra pilaris[49]. Lastly, because of the frequency of overlap syndromes, it is important to look for the skin signs of other autoimmune connective tissue diseases in patients with dermatomyositis.

Patients may present with the classic cutaneous manifestations of dermatomyositis but no muscle disease. Upon careful patient evaluation and longitudinal assessment, some of these patients will be found to have skin disease alone (amyopathic dermatomyositis) while others eventually evolve into classic dermatomyositis (with muscle disease) or develop hypomyopathic dermatomyositis, i.e. no muscle weakness clinically but characteristic laboratory or radiographic abnormalities[50]. The clinical characteristics of patients with classic and amyopathic dermatomyositis have been compared[9], including an examination of differences in malignancy risk. Although it was generally thought that the malignancy risk was greater in the setting of classic dermatomyositis, there have been multiple studies that have observed associated malignancies in patients with amyopathic dermatomyositis. Fulminant lung disease has also been reported in patients with amyopathic dermatomyositis. Therefore, both malignancy screening and evaluation for pulmonary involvement are recommended, irrespective of muscle involvement.

Systemic Disease

In dermatomyositis, the dermatologic manifestations frequently precede the onset of *objective* muscle disease; however, when present, the muscle disease is clinically indistinguishable from that seen in polymyositis. The myopathy affects proximal muscle groups, especially the extensor groups (triceps and quadriceps), in a symmetric fashion. In advanced disease, all muscle groups can be affected. Patients may be unable to complete simple tasks such as combing their hair or rising to their feet from a sitting position. Muscle involvement is often accompanied by malaise and fatigue.

Muscle strength should be graded on sequential visits by muscle groups (e.g. right and left triceps 3/5, right and left quadriceps 4/5,

Downloaded for Anonymous User (n/a) at Egyptian Knowledge Bank from ClinicalKey.com by Elsevier on March 10, 2024. For personal use only. No other uses without permission. Copyright ©2024. Elsevier Inc. All rights reserved.

Fig. 42.4 Dermatomyositis – Gottron papules. A Only a few Gottron papules are present, but there is definite accentuation of the pink–violet inflammation over the metacarpophalangeal (MCP) joints and proximal and distal interphalangeal (PIP, DIP) joints as well as the proximal nail folds. Note the ragged cuticles. **B** The flat-topped (lichenoid) papules overlying the DIP, PIP, and MCP joints (knuckles) are subtle and were misdiagnosed as verrucae vulgares in this child. **C** More obvious disease in which the multiple pink–violet lichenoid papules are coalescing and there is some involvement of the interphalangeal skin. *A, Courtesy Kalman Watsky, MD; B, Courtesy Julie V. Schaffer, MD.*

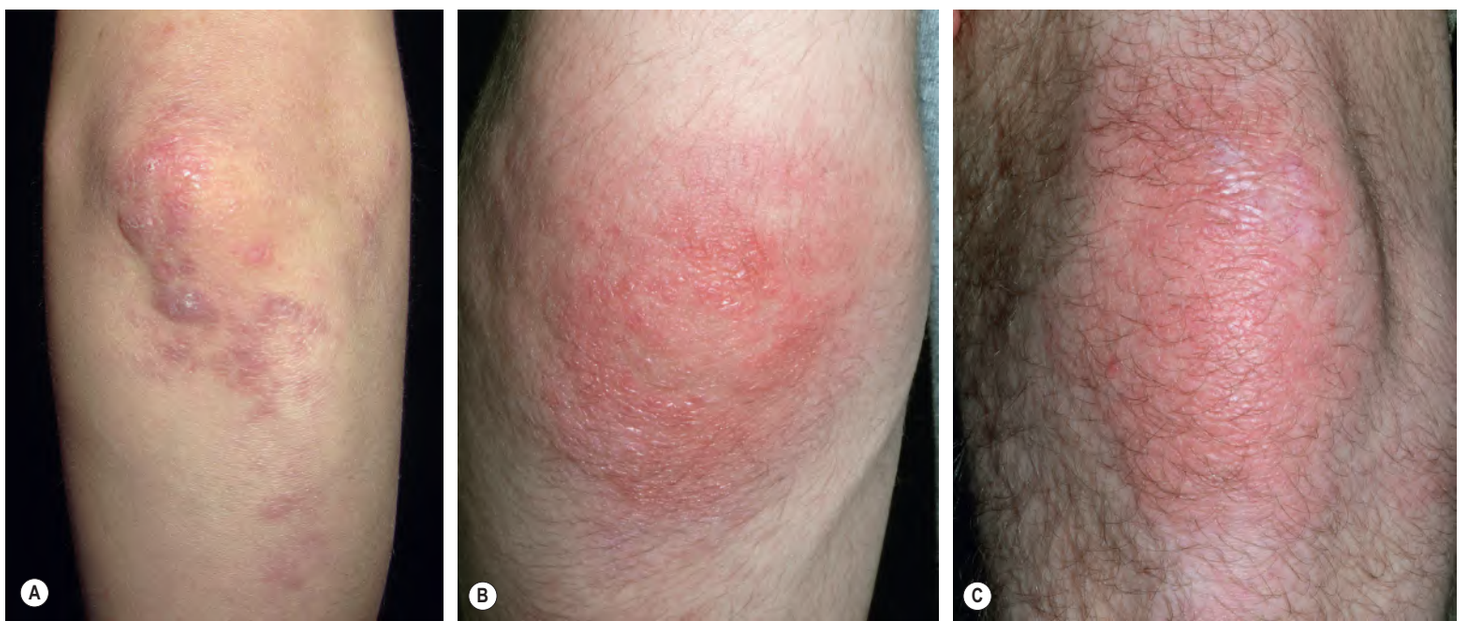

Fig. 42.5 Dermatomyositis – Gottron sign. Pink–violet papules (**A**) and thin pink plaques (**B**) of the elbows and knee (**C**). Some of the papules on the elbow are flat-topped (lichenoid) and others have white scale. The presence of plaques on the elbows and knees can lead to the misdiagnosis of psoriasis. *B,C, Courtesy Julie V. Schaffer, MD.*

etc.), although other more formal methods of quantification have been described. Assessment of neck flexor weakness can also be used to gauge muscle involvement. Symptoms of dysphagia should prompt investigation for overlap with systemic sclerosis, although patients with advanced muscle disease can have cricopharyngeal muscle dysfunction and consequently difficulty initiating swallowing. Distal esophageal involvement can present as gastroesophageal reflux disease.

Pulmonary disease occurs in ~15%–30% of patients with dermatomyositis, and generally presents as a diffuse interstitial fibrosis that is similar to that seen in patients with rheumatoid arthritis or systemic sclerosis[51]. Symptoms include a dry cough and progressive breathlessness. In one US-based study, there was no significant difference in the prevalence of interstitial lung disease when amyopathic dermatomyositis was compared to the classic form[52]. All adult patients should have screening pulmonary function tests (PFTs) that include diffusion capacity for carbon monoxide (DLCO)[52]. In those who have reduced DLCO, a high-resolution chest CT should then be performed. Patients with a high-risk phenotype for pulmonary involvement (e.g. anti-MDA5 dermatomyositis) often have a high-resolution chest CT performed at baseline as well as PFTs with DLCO.

In Eastern Asian populations, patients with anti-MDA5 (CADM) antibodies have a high risk of rapidly progressive lung disease and a poor prognosis despite a lack of muscle disease (see Table 42.4)[53,54]. Furthermore, a novel MDA5 antibody-associated dermato-pulmonary syndrome has been reported in non-Asian populations[55] in which patients develop tender palmar papules and cutaneous ulcerations, primarily on the elbows, dorsal hands, and periungual region (Fig. 42.11)[56]. Additional characteristic features of anti-MDA5 dermatomyositis include arthritis, oral ulcerations, and severe non-scarring alopecia. Recognition of this constellation of cutaneous findings alerts the clinician to the increased risk of associated and potentially fatal pulmonary disease.

Pulmonary involvement is also a notable feature of the antisynthetase syndrome[43]. For example, if anti-Jo-1 antibodies are present, there is a 70% likelihood that the patient will develop pulmonary disease. Because pulmonary disease associated with dermatomyositis is resistant to corticosteroid therapy, it follows a course independent from that of the muscle disease and can adversely affect prognosis.

Cardiac disease is usually not symptomatic. When it is, it commonly presents as arrhythmias or as conduction defects[57]. Patients with

Downloaded for Anonymous User (n/a) at Egyptian Knowledge Bank from ClinicalKey.com by Elsevier on March 10, 2024. For personal use only. No other uses without permission. Copyright ©2024. Elsevier Inc. All rights reserved.

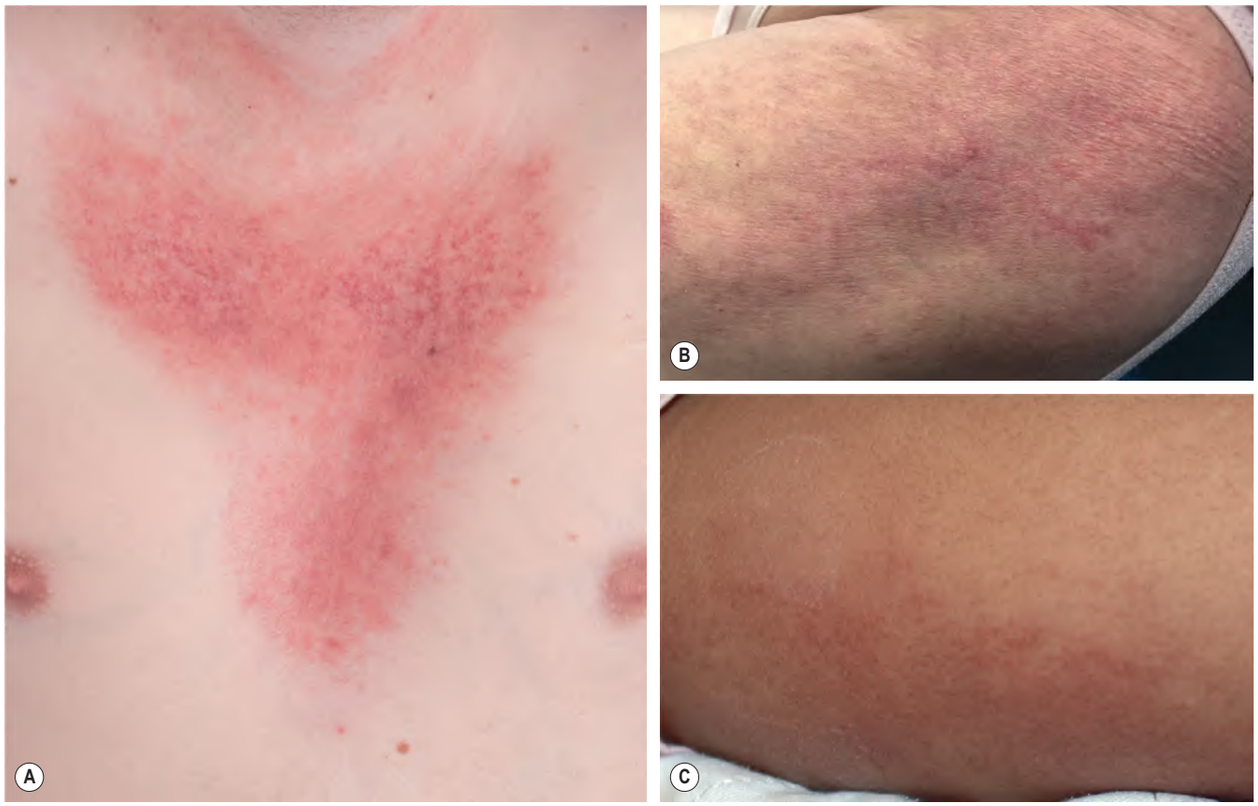

Fig. 42.6 Dermatomyositis – poikiloderma and holster sign. A Photodistributed poikiloderma is very characteristic of dermatomyositis and often involves the upper chest (*V-neck sign*). In this patient with skin phototype I, the color is pink–red. **B** Broken-up pink–violet plaque on the upper lateral thigh (holster sign). **C** Holster sign with a pink–brown color in a patient with more darkly pigmented skin. *A, Courtesy Edward Cowen, MD; B, Courtesy Jonathan Leventhal, MD; C, Courtesy Sara Perkins, MD.*

Fig. 42.7 Dermatomyositis – involvement of the upper back. The pink–violet plaques, some with associated scale, were very pruritic, as evidenced by multiple excoriations. Linear streaks of erythema are also seen. *Courtesy Jean L. Bolognia, MD.*

Fig. 42.8 Dermatomyositis – cuticular dystrophy and nail-fold telangiectasias. The cuticles are "ragged" and within the proximal nail fold, dilated capillary loops alternate with vessel dropout (inset). Atrophy, telangiectasias, and hypopigmentation are present on the fingers. *Courtesy Julie V. Schaffer, MD.*

dermatomyositis are often not thoroughly evaluated for possible cardiac disease, and prompt treatment of the muscle disease may mask the true frequency of cardiac involvement. In one retrospective review, cardiac involvement was shown to be the major prognostic factor for death in patients with dermatomyositis, in the absence of an underlying malignancy[58]. Additional reported indicators of poor prognosis (other than malignancy) include older age, progressive disease, initiation of therapy after 24 months of muscle weakness, longer duration of symptoms before diagnosis, pulmonary disease, dysphagia, and extensive cutaneous involvement of the trunk[59].

For the patient with dermatomyositis, a thorough review of systems should include a discussion of arthritis, gastrointestinal disease, pulmonary disease, cardiac disease, and other manifestations such as Raynaud phenomenon. The presence of additional clinical findings and/or systemic symptoms may signify an overlap with other connective tissue diseases – in particular, systemic LE, rheumatoid arthritis, and systemic sclerosis. One dermatology-based case series observed a 19% overlap rate in adult patients with dermatomyositis[60].

Malignancy

The reported frequency of an internal malignancy in adults with dermatomyositis varies from <10% to >50%; however, the best data point to a probable risk of 15%–25%. The malignancy association occurs with adult dermatomyositis (both classic and amyopathic), but not with the juvenile form or with polymyositis. Genitourinary

Downloaded for Anonymous User (n/a) at Egyptian Knowledge Bank from ClinicalKey.com by Elsevier on March 10, 2024. For personal use only. No other uses without permission. Copyright ©2024. Elsevier Inc. All rights reserved.

Fig. 42.9 Calcinosis cutis. A Rock-hard hyperpigmented plaques on the buttocks with multiple sites of drainage in an adult with longstanding dermatomyositis. **B** In this patient with juvenile dermatomyositis, the nodules favored the extensor surface of the knees and resulted in a decrease in joint mobility. *A, Courtesy Edward Cowen, MD.*

Fig. 42.10 Dermatomyositis – less common presentations. A Flagellate erythema of the posterior trunk. **B** Cutaneous erosions and ulcerations can also occur. **C** Hyperkeratosis and mild erythema of the lateral and palmar surfaces of the fingers in a patient with "mechanic's hands".

malignancies, especially ovarian cancer, and colon cancer may be overrepresented[61,62]; in some Southeast-Asian populations, nasopharyngeal carcinoma is overrepresented[63]. Other commonly detected malignancies include breast, lung, gastric, pancreatic, and lymphomas (including non-Hodgkin)[62]. The risk of malignancy may return to a relative baseline after 3 years[28,62,64].

Callen has suggested that the best approach to patient management in this setting is ongoing vigilance with frequent and thorough medical histories, repeated review of systems, complete physical examinations, and screening laboratory tests[65]. He has also advocated for additional cancer-screening investigations, including CT of the chest, abdomen, and pelvis as well as transvaginal pelvic ultrasound in women (Table 42.6)[64]. Patients should be up-to-date with regard to recommended screenings such as colonoscopy and mammography.

Several myositis-associated autoantibodies have been described (see Table 42.4), and presence of the anti-TIF1-γ (p155) autoantibody in particular has been associated with an increased risk of malignancy[30]. Indeed, in one study, at least 80% of patients with cancer-associated dermatomyositis had antibodies against either TIF1-γ (transcription intermediary factor 1-γ) or nuclear matrix protein NXP-2[29]. In a recent systematic review and meta-analysis, older age, male sex, dysphagia, cutaneous ulceration, anti-TIF1-γ antibodies, and classic dermatomyositis (i.e. without anti-synthetase syndrome or clinically amyopathic dermatomyositis) were associated with a significantly higher risk of an underlying malignancy[66]. This study also concluded that CT

Downloaded for Anonymous User (n/a) at Egyptian Knowledge Bank from ClinicalKey.com by Elsevier on March 10, 2024. For personal use only. No other uses without permission. Copyright ©2024. Elsevier Inc. All rights reserved.

MUCOCUTANEOUS MANIFESTATIONS OF DERMATOMYOSITIS	
Common	**Uncommon**
Heliotrope sign (Fig. 42.2) Eyelid edema (Fig. 42.2) Gottron papules (Fig. 42.4) Gottron sign (Fig. 42.5) Photodistributed poikiloderma (includes facial erythema, shawl sign, V-neck sign) (Figs. 42.3, 42.6A & 42.7) Scalp poikiloderma and scaling Non-scarring alopecia Nail-fold changes (includes ragged cuticles, cuticular hypertrophy, nail-fold telangiectasias*) (Fig. 42.8) Holster sign (poikiloderma of the lateral thighs) (Fig. 42.6B,C) Psoriasiform lesions Calcinosis cutis (especially in juvenile dermatomyositis) (Fig. 42.9)	Cutaneous erosions or ulcerations (Figs. 42.10B & 42.11A,B) Flagellate erythema (Fig. 42.10A) Tender palmar macules and papules (Fig. 42.11C) Hyperkeratotic palmar papules "Mechanic's hands" (Fig. 42.10C) Exfoliative erythroderma Cutaneous eruption that mimics PRP (Wong variant) Vesiculobullous lesions Oral ulcers† Ovoid palatal patch Gingival erythema & telangiectasias Panniculitis Lipoatrophy (especially in juvenile dermatomyositis) Small vessel vasculitis (especially in juvenile dermatomyositis)

*Dilated capillary loops alternating with vessel dropout.
†Additional intraoral findings include xerostomia and lichen planus-like changes.

Table 42.5 Mucocutaneous manifestations of dermatomyositis. See Fig. 42.1. Rarely, patients have associated erythromelalgia. PRP, pityriasis rubra pilaris.

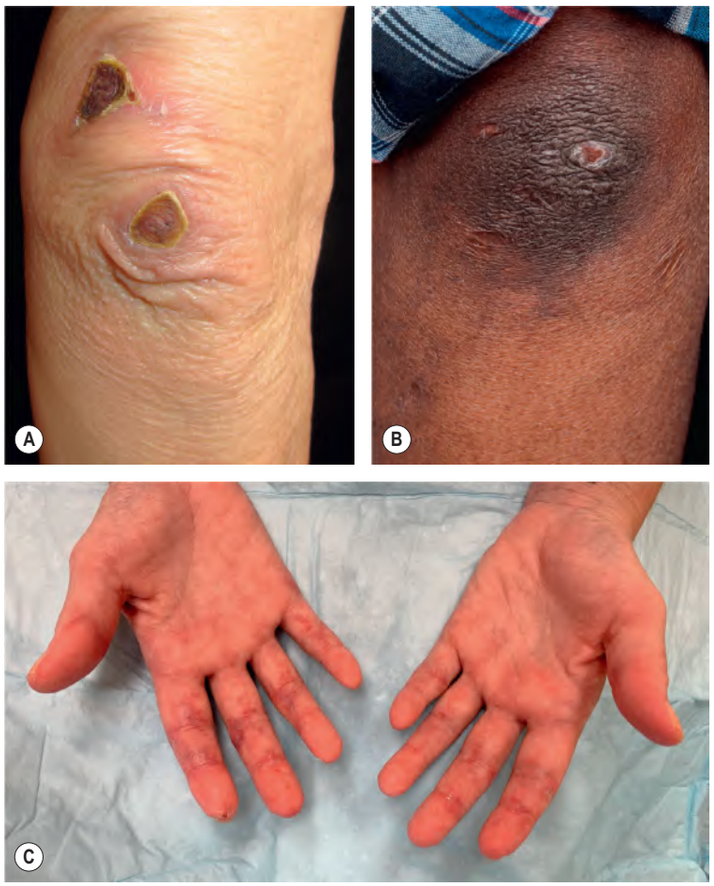

Fig. 42.11 Three patients with anti-MDA5 dermatomyositis. A, B Vasculopathic ulcerations favor the elbows, dorsal hands, and periungual region; they can be associated with Gottron sign and Gottron papules. **C** Painful violaceous macules and papules with an irregular outline that favor the digital creases.

of the chest, abdomen, and pelvis appeared to be effective in identifying otherwise asymptomatic malignancies, further supporting this screening strategy.

With regard to long-term survival, as expected, patients with cancer-associated dermatomyositis have an inferior survival curve when compared to patients with juvenile or non-cancer-associated adult myopathies[58].

EVALUATION OF THE PATIENT WITH DERMATOMYOSITIS	
History and physical examination	
• History, including potential triggers (see Table 42.3) and previous malignancies, and a review of systems • Physical examination – skin, muscle, and complete general examination, including, in adults, breast and pelvic (women), testicular and prostate (men), and rectal (both sexes) examinations; in Southeast-Asian patients, consider full ENT examination	
Laboratory evaluation	
Cutaneous	• Skin biopsy(ies)
Muscle	• Serum creatine kinase, serum aldolase, occasionally LDH (particularly in juvenile dermatomyositis) or urine creatine* • Electromyography (EMG); muscle biopsy; MRI or U/S (increasingly, MRI is being done in lieu of EMG and muscle biopsy if classic cutaneous findings are present)
Pulmonary	• Pulmonary function tests (PFTs) with CO diffusion • If PFTs abnormal, high-resolution chest CT; in patients with high-risk phenotypes (e.g. anti-MDA5 dermatomyositis), high-resolution chest CT performed at baseline as well as PFTs with DLCO
Cardiac	• Electrocardiogram (EKG) • If symptomatic, echocardiogram and/or Holter monitor
Esophageal	• If muscle involvement and symptoms, barium swallow or manometry
General	• Complete blood count, comprehensive metabolic panel with fasting levels of glucose and lipids†, comprehensive myositis antibody panel (in laboratories with reliable testing, e.g. Oklahoma Medical Research Foundation)
Malignancy screen (adults)‡,¶	• Urinalysis, stool occult blood testing • Serum prostate-specific antigen (PSA) [men] • Serum CA125 [women] • Serum CA19-9 [men and women] • Mammogram, Papanicolaou smear, and transvaginal pelvic U/S [women] • CT of chest, abdomen, and pelvis • Colonoscopy, if age-appropriate, iron deficiency anemia, occult blood in stool, or symptoms • Upper endoscopy – if colonoscopy negative in the setting of iron deficiency anemia, occult blood in stool, or symptoms
If planning chronic systemic corticosteroids	• DEXA bone density scan (see Ch. 125)

*Aspartate transaminase (AST), alanine transaminase (ALT), and lactic dehydrogenase (LDH) may also be elevated due to myositis; in children, serial examination of LDH is considered important.
†Fasting levels of glucose and lipids are important in children.
‡Malignancy screening should be performed at the time of diagnosis and annually for a minimum of 3 years from disease onset; history and physical examination can be performed more frequently.
¶Can also consider serum protein and immunofixation electrophoreses.

Table 42.6 Evaluation of the patient with dermatomyositis. CA125 screens primarily for ovarian carcinoma and CA19-9 for pancreatic and biliary tract carcinoma. Microscopic colitis can be seen in patients with chronic diarrhea. CO, carbon monoxide; CT, computed tomography; DEXA, dual energy X-ray absorptiometry; DLCO, diffusion capacity for carbon monoxide; ENT, ear, nose and throat; LDH, lactic dehydrogenase; MRI, magnetic resonance imaging; U/S, ultrasound.

PATHOLOGY

The characteristic changes seen in skin biopsy specimens from patients with dermatomyositis can be very subtle (Fig. 42.12) and include epidermal atrophy, signs of interface dermatitis with vacuolar alteration of basal keratinocytes and pigment incontinence, and dermal changes consisting of interstitial mucin deposition and a sparse lymphocytic infiltrate. In some cases, a colloidal iron stain may help to highlight

Downloaded for Anonymous User (n/a) at Egyptian Knowledge Bank from ClinicalKey.com by Elsevier on March 10, 2024. For personal use only. No other uses without permission. Copyright ©2024. Elsevier Inc. All rights reserved.

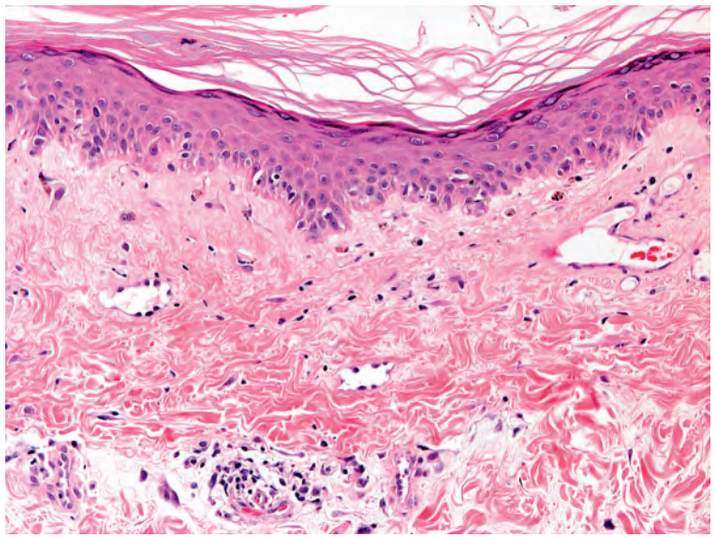

Fig. 42.12 Dermatomyositis – histopathologic features. The vacuolar changes within the basal layer can be subtle. In the dermis, dilated blood vessels and a sparse lymphocytic infiltrate are seen (poikilodermatous changes). *Courtesy Lorenzo Cerroni, MD.*

the presence of mucin. The histopathologic changes may be indistinguishable from those of cutaneous LE, in particular acute and subacute. Gottron papules show an interface dermatitis but have acanthosis and hyperkeratosis rather than epidermal atrophy[67]. A lobular panniculitis can also occur in patients with dermatomyositis and can resemble lupus panniculitis.

Muscle biopsy specimens also show characteristic changes. The combination of type II muscle fiber atrophy, necrosis, regeneration, and hypertrophy with centralized sarcolemmal nuclei, plus lymphocytes in both a perifascicular and a perivascular distribution, is classic[68]. It is best for the clinician to request that the surgeon sample triceps muscle rather than the usually biopsied deltoid muscle because the latter is often spared until late in the disease. Another option, especially for patients with mild involvement, is to choose the biopsy site based upon MRI findings (see below).

DIFFERENTIAL DIAGNOSIS AND EVALUATION

A detailed differential diagnosis of the patient who presents with proximal muscle weakness in the absence of skin lesions, i.e. the differential diagnosis of polymyositis, is beyond the scope of this dermatologic review. The patient with a characteristic cutaneous eruption should have a skin biopsy performed to confirm the clinical impression of dermatomyositis, keeping in mind that cutaneous LE can have similar histologic findings (Fig. 42.13). Table 42.7 summarizes the differential diagnosis of the dermatologic findings in dermatomyositis. Two validated instruments, the Dermatomyositis Skin Severity Index (DSSI) and the updated Cutaneous Dermatomyositis Disease Area and Severity Index (CDASI), can be used to determine the severity of cutaneous disease. These indices are helpful in assessing therapeutic responses in clinical trials[69,70].

Once the presumed diagnosis is confirmed histopathologically, a search for muscle and/or associated systemic disease must be undertaken (see Table 42.6), because it is their presence or absence that dictates therapeutic decisions. The evaluation for myositis can include: strength testing of proximal extensor muscles and other muscles including the neck flexors, serum levels of muscle enzymes, an electromyogram, and/or triceps muscle biopsy. However, increasingly, an MRI (Fig. 42.14) or ultrasound (Fig. 42.15) of proximal muscles is obtained prior to, or in lieu of, a muscle biopsy, especially in patients with classic cutaneous lesions. Individuals with normal muscle enzyme levels should be followed at regular intervals because these patients can have occult muscle disease, evolve into classic dermatomyositis, or remain as amyopathic dermatomyositis (see Fig. 42.13)[50].

Additional baseline investigations for pulmonary disease (predicted in part by autoantibody profile; see above and Table 42.4), for cardiac

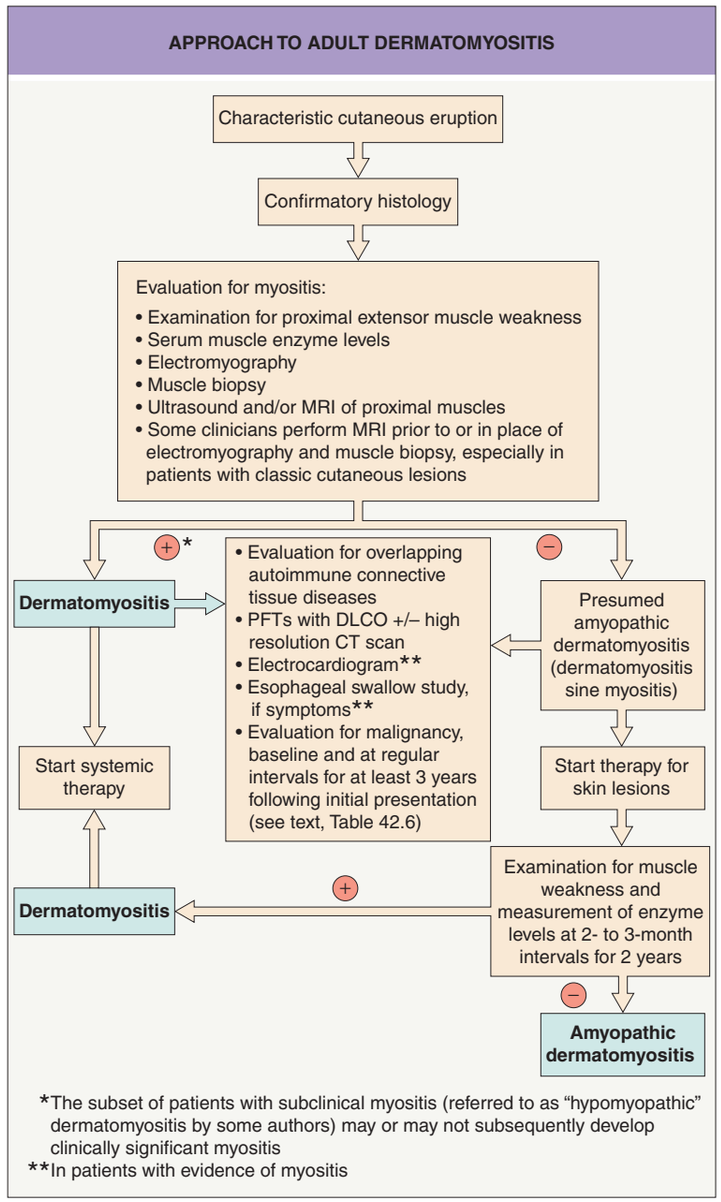

Fig. 42.13 Approach to adult dermatomyositis. The approach for children is similar but without the malignancy evaluation; in addition, pulmonary testing is not performed in children in the absence of symptoms given the low risk of interstitial lung disease. Table 42.1 outlines the definitions of "provisional" and "confirmed" amyopathic dermatomyositis but patients in the former group rarely go on to develop muscle disease. PFTs, pulmonary function tests.

disease, for symptomatic esophageal disease (barium swallow or manometry), and for features of overlap autoimmune connective tissue disease should be performed at this stage, prior to the institution of systemic therapy unless immediate therapy is warranted to halt rapidly progressive disease. Adult patients should have screening for malignancy annually for at least 3 years from disease onset (see Table 42.6), or more frequently based upon symptoms. A detailed history, review of symptoms, and complete physical examination should be performed at regular intervals of 4–6 months. Adult patients with amyopathic dermatomyositis should have similar evaluations for malignancy and associated pulmonary disease.

The classic muscle enzymes that should be assessed at baseline and at regular intervals throughout the treatment period are creatine kinase (CK) and aldolase. Aspartate and alanine transaminases and lactate dehydrogenase are often elevated as well, since they also are released from damaged muscle tissue. It has been estimated that 95% of patients with classic dermatomyositis have an elevated CK at some point during their illness[8]. Urine creatine is elevated in some patients who have a normal serum CK, but this test is not routinely performed.

Downloaded for Anonymous User (n/a) at Egyptian Knowledge Bank from ClinicalKey.com by Elsevier on March 10, 2024. For personal use only. No other uses without permission. Copyright ©2024. Elsevier Inc. All rights reserved.

DIFFERENTIAL DIAGNOSIS OF DERMATOMYOSITIS
Systemic lupus erythematosus*
Physician might notice nail-fold erythema and photodistributed poikiloderma but miss the muscle weakness, heliotrope, extensor distribution, pruritus, and the violaceous hue (Fig. 42.3) The malar rash of SLE classically spares the nasolabial folds, whereas the midfacial erythema of dermatomyositis involves the nasolabial folds Most commonly an issue when patient has amyopathic dermatomyositis and presents with a photosensitive eruption and no muscle weakness
Psoriasis
Involvement of elbows and knees with papulosquamous lesions can lead to misdiagnosis In addition, Gottron papules, extensor surfaces, and scalp can have psoriasiform scaling
Airborne or allergic contact dermatitis
Eyelid edema and lichenification secondary to pruritus can be marked in dermatomyositis; look for additional sites of contact dermatitis or dermatomyositis
Photodrug eruption
Photodistribution
Cutaneous T cell lymphoma
The poikiloderma often begins in intertriginous zones rather than on the scalp, face, and extensor surfaces
Atopic dermatitis
Usually in children, where the physician focuses on the pruritus and secondary lichenification
Systemic sclerosis*
The nail-fold telangiectasias may be similar in appearance, but the dyspigmentation is quite different; edema of the hands ("puffy hand sign") is an early sign of systemic sclerosis
Trichinosis
Patients have painful muscles and periorbital edema, but not other features
Photodistributed form of multicentric reticulohistiocytosis (MRH)
Firm papules have distinct histologic features and may occur along the nail fold Patients with MRH do not have the following nail-fold changes: dilated capillary loops, capillary dropout, cuticular hypertrophy, and ragged cuticles
Still disease
Persistent plaques may be linear Rarely, adults develop erythematous eyelid edema and flagellate erythema
*If the patient has an overlap syndrome, true lupus erythematosus or systemic sclerosis might be present.

Table 42.7 Differential diagnosis of dermatomyositis. SLE, systemic lupus erythematosus.

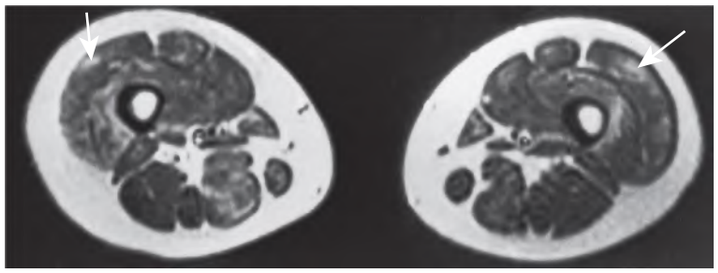

Fig. 42.14 T2-weighted MR images of the proximal thigh in a patient with dermatomyositis. Note the increased signal intensity, primarily in the extensor muscles (white color, arrows). The increased signal correlates with inflammation.

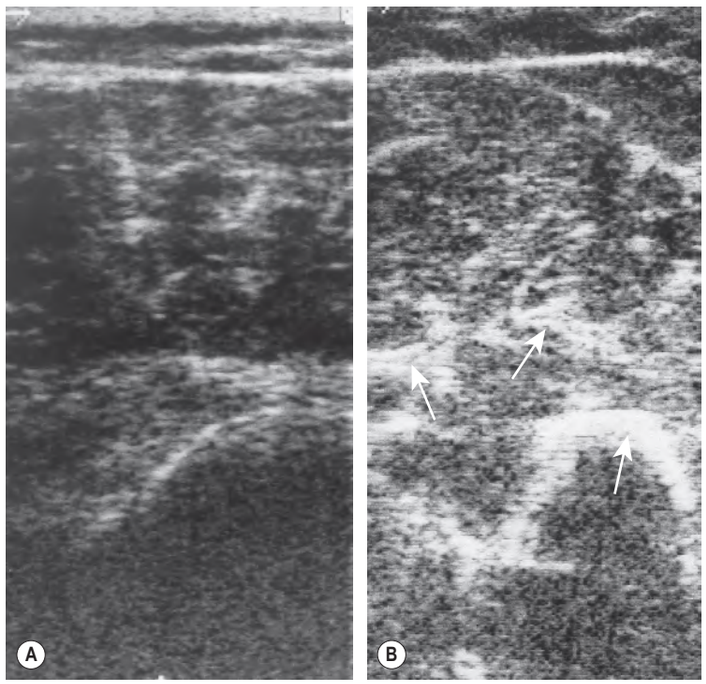

Fig. 42.15 Ultrasound images of the triceps muscle. A Cross-sectional ultrasound image from normal (control) triceps muscle. **B** Ultrasound image from affected triceps muscle in a patient with dermatomyositis. An increase in interstitial echoes is seen (arrows). This image highlights the triceps muscle, which is a higher yield biopsy site in dermatomyositis given that the deltoid muscle is often relatively spared until late in the disease.

Electromyography (EMG) is a sensitive but nonspecific test in patients with dermatomyositis. Over 90% of patients with classic dermatomyositis have abnormal EMG results. In the absence of classic cutaneous lesions, the muscle biopsy is a very important test for confirming the diagnosis and excluding other inflammatory myopathies. Surgeons will usually biopsy the deltoid muscle for convenience, but this muscle is relatively spared until late in the disease; therefore, the surgeon should be directed to perform a triceps muscle biopsy.

MRI (see Fig. 42.14) and ultrasound (see Fig. 42.15) of muscles are sensitive tests that can add greatly to patient evaluation. Both can be used to determine the appropriate site for a muscle biopsy[50]. Ultrasound is less expensive and easier to perform sequentially. MRI may be the most sensitive test for muscle disease, but it is more expensive[50,71]. In children with juvenile dermatomyositis, bilateral thigh MRI utilizing a myositis protocol is considered standard of care in many medical centers. MRI may also be useful in evaluating children for soft tissue changes that might precede calcinosis cutis[71].

TREATMENT

A therapeutic ladder for the treatment of patients with dermatomyositis is summarized in Table 42.8. As with many rare dermatologic diseases, there are few double-blind, placebo-controlled trials. However, a dermatology-based case series supported the belief that a number of patients (75%–85%) can become muscle disease-free, off treatment, after a period of 24–48 months, utilizing a slow corticosteroid taper[60]. Long-term follow-up of pediatric patients also confirmed this conclusion[45,72]. There is a clear discordance between response of the muscle disease to therapy and response of the skin disease[60]. Available therapy for the skin disease is clearly inadequate, with many patients experiencing persistent cutaneous disease and pruritus, especially of the scalp, which can become major complaints once the muscle disease is under control. Aggressive topical therapy and systemic therapy (e.g. antimalarials and/or weekly methotrexate) added specifically for the skin disease often do not provide adequate relief. However, it is clear that, except in adult patients with an advanced malignancy, the prognosis for corticosteroid-treated dermatomyositis in children and adults is excellent, especially when compared with a mortality rate of up to 50% in the pre-corticosteroid era[45].

The treatment of dermatomyositis must take into account the discordance between the response of the muscle disease and that of the dermatologic disease to systemic therapy. If *muscle disease* is confirmed, then

Downloaded for Anonymous User (n/a) at Egyptian Knowledge Bank from ClinicalKey.com by Elsevier on March 10, 2024. For personal use only. No other uses without permission. Copyright ©2024. Elsevier Inc. All rights reserved.

THERAPEUTIC LADDER FOR DERMATOMYOSITIS
Systemic therapy
Oral prednisone: 1 mg/kg/day tapered to 50% over 6 months and to zero over 2–3 years (1) Option to use pulse, split-dose, or alternate-day (2)
Methotrexate: 5–25 mg weekly po, sc, IM (2)
Azathioprine: 2–3 mg/kg/day po (1)
Others: IVIg (2 g/kg/month) (1) Mycophenolate mofetil (1–1.5 g po twice daily) (2) Rituximab (375 mg/m^2 IV weekly × 4) (1) Pulse cyclophosphamide (0.5–1.0 g/m^2 IV monthly) (2) Cyclosporine (3–5 mg/kg/day po) (2) Tacrolimus (0.12 mg/kg/day po) (3) Sirolimus (5 mg/day × 2 weeks, 2 mg/day × 2 weeks, then 1 mg/day po) (3) TNF inhibitors (e.g. infliximab, etanercept) (3)* Fludarabine (3) Hematopoietic stem cell transplantation (3) Plasmapheresis (3)†
Cutaneous lesions
Photoprotection including sunscreens (high SPF including protection against UVA) and clothing (3) Topical corticosteroids (3) Topical tacrolimus (3) Hydroxychloroquine (5 mg/kg divided over two doses daily [up to 200 mg po twice daily]; increased frequency of drug eruptions in patients with dermatomyositis) or chloroquine (250 mg po daily) (2) Hydroxychloroquine (200 mg twice daily) or chloroquine (250 mg po daily) *plus* quinacrine (100 mg po daily) (3) Low-dose weekly methotrexate (5–25 mg weekly po, sc, IM) (2) Mycophenolate mofetil (3) IVIg (2 g/kg/month) (1) Lenabasum (cannabinoid receptor type 2 agonist) (1) Tofacitinib (5–10 mg daily or 11 mg extended-release daily) (2) Rituximab (750 mg/m^2 up to 1 g IV weekly × 2 – *or* – 1 g IV every other week × 2 doses – *or* – 375 mg/m^2 IV weekly × 4) (1) Oral tacrolimus (3) Retinoids (3) Apremilast (3) Dapsone (3) Thalidomide (3) Leflunomide (3) Antiestrogens (e.g. tamoxifen, anastrazole) (3) TNF inhibitors (e.g. infliximab, etanercept) (3)* Low-dose naltrexone (4.5 mg nightly maximum dose) (3)
*Reported to cause drug-induced dermatomyositis and to induce disease flares in patients with pre-existing dermatomyositis; hence, most experts recommend avoiding these agents in patients with dermatomyositis. †Double-blind trial showed no benefit.

Table 42.8 Therapeutic ladder for dermatomyositis. Dazukibart, which targets interferon beta 1, led to a reduction in cutaneous lesions in a phase II placebo-controlled trial. Key to evidence-based support: (1) prospective controlled trial; (2) retrospective study or large case series; (3) small case series or individual case reports. IM, intramuscular; IV, intravenous; IVIg, intravenous immunoglobulin; po, oral; sc, subcutaneous; SPF, sun protection factor.

systemic corticosteroid therapy is initiated in doses aimed at control of the myositis (i.e. generally prednisone 1 mg/kg/day). Patients with dermatologic manifestations alone can be treated as described below, with repeated clinical muscle examination and enzyme screening (generally CK and aldolase) at 2- to 3-month intervals.

If CK and aldolase serum levels are minimally elevated and corticosteroid therapy is initiated early, the disease generally comes under control rapidly over 2–4 weeks, with a taper to half the starting dose by 6 months. If the disease is advanced and enzyme levels are high (e.g. CK >1000 U/L), the disease can be much more difficult to control and often requires intravenous pulse corticosteroids plus early initiation of a steroid-sparing agent such as low-dose weekly methotrexate. Again, an attempt is made to taper the prednisone to 0.5 mg/kg/day in a single morning dose by 6–8 months.

Attention to general health maintenance principles and osteoporosis prevention is a key element of patient management (see Ch. 125). This can be accomplished by joint longitudinal care with an internist or pediatrician. Adults also need frequent (e.g. every 4–6 months for at least 3 years) complete physical examinations for malignancy.

Children with juvenile dermatomyositis should be followed at least twice yearly by a pediatrician comfortable with monitoring their developmental milestones while on immunosuppressive therapy. In addition, lipodystrophy and metabolic abnormalities, including hypertriglyceridemia and insulin resistance, have become increasingly recognized as potential complications of juvenile dermatomyositis[73,74].

When muscle disease is present, there is support for steroid-sparing therapies (especially in the setting of severe or recalcitrant disease), including IVIg[75–77], methotrexate[78], azathioprine[79], mycophenolate mofetil[80,81], rituximab[82,83], pulse cyclophosphamide[84,85], and cyclosporine (also for lung disease)[86]. Less often tacrolimus[87,88], sirolimus[89], infliximab[90], fludarabine[91], and hematopoietic stem cell transplantation[92] are used. Caution should be exercised if TNF inhibitors are being considered as cases of drug-induced and drug-exacerbated dermatomyositis have been reported. Consequently, many experts recommend avoiding these agents in patients with dermatomyositis.

Of the limited number of randomized, controlled trials performed to date, two assessed IVIg, with both demonstrating benefit in both muscle and skin disease[76,77], and one examined rituximab. The rituximab trial failed to reach its primary and secondary endpoints for muscle disease, but this was potentially related to study design – muscle disease improved in 83% of patients and a steroid-sparing effect was noted[83]. In this trial, none of the core measures of disease activity were skin-specific and no validated skin score was used; however, follow-up analysis utilizing a cutaneous visual analog scale demonstrated improvement of skin disease in both adult and juvenile dermatomyositis[93]. In contrast, a pilot trial of rituximab that used a validated skin score found no improvement in cutaneous disease activity[94]. A small, randomized pilot study that investigated abatacept for muscle disease in both dermatomyositis and polymyositis observed a reduction in disease activity in nearly 50% of treated patients[95]. Notably, a placebo-controlled study showed no benefit from plasmapheresis or leukapheresis in dermatomyositis[96]. In children with severe or refractory disease, IVIg is often administered[97].

Adjunctive physical therapy is also very important in improving muscle strength and endurance[98]. Benefits of exercise and rehabilitation have been demonstrated, even in the course of active disease, without inducing flares of the myositis[99].

Dermatologic disease can be particularly challenging therapeutically, and not all patients clear their cutaneous manifestations when their muscle disease remits. Patients with dermatologic disease without active muscle disease are generally not treated with systemic corticosteroids as a mainstay of their therapy, and they often present a unique therapeutic challenge. As a result, the treatment of amyopathic dermatomyositis often differs significantly from the treatment of classic dermatomyositis in that systemic corticosteroids are not traditionally utilized.

For cutaneous disease, anecdotal reports, case series, retrospective reviews, and limited prospective data support the use of topical corticosteroids, topical tacrolimus[100], antimalarial therapy[101,102] (either as monotherapy or in combination but with a less dramatic effect than in cutaneous LE), low-dose weekly methotrexate, mycophenolate mofetil[103], IVIg[76,104,105], dapsone[106], tofacitinib[107–109], and thalidomide[110], as well as additional agents listed in Table 42.8. Of note, there is an increased risk of a cutaneous drug reaction to hydroxychloroquine in patients with dermatomyositis as compared to those with LE[111]. This medication is still frequently used as first-line therapy, but a pre-treatment warning is recommended. Some patients who develop a cutaneous reaction to hydroxychloroquine may tolerate chloroquine[111].

Clinical studies to support a specific treatment algorithm for cutaneous dermatomyositis are lacking. A common therapeutic approach includes a trial of antimalarials for mild cutaneous disease, whereas patients with moderate to severe skin disease are often treated with methotrexate, mycophenolate mofetil, and/or IVIg[112]. As noted previously, antimalarials are considered less effective for cutaneous dermatomyositis as compared to cutaneous LE. In fact, one study

Downloaded for Anonymous User (n/a) at Egyptian Knowledge Bank from ClinicalKey.com by Elsevier on March 10, 2024. For personal use only. No other uses without permission. Copyright ©2024. Elsevier Inc. All rights reserved.

demonstrated that only 11% of patients with clinically amyopathic dermatomyositis achieved adequate control of their skin disease with antimalarial therapy[113].

Calcinosis cutis may respond to diltiazem and/or surgical excision[114]; other therapies include low-dose warfarin, bisphosphonates, probenecid, colchicine, TNF inhibitors, aluminum hydroxide, sodium thiosulfate, and electric shock wave lithotripsy (ESWL). Early and aggressive therapy of juvenile dermatomyositis does seem to reduce the risk of calcinosis cutis, which is often extremely challenging to treat[45].

Additional figures available in our eBook (see inside front cover for access code).