Erythroderma 10

Sean Whittaker

Synonyms: ▪ Exfoliative dermatitis ▪ Exfoliative erythroderma ▪ Red man syndrome (becoming historical term)

Key features

- Erythroderma is clinically defined as erythema and scaling involving >80% of the body surface area
- Systemic manifestations include peripheral edema, tachycardia, loss of fluid and proteins, and disturbances in thermoregulation
- Erythroderma has multiple etiologies; in adults, the most common causes are psoriasis, drug reactions, atopic dermatitis, and cutaneous T cell lymphoma (CTCL)
- Establishing the correct diagnosis requires consideration of initial sites of involvement, additional clinical findings, histopathologic and molecular features, and associated systemic abnormalities, as well as a complete medical history
- Despite an intensive evaluation, the cause remains unknown (idiopathic) in ~25% of patients; some of these patients eventually develop CTCL
- Treatment strategies should address the dermatologic disease as well as the underlying etiology and the systemic complications of the erythroderma

INTRODUCTION

Erythroderma is defined as generalized erythema and scaling involving >80% of the body surface area (BSA). However, it does not represent a defined entity, but rather is a striking and severe clinical presentation that can arise from a variety of diseases. Most commonly, erythroderma is due to generalization of pre-existing dermatoses (such as psoriasis or atopic dermatitis), drug reactions, or cutaneous T cell lymphoma (CTCL). Although up to 50% of the patients have a history of more localized skin lesions prior to the onset of the erythroderma, identification of the underlying disease process represents one of the most complex challenges in dermatology. Sustained efforts during longitudinal evaluation may lead to the precise identification of the etiology. In approximately one-quarter of the patients, no specific etiology is found, and these cases are called "idiopathic erythroderma".

Attention should also be focused on the potential systemic complications of acute erythroderma. Hypothermia, peripheral edema, and loss of fluid, electrolytes and albumin with subsequent tachycardia and cardiac failure are serious threats to the erythrodermic patient. In addition, chronic erythrodermas may be accompanied by cachexia, diffuse alopecia, palmoplantar keratoderma, nail dystrophy, and ectropion.

HISTORICAL PERSPECTIVE

The term "erythroderma" was introduced in 1868 by Hebra to describe an exfoliative dermatitis involving more than 90% of the skin surface. Based upon the clinical course, erythroderma was classified into chronically relapsing (Wilson–Brocq), chronically persisting (Hebra), and self-limiting epidemic (Savill) variants. However, these subdivisions are no longer employed. Even though originally more strictly defined as erythema and scaling involving >90% of BSA, nowadays the term erythroderma is often more liberally applied when there is >80% of BSA involvement.

EPIDEMIOLOGY

No precise data exist regarding the prevalence or incidence of erythroderma as most reports are retrospective but an overall incidence of 1 per 100 000 has been proposed. Large series of patients have focused on male-to-female ratios, average age, and underlying diseases[1–7]. Men are more commonly affected, with the male-to-female ratio ranging from approximately 2:1 to 4:1. An even higher ratio can be found in the subset of idiopathic erythroderma, also referred to as "red man syndrome" (not to be confused with the acute cutaneous reaction to rapid infusion of vancomycin). The average age at onset of erythroderma in these series was 52 years, with an average of 48 years in those including children, and 60 years in series excluding them[1,3,4,6].

Based upon several large series of patients, dermatitis (24%), psoriasis (20%), drug reactions (19%), and CTCL (8%; including Sézary syndrome and erythrodermic mycosis fungoides [MF]) represented the most common underlying causes of erythroderma[1–7]. In a more recent prospective study of over 300 patients, CTCL was diagnosed in a higher proportion of patients (18%)[8], but this could represent tertiary care referral bias or greater access to molecular diagnostics[9]. When categories within the dermatitis group were examined, atopic dermatitis (9%) was the most common type, followed by contact dermatitis (6%), seborrheic dermatitis (4%), and chronic actinic dermatitis (3%)[1,3,4,6]. With regard to etiology, no specific geographic differences have been noted[7,10]. In adults with erythroderma, overall relapse rates at one year range from 20% to 30%.

For adults, uncommon causes include pityriasis rubra pilaris, ichthyoses, bullous dermatoses (usually pemphigus foliaceus), graft-versus-host disease (GVHD), infestations (most often scabies), and autoimmune connective tissue diseases (acute lupus erythematosus, juvenile dermatomyositis). Table 10.1 lists additional unusual causes, from paraneoplastic (e.g. lymphoma, solid organ malignancies) to inflammatory (e.g. sarcoidosis) and neoplastic (e.g. hypereosinophilic syndrome). Despite multiple skin biopsies, an in-depth clinical investigation and a detailed medical history, the underlying cause of erythroderma is not found in at least 25% of patients. Unfortunately, cases of idiopathic erythroderma tend to be chronic and are more likely to recur after treatment[7].

Erythroderma in neonates and infants is rare and causes include inherited ichthyoses, dermatitides, psoriasis, immunodeficiencies[12] (e.g. Omenn syndrome), and consequences of infection (e.g. staphylococcal scalded skin syndrome) (Table 10.2)[13]. In addition, the possibility of drug-induced erythroderma should always be considered.

PATHOGENESIS

The pathogenetic mechanisms of the underlying diseases will be discussed in the respective chapters. The pathways involved in the *de novo* genesis of erythroderma or the generalization of pre-existing skin lesions are not well understood. The number of germinative keratinocytes as well as their mitotic rate is increased in erythrodermic skin, and the transit time of cells through the epidermis is shortened. Consequently, scales consist of material normally retained by the skin (nucleic acids, amino acids, soluble protein), and the daily loss of scales increases from 500–1000 mg to 20–30 g[14]. In acute erythroderma, the desquamated material usually has marginal metabolic significance, but in chronic erythroderma protein loss can be significant, leading to hypoalbuminemia and contributing to anemia of chronic disease. Given that the peak age of onset is during the 6th to 7th decade of life, it is possible that age-related immune senescence is a contributory factor in the development of idiopathic erythroderma. Likewise, the striking presentation of erythroderma in children with immunodeficiencies supports a role for immune dysregulation. Erythroderma in neonates often has a genetic basis and molecular diagnostics can play an important role in identifying causative mutations[15].

Downloaded for Anonymous User (n/a) at Egyptian Knowledge Bank from ClinicalKey.com by Elsevier on March 10, 2024. For personal use only. No other uses without permission. Copyright ©2024. Elsevier Inc. All rights reserved.

CAUSES OF ERYTHRODERMA IN ADULTS			
Underlying disease	**Clinical clues**	**Histologic clues**	**Additional hints**
Common			
Psoriasis (Ch. 8)	• Pre-existing psoriatic plaques or lesions of pustular psoriasis • Often spares the central face • Nail changes (oil-drop, pits, onycholysis) • Subcorneal pustules • Inflammatory arthritis	• Confluent or focal parakeratosis • Epidermal hyperplasia with bottleneck-like rete ridges • Tortuous vessels in a slightly edematous papillary dermis • Neutrophils within epidermis; sparse lymphohistiocytic infiltrate within dermis • Often reduced or absent granular layer	• Personal or family history of psoriasis • Withdrawal of corticosteroids, methotrexate, cyclosporine or targeted immunomodulators ("biologics") • Receiving medication that can exacerbate psoriasis (e.g. lithium, hydroxychloroquine, dupilumab)
Atopic dermatitis (Ch. 12)	• Pre-existing lesions (flexures) • Severe pruritus • Lichenification, including eyelids • Prurigo nodularis	• Mild to moderate acanthosis • Variable spongiosis • Dermal eosinophils • Parakeratosis • Variable lymphohistiocytic infiltrate with exocytosis of lymphocytes • Variable dermal edema	• Elevated serum IgE, eosinophilia • Personal or family history of atopy (e.g. asthma, allergic rhinitis, atopic dermatitis) • Cataracts/keratoconus
Drug reactions (Ch. 21)	• Preceded by morbilliform or scarlatiniform exanthem • Facial edema • In dependent areas, may become purpuric	• Variable patterns, including perivascular, lichenoid, spongiotic, and pseudolymphomatous • Eosinophils can be present, irrespective of pattern • Vacuolar degeneration of basal layer • SJS/TEN: apoptotic keratinocytes at all levels of epidermis • DRESS/DIHS: spongiotic and lichenoid patterns	• No history of skin diseases • More acute onset • Usually resolves within 2–6 weeks after withdrawal of responsible drug; possible exception is DRESS/DIHS • More common in HIV-infected patients • Specific HLA alleles increase risk (see Table 21.3)
Idiopathic erythroderma	• Elderly men • Chronic, relapsing • Severe pruritus • Palmoplantar keratoderma • Dermatopathic lymphadenopathy	• Nonspecific • Acute forms – parakeratosis, spongiosis, and a moderate lymphohistiocytic infiltrate • Chronic forms – compact ortho- and/or hyperparakeratosis, psoriasiform acanthosis, and expanded papillary dermis	• Consider less commonly associated drugs (see Table 10.3) • Continue to re-evaluate for cutaneous T cell lymphoma, including serial skin biopsies
Less common			
Cutaneous T cell lymphoma (Sézary syndrome > erythrodermic mycosis fungoides) (Ch. 120)	• Intense pruritus with excoriations; can develop lichenification or prurigo nodularis • Deep purple–red hue; pigmentary changes (melanoerythroderma) • Infiltration and/or edema; leonine facies • Painful, fissured palmoplantar keratoderma • Alopecia • Lymphadenopathy • Nail dystrophy	• Cerebriform pleomorphic lymphocytes • Clustering of atypical cells within epidermis uncommon • Band-like and occasionally lichenoid infiltrate • Cutaneous histology is non-diagnostic in at least 30% of patients with Sézary syndrome	• Sézary syndrome: peripheral blood $CD4^+$ lymphocytosis (≥1000 Sézary cells/mm^3; CD4/CD8 ratio ≥10; ≥40% $CD4^+/CD7^-$; or ≥30% $CD4^+/CD26^-$) • Sézary syndrome: detection of identical clonal T cell population in skin and lymph node/blood • Erythrodermic MF: variable presence of T cell clone in blood • Erythrodermic MF: lower levels or no Sézary cells (see Table 120.4) • Can mimic several other causes of erythroderma
Dermatitis (non-atopic), including contact (Chs. 14 and 15) and stasis with autosensitization (Ch. 13)	• Pre-existing localized disease • Distribution of initial lesions	• Variable spongiosis	• Occupation and hobbies • Patch testing • Review oral medications (systemic contact dermatitis)
Uncommon			
Pityriasis rubra pilaris (Ch. 9)	• Salmon-colored erythema • Islands of sparing (nappes claires) • Waxy keratoderma • Perifollicular keratotic papules	• Psoriasiform epidermal hyperplasia • Granular layer is normal • Alternating parakeratosis and orthokeratosis, both vertically and horizontally • Follicular plugs with "shoulder parakeratosis" • No neutrophils	• Flare after sun exposure • Cephalocaudal progression • Appearance of erythema gyratum-like lesions as erythroderma improves
Paraneoplastic erythroderma	• Fine scaling • Melanoerythroderma • Cachexia	• Nonspecific changes (skin does not contain malignant cellular infiltrates)	• Lymphoproliferative disorders, including lymphomas other than Sézary syndrome, and rarely thymomas • In the case of solid-organ malignancies, usually late-stage

Table 10.1 Causes of erythroderma in adults.

Downloaded for Anonymous User (n/a) at Egyptian Knowledge Bank from ClinicalKey.com by Elsevier on March 10, 2024. For personal use only. No other uses without permission. Copyright ©2024. Elsevier Inc. All rights reserved.

CAUSES OF ERYTHRODERMA IN ADULTS			
Underlying disease	**Clinical clues**	**Histologic clues**	**Additional hints**
Bullous dermatoses (Chs. 29 and 30) and inherited ichthyoses (Ch. 57)			
Pemphigus foliaceus	• Pre-existing lesions, often on upper trunk • Impetigo-like erosions and vesicles • Moist scale-crust; cornflake scale	• Acantholysis within the superficial epidermis • DIF, intercellular IgG	• IIF, intercellular • Anti-DSG1 Ab
Bullous pemphigoid	• Urticarial plaques • Tense bullae • Elderly patients	• Interface dermatitis and spongiosis; subepidermal blisters may be present • Many eosinophils, in part along the DEJ • DIF, BMZ C3 and IgG	• IIF, BMZ • Anti-BP180/BP230 Ab for longitudinal evaluation
Paraneoplastic pemphigus	• Mucosal erosions and hemorrhagic crusts • Erythema multiforme-like lesions • Mucocutaneous lichenoid lesions	• Interface dermatitis with necrotic keratinocytes • Parakeratosis • Focal acantholysis • DIF, intercellular and BMZ IgG	• IIF, intercellular and BMZ (+ IIF rat bladder)
Inherited ichthyoses	• Present from birth or early infancy (see Table 10.2)	• See Table 10.2	• See Table 10.2
Rare			
Papuloerythroderma of Ofuji	• Widespread, pruritic, flat-topped, red–brown papules that can become confluent • Sparing of skin folds ("deck-chair" sign) • Favors elderly men	• Dense perivascular infiltrate of lymphocytes and eosinophils in the upper to mid dermis	• Multiple etiologies, including CTCL > atopy, other lymphomas; drugs (e.g. DDI, aspirin); infections (e.g. HIV, hepatitis C virus); paraneoplastic phenomenon • May have peripheral eosinophilia, lymphopenia
Chronic actinic dermatitis (Ch. 87)	• Initial lesions in photodistribution • Allergic airborne contact dermatitis to *Compositae*	• Lichenoid infiltrate of lymphocytes and epidermal exocytosis • Acanthosis of epidermis and compact hyperkeratosis • Possible lymphocyte nuclear pleomorphism	• Drug history • UVA, UVB and visible light phototesting • Photopatch testing
Other unusual causes			
• Crusted (Norwegian) scabies • Dermatophyte infection • Leprosy • Toxic shock syndrome (usually staphylococcal) • Toxic exfoliative shock syndrome associated with SARS-CoV-2[11] • Primary immunodeficiencies • Lichen planus • Autoimmune connective tissue disease (e.g. acute or subacute cutaneous lupus erythematosus, juvenile dermatomyositis [adolescents])		• GVHD • Sarcoidosis • Hypereosinophilic syndrome • Other T cell hematologic malignancies (e.g. adult T cell leukemia/lymphoma, angioimmunoblastic T cell lymphoma, T cell prolymphocytic leukemia) • Mastocytosis • Langerhans cell histiocytosis	

Table 10.1 Causes of erythroderma in adults. Ab, antibody; BMZ, basement membrane zone; DDI, dideoxyinosine; DEJ, dermal–epidermal junction; DIF, direct immunofluorescence; DIHS, drug-induced hypersensitivity syndrome; DRESS, drug reaction with eosinophilia and systemic symptoms; GVHD, graft-versus-host disease; HIV, human immunodeficiency virus; IIF, indirect immunofluorescence; SJS, Stevens–Johnson syndrome; TEN, toxic epidermal necrolysis.

CAUSES OF ERYTHRODERMA IN NEONATES AND INFANTS			
Underlying disease	**Clinical clues**	**Histologic clues**	**Additional findings**
Inherited ichthyoses (Ch. 57)			
Non-syndromic			
Congenital ichthyosiform erythroderma	• Collodion baby • Generalized scaling involving flexures • Cicatricial alopecia, nail dystrophy, often palmoplantar hyperkeratosis • Ectropion	• Non-diagnostic	• Autosomal recessive • Mutations in multiple genes, e.g. *TGM1*, *ALOXE3*, *ALOX12B* (encode transglutaminase 1 and arachidonate lipoxygenases); see Table 57.1 for complete list
Epidermolytic ichthyosis	• Formation of superficial blisters and erosions during the first days of life • Later, corrugated hyperkeratosis in flexural areas	• Classic epidermolytic hyperkeratosis	• Autosomal dominant, very rarely autosomal recessive • Mutations in *KRT1* and *KRT10* (encode keratins 1 and 10)

Table 10.2 Causes of erythroderma in neonates and infants.

Continued

Downloaded for Anonymous User (n/a) at Egyptian Knowledge Bank from ClinicalKey.com by Elsevier on March 10, 2024. For personal use only. No other uses without permission. Copyright ©2024. Elsevier Inc. All rights reserved.

CAUSES OF ERYTHRODERMA IN NEONATES AND INFANTS			
Underlying disease	**Clinical clues**	**Histologic clues**	**Additional findings**
Syndromic			
Netherton syndrome	• Atopic-like dermatitis • Food allergies • Immune deficiency • Erythroderma in neonates • Erythroderma may persist or ichthyosis linearis circumflexa develops • Examine eyebrows and eyelashes as well as scalp hairs for trichorrhexis invaginata ("bamboo hair") • Failure to thrive	• Routine histology – non-diagnostic • Loss of tissue LEKTI expression	• Autosomal recessive • Elevated serum IgE levels • Mutations in *SPINK5* (encodes serine peptidase inhibitor, Kazal type 5, also known as lympho-epithelial Kazal-type-related inhibitor [LEKTI])
Conradi–Hünermann–Happle syndrome (X-linked dominant chondrodysplasia punctata)	• Linear and swirled pattern • Skeletal (chondrodysplasia punctata) and ocular anomalies (cataracts)	• Hyperkeratosis, reduced granular layer, follicular plugging with dystrophic calcification	• Mutations in *EBP* (encodes emopamil binding protein [sterol isomerase])
• Other rare ichthyoses and related disorders, e.g. trichothiodystrophy, keratitis–ichthyosis–deafness (KID) syndrome, Sjögren–Larsson syndrome, neutral lipid storage disease with ichthyosis, ichthyosis with confetti, ichthyosis prematurity syndrome, generalized inflammatory peeling skin syndrome, severe dermatitis–multiple allergies–metabolic wasting (SAM) syndrome, other desmosomal disorders, inflammatory skin and bowel disease*			
Immunodeficiencies (Ch. 60)			
Omenn syndrome	• Onset in neonatal period • Exfoliative erythroderma with diffuse alopecia • Lymphadenopathy and hepatosplenomegaly • Recurrent infections • Diarrhea	• Apoptosis of keratinocytes • Vacuolization of basal keratinocytes • Dense dermal infiltrate (predominantly T cells) • Acanthosis, parakeratosis • Degeneration of subcutaneous fat lobules	• Leukocytosis, peripheral eosinophilia • Hypogammaglobulinemia • Elevated serum IgE levels • Lymph nodes: disruption of germinal centers and abundant $S100^+$ interdigitating reticulum cells • Classically, *RAG1* or *RAG2* mutations, but this phenotype can also result from mutations in other genes causing SCID (see Ch. 60)
Other forms of SCID, agammaglobulinemia, complement deficiencies (e.g. C3, C5), IPEX syndrome	• "Leiner phenotype" of exfoliative dermatitis, chronic diarrhea, and recurrent infections	• Non-diagnostic	• See Ch. 60 • Many different genetic etiologies
Wiskott–Aldrich syndrome	• Primarily affects boys • Petechiae, ecchymoses • Atopic-like dermatitis • Recurrent sinopulmonary infections	• Non-diagnostic	• Microthrombocytopenia • Lymphopenia, peripheral eosinophilia • Elevated serum IgE levels • Mutations in *WAS*
• Other primary immunodeficiencies, e.g. DiGeorge syndrome and hyper IgE syndromes • GVHD (e.g. maternal–fetal or transfusion-related) in the setting of SCID (see Fig. 10.11; Ch. 52)			
Primary dermatoses			
Atopic dermatitis (Ch. 12)	• Crusted eczematous lesions on extensor surfaces, face, scalp • Spares diaper area • Pruritus • Onset week 6–16	• See Table 10.1	• See Table 10.1
Seborrheic dermatitis (Ch. 13)	• Greasy, scaling plaques and satellite papules on scalp and in skin folds • Diaper area involvement • Non-pruritic • Early onset (week 2–12)	• Psoriasiform hyperplasia of the epidermis with parakeratosis • Nonspecific inflammatory infiltrate	
Psoriasis (Ch. 8)	• Silvery white scaling and sharply demarcated plaques on face, elbows, and knees • Diaper area involvement • Nail pits • Usually later onset	• See Table 10.1	• Family history of psoriasis • See Table 10.1 • Familial erythrodermic psoriasis (and PRP) can be due to activating mutations in *CARD14* and may respond to ustekinumab • Generalized pustular psoriasis seen in DITRA and (together with sterile osteolysis and neonatal distress) DIRA (see Table 45.7)
• Other primary dermatoses, e.g. pityriasis rubra pilaris and CARD14-associated papulosquamous eruption (Ch. 9)			

Table 10.2 Causes of erythroderma in neonates and infants.

Downloaded for Anonymous User (n/a) at Egyptian Knowledge Bank from ClinicalKey.com by Elsevier on March 10, 2024. For personal use only. No other uses without permission. Copyright ©2024. Elsevier Inc. All rights reserved.

CAUSES OF ERYTHRODERMA IN NEONATES AND INFANTS			
Underlying disease	**Clinical clues**	**Histologic clues**	**Additional findings**
Drug reactions (Tables 10.1 and 10.3)			
Infections			
Staphylococcal scalded skin syndrome	• Temperature instability/low-grade fever • Irritability • Skin-fold accentuation • Large areas of tender erythema • Superficial bulla formation followed by desquamation • Radiating perioral scale-crusts • Extracutaneous staphylococcal infections often responsible	• Blister roof consists of the cornified layer and parts of the granular layer • Subcorneal blisters contain sparse acantholytic keratinocytes and only a few neutrophils and lymphocytes	• Positive culture for *Staphylococcus aureus* (conjunctivae, nares, throat, umbilicus, rectum) • Identification of exfoliative toxins (ET-A & ET-B) via slide latex agglutination, double immunodiffusion, or ELISA (see Ch. 74) • ET-A produced by *S. aureus* specifically cleaves desmoglein 1
Neonatal "toxic shock-like" exanthematous disease	• Generalized diffuse macular erythema or morbilliform eruption with confluence • Minimal scaling • Fever • Occurs during first week of life		• Colonization of umbilical stump, nasopharynx or skin with TSST-1-producing MRSA • Thrombocytopenia • Reported primarily in Japan
Congenital cutaneous candidiasis	• Maternal vaginal *Candida* infection with intrauterine spread • Pustules, collarettes of scale • Oral cavity spared • May have paronychia and nail dystrophy	• Yeast and pseudohyphae in the stratum corneum (PAS) • Subcorneal and spongiform pustules within the epidermis	• KOH examination, fungal culture
• Other infections and infestations, including viral exanthems (e.g. parechovirus), syphilis, and scabies			
Others			
• Ectodermal dysplasias*, e.g. ankyloblepharon–ectodermal dysplasia–clefting (AEC) syndrome, hypohidrotic ectodermal dysplasia with immune deficiency (Ch. 63), neonatal inflammatory skin and bowel syndrome type 1 due to *ADAM17* mutations (psoriatic erythroderma) • Nutritional and enzyme deficiency diseases such as kwashiorkor, organic acidurias, cystic fibrosis, specific deficiencies (e.g. zinc, essential fatty acids, biotin), and Gaucher disease (Chs. 51 and 63)			
*Desmosomal disorders characterized by erythrokeratodermia, ectodermal dysplasia, and/or skin fragility may also present with neonatal erythroderma (Chs. 56 and 57)			

Table 10.2 Causes of erythroderma in neonates and infants. CARD14, caspase recruitment domain family member 14; DIRA, deficiency of interleukin-1 receptor antagonist; DITRA, deficiency of interleukin-36 receptor antagonist; ELISA, enzyme-linked immunosorbent assay; IPEX, immune dysregulation, polyendocrinopathy, enteropathy, X-linked; MRSA, methicillin-resistant *Staphylococcus aureus*; SCID, severe combined immunodeficiency; TSST-1, toxic shock syndrome toxin 1.

CLINICAL FEATURES

Cutaneous Manifestations

Erythroderma is clinically defined by the presence of erythema and scaling involving more than 80% of the skin surface. Based upon its clinical course, erythroderma can be classified into primary or secondary types. In the primary form, the erythema (often initially on the trunk) extends within a few days or weeks to involve the entire skin surface, accompanied by the development of scaling (Fig. 10.1). The secondary form of erythroderma is defined as a generalization of a preceding localized skin disease – for example, psoriasis or atopic dermatitis. An acute onset most commonly occurs when the underlying cause is a drug reaction or dermatitis.

With the exception of very slowly progressing secondary erythroderma, erythema precedes the development of exfoliation by 2–6 days. The associated scaling varies extensively in size and color depending upon the stage of the erythroderma and nature of the underlying disease. During acute phases, scales are usually large and crusted, whereas in chronic states they tend to be smaller and drier. Occasionally, the cause of the erythroderma is suggested by the character of the scale – for example, fine in atopic dermatitis or dermatophytosis, bran-like in seborrheic dermatitis, crusted in pemphigus foliaceus, and exfoliative (i.e. peeling) in drug reactions. The color of the skin can also vary, from pink or red to reddish brown to deep red or purple.

Pruritus, the most frequent complaint, is observed in up to 90% of patients and it varies according to the underlying cause, but is most severe in patients with dermatitis or Sézary syndrome[16]. Given the itch–scratch cycle, the skin may become thickened, and areas of lichenification are seen in one-third of cases. Patients, especially those with a chronic erythroderma, may develop dyspigmentation, with hyperpigmentation (40/90 patients, 45%) observed more frequently than hypo- or depigmentation (18/90 patients, 20%) in one series[4]. Palmoplantar keratoderma appears in ~30% of erythrodermic patients and is often an early sign in pityriasis rubra pilaris[16]. Keratoderma with scale-crust can point to crusted scabies, whereas a painful and fissured keratoderma can occur in Sézary syndrome.

Fig. 10.1 Erythroderma with desquamation. Obvious exfoliation of scale with underlying erythema.

Downloaded for Anonymous User (n/a) at Egyptian Knowledge Bank from ClinicalKey.com by Elsevier on March 10, 2024. For personal use only. No other uses without permission. Copyright ©2024. Elsevier Inc. All rights reserved.

In cases of pre-existing dermatoses, nail changes may precede the erythroderma (e.g. pits in psoriasis or horizontal ridging in atopic dermatitis), whereas others develop subsequently. Nail changes are said to be present in ~40% of patients. Most often "shiny" nails are observed, but discoloration, brittleness, dullness, subungual hyperkeratosis, Beau's lines, paronychia, and splinter hemorrhages can be seen. The nails may even be totally shed. Diffuse non-scarring alopecia of the scalp or other sites appears in 20% of patients with chronic erythroderma, including those with CTCL. Cicatricial alopecia can also develop in the setting of Sézary syndrome or erythrodermic MF.

Patients with erythroderma can develop multiple seborrheic keratoses, which may be pale in color compared with the background erythema. Colonization of the skin with *Staphylococcus aureus* is common and can lead to secondary cutaneous infections as well as bacteremia. Bilateral ectropion and purulent conjunctivitis can also develop as ocular complications (Fig. 10.2). Lastly, an exacerbation of erythroderma may follow UV irradiation or drug ingestion; this is not necessarily restricted to patients with photosensitive eczema or drug-induced erythroderma[4].

Systemic Manifestations

An awareness of potential systemic complications of erythroderma is essential. Pedal or pretibial edema is observed in ~50% of patients (182/380)[1,3–5], and results from hypoalbuminemia and a shift of fluid into extracellular spaces. In patients with CTCL-associated or drug-induced erythroderma, generalized anasarca can develop. Because of the markedly increased blood flow through the skin and increased fluid loss by transpiration, tachycardia affects 40% of patients, and there is a risk of high-output cardiac failure, particularly in the elderly. Furthermore, increased skin perfusion leads to thermoregulatory disturbances. Although hyperthermia is more frequently observed than hypothermia, most patients describe chilly, rigor-like sensations[1,2,4,6,7,10]. The chronic and excessive loss of heat can lead to compensatory hypermetabolism with subsequent development of cachexia. Anemia, reflecting both iron deficiency and chronic disease, may also be observed in patients with chronic erythroderma.

Fig. 10.2 Ectropion in the setting of erythroderma.

The most common extracutaneous manifestation of erythroderma is peripheral lymphadenopathy, which is found in approximately half of the patients. Even in the absence of an underlying lymphoproliferative disorder, lymphadenopathy may be prominent and, if so, histologic and molecular examination of a lymph node is recommended (in particular, immunophenotypic studies and T cell receptor gene analysis)[17]. A core or excisional lymph node biopsy is preferable to a fine needle aspirate as the former provides sufficient tissue for accurate assessment of nodal architecture and cellular morphology. The major differential diagnosis is between lymphomatous involvement and reactive dermatopathic lymphadenopathy. Prior to histopathologic examination of an enlarged lymph node, a CT or PET-CT scan can identify the most morphologically abnormal and/or fluorodeoxyglucose (FDG)-avid node.

Hepatomegaly occurs in 20% of the cases (113/578), with a slight predominance in erythroderma due to drug-induced hypersensitivity. Splenomegaly is rarely seen and occurs most often in association with systemic lymphoma[1–4,6].

Specific Findings of the Underlying Disease

In addition to the general features previously discussed, the clinical presentation may have features suggestive of the underlying etiology (see Tables 10.1 and 10.2).

Psoriasis

Psoriasis is the most common underlying disorder in adults with erythroderma. Invariably, psoriatic erythroderma is preceded by typical psoriatic lesions (see Ch. 8). Its onset is most often due to withdrawal of potent topical or oral corticosteroids, cyclosporine or methotrexate; occasionally, widespread flares follow a systemic infection, phototoxicity, an irritant contact dermatitis to topical medications such as tar, or withdrawal of targeted immunomodulators ("biologics"). After generalization of the erythema, the typical features of psoriasis are often lost (Fig. 10.3), and generalized pustular psoriasis with disseminated sterile subcorneal pustules may develop (see Fig. 1.6). Due to a slower turnover rate, nail changes, such as oil-drop changes, onycholysis or nail pits, may still be visible and provide clues to the diagnosis of psoriatic erythroderma. Treatment of the erythroderma may result in the subsequent reappearance of characteristic psoriatic plaques.

Atopic dermatitis

Although occurring at any age, erythroderma develops most frequently in patients with a history of moderate to severe atopic dermatitis (Fig. 10.4). As a result, well-established pre-existing lesions can be found, especially when the erythroderma is of recent onset. The pruritus is intense, and secondary excoriations or prurigo-like lesions are frequently observed. Lichenification is often prominent and atrophy of the skin due to topical corticosteroids may be seen. Increased serum IgE and eosinophilia may accompany other signs and symptoms of atopy.

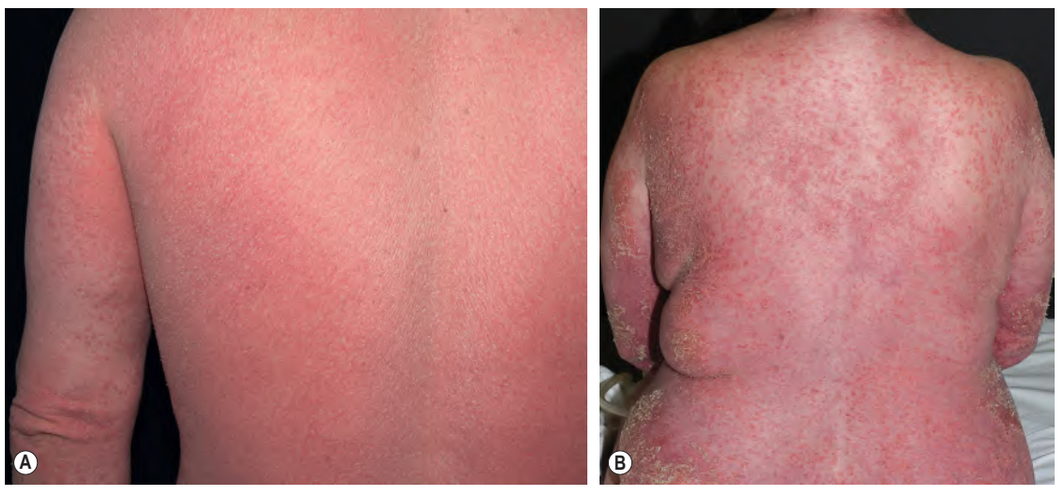

Fig. 10.3 Psoriatic erythroderma. **A** There is diffuse involvement of the trunk but a clue to the diagnosis is the individual lesions on the arm. **B** Significant exfoliation of the lateral trunk and arms. *A, Courtesy Luis Requena, MD; B, Courtesy Lorenzo Cerroni, MD.*

Downloaded for Anonymous User (n/a) at Egyptian Knowledge Bank from ClinicalKey.com by Elsevier on March 10, 2024. For personal use only. No other uses without permission. Copyright ©2024. Elsevier Inc. All rights reserved.

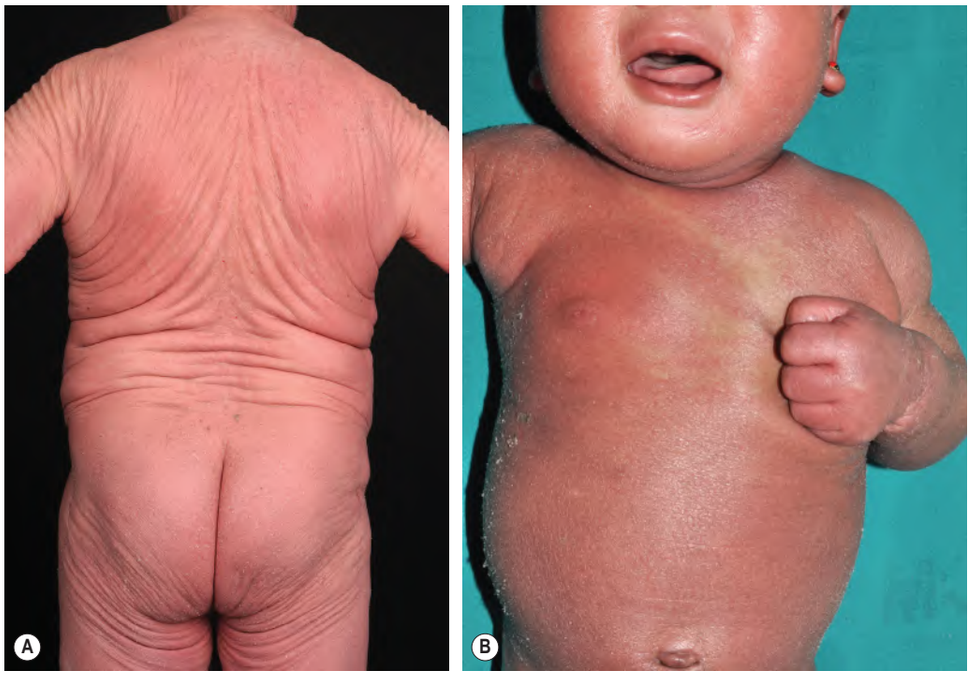

Fig. 10.4 Erythroderma due to atopic dermatitis. A Widespread erythema with fine white scaling and excoriations. **B** Fine white scaling and obvious pruritus in addition to circumoral pallor. *A, Courtesy Lorenzo Cerroni, MD; B, Courtesy Antonio Torrelo, MD.*

Drug reactions

The number of drugs implicated as causes of erythroderma is staggering (Table 10.3; see also Ch. 21)[18]. Whereas erythroderma resulting from topical medications usually begins as an irritant or allergic contact dermatitis, erythroderma due to systemic drugs often begins with the acute onset of a morbilliform or scarlatiniform exanthem. There are occasional exceptions such as the chronic eczematous eruptions associated with calcium channel blockers. In areas of greatest hydrostatic pressure (distal lower extremities), the eruption may become secondarily purpuric. While drug-induced erythrodermas have the shortest duration, usually resolving 2–6 weeks after withdrawal of the responsible drug, rarely erythroderma persists despite withdrawal of the putative drug and such cases may then be designated as idiopathic. Occasionally, there is a pseudolymphomatous presentation which can be associated with a transient peripheral blood lymphocytosis[19].

A minority of patients with DRESS (drug reaction with eosinophilia and systemic symptoms) syndrome, also referred to as drug-induced hypersensitivity syndrome (DIHS), become erythrodermic[20]. In addition to fever, these patients can develop peripheral blood eosinophilia, hepatitis, and peripheral lymphadenopathy (see Table 21.9).

Idiopathic erythroderma

In ~25% of erythrodermic patients, no underlying disease is detectable. This group consists primarily of elderly men with a chronic pruritic erythroderma in association with dermatopathic lymphadenopathy and extensive palmoplantar keratoderma (Fig. 10.5); this constellation is often referred to as "red man syndrome" or "l'homme rouge" (not to be confused with the infusion reaction ["red man syndrome"] that accompanies rapid intravenous infusions of vancomycin). When this group was compared with the entire group of erythrodermic patients, lymphadenopathy (68% vs 44%) and peripheral edema (54% vs 40%) were found to be more common than in other types of erythroderma, and hypothermia exceeded hyperthermia[21].

In one series of patients with idiopathic erythroderma, atopic dermatitis, drug-induced, and CTCL were the most common etiologies eventually identified[2]. In a second series, in which detection of a clonal T cell population in the skin was a diagnostic criterion for CTCL, the latter was the most common underlying disease[22]. However, it is important to note that in the absence of additional clinicopathologic features, the sole presence of a T cell clone in the skin is insufficient for the diagnosis of CTCL. Furthermore, peripheral blood T cell clones can be detected in elderly individuals and may reflect a diminished T cell receptor repertoire due to immune senescence rather than CTCL. Nonetheless, the detection of identical T cell clones in multiple biopsy specimens can serve as an important diagnostic clue for CTCL. Lastly, chronic actinic dermatitis should be considered in this group of patients.

DRUGS ASSOCIATED WITH ERYTHRODERMA	
Common	
• Allopurinol	• Phenytoins
• β-lactam antibiotics	• Sulfasalazine
• Carbamazepine/oxcarbazepine	• Sulfonamides*
• Gold	• Zalcitabine
• Phenobarbital	
Less common	
• Captopril/lisinopril	• Isotretinoin/acitretin
• Carboplatin/cisplatin	• Lithium
• Cytarabine	• Mercury compounds
• Cytokines (IL-2/GM-CSF)	• Minocycline
• Dapsone	• Omeprazole/lansoprazole
• Diflunisal	• Ribavirin
• Dupilumab	• Telaprevir
• Fluindione	• Thalidomide
• Hydroxychloroquine/chloroquine	• Tocilizumab
• Immune checkpoint inhibitors†	• Vancomycin‡
• Isoniazid	
Rare¶	
• Abacavir	• Mitomycin C
• Amiodarone	• Nifedipine/diltiazem
• Aspirin (ASA)	• Other antiretrovirals (e.g. efavirenz)
• Aztreonam	• Other NSAIDs
• β-blockers	• Penicillamine
• Chlorpromazine	• Pentostatin
• Cimetidine	• Pseudoephedrine
• Ciprofloxacin	• Rifampin
• Clofazimine	• St John's wort
• Codeine	• Sulfonylureas
• Erythropoietin	• Tear gas (CS gas)
• Fluorouracil	• Terbinafine
• Imatinib	• Tobramycin
• Indinavir	• Tramadol
• Lamotrigine	• Vinca alkaloids
• Methotrexate	• Zidovudine

*Includes furosemide.
†Including ipilimumab, nivolumab, pembrolizumab.
‡Not to be confused with the infusion reaction ("red man syndrome") due to rapid infusion of drug.
¶For additional drugs, see ref. 18.

Table 10.3 Drugs associated with erythroderma.

Downloaded for Anonymous User (n/a) at Egyptian Knowledge Bank from ClinicalKey.com by Elsevier on March 10, 2024. For personal use only. No other uses without permission. Copyright ©2024. Elsevier Inc. All rights reserved.

Cutaneous T cell lymphoma (Sézary syndrome and erythrodermic mycosis fungoides)

CTCL can mimic other causes of erythroderma and is frequently a significant diagnostic challenge. Erythroderma due to CTCL is subdivided into Sézary syndrome and erythrodermic MF (see Ch. 120). Sézary syndrome is defined by the triad of erythroderma, generalized lymphadenopathy, and peripheral blood lymphocytosis with morphologically abnormal Sézary cells; however, patients may have more limited skin involvement prior to the development of erythroderma[23]. Additional clinical features include a painful and fissured keratoderma, diffuse alopecia, edema, and leonine facies. The skin is often infiltrated or hyperpigmented (melanoerythroderma) and severe pruritus is common (Fig. 10.6).

To distinguish between Sézary syndrome and erythrodermic MF, revised criteria were proposed by the International Society of Cutaneous Lymphomas and the Cutaneous Lymphoma Task Force of the EORTC for the diagnosis of Sézary syndrome, namely erythroderma and evidence of an identical T cell clone in the blood and skin plus one of the following: (1) ≥1000 Sézary cells/mm^3; (2) a CD4:CD8 ratio of ≥10:1; or (3) an increased percentage of CD4$^+$ cells with an abnormal phenotype (≥40% CD4$^+$/CD7$^-$ or ≥30% CD4$^+$/CD26$^-$) by peripheral blood flow cytometry (B_2 in the TNMB classification; see Table 120.4). The latter cellular analysis provides a more objective measure of circulating tumor burden[24]. Erythrodermic MF can also have an identical T cell clone in the skin and blood, but flow cytometry results are normal or demonstrate low-level blood involvement (B_0 or B_1). In addition, diagnosis of erythrodermic MF can be challenging because the histopathologic findings are not diagnostic in at least one-third of patients.

Longitudinal evaluation, including repeated skin biopsies and PET-CT scans as well as lymph node biopsies and peripheral blood flow cytometry, is required to distinguish CTCL from idiopathic erythroderma. Identification of identical dominant T cell clones via more sensitive and specific high-throughput T cell receptor sequencing may prove helpful. Rarely patients with other hematologic malignancies, in particular angioimmunoblastic T cell lymphoma, adult T cell leukemia/lymphoma or T cell prolymphocytic leukemia, can present with erythroderma due to cutaneous infiltration of malignant T cells.

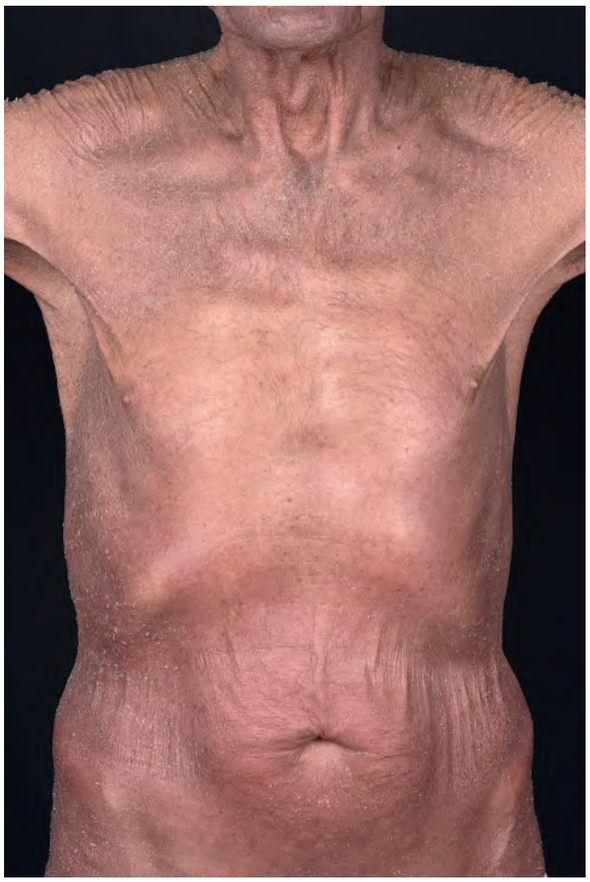

Fig. 10.5 Idiopathic erythroderma. This is the type of patient who requires longitudinal evaluation to exclude the development of cutaneous T cell lymphoma. *Courtesy Lorenzo Cerroni, MD.*

Pityriasis rubra pilaris

Erythrodermic pityriasis rubra pilaris (PRP) can be observed in children and adults (see Ch. 9). Usually, the lesions have a salmon to orange–red color. The degree of scaling varies, but it can be marked with large scales (Fig. 10.7). The combination of follicular keratotic papules on the knees, elbows and dorsal aspects of the fingers plus nappes claires (islands of uninvolved skin within the erythroderma) favors the diagnosis of PRP (Fig. 10.8). When the classic histologic features are present (see below), this is also helpful in distinguishing PRP from psoriasis. Occasionally, CTCL and the Wong type of dermatomyositis can have an appearance similar to PRP.

Papuloerythroderma of Ofuji

This represents a distinctive reaction pattern most often described in older men. Pruritic, monomorphic reddish brown papules often become confluent, with sparing of skin folds ("deck-chair" sign). In one review of

Fig. 10.6 Sézary syndrome. Diffuse erythroderma with a red–brown color. Note the evidence of scratching on the lower back. *Courtesy Lorenzo Cerroni, MD.*

Fig. 10.7 Erythroderma due to pityriasis rubra pilaris. Large thin scales are seen as well as the characteristic orange–red color.

Downloaded for Anonymous User (n/a) at Egyptian Knowledge Bank from ClinicalKey.com by Elsevier on March 10, 2024. For personal use only. No other uses without permission. Copyright ©2024. Elsevier Inc. All rights reserved.

Fig. 10.8 Erythroderma secondary to pityriasis rubra pilaris. Islands of sparing are noted on the flank and breast. Note the salmon color.

Fig. 10.9 Erythroderma due to pemphigus foliaceus. Generalized erythema with widespread scale-crusts and large areas of erosion.

170 reported cases, a causative factor was not identified in the majority of patients. Of the remaining individuals, CTCL represented the most common underlying etiology and thus needs to be excluded (see Table 10.1 for additional etiologies)[25].

Paraneoplastic erythroderma

Paraneoplastic erythroderma is most commonly associated with lymphoproliferative disorders, including systemic lymphomas and rarely thymomas. In patients with solid organ malignancies, erythroderma is rare and usually only appears during the late stages of the disease. Of note, in these patients the skin does not contain malignant cellular infiltrates. Fine scales and erythema can be accompanied by a brownish hue (i.e. melanoerythroderma). Additional signs of malignancy, such as cachexia or fatigue, may be seen.

Bullous dermatoses

Among the bullous dermatoses, pemphigus foliaceus is the one most likely, albeit rarely, to present as erythroderma; erythrodermic forms of paraneoplastic pemphigus and bullous pemphigoid have also been reported (see Table 10.1; see also Chs. 29 and 30). In pemphigus foliaceus, impetigo-like blisters and erosions are followed by collarettes of scale and scale-like crusts (Fig. 10.9). The erythroderma is usually preceded by localized lesions on the face and upper trunk.

Ichthyoses

Erythroderma due to one of the syndromic or non-syndromic inherited ichthyoses is usually present from birth or infancy (see Table 57.1)[26,27]. In neonates, congenital ichthyosiform erythroderma (CIE; previously referred to as non-bullous CIE), epidermolytic ichthyosis (previously referred to as bullous CIE), and Netherton syndrome should be considered (see Table 10.2). As a rule, CIE presents as a collodion baby (90% of the cases)[28], and within a few days after birth, an erythroderma with fine white scaling appears. Epidermolytic ichthyosis initially presents as generalized erythema with superimposed superficial blisters and erosions. This disorder may be mistakenly diagnosed as staphylococcal scalded skin syndrome or as a form of epidermolysis bullosa. Later, children develop spiny, corrugated hyperkeratoses, particularly in flexural areas, and blisters and erosions become less prevalent. Netherton syndrome manifests as an ichthyosiform erythroderma in neonates. It is associated with trichorrhexis invaginata ("bamboo hair"), elevated serum levels of IgE, and an immune defect that can result in life-threatening infections, particularly within the first years of life. Later, either the ichthyosiform erythroderma persists or ichthyosis linearis circumflexa develops, which is characterized by garland-like scaly eruptions. Because there are very rare ichthyoses that can present with an ichthyosiform erythroderma as well as multiple genes associated with a specific ichthyosis (see Table 57.1), molecular diagnostics consisting of next generation sequencing of large gene panels or whole exome sequencing have become an important evaluation tool[15].

Staphylococcal scalded skin syndrome

Staphylococcal scalded skin syndrome (SSSS; see Ch. 74) is seen primarily in children (<5 years of age), and it is due to a circulating exfoliative toxin produced by *S. aureus*. Since desmoglein 1 is cleaved by exfoliative toxin A, pemphigus foliaceus and SSSS exhibit clinical similarities, with the latter often becoming erythrodermic. Common foci for the initial infection include the nares, nasopharynx, conjunctivae, and umbilicus. After a period of 1–2 days of a low-grade fever, large areas of tender erythema develop. The skin appears tense and subcorneal blisters appear, which subsequently desquamate. A very similar syndrome, the toxic shock syndrome, can be caused by staphylococcal or streptococcal exotoxins, but more commonly affects adults and acral exfoliation has a delayed appearance, usually 2 weeks later.

Omenn syndrome

Omenn syndrome represents an autosomal recessive form of severe combined immunodeficiency (SCID; see Table 60.16). It is characterized by failure to thrive, leukocytosis with prominent eosinophilia, hypogammaglobulinemia, and elevated serum IgE levels. Cutaneous findings, which appear in neonates, are generally the first sign of the syndrome and include an erythroderma with diffuse alopecia. Systemic manifestations include prominent lymphadenopathy, hepatosplenomegaly, and recurrent diarrhea. In the absence of hematopoietic stem cell or bone marrow transplantation, severe infections lead to early death. Additional forms of SCID can also cause exfoliative dermatitis in neonates (see Table 60.16).

PATHOLOGY

Although sometimes subtle, histopathologic features of the underlying disease are present in about two-thirds of patients (see Tables 10.1 and 10.2)[29]. As a result, biopsy specimens in one-third of individuals with erythrodermic MF or Sézary syndrome are non-diagnostic[30]. Of note, epidermotropism of neoplastic lymphocytes is less commonly observed in these two disorders than in conventional MF[29]. Diagnostic findings are frequently found in psoriatic erythroderma[31], but less often in PRP.

It is important to remember that concurrent topical or systemic therapies as well as superimposed phenomena, e.g. atopic diathesis, contact dermatitis, impetiginization, can modify the histopathologic findings. In addition, multiple and sequential biopsies are often necessary in the evaluation of erythroderma.

Downloaded for Anonymous User (n/a) at Egyptian Knowledge Bank from ClinicalKey.com by Elsevier on March 10, 2024. For personal use only. No other uses without permission. Copyright ©2024. Elsevier Inc. All rights reserved.

DIFFERENTIAL DIAGNOSIS

Erythroderma is a clinical presentation for a variety of diseases, and identification of the underlying etiology represents one of the most complex challenges in dermatology (Figs. 10.10 and 10.11; see Tables 10.1 and 10.2). The evaluation starts with a complete medical history: up to 45% of the patients will have a prior history of a more localized skin disease, and ~20% of cases represent drug reactions[1–6]. A comprehensive clinical examination may reveal additional clues to the underlying disease. However, it is important to recognize that pre-morbid susceptibilities may modify the clinical morphology of an erythroderma, e.g. a drug reaction in an atopic individual may appear lichenified. Once the number of possible underlying diseases is reduced, further laboratory investigation can aid in establishing the final diagnosis. Hopefully in the future, specific diagnostic biomarkers will emerge that can assist in establishing a precise etiology[32]. For erythroderma in neonates and young children, molecular diagnostics represent a critical laboratory investigation (see above)[15].

TREATMENT

Erythroderma can represent a serious medical threat to the patient and therefore hospitalization may be required. Regardless of the underlying disease, the initial management consists of nutritional assessment, correction of fluid and electrolyte imbalances, prevention of hypothermia, and both prevention and treatment of secondary infections. Sedating oral antihistamines may ease severe pruritus[16]. Systemic corticosteroids may be necessary in idiopathic erythroderma and drug reactions. With an initial prednisone dose of 1–2 mg/kg/day and a maintenance dose of 0.5 mg/kg/day or less, rapid clearing of the erythroderma can be achieved. Caution must be exercised upon tapering, as rebound may occur. Topical therapy includes open wet dressings and bland emollients or low-potency corticosteroid ointments. High-potency topical corticosteroids should be reserved for lichenified areas, and because of enhanced transcutaneous absorption via erythrodermic skin, chronic, extensive application should be avoided. Coal tar ointments and phototherapy may aggravate the condition.

In neonates and children with erythroderma, management of fluid and electrolyte balance is critical in order to prevent hypernatremic dehydration. Emollients, topical antibiotics and, depending upon the extent and severity of the secondary infections, systemic antibiotics are administered. Due to increased transcutaneous absorption, topical salicylic and lactic acid should be avoided[33].

Treatment of specific underlying diseases is outlined in the respective chapters (see Tables 10.1 and 10.2). In the case of psoriatic erythroderma, administration of methotrexate, acitretin, cyclosporine or targeted immunomodulators ("biologics") is preferred over systemic corticosteroids, given the risk of a pustular flare when corticosteroids are tapered[34]. For drug reactions, discontinuation of all non-essential drugs and all suspected drugs will usually lead to

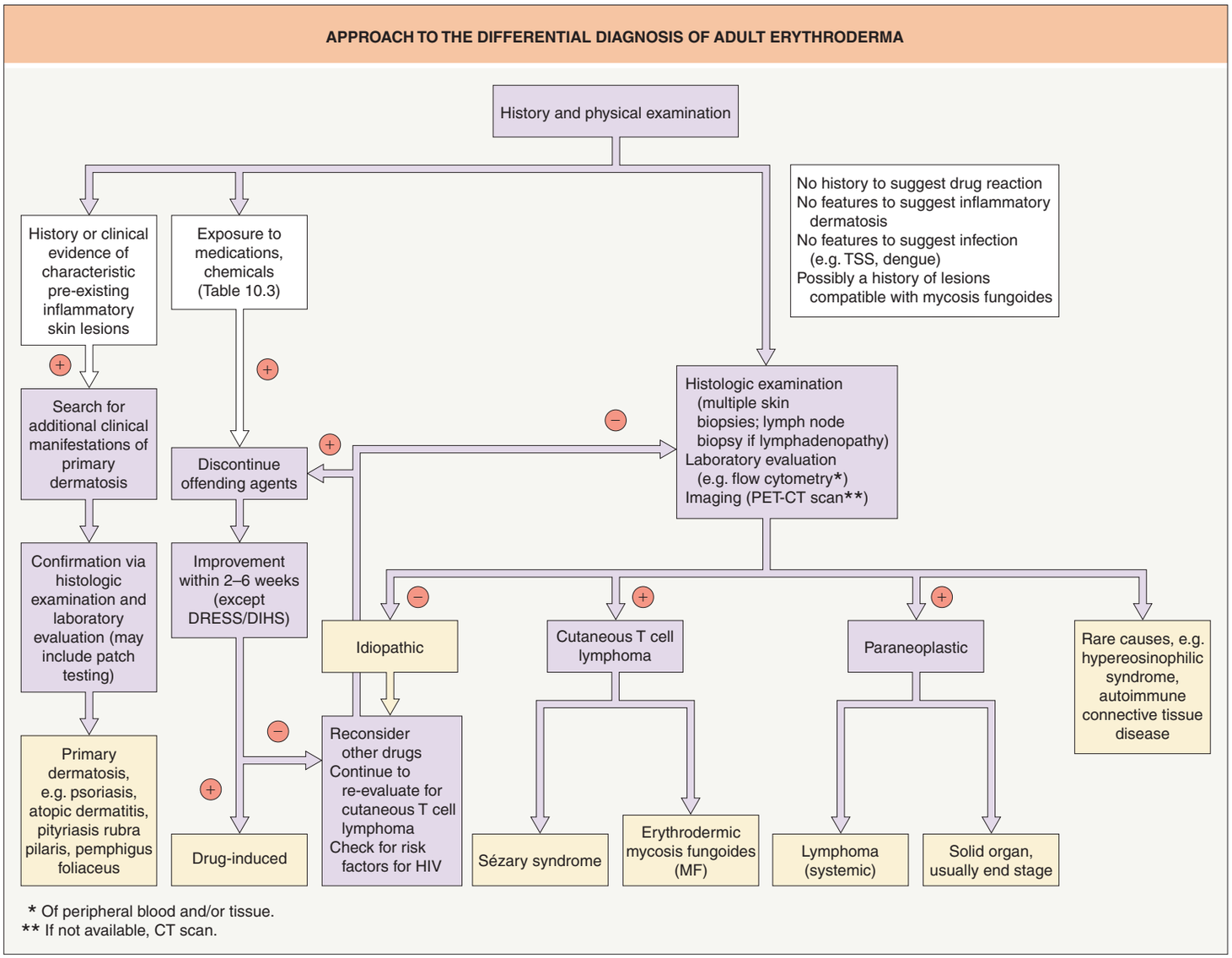

Fig. 10.10 Approach to the differential diagnosis of adult erythroderma. CT, computed tomography; DRESS/DIHS, drug reaction with eosinophilia and systemic symptoms/drug-induced hypersensitivity syndrome; PET, positron emission tomography; TSS, toxic shock syndrome.

Downloaded for Anonymous User (n/a) at Egyptian Knowledge Bank from ClinicalKey.com by Elsevier on March 10, 2024. For personal use only. No other uses without permission. Copyright ©2024. Elsevier Inc. All rights reserved.

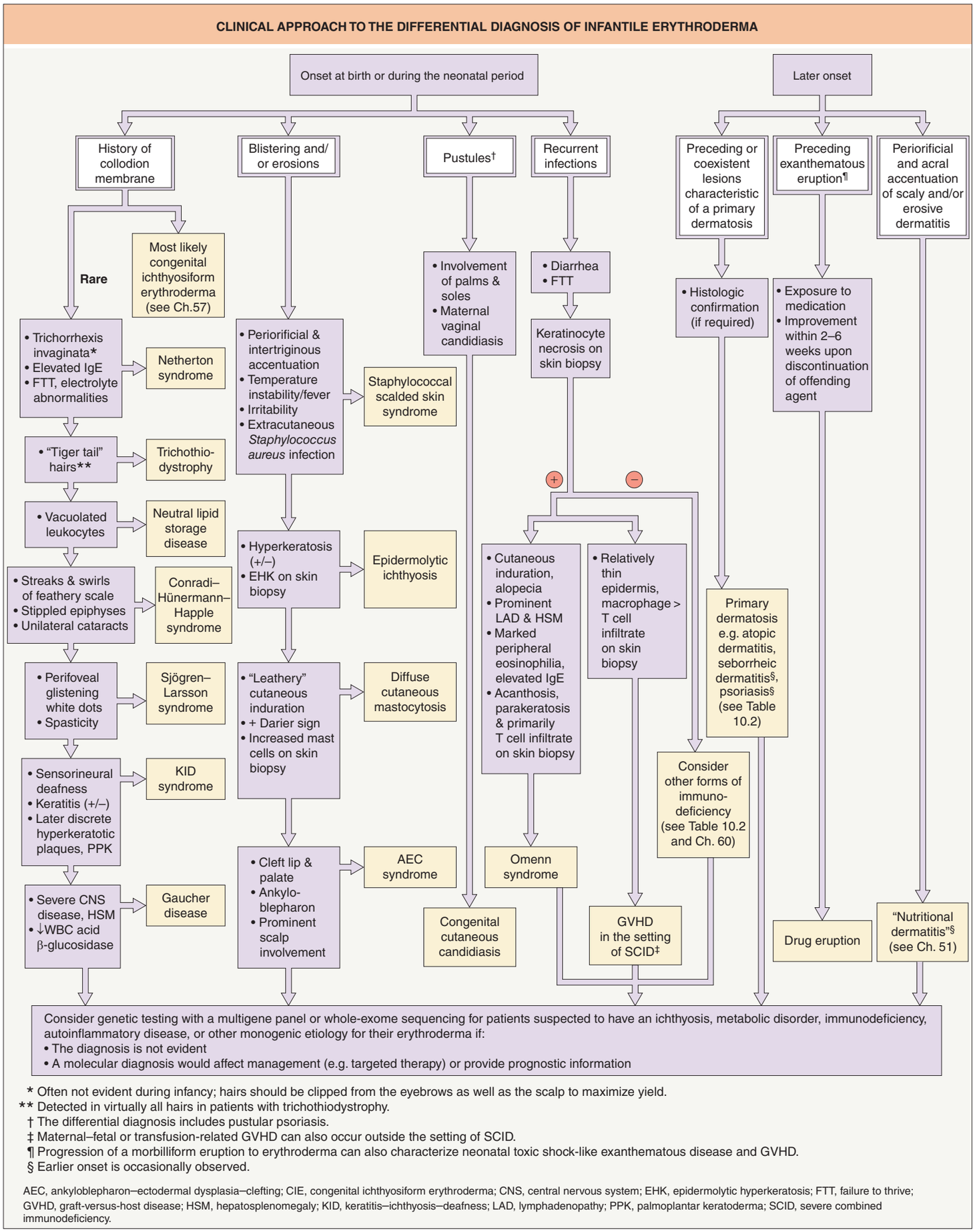

* Often not evident during infancy; hairs should be clipped from the eyebrows as well as the scalp to maximize yield.
** Detected in virtually all hairs in patients with trichothiodystrophy.
† The differential diagnosis includes pustular psoriasis.
‡ Maternal–fetal or transfusion-related GVHD can also occur outside the setting of SCID.
¶ Progression of a morbilliform eruption to erythroderma can also characterize neonatal toxic shock-like exanthematous disease and GVHD.
§ Earlier onset is occasionally observed.

AEC, ankyloblepharon–ectodermal dysplasia–clefting; CIE, congenital ichthyosiform erythroderma; CNS, central nervous system; EHK, epidermolytic hyperkeratosis; FTT, failure to thrive; GVHD, graft-versus-host disease; HSM, hepatosplenomegaly; KID, keratitis–ichthyosis–deafness; LAD, lymphadenopathy; PPK, palmoplantar keratoderma; SCID, severe combined immunodeficiency.

Fig. 10.11 Clinical approach to the differential diagnosis of infantile erythroderma.

Downloaded for Anonymous User (n/a) at Egyptian Knowledge Bank from ClinicalKey.com by Elsevier on March 10, 2024. For personal use only. No other uses without permission. Copyright ©2024. Elsevier Inc. All rights reserved.

improvement within 2–6 weeks (with the exception of some patients with DRESS/DIHS). However, systemic prednisone (1–2 mg/kg/day) or even the co-administration of IVIg may be useful in severe cases. After careful exclusion of any underlying cause, idiopathic erythroderma may be treated with low-potency topical corticosteroids and oral antihistamines. In refractory cases, cyclosporine has been used successfully, with an initial dosage of 5 mg/kg/day, and subsequent reduction to 1–3 mg/kg/day. Additional steroid-sparing agents include methotrexate, azathioprine and mycophenolate mofetil, all of which have been used anecdotally, with dosages similar to those for recalcitrant atopic dermatitis.

Additional figures available in our eBook (see inside front cover for access code).

REFERENCES

1. Sehgal VN, Srivastava G. Exfoliative dermatitis: a prospective study of 80 patients. *Dermatologica*. 1986;173:278–284.
2. Botella-Estrada R, Sanmartin O, Oliver V, et al. Erythroderma: a clinicopathological study of 56 cases. *Arch Dermatol*. 1994;130:1503–1507.
3. Sigurdsson V, Toonstra J, Hezemans-Boer M, van Vloten WA. Erythroderma: a clinical and follow-up study of 102 patients, with special emphasis on survival. *J Am Acad Dermatol*. 1996;35:53–57.
4. Pal S, Haroon TS. Erythroderma: a clinico-etiologic study of 90 cases. *Int J Dermatol*. 1998;37:104–107.
5. Wong KS, Wong SN, Than SN, Giam YC. Generalised exfoliative dermatitis – a clinical study of 108 patients. *Ann Acad Med Singapore*. 1988;17:520–523.
6. Nicolis GD, Helwig EB. Exfoliative dermatitis: a clinicopathologic study of 135 cases. *Arch Dermatol*. 1973;108:788–797.
7. Li J, Zheng H-Y. Erythroderma: a clinical and prognostic study. *Dermatology*. 2012;225:154–162.
8. Miyashiro D, Sanches JA. Erythroderma: a prospective study of 309 patients followed for 12 years in a tertiary center. *Sci Rep*. 2020;10:9774–9786.
9. Mathew R, Sreedevan V. Erythroderma: a clinicopathological study of 370 cases from a tertiary care center in Kerala. *Indian J Dermatol Venereol Leprol*. 2017;83:625.
10. Tan G, Kong Y, Tan S, Tey H. Causes and features of erythroderma. *Ann Acad Med Singapore*. 2014;43:391–394.
11. Bitar C, Chan MP, Harms PW, et al. Cutaneous manifestations of hospitalized coronavirus disease 2019 patients: a report of six cases with clinicopathologic features and viral RNA in situ hybridization. *J Eur Acad Dermatol Venereol*. 2020;34:e656–e659.
12. Relan M, Lehman H. Common dermatologic manifestations of primary immune deficiencies. *Curr Allergy Asthma Rep*. 2014;14:480–488.
13. Pruszkowski A, Bodemer C, Fraitag S, et al. Neonatal and infantile erythrodermas: a retrospective study of 51 patients. *Arch Dermatol*. 2000;136:875–880.
14. Kanthraj GR, Srinivas CR, Devi PU, et al. Quantitative estimation and recommendations for supplementation of protein lost through scaling in exfoliative dermatitis. *Int J Dermatol*. 1999;38:91–95.
15. Cuperus E, Sigurdsson V, van den Akker PC, et al. Diagnostic next generation sequencing neonatal erythroderma. *J Dtsch Dermatol Ges*. 2021;19:612–614.
16. Rothe MJ, Bernstein ML, Grant-Kels JM. Life-threatening erythroderma: diagnosing and treating the "red man". *Clin Dermatol*. 2005;23:206–217.
17. Assaf C, Hummel M, Steinhoff M, et al. Early TCR-β and TCR-γ PCR detection of T-cell clonality indicates minimal tumor disease in lymph nodes of cutaneous T-cell lymphoma: diagnostic and prognostic implications. *Blood*. 2005;105:503–510.
18. Shear NH. *Litt's Drug Eruption and Reaction Manual*. 26th ed. Boca Raton: CRC Press; 2019.
19. Reeder M, Wood G. Drug-induced pseudo-Sézary syndrome: a case report and literature review. *Am J Dermatopathol*. 2015;37:83–86.
20. Walsh S, Diaz-Cano S, Higgins E, et al. Drug reaction with eosinophilia and systemic symptoms: is cutaneous phenotype a prognostic marker for outcome? A review of clinicopathological features of 27 cases. *Br J Dermatol*. 2013;168:391–401.
21. Sigurdsson V, Toonstra J, van Vloten WA. Idiopathic erythroderma: a follow-up study of 28 patients. *Dermatology*. 1997;194:98–101.
22. Cherny S, Mraz S, Su L, et al. Heteroduplex analysis of T-cell receptor gamma gene rearrangement as an adjuvant diagnostic tool in skin biopsies for erythroderma. *J Cutan Pathol*. 2001;28:351–355.
23. Mangold A, Thompson A, Davis M, et al. Early clinical manifestations of Sézary syndrome: a multicenter retrospective cohort study. *J Am Acad Dermatol*. 2017;77:721–727.
24. Olsen E, Vonderheid E, Pimpinelli N, et al. Revisions to the staging and classification of mycosis fungoides and Sézary syndrome: a proposal of the International Society for Cutaneous Lymphomas (ISCL) and the cutaneous lymphoma task force of the European Organization of Research and Treatment of Cancer (EORTC). *Blood*. 2007;110:1713–1722.
25. Torchia D, Miteva M, Hu S, et al. Papuloerythroderma 2009: two new cases and systematic review of the worldwide literature 25 years after its description by Ofuji et al. *Dermatology*. 2010;220:311–320.
26. Takeichi T, Akiyama M. Inherited ichthyosis: non-syndromic forms. *J Dermatol*. 2016;43:242–251.
27. Yoneda K. Inherited ichthyosis: syndromic forms. *J Dermatol*. 2016;43:252–263.
28. Judge MR, Harper JI. The ichthyoses. In: Harper JI, ed. *Inherited Skin Diseases. The Genodermatoses*. Oxford: Butterworth; 1996:69–96.
29. Zip C, Murray S, Walsh NMG. The specificity of histopathology in erythroderma. *J Cutan Pathol*. 1993;20:393–398.
30. Trotter M, Whittaker S, Orchard G, Smith N. Cutaneous histopathology of Sézary syndrome: a study of 41 cases with a proven circulating T-cell clone. *J Cutan Pathol*. 1997;24:286–291.
31. Tomasini C, Aloi F, Solaroli C, Pippione M. Psoriatic erythroderma: a histopathologic study of forty-five patients. *Dermatology*. 1997;194:102–106.
32. Kou K, Okawa T, Yamaguchi Y, et al. Periostin levels correlate with disease severity and chronicity in patients with atopic dermatitis. *Br J Dermatol*. 2014;171:283–291.
33. Hoeger PH, Harper JI. Neonatal erythroderma: differential diagnosis and management of the "red baby". *Arch Dis Child*. 1998;79:186–191.
34. Boyd AS, Menter A. Erythrodermic psoriasis: precipitating factors, course and prognosis in 50 patients. *J Am Acad Dermatol*. 1989;21:985–991.

Downloaded for Anonymous User (n/a) at Egyptian Knowledge Bank from ClinicalKey.com by Elsevier on March 10, 2024. For personal use only. No other uses without permission. Copyright ©2024. Elsevier Inc. All rights reserved.

eFig. 10.1 Erythroderma with desquamation. Obvious exfoliation of scale with underlying erythema.

eFig. 10.2 Psoriatic erythroderma. The disease flare correlated with the administration of lithium. *Courtesy Jean L. Bolognia, MD.*

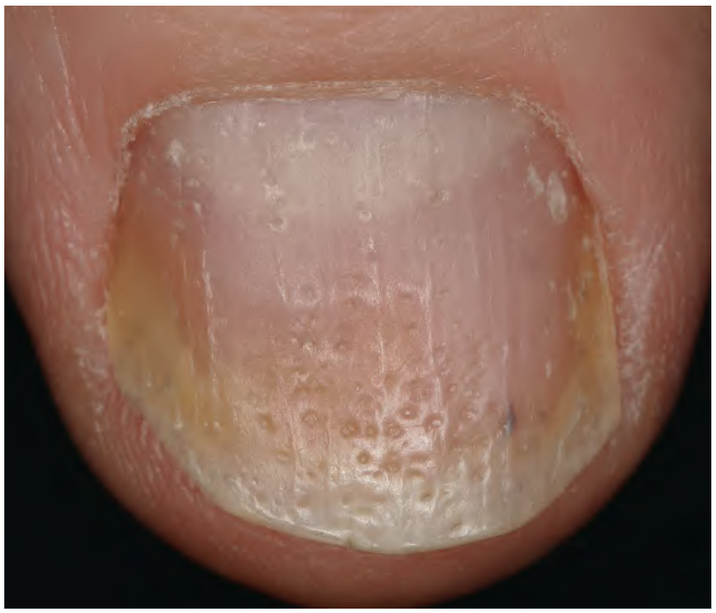

eFig. 10.3 Psoriatic erythroderma. Nail findings (pitting and onycholysis with a proximal rim of inflammation) point to the diagnosis of psoriasis.

eFig. 10.4 Eruptive seborrheic keratoses in a patient with idiopathic erythroderma. *Courtesy Jean L. Bolognia, MD.*

Downloaded for Anonymous User (n/a) at Egyptian Knowledge Bank from ClinicalKey.com by Elsevier on March 10, 2024. For personal use only. No other uses without permission. Copyright ©2024. Elsevier Inc. All rights reserved.

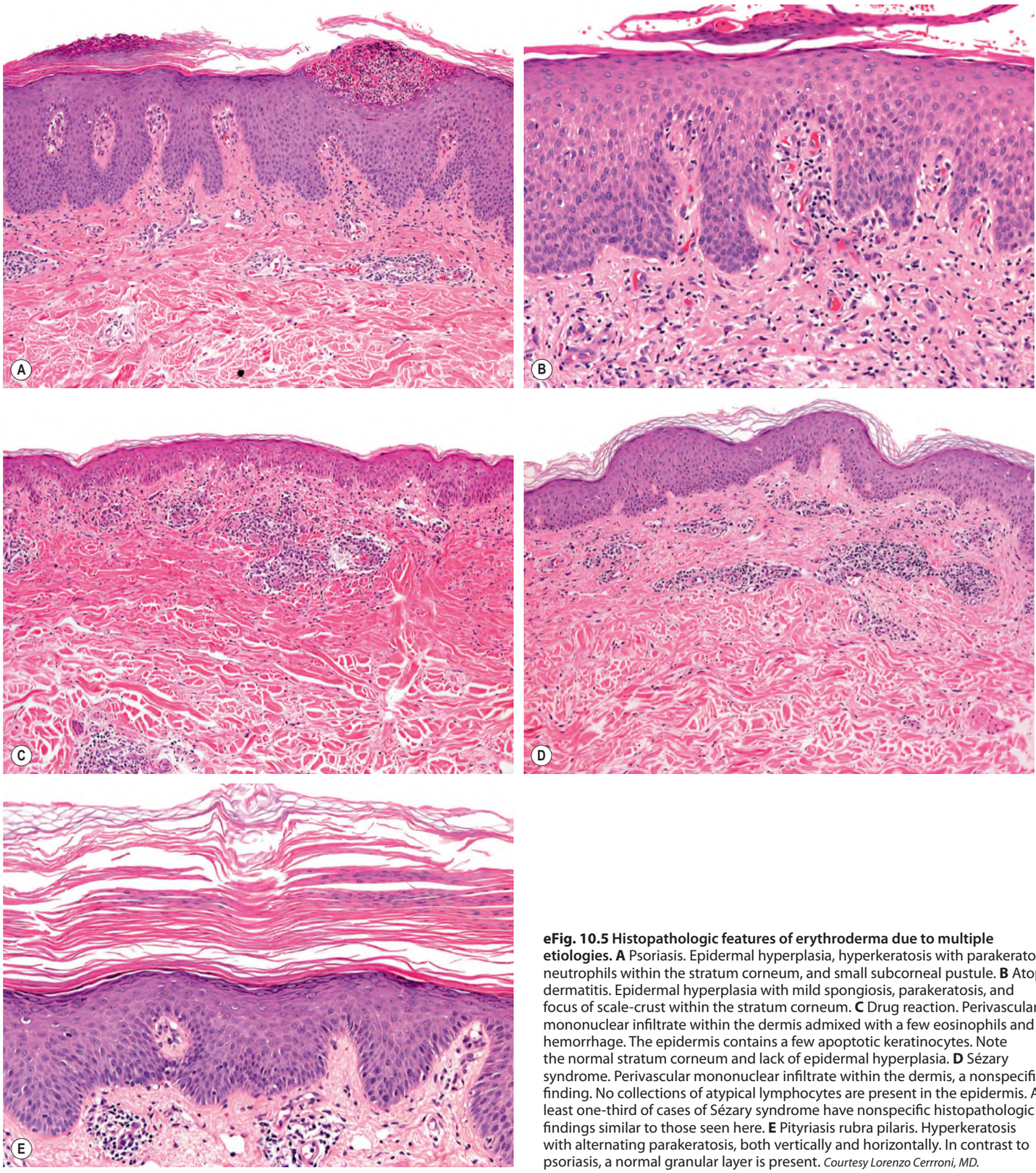

eFig. 10.5 Histopathologic features of erythroderma due to multiple etiologies. A Psoriasis. Epidermal hyperplasia, hyperkeratosis with parakeratosis, neutrophils within the stratum corneum, and small subcorneal pustule. **B** Atopic dermatitis. Epidermal hyperplasia with mild spongiosis, parakeratosis, and focus of scale-crust within the stratum corneum. **C** Drug reaction. Perivascular mononuclear infiltrate within the dermis admixed with a few eosinophils and hemorrhage. The epidermis contains a few apoptotic keratinocytes. Note the normal stratum corneum and lack of epidermal hyperplasia. **D** Sézary syndrome. Perivascular mononuclear infiltrate within the dermis, a nonspecific finding. No collections of atypical lymphocytes are present in the epidermis. At least one-third of cases of Sézary syndrome have nonspecific histopathologic findings similar to those seen here. **E** Pityriasis rubra pilaris. Hyperkeratosis with alternating parakeratosis, both vertically and horizontally. In contrast to psoriasis, a normal granular layer is present. *Courtesy Lorenzo Cerrroni, MD.*

Downloaded for Anonymous User (n/a) at Egyptian Knowledge Bank from ClinicalKey.com by Elsevier on March 10, 2024. For personal use only. No other uses without permission. Copyright ©2024. Elsevier Inc. All rights reserved.