POLITECNICO DI MILANO

School of Industrial and Information Engineering

MSc in Biomedical and Mechanical Engineering

Course of Human Modelling in Engineering

DIGITAL PROTOTYPES FOR PEDIATRIC CARDIAC SURGERY

Professor: Bertolini Michele

Students:

Miuccio Michela Paola Benedetta-222574

Rizzo Chiara-220285

A.Y. 2023-2024

Contents

ABBREVIATIONS AND ACRONYMS 3

ABSTRACT 4

2 INTRODUCTION 5

2.1 CLINICAL CONTEXT 5

2.1.1 TGA 6

2.1.2 DORV 8

2.2 SIMULATORS 12

2.2.1 STATE OF THE ART 12

2.3 PROJECT AIM 16

3 MATERIALS AND METHODS 17

3.1 PHYSIOLOGICAL HEART 17

3.1.1 SEGMENTATION 17

3.2 TWO PATHOLOGICAL HEARTS 20

3.2.1 SEGMENTATION 20

3.2.2 POST-PROCESSING 21

3.3 SIMULATOR 22

4 CONCLUSIONS 26

4.1 DISCUSSION OF THE RESULTS 26

4.2 CONCLUSION 26

4.3 FUTURE DEVELOPMENTS 26

BIBLIOGRAPHY 27

WEBLIOGRAPHY 28

LIST OF FIGURES 28

Abbreviations and Acronyms

CHD: congenital heart diseases

HOST Hands-on Surgical Training

RA: Right Atrium

RV: Right Ventricle

IVC: Inferior Vena Cava

SVC: Superior Vena Cava

TV: Tricuspid Valve

TGA: Transposition of the Great Arteries

DORV: Double Outlet Right Ventricle

VSD: Ventricular Septal Defect

AVSD: Atrio-Ventricular Septal Defect

HU: Hounsfield Unit

CT: Computed Tomography

MRI: Magnetic Resonance Imaging

Abstract

Paediatric cardiac malformations are congenital heart defects that occur during fetal development. These abnormalities can range from mild to severe and may require surgical intervention. Traditionally, congenital heart morphology teaching has heavily relied on the observation of pathologic specimens removed from corps or during cardiac transplantation. However, pathologic specimens are rare resources that are available in a limited number of institutions and are deteriorating with time: this highlights how important is to develop and improve the replication of congenital heart diseases with the 3D-printing.

Performing surgeries on 3D-pediatric models is of great use to clinicians: patient-specific models can improve anatomy knowledge and training activities, could help the surgeon to make the best decision about the surgery and allow to practice on an artificial model with the same characteristics and shape of the patient's heart.

The aim of this project is to design two digital 3D prototypes of two paediatric hearts with congenital cardiac malformations. The pathologies taken into consideration are the Transposition of the Great Arteries and the Double Outlet Right Ventricle. Each cardiac model includes both the heart anatomy of the specific patient and the training station where the heart has been placed. CT scans images, acquired in London, are used to create the 3D models of the hearts and *Mimics Innovation Suite* software (Materialise HQ, Leuven, Belgium) has been used to visualize and segment the images obtaining approximative 3D models. Subsequently *3-Matic* software has been used to define the heart prototypes. On the other hand, the training stations have been developed modifying an existing one. The goal was to create an environment that replicates the rib cage and some connectors to support the 3D models letting them be suspended in order to replicate the heart realistic position in the chest.

It is worth noting that in the present study the last step of 3D printing has not be done because the work is focused on the production of the 3D prototypes that could be printed in the next future using the STL files obtained through 3-Matic

1 Introduction

The heart is one of the most complex and delicate organs in the human body and its surgery has always been complicated. In particular, pediatric cardiac surgery - that aims to correct heart defects in fetuses, infants, and children - is notably challenging due to the small nature of a child's heart. For this reason, these surgeries require a high degree of experience from the surgeons, who have traditionally practiced using static images or animal models.

However, 3D printing is transforming the way pediatric cardiac surgeons train. In fact, it allows to print 3D simulators that create patient-specific models of hearts using data from CT scans and MRIs: this favors surgeons to practice procedures on replica that closely resemble the actual anatomy of the child they will be operating on. As a consequence, it may be reasonable to think that surgeons may acquire more awareness enhancing their technical skills and decision-making abilities [1].

This being so, it is interesting to focus on some pediatric heart diseases and on the potential that 3D simulators have in treating them.

1.1 Clinical context

Paediatric cardiac malformations are structural defects of one or more parts of the heart and/or the great vessels due to an altered embryonic development or growth-related arrest at an early embryonic or fetal stage. Despite significant medical and surgical advances, they remain one of the main causes of perinatal mortality [2].

Malformations can arise from:

- aneuploid (8-10%);
- single gene abnormalities (3-5%);
- environmental factors (2%) such as DM, phenylketonuria, obesity, alcoholism, drugs, intrauterine infections;
- multifactorial pathologies.

Complex Congenital Heart Diseases (CHD) include the Transposition of the Great Arteries (TGA) and the Double Outlet Right Ventricle (DORV), which are the pathologies taken into consideration in this project. Even though they have been analyzed separately, it is worth saying that, in some case, these two can be present at the same moment in a patient.

In the following paragraphs these are descripted in more detail together with their most common chirurgical treatments.

1.1.1 TGA

1.1.1.1 Pathology

Transposition of the great arteries (TGA) is a congenital heart defect, which means children are born with it. The heart forms during the first eight weeks of fetal development and the problems associated with TGA occur in the middle of these weeks, when both the aorta and the pulmonary artery attach to the incorrect heart chamber as shown in Figure 1. It is not clear what causes congenital heart malformations, including TGA, although in most cases it appears that a combination of genetics and environmental factors is involved. Very few risk factors have been identified, but it appears that the risk of TGA is increased in mothers with type 1 diabetes mellitus and possibly with the ingestion of certain drugs, such as benzodiazepines [3].

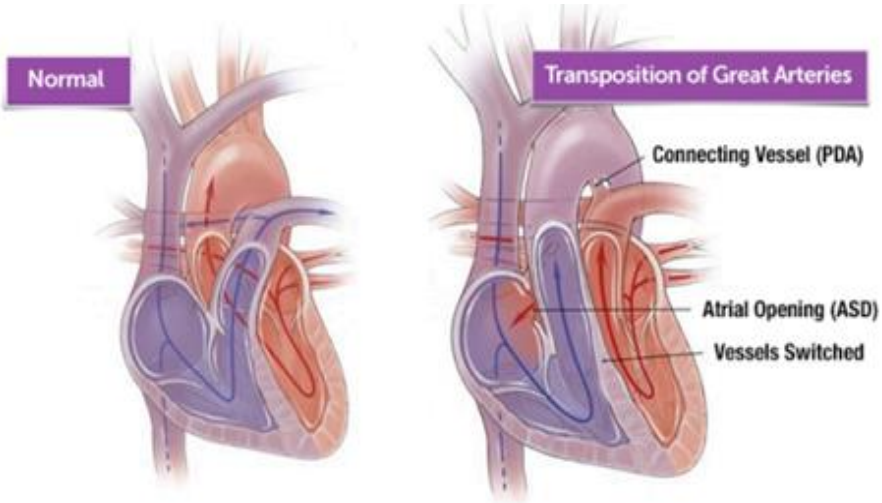

Figure 1 Visual comparison of a healthy heart and one affected by TGA.

TGA is a universal term that may also be referred to as dextro-Transposition of the great arteries (d-TGA) and levo-transposition of the great arteries (l-TGA), otherwise known as congenitally corrected transposition of the greater arteries[3].

In the transposition of the great arteries, the "great" arteries - the aorta and the pulmonary artery - are reversed in their origins from the heart with respect to the normal heart's anatomy: the aorta is connected to the right ventricle and the pulmonary artery is connected to the left ventricle. With these arteries reversed, oxygen-poor blood (blue) returns to the right atrium from the body, passes into the right ventricle, then goes into the aorta and back to the body. Oxygen-rich blood (red) returns to the left atrium from the lungs and passes into the left ventricle, which pumps it back to the lungs, it is the opposite of the way blood normally circulates.

The symptoms may include:

- cyanosis (blue coloration of the skin);
- shortness of breath;

- lack of appetite;
- poor weight gain.

Most patients with TGA have only that defect, but there are other defects that could coexist:

- atrial septal defect (ASD): opening between right and left atria;
- ventricular septal defect (VSD);
- patent ductus arteriosus (PDA): the prenatal connection between the aorta and the pulmonary artery, which usually closes shortly after birth, but which is in this case important as an alternative pathway for blood flow.

The presence or not of other defects can influence the surgeon's decision-making process about the best surgery to perform [3].

1.1.1.2 Chirurgical treatments

The first surgery may be done urgently as a temporary fix before permanent surgery and is *Atrial septostomy*. During this operation a small cut is done between the heart's upper chambers and a thin tube is insert to widen it creating a natural connection between the two atria. This temporary solution helps mix oxygen-rich and oxygen-poor blood improving oxygen levels in the baby's body.

The most used operations to fix this pathology are the *Arterial switch operation* (ASO) and *Atrial switch operation.*

TGA patients are currently operated by the ASO a few days after birth. During the Arterial switch operation the surgeon corrects the position of the great arteries leaving the heart. The native semilunar valves and roots are kept in place and the aorta-root becomes the neo-pulmonary trunk while the pulmonary trunk becomes the neo-aortic root. Additionally, the coronary arteries are excised from the native aortic root and re-implanted in the neo-aortic root [4]. Figure 2 shows the heart's appearance after the surgery.

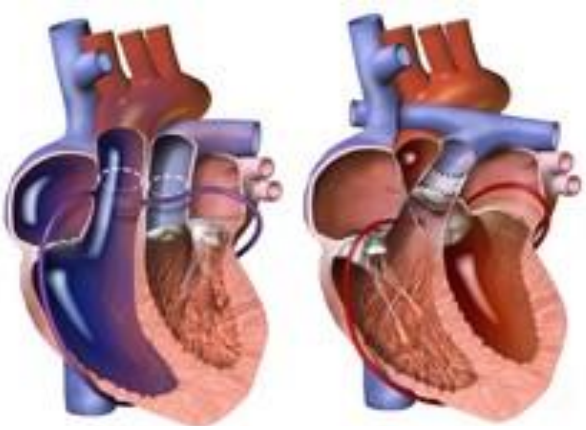

Figure 2 Heart affected by TGA (on the left) and the same heart after the arterial switch operation (on the right).

The Atrial switch operation involves the construction of an atrial baffle which redirects the blood coming into the atria to restore the connection between systemic and pulmonary circulation. In this case, the right lower heart chamber must pump blood to the body, instead of just to the lungs ,as shown in Figure 3. Nowadays atrial switch operation has been replaced by the ASO in most patients.

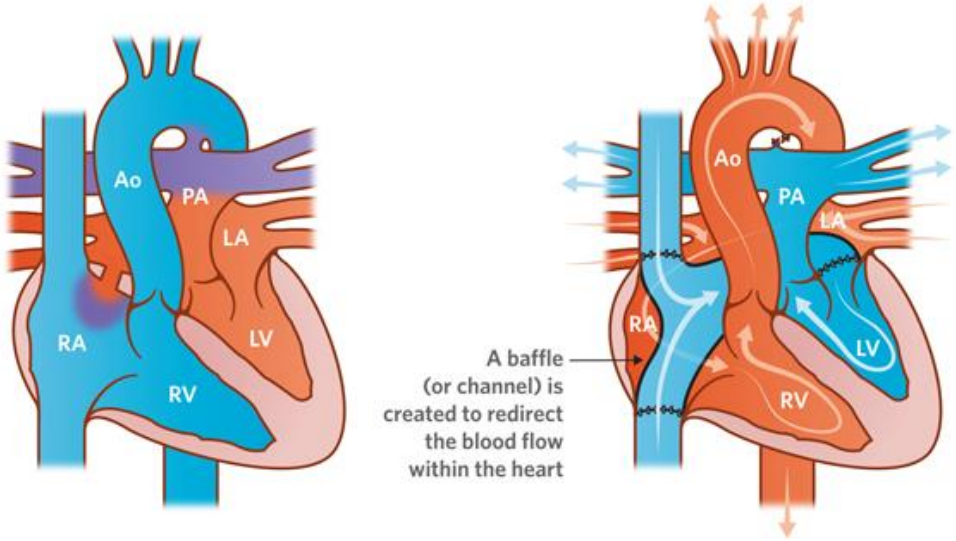

Figure 3 On the right the heart before the Arterial switch operation and on the left the heart after that.

Other operation could be chosen if there are additional defects like ventricular septal defect: in this case a *Rastelli procedure* is preferred.

Finally, it is worth noticing that when the TGA patients enter their third or fourth decade, it is unknown how their cardiovascular status will develop during young adulthood. For this reason, lifelong care is needed with a provider trained in heart problems present at birth [5].

1.1.2 DORV

1.1.2.1 Pathology

The DORV (Double Outlet Right Ventricle) is a rare congenital heart defect. In a healthy heart, the aorta - which carries oxygen-rich blood to the body - arises from the left ventricle while the pulmonary artery - which carries oxygen-poor blood to the lungs - arises from the right one, shown in Figure 4. However, in patients affected by this anomaly both the aorta and the pulmonary artery arise abnormally from the right ventricle [13].

The right ventricle with double outlet is due to a defect that arises during the formation of the heart trunk and conus, which represents the primary outflow tract of the heart during embryonic development. The malformation may origin from the mutation of several genes.

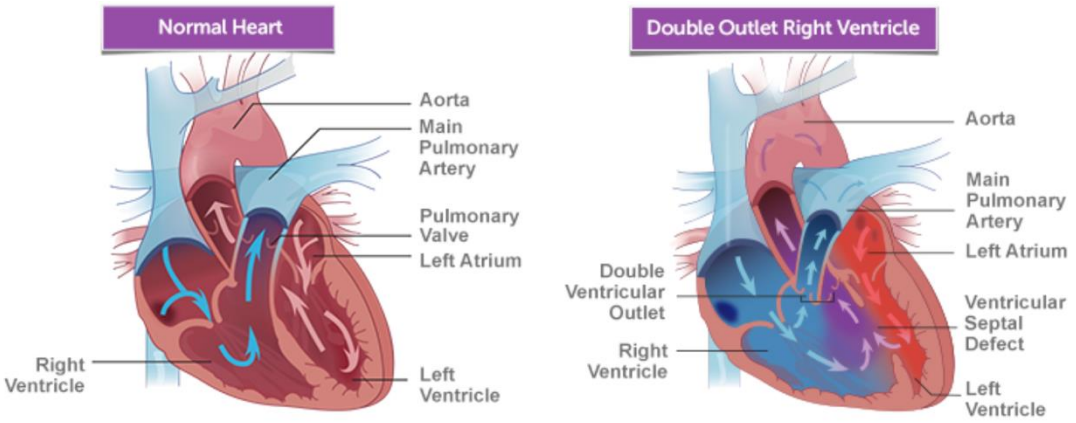

Figure 4 Visual comparison of a healthy heart and a one affected by DORV.

In general, due to this pathology, the ventricles can become overworked in an attempt to supply the body with enough blood and the right ventricle may pump harder and faster than normal: this extra work can cause heart enlargement.

In general, this pathology almost always includes an interventricular communication such as Ventricular Septal Defect (VSD) or Atrio-Ventricular Septal Defect (AVSD). In particular, the VSD is a hole in the wall (septum) that separates the lower chambers of the heart allowing some of the blood to flow into the right ventricle instead of flowing normally to the rest of the body. Initially, this hole is extremely helpful in children with DORV because it becomes the only way oxygen-rich blood can reach the aorta going into the body; however, its amount is usually not sufficient. In addition, there are several types of DORV depending on how much each artery arises from the right ventricle and on their relative position.

The major classification of DORV typologies depends on the position of the VSD with respect to the great arteries [6]:

- DORV with subaortic VSD;
- DORV with sub pulmonary VSD;
- DORV with a non-committed VSD (or remote VSD), where the VSD is not located near either the aorta or the pulmonary artery;
- DORV with a doubly committed VSD, where there are two VSDs, one below the aorta and one below the pulmonary artery.

Subaortic VSD	
Subpulmonary VSD	
Doubly committed VSD	
Non-committed VSD/remote VSD	
DORV categories based on great vessel relationship	
Right anterior aorta	Left anterior aorta
Right posterior aorta	Left posterior aorta
Right lateral/side-by-side aorta	
DORV categories by Van Praagh (9)	
Type I DORV as an isolated conotruncal anomaly	
Type II DORV with conotruncal anomalies and associated malformations of the atrioventricular valve(s) and ventricles	
Type III DORV associated with heterotaxy	
Functional categories by congenital heart surgery nomenclature and database project (3)	
DORV, VSD type (DORV-VSD)	
DORV with subaortic or doubly committed VSD and pulmonary stenosis, Fallot type (DORV-Fallot)	
DORV, with subpulmonary VSD, transposition type (DORV-TGA)	
DORV, non-committed VSD (nc-VSD)	

Figure 5 DORV classification.

This malformation is often associated with other anomalies, such as pulmonary stenosis, variable ventricular hypoplasia, atrioventricular valve anomalies and other extra-cardiac anomalies. The clinical picture depends essentially on the combination of these defects and its symptoms typically appear in the first few days or weeks of life and can include [15]:

- cyanosis (bluish coloration of the skin and mucous membranes);
- tachypnea (rapid breathing);
- dyspnea (shortness of breath);
- tachycardia (rapid heartbeat);
- difficulty feeding and poor growth;
- sweating;
- heart murmur.

1.1.2.2 Chirurgical treatments

DORV is generally diagnosed before birth allowing surgeons to think about the proper treatment of the newborn. The diagnosis is based on echocardiography, which allows visualization of both major arteries and identification of their point of origin. In some more complex forms, it is also necessary to perform other in-depth investigations, such as cardiac catheterization-angiography, magnetic resonance imaging (MRI) and CT scan.

The treatment of DORV depends on the type and severity of the DORV to operate, the child's age, the position and size of the VSD, eventual abnormalities in the atrioventricular valve and the dimensions of the ventricles and the atria. Nevertheless, for most cases surgery is the treatment of choice: this typically involves patient-specific surgery to close the VSD and repair the abnormal connections of the aorta and pulmonary artery restoring normal anatomy - so the link between the aorta and the left ventricle. Surgical treatment can be biventricular or univentricular, which is chosen in more complex cases [7].

Between the firsts, the most common procedure is called intraventricular tunnel repair, during which the surgeon creates a kind of tunnel to connect the left ventricle to the aorta and a patch placed within the heart directs left ventricle blood flow to the aorta. Figure 6 shows the crucial passages of the DORV's surgery so as to restore blood circulation to physiological levels.

The arterial switch operation is another procedure that becomes needed if the major vessels are connected in the wrong way (in particular, the aorta and the pulmonary artery are reversed in relation to each other). For this procedure, the surgeon creates a tunnel from the VSD to the pulmonary artery connecting the left ventricle to the pulmonary artery. Then, the vessels are disconnected and reconnected so that the pulmonary artery becomes the aorta, and the aortic valve is connected to the pulmonary artery. At the end, the holes between the left and right ventricles of the heart are closed [7].

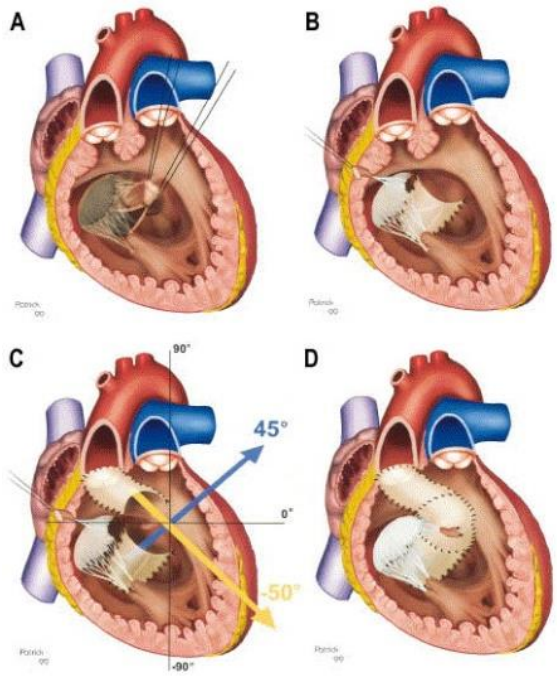

Figure 6 Chirurgical procedure to treat DORV: ***A:*** *Anterosuperior enlargement of the VSD to create a larger anterior and medial passageway.* ***B:*** *Bovine pericardial patch secured with interrupted mattress sutures to the margin of the VSD.* ***C:*** *The long axis of the first patch forms an almost 45° angle to an imaginary line drawn through the center of the aortic anulus. The second, more distal patch is secured around the aortic orifice and subaortic conus, with the long axis of the oval patch almost perpendicular to the long axis of the first patch.* ***D:*** *Final aspect of the intraventricular tunnel constructed with 3 bovine pericardial patches. The papillary muscles of the tricuspid valve are reinserted at the patch.*

1.2 Simulators

Developing technical skills in congenital heart surgery is usually very challenging because of limitations on hands-on operative experience during surgical training. For this reason, the development of 3D-printed models for simulation-based training, known as HOST (Hands-on Surgical Training), has become a great resource because it allows surgeons to practice regularly chirurgical procedures improving their technical skills across a range of congenital heart surgeries (CHS) and training minimally invasive surgeries.

The important finding is that these replicas provide a unique patient-specific method to assess complex anatomy since they emulate very accurately in shape and size the real pathological heart because they are created using patient-specific data from CT scans or MRIs. On the other hand, they also have some limitations such as the choice of the material - that even in the best case does not function as the real myocardium - and the impossibility to practice procedures that involve bleeding or other fluids. Moreover, the reproduction of thin or small structures such as cardiac valves, chordae tendinae and surrounding structures is expensive in terms of cost and time mainly because the currently available imaging modalities do not provide a clear definition of these structures. For this reason nowadays for most intracardiac procedures, the models are made only for the endocardial surface anatomy.

Nevertheless, despite these limitations, 3D printed hearts are considered a valuable new tool for surgical training also because they can be produced quickly and with a limited cost. This means that theoretically more surgeons can use these replicas as platforms to visualize the specific anatomy of the heart they have to operate, deep knowledge of all the steps the surgery requires (pre-operative planning), improve surgical skills and make the best-informed choices before the real surgery: as a consequence, this training leads to a much useful and safer surgical practice**.** In addition, the heart models are also helpful for teaching adult cardiac and vascular surgery [16], including catheter-based heart surgery [17].

As a result, there are several evident advantages provided by the use of 3D printed heart simulators that have encouraged their continuous improvement since their introduction in 2015 to include more realistic materials that mimic real tissue and valvar/sub-valvar apparatus: the literature in merit is deeply wide.

1.2.1 State of the art

In the literature there are some examples of three-dimensional simulators for both the TGA and DORV pathologies. They typically present an endocardial surface with a wall thickness of 1-2 mm and the ends of the vessels open.

Regarding the TGA models (an example is shown in Figure 7), the route for surgical approach is usually created by removing a part of the right atrial wall and of the left ventricular wall so that the surgical results can be easily inspected [8]. On the other hand, the DORV simulators, (with an example in Figure 8), commonly do not have parts of the free wall of the atria and ventricles to visualize the ventricular septal and the orientation of the inlets. In addition, the large parts of right atrium and left ventricle are removed for a better simulation of the surgical procedure, while the right ventricle is usually kept intact. This configuration helps the surgeon to understand if the patch can be applied without compromising the anatomy and functionality of the heart and in particular of the right ventricular inlet and the tricuspid valve [9]. Most of the 3D heart simulators are mounted on a flat platform with supporting pillars so that the platform is simply plastered on the table.

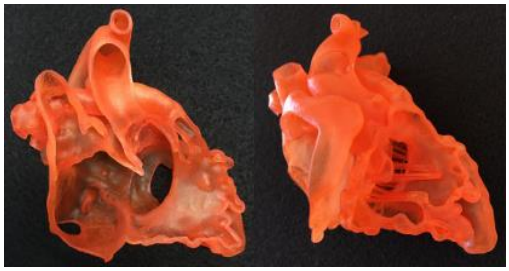

Figure 8 3D model of a heart affected by DORV without the platform.

Figure 7 Example of 3D printed model of a heart affected by TGA.

The Table 1 below shows two examples of 3D simulator for the two specific pathologies covered in this project. Some information is provided such as the authors of the simulators, their main characteristics and limitations.

Pathology	Authors	Description	Limitation	
TGA	Shi-Joon Yoo et al.	- The ends of the vessels are open. - A part of the right atrial and left ventricular wall is removed. - Material for the heart: TangoPlus FullCure resin - Material for platform: VeroWhite	- Heart's material does not satisfice the physical properties. - Valves must be designed separately. - High cost of production. - No external chest.	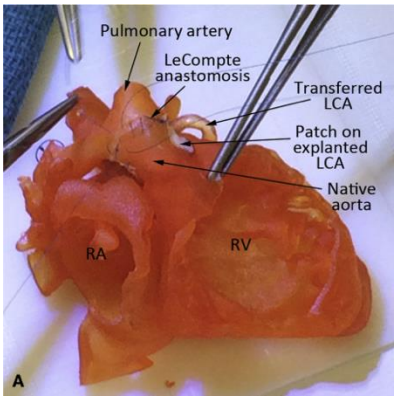

DORV	Shi-Joon Yoo1 and Glen S. van Arsdell	- The ends of the vessels are open. - A part of the right atrial and left ventricular wall is removed. - The right ventricular wall presents a small hole in the apex. - Material for the heart: TangoPlus FullCure resin - Material for platform: VeroWhite	- High cost of production. - Heart's material does not satisfice the physical properties. - Valves must be designed separately. - No external chest.	 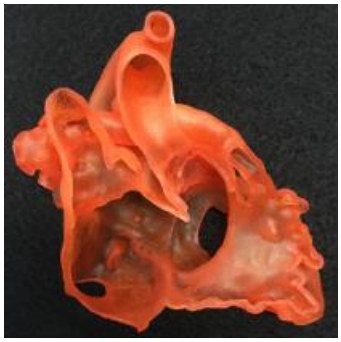

Yoo et al. have also developed a heart surgery simulator to underline the importance of not only having accurate 3D heart models, but also replicating the surgery conditions, like the position of the surgeon and light exposure, in order to enhance the surgery simulation experience. The simulator comprehends a dynamic chest wall, an operating table simulator and a retraction disk, as can be seen in Figure 9. Moreover, illumination system and recording camera are provided [10].

Figure 9 Operating table-chest wall simulator assembly developed by Yoo et al.

1.2.1.1 Future developments

The 3D printed models produced with the currently available technologies do not have the optimal physical properties for traction, cutting, and suturing during simulation, as reported in Table 1. To overcome these weaknesses, silicone models have been successfully introduced. These models are created applying the "parting and assembly" strategy: the distinct parts are created separately with different silicone thickness and using the molding technique and are then manually assembled. This strategy allows the molding of complex structures, the use of multiple realistic colors to better distinguish the model parts, and modeling without adhesion between the structures in direct contact, as shown in Figure 10.

Surveys conducted by engineering Brandon et all. in his study involve around twenty-six surgeons and return that almost all clinicians agree that silicone molded models provided a closer anatomic similarity to reality and allowed a superior simulation experience. However, the major limitation of silicone molding with the "parting and assembly" strategy are the high production costs, which may overcome the ones of 3D printing.

3D printing with silicone has been explored only in recent years and new types of materials are being studied to create a more realistic 3D model [11], but various limitations prevent the production of models suitable for the simulation of complex anatomy.

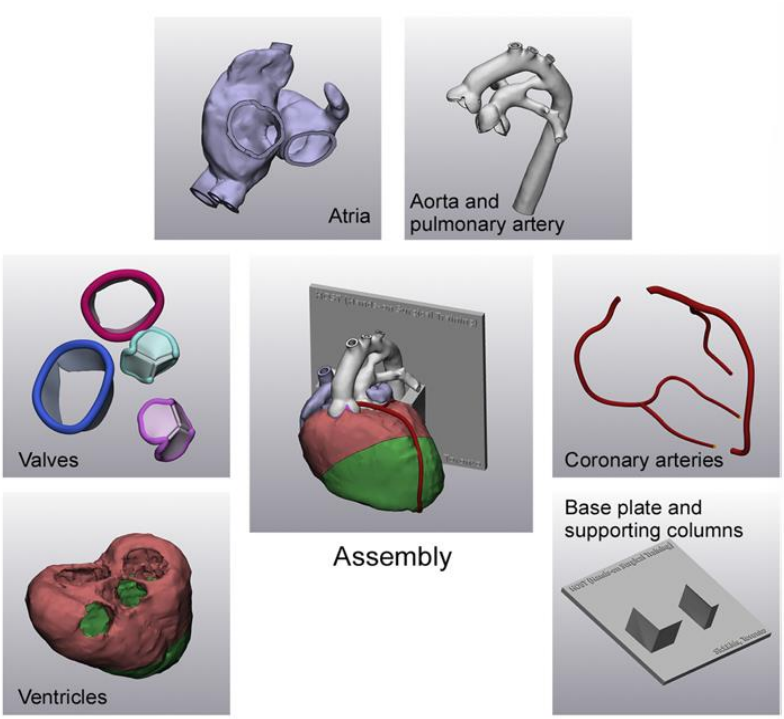

Figure 10 The figure reports all the components that are made separately: ventricles, valves, aorta and pulmonary artery, atria and coronary arteries. In the middle there is the assembly, in which the parts are assembled using an adhesive agent. The final heart is mounted on a plate.

In another study the engineering Roche developed a "bio-robotic hybrid heart" shown in Figure 11: this is a general replica of a heart made from synthetic muscle containing small

inflatable cylinders which try to mimic the contractions of a real beating heart. To do this the team has fabricated sleeves with a patterned bubble wrap and similar to blood pressure cuffs that wrap around the printed heart and aorta. When the sleeve is connected to a pneumatic system, researchers can tune the outflowing air to rhythmically inflate the sleeve's bubbles and contract the heart, mimicking its pumping action [14].

It is worth noting that this simulator can be used in many diverse types of surgery simulation because it replicates not only the heart's anatomy, but also its mechanics and physiology. It is realistic thinking that in the future it may be used to study the fluid dynamics effects caused by valve implantation, prior to the operation and referring to the specific anatomy of the patient.

Figure 11 Biorobotic hybrid heart developed by Roche's lab that mimc the anatomy and the contraction of real beating heart.

1.3 Project aim

Considering all the above, the aim of this project is to design a complete heart simulator made of the models of the two pathological hearts put in an environment that replicates the rib cage and sustained by some supports. This ensemble is thought to be used for surgical simulation allowing surgeons to practice the surgical procedures designed to treat the TGA and DORV pathologies.

In particular, the platform that will be used already exists and was designed and implemented by Ing. Marchini for his master Thesis [12], but the connectors which bear the heart models linking them to the platform will be revised and adapted to the specific models analyzed. Indeed, this work is focused on the segmentation and the study of the two pediatric pathological hearts affected by TGA and DORV.

2 Materials and Methods

This chapter is focused on how the study has been developed and the softwares used to perform the assignment.

As stated before, the aim of the project can be distinguished into two steps. As a first point, the goal was to create the 3D models of the two pathological pediatric hearts starting from the CT scans of two real patients, which had been acquired in a hospital in London. Then, these prototypes had to be included in the simulated rib cage. The three-dimensional templates were obtained through *Mimics_2024* software and have been then modified and finalized with *3-Matic* software. All steps taken to achieve the pre-established results are discussed in detail in the next paragraphs.

At the beginning, a physiological heart has been segmented and post- processed to increase confidence with the software.

2.1 Physiological Heart

This section describes in detail the different steps taken for the creation of the three-dimensional model of a healthy heart with the myocardium. For an optimal segmentation of the CT scans, it is suggested to obtain a first approximative 3D part which is then enhanced by the post-processing.

2.1.1 Segmentation

The CT scans of the physiological heart are collected in the archive of the *Mimics* software. CT scans give a visualization of the heart and the physiological environment around it through projections on the transversal, frontal and sagittal planes. In each plane there is a sequence of images representing the sections of the heart at different heights.

The segmentation started with the selection of a threshold suitable to isolate all the parts with the same grey intensity that is representative of the tissue's density. Choosing adequate values (226 HU – 1184 HU) in the function *Threshold*, it has been possible to obtain a mask with the heart, some ribs and a part of the vertebral column while excluding the muscular tissue as shown in Figure 12.

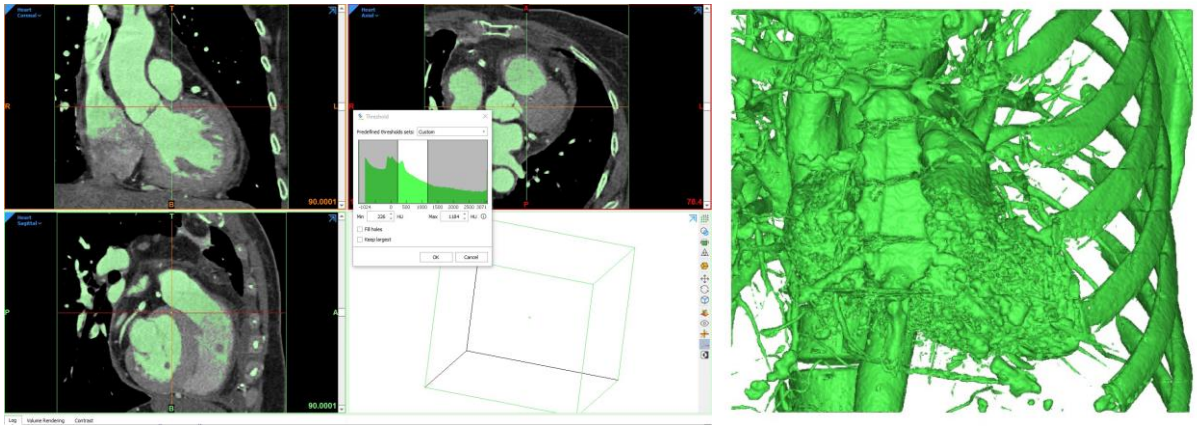

Figure 12 on the left: software interface with the three-visualization plane and the selection of the threshold. On the right: the 3D mask of the tissues selected in the threshold.

Then, all the parts which do not belong to the heart were manually removed and a first 3D model was obtained. Subsequently, it has been possible to separate the different chambers and big vessels of the heart using the functions *Split mask*, *Edit mask* and *Multiple Slice Edit* of the software to create different masks, one for each component (Figure 13):

- Right Ventricle;
- Left Ventricle;
- Right Atrium;
- Left Atrium;
- Aorta;
- Pulmonary artery.

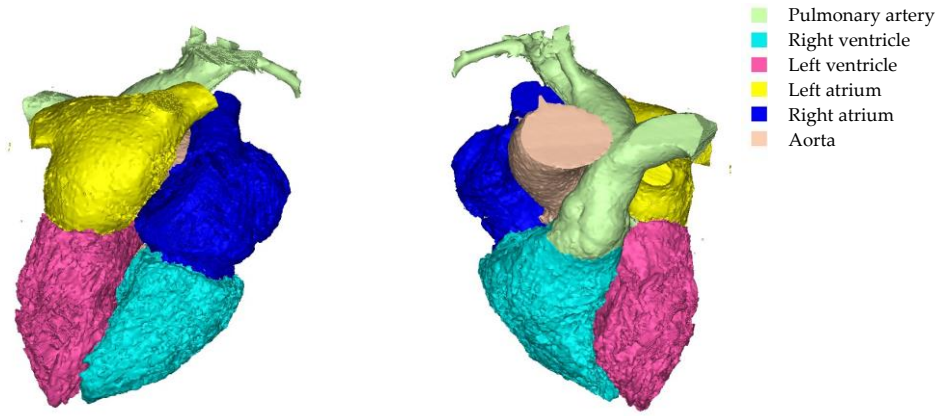

Figure 13 On the left: frontal view of the healthy heart. On the right: the back view of the healthy heart

2.1.2 Post-processing

To enhance and conclude the segmentation, the obtained parts have been exported in *3-Matic* for the post-processing, which consisted in some steps that improve the quality of the model. Firstly, an *Adaptive Mesh* was performed on the model with the triangle edge length set equal to 0.1 mm; then, the function *Wrap* with the minimum gap closing distance equal to 3 mm was applied to reduce the possible holes present in the model and the *Smooth* one to enhance the surface (smooth factor equals in the range 0.6-0.9). *Local Smooth* was then used to treat the smallest details.

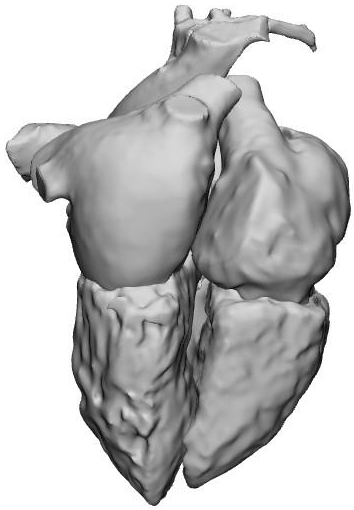

Figure 14 Final model of the heart without myocardium.

Once obtained the 3D model of the heart showed in Figure 14 the myocardium has been added. This is a thick muscular layer displaced between the outer layer of the heart wall (the pericardium) and the inner one (the endocardium). Still working on the same CT scans used before, a new threshold (65 HU - 3071 HU) was set in *Mimics* with the purpose of isolating the myocardium around the ventricles and segmenting it, as shown in Figure 15.

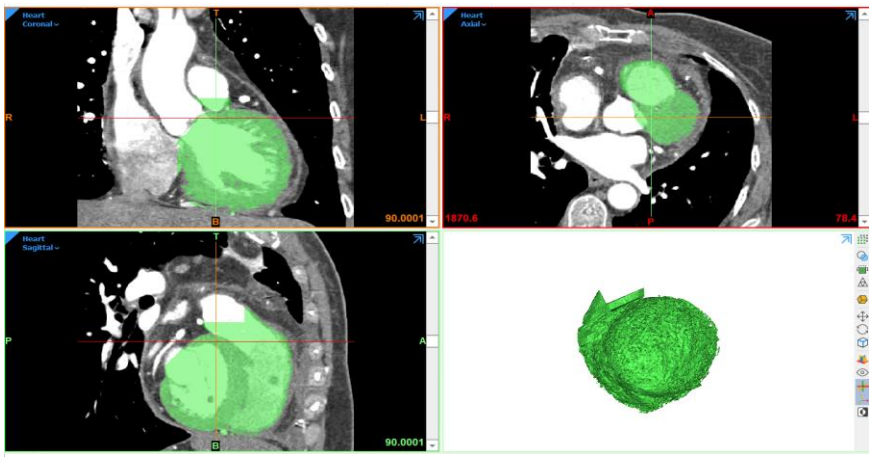

Figure 15 Health heart myocardium in Mimics.

As done for the heart, the new 3D part created in *Mimics* was then exported in *3-Matic* for the post processing and was subjected to some modifications with the aim of improving its surface quality: *Adaptive Mesh, Wrap* and *Smooth* have been applied with the same values as before. To conclude, the part has been added to the replica of the heart created before obtaining the final model of the heart with the myocardium; Figure 16 shows it.

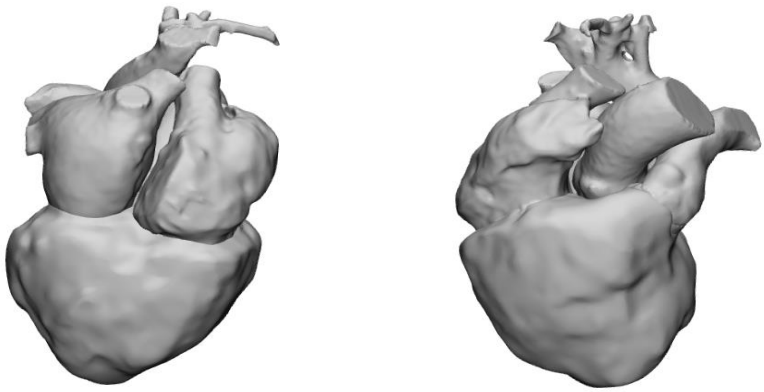

Figure 16 Healthy heart with myocardium. On the left: the frontal view. On the right: the rear view.

2.2 Two Pathological Hearts

After having acquired enough confidence with the two software, it has been possible to proceed with the development of the pathological hearts' 3D models.

2.2.1 Segmentation

The segmentation has been performed as previously described also for the pathological hearts. In these cases, the CT images were given from a hospital located in London and were representing the chests of two pediatric patients respectively with the TGA or the DORV pathologies.

Even though this procedure was conducted in the same way as before choosing a suitable threshold to isolate the heart, in these cases the process has been more complex due to the congenital anatomical malformations. In fact, the latter have caused some difficulties in recognizing the different components (chambers and big vessels) of the hearts. Nevertheless, using the functions *Split mask*, *Edit mask* and *Multiple Slice Edit* it has been possible to isolate and create different masks for each component. As a result, for the TGA they are (Figure 17):

- Right Ventricle;
- Left Ventricle;
- Right Atrium;
- Left Atrium;
- Pulmonary artery;
- Aorta;

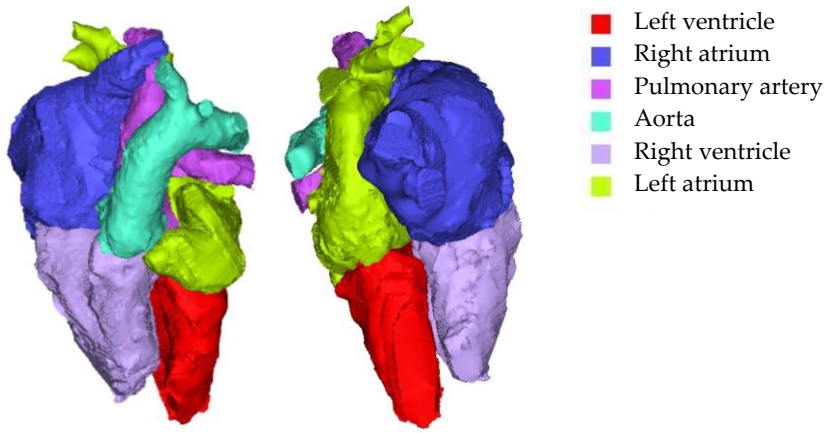

Figure 17 Segmentation of pathological heart with TGA without myocardium.

and for the DORV (Figure 18):

- Right Ventricle;
- Left Ventricle;
- Right Atrium;
- Left Atrium;
- Aorta;
- Superior vena cava;
- Pulmonary artery.

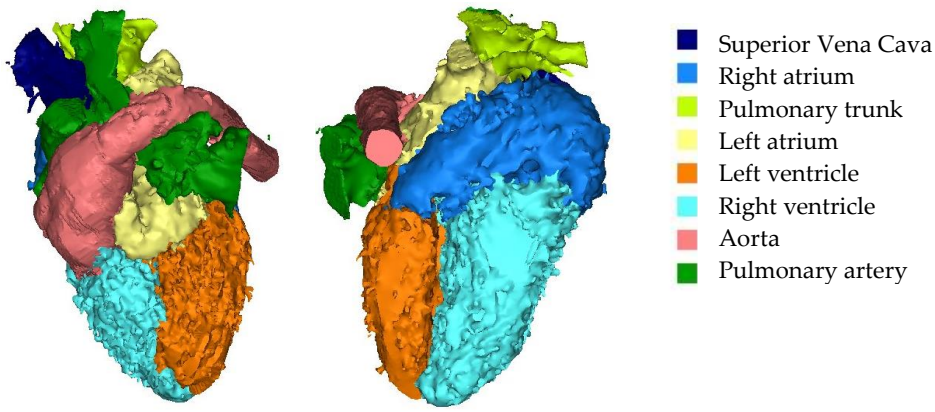

Figure 18 Segmentation of the pathological hearts without myocardium.

2.2.2 Post-processing

Once ready, the parts have been exported in *3-Matic* for the post-processing to improve the quality of the model using the functions *Adaptive Mesh*, *Wrap* and *Smooth* as described before. Concerning the *Adaptive Mesh* triangle edge length is set equal to 0.1 mm, while in the function *Wrap* the minimum gap closing distance is imposed equal to 3 mm. *Smooth* is the last one to

be performed, and the smooth factor, which represents the strength of smoothing, is imposed equal to 1 in order to decrease the "noise" in the mesh. Also in these pathological reproductions, once obtained the 3D models of the heart, the myocardium has been identified, segmented and exported in *3-Matic* to be improved with the post-processing and added to the previous models.

After having obtained the final models of the hearts with the myocardium, the function *Hollow* has been used to empty the hearts leaving the edge of an adequate thickness. In particular, it has been used with the type *Both*, which creates a surface around the original entity in both directions choosing an offset of 0.35 mm for each side to realize an edge of 0.7mm totally. To conclude, the function *Trim* has been applied to open the vessels: Figure 19 shows the models obtained.

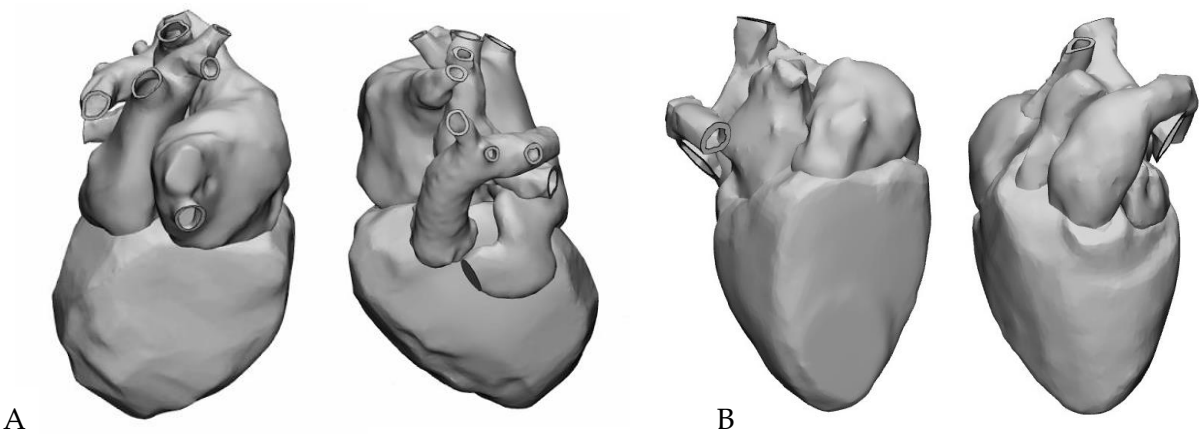

Figure 19 A: Empty TGA heart with myocardium B: Empty DORV heart with myocardium.

2.3 Simulator

The last step was designing a simulator adequate to integrate with both the two pathological hearts by providing stability to their 3D models during the surgery simulation ensuring the maximum possible realism. The solution found to fulfill this goal is a modular simulator, composed by a platform, a rib cage divided in two parts and some connectors, which are used to fix the model to the platform. While the first two elements (the platform and the rib cage) are unique and were designed by engineer A. Marchini, the set of connectors were designed from scratch and vary with the heart model considered in order to guarantee a better coupling. In this project two sets - one for each pathology taken into account - have been realized.

Considering the external structure, the platform was made to replicate the rib curvature, and the dimension had been taken from CT images of anonymous paediatric patients. Instead, the rib cage had been downloaded from *Sketchfab* and was scaled in order to fit the platform. It is possible to notice a gap in the sternum, which has been done to simulate the surgical chest cut done during the surgery. In addition, the platform presents five holes used to fix the

connectors which bear the model of the heart [12]. Figure 20 shows the simulator's parts described before.



Figure 20 A: Platform with the holes B: Rib cage designed by engineer Marchini.

To conclude the development of the simulator, the connectors between the platform and the two pathological hearts have been created by using the software *Solidworks 2023*.
The idea was to use the holes already existing in the platform to create connectors that would fit snugly within the vessels. Indeed, the vessels, being both elastic and hollow, could then mold around these rigid connectors, provided the shapes were compatible.
For both the pathological heart models created, three vessels were selected as attachment points: the right and left pulmonary arteries, and the superior vena cava. Connectors were inserted into these vessels to suspend the heart within the simulated rib cage and the distal end of each connector was manually shaped to replicate the proximal end of the corresponding vessel and to enhance the stability of the attachment. Subsequently, using the *Extrude* and *Sweep* functions in *Solidworks 2023*, the connectors were modelled from the base holes to fit the position of the vessel openings, being modelled on multiple planes and avoiding contacts with the heart models.

Figure 21 and Figure 22 show the final connectors designed for the two pathological specific cases.

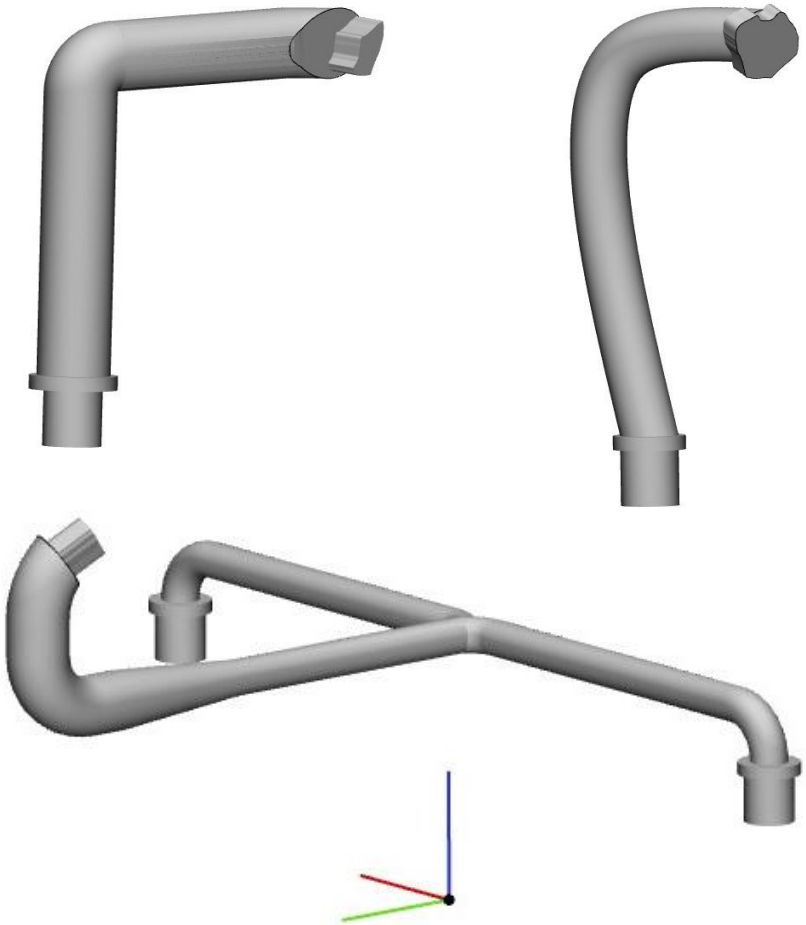

Figure 21 Connectors for DORV model.

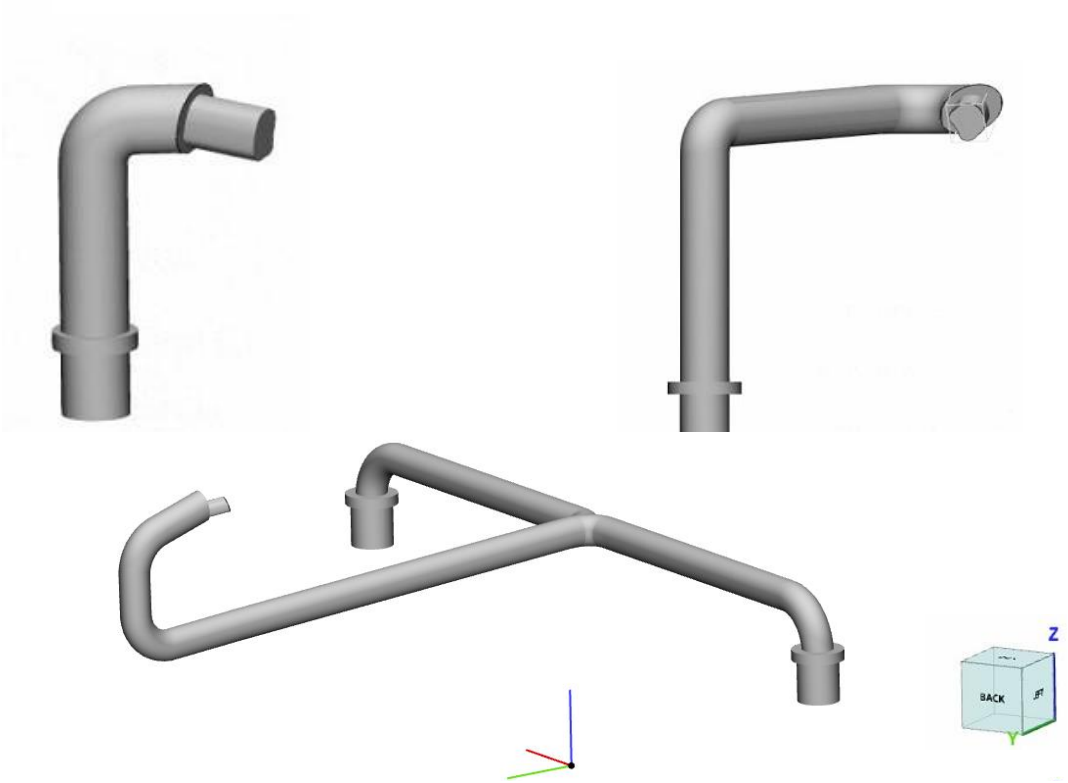

Figure 22 Connectors for TGA model.

Then, Figure 23 and Figure 24 illustrate the two ultimate simulators, each composed of: the platform, the rib cage, the connectors and 3D model of the heart.

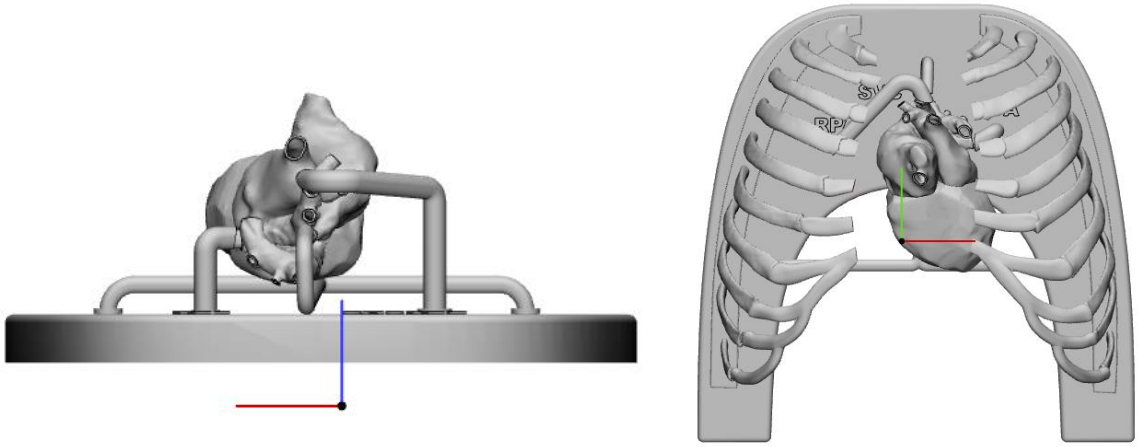

Figure 23 Final Simulator for TGA case.

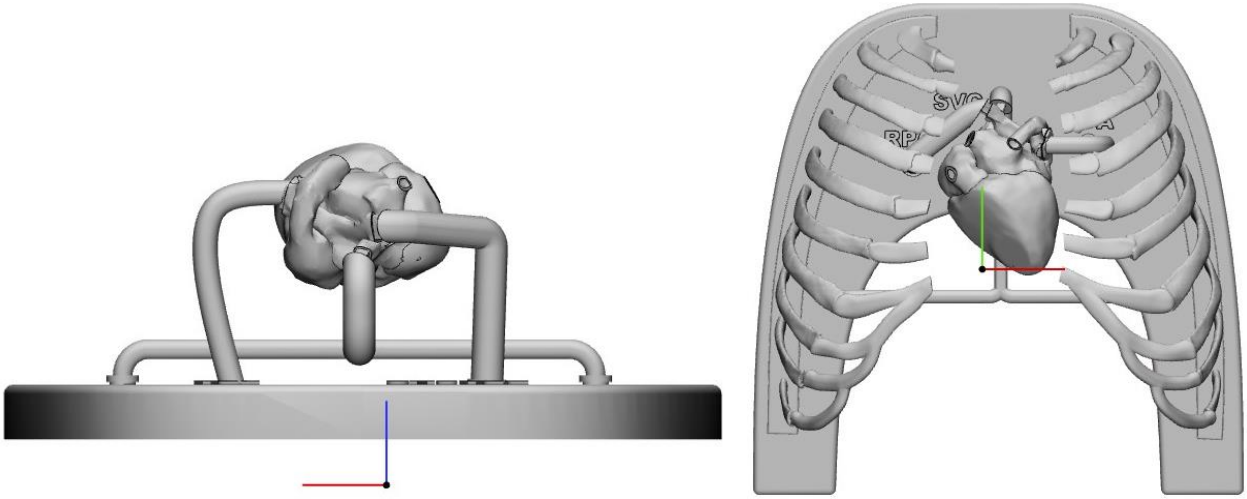

Figure 24 Final Simulator for DORV case.

As illustrated in the images, one of the holes on the platform was not used: this was because, due to the anatomical complexity of the pathological hearts, some vessels (not essential for the corrective surgeries) were omitted to simplify the 3D models. Nonetheless, the heart replicas can be considered firmly fixed, thanks also to the presence of the connector with the SVC, which is longer and provides lateral support on both sides.

3 Conclusions

3.1 Conclusion

This project has successfully demonstrated the feasibility of creating highly accurate 3D models of paediatric hearts with congenital cardiac malformations. The development of 3D-printed cardiac models represents a significant advancement in the field of paediatric cardiology because they have the potential to enhance surgical training improving the quality of care provided to children with congenital heart defects.

By utilizing CT scan images and advanced 3D modeling software, two distinct cardiac pathologies—Transposition of the Great Arteries and Double Outlet Right Ventricle—were accurately replicated. These models not only provide valuable insights into the intricate anatomy of these congenital heart defects but also offer a tangible platform for surgeons to enhance their understanding, training, and surgical planning. Moreover, the modular design of the simulator can be adapted to various pathologies by simply modelling adequate connectors, making it easier to create a greater number of surgical simulators. This type of product promotes the use and dissemination of HOST in both clinical and academic environments, offering an innovative solution to replace the degradable human organs that are still used by surgeons for training purposes. Additionally, reproducing the specific anatomy of a patient helps clinical staff make better decisions and plan surgeries more effectively, thereby increasing the likelihood of success.

3.2 Future developments

Future development in this area is really promising with the potential to update and revolutionize the diagnosis, treatment, and management of congenital heart defects.

The research may focus on improving the anatomical accuracy of the model and on testing biocompatible materials that can accurately mimic the mechanical and biological properties of cardiac tissue. For a more realistic heart model, improvements could include the addition of coronary arteries, valves, and chordae tendineae. However, these upgrades are not feasible with the current 3D printing technology, requiring further research.

Regarding the platform, the rib cage could be printed together with the sternum in order to enable surgeons, particularly younger ones, to practice all steps of the surgery and create a hole open enough. In the future, if hospitals will have dedicated 3D simulation labs, both the platform and rib cage could be customized to replicate the patient's anatomy, eliminating the need for standardized models.

Concluding, 3D printed models may also be integrated with augmented reality allowing surgeons to proceed with highly immersive and interactive simulations.

Bibliography

[1] C. Cattapan *et al.*, "The introduction of surgical simulation on three-dimensional-printed models in the cardiac surgery curriculum: an experimental project," *Journal of Cardiovascular Medicine*, vol. 25, no. 2, pp. 165–172, Feb. 2024, doi: 10.2459/JCM.0000000000001577.

[2] P. E. F. Daubeney, *Pediatric heart disease : a practical guide*. Wiley-Blackwell, 2012.

[3] "Transposition of the Great Arteries (TGA) What is transposition of the great arteries?" [Online]. Available: https://www.childrenshospital.org/conditions/transposition-great-arteries

[4] S. P. Marathe and S. Talwar, "Surgery for transposition of great arteries: A historical perspective," *Ann Pediatr Cardiol*, vol. 8, no. 2, pp. 122–128, May 2015, doi: 10.4103/0974-2069.157025.

[5] L. Engele, "CLINICAL COURSE AFTER ARTERIAL SWITCH OPERATION."

[6] Y. Bell-Cheddar *et al.*, "Double outlet right ventricle," Feb. 08, 2023, *Frontiers Media SA*. doi: 10.3389/fped.2023.1244558.

[7] Y. Bell-Cheddar *et al.*, "Double outlet right ventricle," Feb. 08, 2023, *Frontiers Media SA*. doi: 10.3389/fped.2023.1244558.

[8] S. J. Yoo, T. Spray, E. H. Austin, T. J. Yun, and G. S. van Arsdell, "Hands-on surgical training of congenital heart surgery using 3-dimensional print models," *Journal of Thoracic and Cardiovascular Surgery*, vol. 153, no. 6, pp. 1530–1540, Jun. 2017, doi: 10.1016/j.jtcvs.2016.12.054.

[9] K. Ponchant, D. A. Nguyen, M. Prsa, M. Beghetti, T. Sologashvili, and J. P. Vallée, "Three-dimensional printing and virtual reconstruction in surgical planning of double-outlet right ventricle repair," JTCVS Tech, vol. 17, pp. 138–150, Feb. 2023, doi: 10.1016/j.xjtc.2022.11.005.

[10] B. Peel, P. Voyer-Nguyen, O. Honjo, S.-J. Yoo, and N. Hussein, "Development of a dynamic Chest Wall and operating table simulator to enhance congenital heart surgery simulation," *3D Print Med*, vol. 6, no. 1, Dec. 2020, doi: 10.1186/s41205-020-00067-4.

[11] B. Peel, W. Lee, N. Hussein, and S. J. Yoo, "State-of-the-art silicone molded models for simulation of arterial switch operation: Innovation with parting-and-assembly strategy," *JTCVS Tech*, vol. 12, pp. 132–142, Apr. 2022, doi: 10.1016/j.xjtc.2021.12.009.

[12] A. M. Marchini, "Feasibility of a novel simulator to train Congenital Heart Defect repair Tesi di Laurea Magistrale in Double Degree in Biomedical and Mechanical Engineering-Doppia Laurea in Ingegneria Biomedica e Meccanica."

Webliography

[13] *Boston Children's Hospital*. (2005). Tratto da https://www.childrenshospital.org/conditions/dorv

[14] Changtian Wang, L. Z. (2020, 05 08). *journal of thoracic disease.* Tratto da https://jtd.amegroups.org/article/view/40340/html#:~:text=The%20important%20finding%20is%20that,including%20catheter%2Dbased%20heart%20surgery

[15] Chu, J. (2023, February 22). Retrieved from MIT News | Massachusetts Institute of Technology: https://news.mit.edu/2023/custom-3d-printed-heart-replicas-patient-specific-0222#:~:text=The%20procedure%20involves%20first%20converting,of%20the%20patient's%20own%20heart.

[16] Hospital, T. G. (2021, 01 11). *Cardiovascular Simulation Lab features 3D Printing to Improve Heart Surgery Techniques.* Tratto da Tampa General Hospital: https://www.tgh.org/news/tgh-health-news/2021/january/cardiovascular-simulation-lab-features-3d-printing-to-improve-heart-surgery-techniques

[17] University, J. H. (2018). Tratto da https://www.hopkinsmedicine.org/health/treatment-tests-and-therapies/double-outlet-right-ventricle-surgery-for-children

List of figures

Figure 1 Visual comparison of a healthy heart and one affected by TGA. 6

Figure 2 Heart affected by TGA (on the left) and the same heart after the arterial switch operation (on the right). 7

Figure 3 On the right the heart before the Arterial switch operation and on the left the heart after that. 8

Figure 4 Visual comparison of a healthy heart and a one affected by DORV. 9

Figure 5 DORV classification. 9

Figure 6 Chirurgical procedure to treat DORV: **A:** Anterosuperior enlargement of the VSD to create a larger anterior and medial passageway. **B:** Bovine pericardial patch secured with interrupted mattress sutures to the margin of the VSD. **C:** The long axis of the first patch forms an almost 45° angle to an imaginary line drawn through the center of the aortic anulus. The second, more distal patch is secured around the aortic orifice and subaortic conus, with the long axis of the oval patch almost perpendicular to the long axis of the first patch. **D:** Final aspect of the intraventricular tunnel constructed with 3 bovine pericardial patches. The papillary muscles of the tricuspid valve are reinserted at the patch. 11

Figure 8 Example of 3D printed model of a heart affected by TGA. 13
Figure 7 3D model of a heart affected by DORV without the platform. 13
Figure 9 Operating table-chest wall simulator assembly developed by Yoo et al. 14
Figure 10 The figure reports all the components that are made separately: ventricles, valves, aorta and pulmonary artery, atria and coronary arteries. In the middle there is the assembly, in which the parts are assembled using an adhesive agent. The final heart is mounted on a plate. 15
Figure 11 Biorobotic hybrid heart developed by Roche's lab that mimc the anatomy and the contraction of real beating heart. 16
Figure 12 on the left: software interface with the three-visualization plane and the selection of the threshold. On the right: the 3D mask of the tissues selected in the threshold. 18
Figure 13 On the left: frontal view of the healthy heart. On the right: the back view of the healthy heart 18
Figure 14 Final model of the heart without myocardium. 19
Figure 15 Health heart myocardium in Mimics 19
Figure 16 Healthy heart with myocardium. On the left: the frontal view. On the right: the rear view. 20
Figure 17 Segmentation of pathological heart with TGA without myocardium. 21
Figure 18 Segmentation of the pathological hearts without myocardium. 21
Figure 19 A: Empty TGA heart with myocardium B: Empty DORV heart with myocardium. 22
Figure 20 A: Platform with the holes B: Rib cage designed by engineer Marchini. 23
Figure 21 Connectors for DORV model. 24
Figure 22 Connectors for TGA model. 24
Figure 23 Final Simulator for TGA case. 25
Figure 24 Final Simulator for DORV case. 25