REVIEW
William J. Mullally, MD, Neurology Series Editor

THE AMERICAN JOURNAL of MEDICINE®

Ischemic Stroke

Steven K. Feske, MD

Department of Neurology, Boston Medical Center, Boston University School of Medicine, Boston, Mass.

ABSTRACT

This concise review of the epidemiology, pathophysiology, evaluation, acute management, and prevention of ischemic stroke targets internists, family practitioners, and emergency physicians who manage patient with stroke.
© 2021 Elsevier Inc. All rights reserved. *• The American Journal of Medicine (2021) 134:1457−1464*

KEYWORDS: Anticoagulant therapy; Anti-platelet therapy; Endovascular thrombectomy; Ischemic stroke; Stroke; Stroke prevention; Stroke therapy; Thrombolysis

INTRODUCTION

Cerebrovascular diseases are commonly confronted by primary care providers. Stroke, the most common serious manifestation of cerebrovascular disease, is the fifth-leading cause of death in the United States and a major cause of severe disability. It is the leading cause of hospitalization for neurologic disease. This review addresses issues of the prevention, diagnosis, and management of cerebrovascular diseases that are commonly encountered by primary care physicians.

Epidemiology

The 2020 American Heart Association report on Heart Disease and Stroke Statistics estimated that the prevalence of stroke in the United States in 2016 was 2.5%, corresponding to 7 million Americans older than 20 years of age who had suffered a stroke, nearly 800,000 stroke events, and nearly 150,000 deaths. Age is the most important demographic risk factor, and although the incidence of stroke has fallen in recent years, the lifetime risk of stroke has increased due to aging of the population. Female sex and African American race confer added risk. The estimated annual cost of stroke in 2014-2015 was $45.5 billion.[1]

The falling incidence of stroke since 1999 correlates with improvements in control of cardiovascular risk factors, hypertension, diabetes mellitus, hyperlipidemia, and lower rates of smoking, as well as better stroke preventive treatment of cardiac arrhythmias.[1]

ISCHEMIC STROKE

Ischemic Stroke: Pathology, Pathophysiology, and Stroke Types

Pathophysiology and Classification of Ischemic Stroke. The primary lesion of ischemic stroke is cerebral infarction. With inadequate supply of blood to cerebral tissue, there is first a reversible loss of tissue function and, given enough time, infarction with loss of neurons and supportive structures. Ischemia sets off a cascade of events that begins with loss of electrical function and progresses to disturbance of membrane function with calcium influx leading to calcium-dependent excitotoxicity, generation of reactive oxygen species, and ultimately destruction of cell membranes and lysis of cells.

There are several different mechanisms of vascular occlusion and many diseases that may underlie them (Tables 1 and 2).

Embolism is the most common mechanism of stroke. The great majority of emboli are blood clots generated from the heart (*cardioembolism*) due to cardiac disease. Common cardiac disorders leading to stroke include atrial fibrillation, valvular heart disease, and cardiomyopathy from myocardial infarction or hypertension. Less common causes of cardiomyopathy (eg, viral, drug-induced, infiltrative, hereditary, or idiopathic) leading to low left ventricular ejection fraction, arrhythmia, and intracardiac thrombus

Funding: None.
Conflicts of Interest: None.
Authorship: The author is solely responsible for the content of this manuscript.
Requests for reprints should be addressed to Steven K. Feske, MD, Neurology Department, Boston Medical Center, 72 East Concord Street, Collamore C3, Boston, MA, 02118.
E-mail address: sfeske@bu.edu

0002-9343/© 2021 Elsevier Inc. All rights reserved.
https://doi.org/10.1016/j.amjmed.2021.07.027

formation may also cause embolic strokes. Valvular vegetations from infective or noninfective thrombotic endocarditis may cause cardioembolism. Right-to-left shunting most commonly from patent foramen ovale or from congenital heart disease may lead to *paradoxical embolism* from the venous circulation. *Artery-to-artery embolism* occurs when thrombus, usually in association with atherosclerotic plaque or at sites of arterial dissection, is dislodged from large vessel walls to flow distally and lodge in smaller downstream vessels. Much less common, but important to consider in the right circumstances, material other than thrombus may embolize to cause strokes (Table 2).

Large vessel disease is another common underlying cause of stroke. *Large vessel atherosclerotic disease*, most commonly in the proximal cervical internal carotid arteries, but often more distally in the internal carotid arteries, in the aorta, the vertebral and basilar arteries, or intracranially, may cause strokes. Arterial dissection of the internal carotid or vertebral arteries is the next most common cause of large vessel disease. Arterial dissection is a common cause of stroke in young patients without alternative risk factors and in patients with certain predisposing conditions. Dissection may be caused by major trauma or by minor trauma from vigorous coughing, vomiting, or chiropractic manipulation. Some diseases that compromise the integrity of connective tissues and lead to dissection are listed in Table 2. Many arterial dissections occur without any apparent provocation and without any of these disorders. The most common mechanism by which large vessel disease leads to stroke is artery-to-artery embolism, so large vessel disease and embolism are overlapping categories defining stroke mechanisms. Large vessel stenosis or occlusion may alternatively lead to low flow in distal branches, typically causing infarction in the border zones of converging perfusion fields.

Small vessel disease typically causes small deep strokes. Ischemia extends around occluded distal arteries to create lacunar strokes. Small penetrating arteries, most vulnerable to the effects of chronic hypertension and other risk factors, are most commonly affected. Lacunar infarction at common sites may cause recognizable clinical presentations: posterior limb (*pure motor hemiplegia* and *ataxic hemiparesis)* and genu (*clumsy hand-dysarthria)* of the internal capsule, the basis pontis (*pure motor hemiplegia* and *clumsy hand-dysarthria*), the thalamus (*pure hemisensory*), and the cerebellum. Other sites of deep white matter infarction may cause symptoms referable to their locations.

Many other uncommon vascular and hematologic lesions may cause vascular disease with occlusion or embolism leading to strokes. Many of these less common causes of stroke are listed in Table 2.

CLINICAL SIGNIFICANCE

- Stroke is a major cause of death and serious disability.
- The progression of stroke over hours provides a short time for early intervention.
- Rapid evaluation of patients experiencing a stroke should determine their suitability for urgent intravenous thrombolysis or thrombectomy.
- All eligible patients should be offered intravenous thrombolysis or thrombectomy to optimize outcomes.
- The type and mechanism of stroke will determine the optimal acute and preventive therapies.

Pathophysiology: Time Course of Blood Flow Deficit. The progression of cerebral tissue to irreversible infarction, depends on the magnitude of the drop in cerebral blood flow and the duration of this drop. With a fall of cerebral blood flow by approximately 50%, patients remain asymptomatic. With a further fall, reversible neuronal dysfunction occurs, leading to ischemic symptoms, typically deficits of function corresponding to the location of the ischemia. If flow is restored rapidly enough, neuronal function returns without infarction and the patient is said to have had a *transient ischemic attack*. If low flow causing ischemia lasts long enough, irreversible tissue injury occurs, leading to the pathophysiologic events described for *cerebral infarction* or *ischemic stroke*. The time from onset of symptoms until the onset of irreversible tissue injury depends on the magnitude and duration of the drop in cerebral blood flow (Figure 1). Infarction may occur within minutes in the core of the lesion, and it may occur much later in the periphery of the lesion (Figure 2). The duration of delay until the completion of infarction varying from minutes to many hours provides both an opportunity for urgent therapy to restore blood flow and also an imperative to act rapidly, before the window of opportunity to minimize the stroke volume closes.

Ischemic Stroke: Diagnostic Imaging

A patient presenting with acute onset of a focal neurologic deficit should undergo a rapid, focused history and examination. History should elicit the time the patient was last seen well, details of onset, risk factors, medications, and clues raised by possibly relevant illness. Examination should record the heart rate and rhythm, blood pressure, the presence or absence of fever, and signs of possible endocarditis or other immediately relevant illness, and a focused neurologic examination, ideally incorporating the NIH Stroke Scale for clear communication. The patient should then proceed immediately to urgent brain imaging.

Noncontrast head computed tomography (CT) is, in most institutions, the first study of choice. The CT is reviewed with special attention to the following: (1) hemorrhage or other alternative nonstroke diagnoses that might explain the presentation; 2) signs of infarction; and 3) evidence of the site of vascular occlusion. Hemorrhage appears as hyperdensity on the head CT. Acute hemorrhage represents an absolute contraindication for intravenous thrombolytic therapy, so it is important to review the images carefully to rule

Table 1 Mechanisms of Ischemic Stroke*

Embolism
Cardioembolism
Artery-to-artery embolism
Paradoxical embolism
Large vessel disease
Atherosclerotic stenosis of occlusion
Arterial dissection (see Table 2)
Small vessel disease
Other identifiable underlying causes (see Table 2)
No identified cause despite extensive evaluation

*Based on the TOAST classification. (Trial of Org 10172 in Acute Stroke Treatment)

it out. Early signs of infarction include loss of gray-white differentiation due to decreased density in gray matter structures such as the insular cortex (insular ribbon sign) or the deep gray (eg, loss of putaminal definition). With more time, sulcal effacement due to tissue swelling, other signs of mass effect, and frank hypodensity are seen. The Alberta Stroke Program Early CT Score (ASPECTS) score is a grading scale commonly used to standardize communication about the extent of early infarction (Figure 3). Head CT may be normal early after onset of acute ischemic stroke, so the lack of hemorrhage or of an alternative cause for the focal deficit and the lack of a large completed stroke on CT provides adequate imaging to support urgent intravenous thrombolysis with alteplase or tenecteplase.

Table 2 Some Uncommon Causes of Ischemic Stroke

Embolism
Infective endocarditis
Nonbacterial thrombotic (marantic) endocarditis
Embolism of other materials: calcium, fat, air, amniotic fluid, medical devices
Hypercoagulability (see below)
Large vessel disease
Arterial dissection due to uncommon inherited disorders
Fibromuscular dysplasia, Marfan syndrome, vascular Ehlers-Danlos syndrome, Loeys-Dietz syndrome, arterial tortuosity syndrome
Moyamoya disease and moyamoya syndrome
Large vessel vasculitis
Small vessel disease
Small vessel vasculitis
CADASIL* and other inherited vasculopathies
Cerebral amyloid angiopathy (more commonly causes hemorrhage)
Hypercoagulability
Hypercoagulability of malignancy
Antiphospholipid antibody syndrome
Inherited and acquired clotting disorders (most commonly cause venous thrombosis)
Hypercoagulability of pregnancy
Sickle cell disease (with or without secondary moyamoya syndrome)
Infections
Infective endocarditis (see above)
Zoster ophthalmicus (an infectious form of vasculitis)
Syphilis
Tuberculosis and angio-invasive fungi (e.g. Aspergillus)
Cerebral venous thrombosis

*Cerebral autosomal dominant arteriopathy with subcortical infarcts and leukoencephalopathy.

To plan for possible urgent thrombectomy, many centers typically add vascular imaging with CT angiography (CTA) to the initial CT study. CT angiography from the aortic arch to the crown allows the identification of large vessel occlusions that might be amenable to endovascular therapy.

Magnetic resonance imaging (MRI) is more sensitive for the early identification of acute ischemic stroke, yet it is not commonly used as the initial study because it is less widely available and it takes longer to complete. However, when there is doubt about the diagnosis of stroke or when the timing of presentation or other aspects of the case demand a clearer early definition of the infarcted core or when iodinated contrast is contraindicated and urgent vascular imaging it needed, early MRI may be useful. Diffusion-weighted imaging (DWI) and apparent diffusion coefficient (ADC) sequences are nearly 100% sensitive in identifying acute infarction. MRI lesions that are bright on the DWI sequence and dark on the ADC sequence without early changes on the fluid attenuated inversion and recovery (FLAIR) are typical of acute strokes imaged less than approximately 6 hours after onset.

MR angiography (MRA) can demonstrate flow or stenosis or occlusion in the arteries of the chest, neck, and head. Perfusion imaging to define the core and penumbra can be done with CT or MRI, and these studies are recommended in many cases presenting late and being considered for endovascular thrombectomy. Diagnostic digital subtraction angiogram (DSA) remains the gold standard for vascular imaging, and it will be done urgently before proceeding to endovascular thrombectomy.

Ischemic Stroke: Acute Treatment

Acute treatment of stroke is directed at early reperfusion of tissue at risk with intravenous thrombolysis or endovascular thrombectomy and with optimization of hemodynamic status through management of fluid volume, blood pressure, and cardiovascular status.

A revolution in acute stroke care began with the publication in 1995 of the NINDS trial of intravenous (IV) tissue-plasminogen activator (tPA, alteplase) for acute ischemic stroke.[2] This trial showed a benefit of urgent treatment for selected patients when IV tPA was started within 3 hours of onset. A subsequent trial and meta-analyses extended the window for treatment with IV tPA to 4.5 hours in selected patients[3] (Table 3). Although beneficial overall, many patients, especially those with proximal large vessel occlusions (middle cerebral artery [MCA] stem and internal carotid artery [ICA]), do not respond to IV tPA. Fine-tuning of techniques of urgent endovascular thrombectomy has led

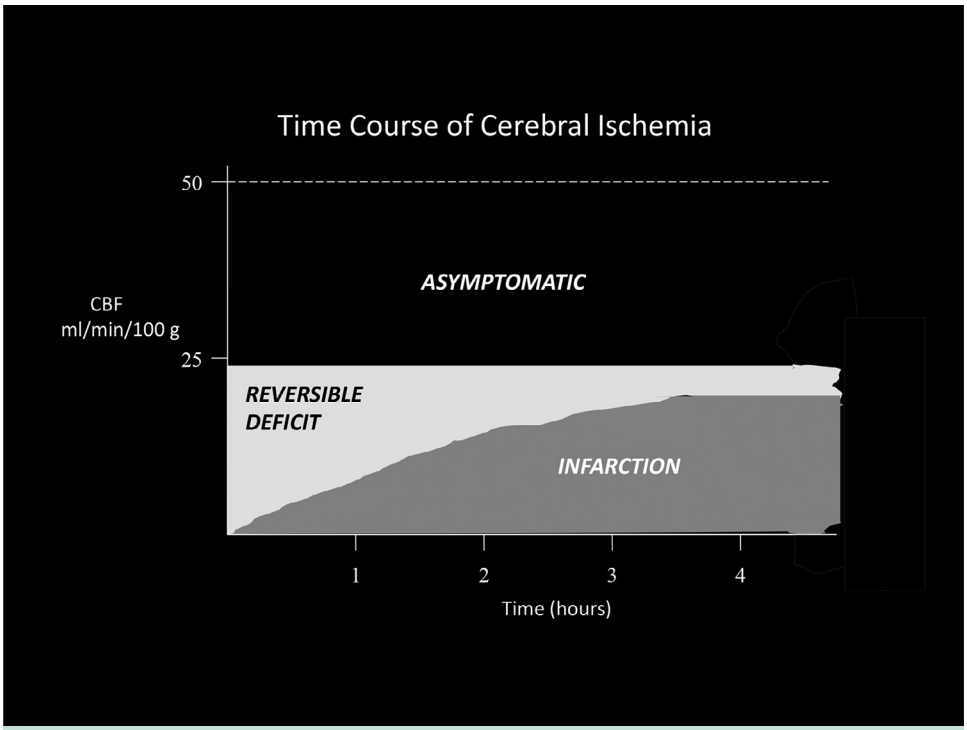

Figure 1 Cerebral infarction depends on the magnitude and duration of reduced perfusion. CBF = cerebral blood flow.

to a second revolution in reperfusion therapy for patients with these common large vessel occlusions.[4-8] All patients presenting within 6 hours of onset with significant functional deficits, with a large vessel occlusion, without a large established stroke on CT or MRI, and without contraindications, as well as additional selected patients up to 24 hours, should be considered for endovascular thrombectomy. Selection for late-window (>6 h) intervention is defined by imaging to confirm the likelihood of recoverable tissue at risk and a small established core infarct.[9,10]

Prevention of Stroke

Although work in the last 25 years has greatly extended our ability to minimize the volume of acute strokes and preserve neurologic function in many cases, we can make our greatest contribution to stroke care and patient health by preventing strokes. The great majority of this care falls ultimately to primary care physicians. Over the past 25 years, stroke has fallen from the third to the fifth leading cause of death in the United States;

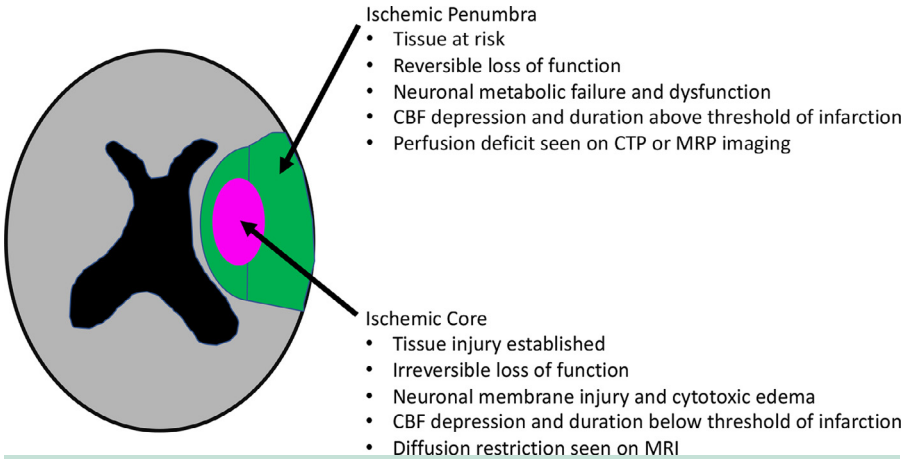

Figure 2 Infarct core and penumbra. CBF = cerebral blood flow; CTP = computed tomography perfusion; MRI = magnetic resonance imaging; MRP = magnetic resonance perfusion.



Figure 3 Alberta Stroke Program Early CT Score (ASPECTS) score. A = anterior circulation; P = posterior circulation; C = caudate; I = insular ribbon; IC = internal capsule; L = lentiform nucleus; M1 = anterior MCA cortex; M2 = MCA cortex lateral to the insular ribbon; M3 = posterior MCA cortex; M4, M5, and M6 = anterior, lateral, and posterior MCA territories immediately superior to M1, M2, and M3, rostral to the basal ganglia; MCA = middle cerebral artery. One point is subtracted from 10 for each affected area to give a score from 10 (no ischemic change) to 0 (all areas affected). From: Barber PA, et al. Validity and reliability of a quantitative computed tomography score in predicting outcome of hyperacute stroke before thrombolytic therapy. *Lancet*. 2000;355:1670-1674.

however, the lifetime risk has increased due to aging of the population, so the need for vigilance in preventive care has only increased. Success depends on the proper application of the various modalities of therapy, optimizing our choices of antiplatelet and anticoagulant therapies, optimal control of treatable risk factors, and selective referral for surgical therapies.

Antiplatelet Agents. Except when displaced by anticoagulants or when contraindicated due to bleeding risks, antiplatelet agents should be given for secondary stroke prevention in almost all patients after transient ischemic attack (TIA) or ischemic stroke. Low-dose aspirin is the mainstay of such therapy. Doses of 81-325 mg daily lower relative risk of recurrent stroke by approximately 20% per year.[11] Clopidogrel and aspirin combined with dipyridamole confer risk reduction similar to aspirin. Clopidogrel may be chosen in patients with sensitivity to aspirin. Either alternative may be chosen for patients who have events despite proper aspirin use.[12,13]

Dual-antiplatelet therapy for long-term use has been found to confer no long-term advantage over single-agent therapy.[14-16] However, after TIA and nondisabling stroke, the greatest risk of recurrent stroke occurs in the first couple of weeks after the event.[17] Dual-antiplatelet therapy with combined aspirin and clopidogrel has been found in 2 large trials to confer lasting benefit if given for the first 3 weeks after TIA or small stroke.[18,19] The second of these trials gave aspirin for 3 months with no benefit over the 3-week regimen and a higher rate of adverse hemorrhagic effects.[19]

Anticoagulants. Many clinical situations call for anticoagulation rather than antiplatelet therapy. (Table 4) The mainstay of oral anticoagulation was for many years warfarin. Since 2009, several new oral anticoagulants have been shown to be equivalent to warfarin and, in some cases safer, and they are more convenient because then do not require international normalized ratio [INR] monitoring.

For nonvalvular atrial fibrillation (AF), stroke risk depends on the presence of other risk factors. This risk is commonly estimated based on the $CHADS_2VA_2Sc$ score (Table 5).[20] Patients with true lone AF, $CHADS_2$ score 0-1 may not benefit from anticoagulation; those with scores 2 or greater benefit. Age is not a contraindication to anticoagulation. Although age does confer greater risk of hemorrhage from anticoagulant use, the proportional increase of ischemic stroke risk with age is yet greater so that the relative benefit of anticoagulation increases with age.[21]

The three factor Xa inhibitors, apixaban, rivaroxaban, and edoxaban, and the direct thrombin inhibitor dabigatran have all been shown to be roughly equivalent (noninferior) to warfarin for stroke prevention in AF.[22-25] All may serve as appropriate substitutes. We typically choose apixaban based on the low risk of adverse effects and the favorable pharmacokinetics for twice daily dosing. Several studies

Table 3 Protocol for IV tPA for Acute Ischemic Stroke

Indications for IV thrombolysis
1. Acute ischemic stroke with disabling deficit
2. Onset time within 3 h and within
3. Onset time within 3-4.5 h with these added exclusions:
   a. Age >80 years
   b. NIHSS >25
   c. Taking oral anticoagulants
   d. History of both diabetes mellitus and prior stroke
4. Head CT without well-established infarct, hemorrhage, or alternative explanation for the focal neurologic deficit

Absolute Contraindications
1. Head CT showing hemorrhage, or well-established infarct, or other diagnosis that contraindicates treatment, such as tumor, abscess, etc.
2. Known CNS vascular malformation or tumor (except certain benign tumors, such as small meningiomas, etc.)
3. Mild deficit
4. Added exclusions for 3-4.5 h use (see above)

Relative Contraindications*
1. Bacterial endocarditis
2. Significant trauma within 3 mo
3. Stroke within 3 mo
4. History of intracranial hemorrhage or symptoms suspicious for SAH
5. Major surgery within 14 d; minor surgery within 10 d, including liver or kidney biopsy, thoracocentesis, lumbar puncture
6. Arterial puncture at noncompressible site. Within 7 d
7. Gastrointestinal, urologic, or pulmonary hemorrhage within 21 d
8. Known bleeding diathesis or hemodialysis
9. aPTT >40s; INR >1.5; platelet count <100.000/mm^3
10. SBP >185 or DBP> 110, despite therapy to lower BP acutely
11. Seizure at onset of stroke†
12. Glucose < 50 or >400 mg/dL†

aPTT = activated partial thromboplastin time; BP = blood pressure; CNS = central nervous system; CT = computed tomography; DBP = diastolic blood pressure; INR = international normalized ratio; IV= intravenous; MR = magnetic resonance; NIHSS = National Institutes of Health Stroke Scale; SAH = subarachnoid hemorrhage; SBP = systolic blood pressure; tPA = tissue-plasminogen activator.

*In clinical practice where the risk of permanent disability due to stroke is felt to be great, judgments may favor therapy.

†This relative contraindication is intended to prevent the treatment of patients with focal deficits due to cause other than stroke. If the deficit persists after correction of the glucose abnormality, or if the rapid diagnosis of a vascular occlusion can be made by CT or MR angiography, then treatment may be indicated.

suggest that rivaroxaban and apixaban may substitute for cancer-associated hypercoagulability.[26] So far, studies comparing warfarin to the newer agents have not been promising in patients with antiphospholipid antibody syndrome; therefore, we continue to recommend warfarin for that indication. Warfarin also remains the recommended anticoagulant for protection in patient with mechanical heart valve prostheses. One large trial supports the use of low-dose rivaroxaban and aspirin for long-term secondary prevention of stroke in patients wtih stable atherosclerotic vascular disease.[27]

Table 4 Indication for Anticoagulation for Stroke Prevention

Mechanical heart valve prosthesis
Atrial fibrillation (see also Table 5)
Intracardiac thrombus
Hypercoagulable states
Cerebral venous sinus thrombosis

Risk Factor Management. The major decline in the incidence of stroke in recent decades correlates with major improvements in the management of vascular risk factors, including smoking cessation and control of hypertension, hypercholesterolemia, and diabetes mellitus. Therefore, it is important to address all of these conditions for both primary and secondary stroke prevention. High-intensity statin therapy with a goal low-density lipoprotein (LDL) <70 is recommended for secondary stroke prevention in patients with atherosclerotic risk factors.[28,29] It is also important to encourage and support healthy lifestyles, including weight reduction, healthy diet, and regular exercise. We also recommend screening for obstructive sleep apnea and treatment of affected patients.

Surgical Therapies for Stroke Prevention. *Carotid endarterectomy.* Patients with symptomatic stenosis of the cervical internal carotid artery of ≥50% benefit from carotid endarterectomy (CEA) if surgeons maintain low surgical risk.[30,31] Endovascular placement of carotid artery stents (CAS) may be an alternative to CEA in selected patients.[32] Studies from approximately 20 years ago, found benefit of CEA in patients with asymptomatic carotid stenosis.[33,34] However, a fall in the risk of stroke since these studies were done has raised doubt concerning the benefit of CEA or CAS in asymptomatic patients.[35] This issue is currently under investigation in a large clinical trial.[36] Until this issue is settled, we recommend consultation with a vascular neurologist to help with optimal patient selection for CEA or CAS.

PFO closure. Patent foramen ovale (PFO) is a common and usually benign condition with estimates of approximately 25% in the general population. When patients with few vascular risk factors have embolic strokes and are

Table 5 $CHADS_2VA_2Sc$ Score

CONDITION	POINTS
C - Congestive heart failure	1
H — Hypertension	1
A_2 — Age ≥75 years	2
D — Diabetes mellitus	1
S_2 — Prior stroke or TIA or other thromboembolism	2
V — Vascular disease (CAD, PAD aortic plaque)	1
A — Age 65-74 years	1
Sc — Sex category (female)*	1

CAD = coronary artery disease; PAD = peripheral artery disease; TIA = transient ischemic attack.

*A point is given for female sex only if at least 1 other point is given.

found to have PFO, the question of device closure of the PFO arises. The risk of paradoxical embolism (RoPE) score is a useful tool to estimate the attributable risk in a particular patient.[37] Initial trials of device closure for presumed symptomatic PFO suggested that the procedure can be done safely; however, they failed to establish clear benefit.[38-41] More recent trials have shown benefit.[42,43] Consultation with a vascular neurologist and interventional cardiologist with experience in this procedure is now recommended in patients with embolic stroke or TIA without apparent alterative cause and PFO.

Extracranial-intracranial (EC-IC) bypass and indirect surgical revascularization procedures. Controlled trials of extracranial-intracranial bypass for carotid occlusion have not shown benefit.[44,45] However, in expert surgical hands, and in patients with cervical or intracranial vascular stenoses with high risk of stroke, especially in moyamoya syndrome, such procedures may be beneficial.[46] This therapy remains unvalidated, and we recommend that symptomatic patients with such vascular occlusions be evaluated by neurologists and surgeons with expertise in this area.

Intracranial stenting. Studies of the placement of intracranial arterial stents in patients with symptomatic intracranial stenoses have not shown benefit. In fact, these studies have shown an excess of events in surgically treated patients.[47,48] We currently treat such patients according to the protocol used in the medical arm of the Stenting versus Aggressive Medical Management for Preventing Recurrent Stroke in Intracranial Stenosis (SAMMPRIS) trial, saving the option of intervention for exceptional patients with demonstrated higher risk.[49]

CONCLUSIONS

Advances in recent decades in medical and surgical therapy have had a major impact on stroke care. The most important interventions continue to be the optimal application of available medical therapies for primary and secondary stroke prevention, that is, those interventions introduced and maintained by primary care physicians. Expertise is available to properly select patients for surgical therapies. Since 1995, there has been a revolution in the management of acute stroke that has led to the development of effective thrombolytic and endovascular therapies that can in many cases minimize the disability from strokes. The availability of these therapies has prompted the development of enhanced systems of stroke care to maximize patients' access to advanced care.

References

1. Virani SS, Alonso A, Benjamin EJ, et al. Heart disease and stroke statistics −2020 update: a report of the American Heart Association. *Circulation* 2020;141(9):e139–596.
2. The National Institute of Neurological Disorders and Stroke rt-PA Stroke Study Group. Tissue plasminogen activator for acute ischemic stroke. *N Engl J Med* 1995;333(24):1581–8.
3. Hacke W, Kaste M, Bluhmki E, et al. Thrombolyssis with alteplase 3 to 4.5 hours after acute ischemic stroke. *N Engl J Med* 2008;359 (13):1317–29.
4. Berkkemer OA, Fransen PSS, Beumer D, et al. for the MR CLEAN Investigators. A randomized trial of intraarterial treatment for acute ischemic stroke. *N Engl J Med* 2015;372(1):11–20.
5. Goyal M, Demchuk AM, Menon BK, et al. Randomized assessment of rapid endovascular treatment of ischemic stroke. *N Eng J Med* 2015;372(11):1019–30.
6. Campbell BCV, Mitchell PJ, Kleinig TJ, et al. for the EXTEND-IA Investigator. Endovascular therapy for ischemic stroke with perfusion-imaging selection. *N Engl J Med* 2015;372(11):1009–18.
7. Saver JL, Goyal M, Bonafe A, et al. Stent-retriever thrombectomy after intravenous t-PA vs. t-PA alone in stroke. *N Engl J Med* 2015;372(24):2285–95.
8. Jovin TG, Chamorro A, Cobo E, et al. Thrombectomy within 8 hours after symptom onset in ischemic stroke. *N Engl J Med* 2015;372 (24):2296–306.
9. Nogueira RG, Jadhav AP, Haussen DC, et al. Thrombectomy 6 to 24 hours after stroke with a mismatch between deficit and infarct. *N Engl J Med* 2018;378(1):11–21.
10. Albers GW, Marks MP, Kemp S, et al. Thrombectomy for stroke at 6 to 16 hours with selection by perfusion imaging. *N Engl J Med* 2018;378(8):708–18.
11. Antithrombotic Trialist' (ATT) Collaboration. Aspirin in the primary and secondary prevention of vascular disease: collaborative meta-analysis of individual participant data from randomized trials. *Lancet* 2009;373:1849–60.
12. CAPRIE Steering Committee. A randomized, blinded, trial of clopidogrel versus aspirin in patients at risk of ischaemic events (CAPRIE). *Lancet* 1996;348:1329–39.
13. Diener HC, Cunha ZL, Forbes C, et al. European Stroke Prevention Study 2. Dipyridamole and acetylsalicyclic acid in the secondary prevention of stroke. *J Neurol Sci* 1996;143(1-2):1–13.
14. Diener H-C, Bogousslavsky J, Brass LM, et al. Aspirin and clopidogrel compared with clopidogrel alone after recent ischaemic stroke or transient ischaemic attack in high-risk patients (MATCH): randomized, double-blind, placebo-controlled trial. *Lancet* 2004;364:331–7.
15. Bhatt DL, Fox KAA, Hacke W, et al. Clopidogrel and aspirin versus aspirin alone for the prevention of atherothrombotic events. *N Engl J Med* 2006;354(16):1706–17.
16. Sacco RL, Diener H-C, Yusuf S, et al. Aspirin and extended-release dipyridamole versus clopidogrel for recurrent stroke. *N Engl J Med* 2008;359(12):1238–51.
17. Johnston SC, Gress DR, Erowner WS, et al. Short-term prognosis after emergency-department diagnosis of transient ischemic attack. *JAMA* 2000;284:2901–6.
18. Wang Y, Wang Y, Zhao X, et al. Clopidogrel with aspirin in acute minor stroke or transient ischemic attack. *N Engl J Med* 2013;369 (1):11–9.
19. Johnston SC, Easton JD, Farrant M, et al. Clopidogrel and aspirin in acute ischemic stroke and high-risk TIA. *N Engl J Med* 2018;379 (3):215–25.
20. Lip GY, Nieuwlaat R, Pisters R, et al. Refining clinical risk stratification for predicting stroke and thromboembolism in atrial fibrillation using a novel risk factor-based approach: the Euro Heart Survey on Atrial Fibrillation. *Chest* 2010;137(2):263–72.
21. Singer DE, Chang Y, Fang MC, et al. The net clinical benefit of warfarin anticoagulation in atrial fibrillation. *Ann Intern Med* 2009;151 (5):297–305.
22. Granger CB, Alexander JH, McMurray JJV, et al. Apixaban versus warfarin in patients with atrial fibrillation. *N Engl J Med* 2011;365 (11):981–92.
23. Patel MR, Mahaffey KW, Garg J, et al. Rivaroxaban versus warfarin in nonvalvular atrial fibrillation. *N Engl J Med* 2011;365(10):883–91.
24. Giugliano RP, Ruff CT, Braunwall E, et al. Edoxaban versus warfarin in patients with atrial fibrillation. *N Engl J Med* 2013;369(22):2093–104.

25. Connolly SJ, Ezekowitz MD, Yusuf S, et al. Dabigatran versus warfarin in patients with atrial fibrillation. *N Engl J Med* 2009;361(12):1139–51.
26. Li A, Garcia DA, Lyman GH, Carrier M. Direct oral anticoagulant (DOAC) versus low-molecular-weight heparin (LMWH) for treatment of cancer associated thrombosis (CAT): A systematic review and meta-analysis. *Thrombosis Res* 2019;173:158–63.
27. Eikelboom JW, Connolly SJ, Bosch J, et al. Rivaroxaban with or without aspirin in stable cardiovascular disease. *N Engl J Med* 2017;377(14):1319–30.
28. The Stroke Prevention by Aggressive Reduction in Cholesterol Levels (SPARCL) Investigators. High-dose atorvastatin after stroke or transient ischemic attack. *N Engl J Med* 2006;355(6):349–59.
29. Amarenco P, Kim JS, Labreuche J, et al. A comparison of two LDL cholesterol targets after ischemic stroke. *N Engl J Med* 2020;382(1):9–19.
30. North American Symptomatic Carotid Endarterectomy Trial Collaborators. Beneficial effect of carotid endarterectomy in symptomatic patients with high-grade carotid stenosis. *N Engl J Med* 1991;325(7):445–53.
31. Barnett HJM, Taylor W, Eliasziw M, et al. Benefit of carotid endarterectomy in patients with symptomatic moderate or severe stenosis. *N Engl J Med* 1998;339(20):1415–25.
32. Brott TG, Hobson RW, Howard G, et al. Stenting versus endarterectomy for treatment of carotid-artery stenosis. *N Engl J Med* 2010;363(1):11–23.
33. Walker MD, Marler JR, Goldstein M, et al. Endarterectomy for asymptomatic carotid stenosis. *JAMA* 1995;273(18):1421–8.
34. MRC Asymptomatic Carotid Surgery Trial (ACST) Collaborative Group. Prevention of disabling and fatal stroke by successful carotid endarterectomy in patients without recent neurological symptoms: randomized controlled trial. *Lancet* 2004;363:1491–502.
35. Keyhani S, Cheng EM, Hoggatt KJ, et al. Comparative effectiveness of carotid endarterectomy vs initial medical therapy in patients with asymptomatic carotid stenosis. *JAMA Neurol* 2020;77:1110–21. https://doi.org/10.1001/jamaneurol.2020.1427.
36. Howard VJ, Meschia JF, Lal BK, et al. Carotid revascularization and medical management for asymptomatic carotid stenosis: protocol of the CREST-2 clinical trials. *Int J Stroke* 2017;12(7):770–8.
37. Kent DM, Ruthazer R, Weimar C, et al. An index to identify stroke-related vs incidental patent foramen ovale in cryptogenic stroke. *Neurology* 2013;81:619–25.
38. Furlan AJ, Reisman M, Massaro J, et al. Closure or medical therapy for cryptogenic stroke with patent foramen ovale. *N Engl J Med* 2012;366:991–9.
39. Meier B, Kalesan B, Mattle HP, et al. Percutaneous closure of patent foramen ovale in cryptogenic embolism. *N Engl J Med* 2013;368:1083–91.
40. Carroll JD, Saver JL, Thaler DE, et al. Closure of patent foramen ovale versus medical therapy after cryptogenic stroke. *N Engl J Med* 2013;368:1092–100.
41. Saver JL, Carroll JD, Thaler DE, et al. Long-term outcomes of patent foramen ovale closure or medical therapy after stroke. *N Engl J Med* 2017;377(11):1022–32.
42. Mas J-L, Derumeaux G, Guillon B, et al. Patent foramen ovale closure or anticoagulation vs. antiplatelets after stroke. *N Engl J Med* 2017;377(11):1011–21.
43. Søndergaard L, Kasner SE, Rhodes JF, et al. Patent foramen ovale closure or antiplatelet therapy for cryptogenic stroke. *N Engl J Med* 2017;377(11):1033–42.
44. The EC/IC Bypass Study Group. Failure of extracranial-intracranial arterial bypass to reduce the risk of ischemic stroke: Results of an international randomized trial. *N Engl J Med* 1985;313:1191–200.
45. Powers WJ, Clarke WR, Grubb RL, et al. Extracranial-intracranial bypass surgery for stroke prevention in hemodynamic cerebral ischemia: the Carotid Occlusion Surgery Study randomized trial. *JAMA* 2011;306(18):1983–92.
46. Hallemeier CL, Rich KM, Grubb RL, et al. Clinical features and outcome in North American adults with moyamoya phenomenon. *Stroke* 2006;37:1490–6.
47. Chimowitz MI, Lynn MJ, Derdeyn CP, et al. Stenting versus aggressive medical therapy for intracranial arterial stenosis. *N Engl J Med* 2011;365(11):993–1003.
48. Zaidat OO, Fitzsimmons B-F, Woodward BK, et al. Stroke in patients with symptomatic intracranial stenosis: the VISSIT randomized clinical trial. *JAMA* 2015;313(12):1240–8.
49. Alexander MJ, Zauner A, Chaloupka JC, et al. WEAVE trial: final results in 152 on-label patients. *Stroke* 2019;50(4):889–94.