1 The concept of neuroglia: a historical perspective

HELMUT KETTENMANN AND BRUCE R. RANSOM

Our intent in this chapter is to provide a historical perspective that highlights the early period of glial research. The scientific arguments and historical context were as important to us as the individual facts in trying to understand the emergence of the concept of neuroglia. One of the authors (H.K.) is German and has collected or has special access to a wide range of historical texts, most in German, permitting detailed study of some original material that has not been reviewed for decades. This was advantageous in unexpected ways. Many important nineteenth-century studies by early investigators of various nationalities were either directly published in German, such as the complete work of Gustav Retzius (Swedish), or were translated into German, including studies by Ranvier (French) and Golgi (Italian). Yet we are aware that there are more discoveries awaiting us in the historical literature recorded exclusively in Italian, Spanish, and French, particularly. We hope that this chapter will inspire individuals with unique access to documents in these languages to delve into them in an effort to bring greater clarity to the history of glial research. Several prior reviews touch on various aspects of the history of glial research (Deiters, 1865; Retzius, 1893; Lenhossék, 1895; Weigert, 1895; Robertson, 1897; Held, 1903; Penfield, 1932; Rand, 1953; Glees, 1955; Somjen, 1988; Jacobson, 1993).

It is worth considering momentarily the contentious issue of priority of discovery. The reason, of course, is that any historical work such as this cannot help but make pronouncements about the order in which scientific discoveries were made. In fact, scientists seem to have an appetite for such information, and we readily admit taking guilty pleasure in the practice. The process of assigning priority is imprecise, however, and we suggest keeping several points in mind as you read this account, or any historical account for that matter. First, the historical record itself is complicated and often incomplete. Historians inevitably view only portions of the relevant material, are influenced by their own presumptions and background, and are forced to depend, in many instances, on written accounts that are themselves derivative. Second, scientific papers from 100 or more years ago can be difficult to interpret because of ambiguous language and/or illustrations. Finally, there is the matter of defining what constitutes priority. In his enjoyable book *Foundations of Neuroscience*, Jacobson (1993) nicely states the problem: "Is priority established by the one who pronounced the original theory, or who gave the first inconclusive evidence, or who finally proved the theory? Or should priority be given to those who invented the techniques that made it possible to obtain the facts?" He does not provide an answer to this question, nor do we.

VIRCHOW COINS THE NAME

> Belief begins where science leaves off and ends where science begins.
>
> —*Rudolph Virchow*

Ironically, the concept of neuroglia may have been introduced prior to the actual discovery of the cells. In fact, as first used, the term *neuroglia* was more about interstitial substance than about cells. At a minimum, it can be said that Virchow's invention of the term *neuroglia* in 1856 predated clear histological recognition of the cells that we call neuroglia today.

Discovery is heavily influenced by the intellectual milieu. When the term *neuroglia* was coined, the *cell concept* was becoming established. Schleiden, and other botanists first developed the *cell theory* through the study of plants. An after-dinner conversation with Schleiden propelled Theodor Schwann (1810–1882) to search for and discover nucleated cells in animal tissues. This led Schwann to pronounce what Garrison (1929) calls "the most important generalization in the science of morphology, viz., the principle of structural similarity in animal and vegetable tissues." Other young scientists and students directed by Johannes Müller, the chairman of the department of physiology and anatomy at Berlin University, did pioneering work on the fundamental nature of tissues starting in the late

Scanned by CamScanner

1830s. Along with Schleiden and Schwann, Jakob Henle, Rudolph Albert Kölliker, Robert Remak, and Rudolf Virchow studied various tissues and strengthened the concept that all tissues are built from cells. An error had crept into this theory, however. It was believed by the influential Schwann that cells developed from a matrix referred to as the *cytoblastema*. Virchow pointed out that this was tantamount to acceptance of *spontaneous generation*. One of Virchow's greatest contributions was his work supporting the concept that all cells derive from other cells ("Omnis cellula e cellula").

Rudolph Virchow (1821–1902) was a pathologist, and his main object of study was diseased tissue. He had abundant access to postmortem human tissue and was familiar with diseased brains. A prevailing theory, supported by Virchow, held that cells derived from ectoderm must directly contact cells of mesodermal origin. Moreover, he had published extensively on the topic of connective tissue, a mesodermal tissue that was a frequent site of inflammation. These ideas were in the air when *neuroglia* was first defined. Virchow, only 35 years old at the time, published an annotated two-volume collection of his papers in 1856 (Virchow, 1856). In a comment about his previous paper "Ueber das granulierte Ansehen der Wandung der Gehirnventrikel" (On the granulated appearance of the ventricular walls) (Virchow, 1846), he wrote: "In accordance with my studies, the ependyma does not only consist of an epithelium, but is a connective tissue layer covered by an epithelium. Despite the fact that it can be dissected from the surface, it does not form an isolated skin in the true sense of the word, but is a connective tissue originating from the brain and protruding on to the brain's surface. This connective substance forms a sort of cement (neuroglia) in the brain, spinal cord and higher sensory nerves, in which the nervous elements are embedded. Studied freshly, one finds a granulated, very rich substance with oval, fairly large nuclei, which was previously considered as a particular form of nerve tissue. These nuclei are contained in very soft and fragile cells, which can be observed in fresh objects, but more clearly after fixation."

In his book *Cellular Pathology*, Virchow elaborated further on neuroglia. This book, published in 1858, was based on a series of 20 lectures held between February and April 1858 in the Pathology Institute in Berlin. It has influenced a generation of scientists and also contains Virchow's first illustrations of neuroglia (Fig. 1.1). The historical importance of this book is that it introduces and provides support for the concept that diseases are a consequence of cellular changes. In the 13th lecture, held on April 3, 1858 Virchow states (Virchow, 1858; see also Virchow, 1978): "Hitherto, gentlemen, in considering the nervous system, I have only spoken of the really nervous parts of it. But if we would

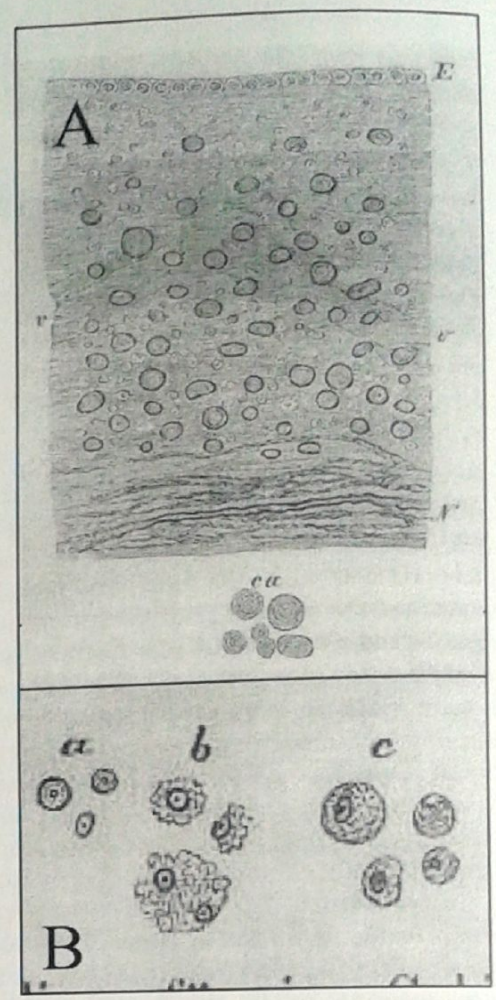

FIGURE 1.1 Virchow's illustration of neuroglia. *A*. Ependyma and neuroglia in the floor of the fourth ventricle. Between the ependyma and the nerve fibers is "the free portion of the neuroglia with numerous connective tissue corpuscles and nuclei." Numerous corpora amylacea are also visible, shown enlarged below the main illustration (*ca*). *E*: ependymal epithelium; *N*: nerve fibers; *v-w*: blood vessel. *B*: Elements of neuroglia from white matter of the human cerebral hemispheres. *a*. free nuclei with nucleoli; *b*. nuclei with partially destroyed cell bodies; *c*: complete cells. (From Virchow, 1858.)

study the nervous system in its real relations in the body, it is extremely important to have a knowledge of that substance also which lies between the proper nervous parts, holds them together and gives the whole its form in a greater or less degree" (p. 272). Further on he explains the term neuroglia:

"This peculiarity of the membrane (i.e., the layer immediately beneath the ependyma), namely, that it becomes continuous with the interstitial matter, the real cement, which binds the nervous elements together, and that in all its properties it constitutes a tissue different from the other forms of connective tissue, has induced me to give it a new name, that of *neuro-glia* (nerve-cement). The view that the substance in question belongs to the class of connective tissues has recently been admitted on nearly all sides, but with regard to the ex-

Scanned by CamScanner

tent to which any isolated structures that occur in it are to be considered as belonging to this substance, opinions are divided" (1978, p. 277). In the end, however, he concludes: "where neuro-glia is met with, it also contains a certain number of cellular elements" (Virchow, 1978, p. 278). He referred to these cells variably as *connective tissue corpuscles* or *elements of the neuro-glia*, never as *neuro-glial cells*. He did not comment on the role of these cells or how they related to neuro-glia (i.e., brain interstitial substance).

We may conclude, therefore (although it is not emphasized in most historical accounts), that Virchow in 1856 used the term *neuro-glia* to refer to interstitial substance, not to the cellular elements within it. Time has blurred this distinction. What then is Virchow's interstitial substance or tissue in today's terms? It is undoubtedly the complex, space-filling processes of macroglial cells, especially astrocytes (Nedergaard et al., 2003). So, in retrospect, the meaning of Virchow's term *neuro-glia* morphed to accommodate the reality that neuroglial cells are the material between neurons. In other words, the two terms, *neuroglia* and *neuroglial cells*, soon became synonymous.

MÜLLER CELLS ARE THE FIRST WELL-DESCRIBED AND DEPICTED GLIAL CELLS

Virchow's published figures illustrating his "new" tissue (and the cells it contained) in *Cellular Pathology* are often considered the first images of glial cells. These illustrations show what are presumed to be "connective-tissue-corpuscles and nuclei" beneath ependymal cells in the floor of the fourth ventricle (Fig. 1.1). Historically, it has generally been accepted that these are the nuclei of astrocytes or oligodendrocytes but, given the location, it seems possible that some, maybe most, are the nuclei of small neurons. The influential neurohistologist Weigert summed up the evidence in 1895 and concluded that Virchow had described and illustrated neuroglial cells (see above). Jacobson (1993), however, provides an alternative view: "It is doubtful whether Virchow saw neuroglial cells in 1846 and there are no convincing pictures of them in Virchow's book, Die Cellularpathologie (1858), although he there discusses the theory of a neuroglial tissue." Given the vagaries of microscopy in this era, especially tissue fixation and staining, it is not possible to say with certainty what these objects were.

While most historians award Virchow exclusive credit for first recognizing glial cells, another pathologist published a picture of a glial cell in the same year, and his picture was vastly superior in clarity. Heinrich Müller (1820–1864) already noted in 1851 that the retina contains radial fibers (Müller, 1851), and in 1852 his colleague Kölliker termed these *Müller fibers* (Kölliker, 1852). In his detailed article Müller compares the retina in the fish (perch), amphibia (frog), bird (pigeon), and human. In his summary he states: "The presence of radial fibers is a common feature. In all cases, they extend from the inner surface of the retina to the inner granular layer where they show a swelling containing a nucleus; from there they continue to the outer layers." Müller had clearly recognized that these fibers are part of a cell with the soma in the inner granular layer. This is convincingly supported by his figures (Fig. 1.2*A*,*B*), which are, in fact, the first documentation of a glial cell (i.e., two years prior to Virchow's publication!). Still, one must credit Virchow for introducing the theory of a neuroglial tissue, even if "the theory led and the facts followed" (Jacobson, 1993). It is this theory or idea, more than anything else, that secures for Virchow his special place in the history of this field.

There is an interesting story about Virchow and Müller that influenced the discovery of the Müller cell. Müller was a senior assistant in the department of pathology at Würzburg with a research focus on cancer. He took over the chair of pathology as a deputy after the sudden death of Bernard Mohr, the previous chair holder, in 1848, and most of his colleagues in the faculty favored him as the next chair holder. At the same time that this nomination process was moving forward, Virchow was having political problems in Berlin because he was an active member in the 1848–1849 revolution. After the revolution failed, Virchow's career in Berlin seemed at an end. The faculty in Würzburg recognized their chance and offered the chair of pathology to Virchow, not to Müller. Virchow accepted the position (he returned to Berlin seven years later to become professor of pathology). Müller was so depressed by this unfortunate turn of events that he had to recover for half a year in a sanatorium. After his return, he decided to switch to comparative histology and joined Kölliker's department of anatomy and histology. There he began his thorough analysis of retinal histology.

While Müller's illustrations showed clearly the cell that bears his name, even judged by today's standards, soon thereafter (in 1859) utterly stunning pictures of these cells were published by Max Schultze (Fig. 1.2C). Schultze's illustrations seem almost modern in their detail and precision. He went on to have an illustrious career and is referred to by Garrison (1929) as "the master worker of histology." He succeeded the great Helmholtz in Bonn in 1859.

All these studies were done on unstained tissue. The cells were isolated by very carefully teasing the tissue apart with fine needles and thereby trying to isolate single cells or ensembles of a few cells. Of course, this was much easier in the retina than in the whole brain and explains why the first modern pictures of glial cells came from the retina.

Scanned by CamScanner

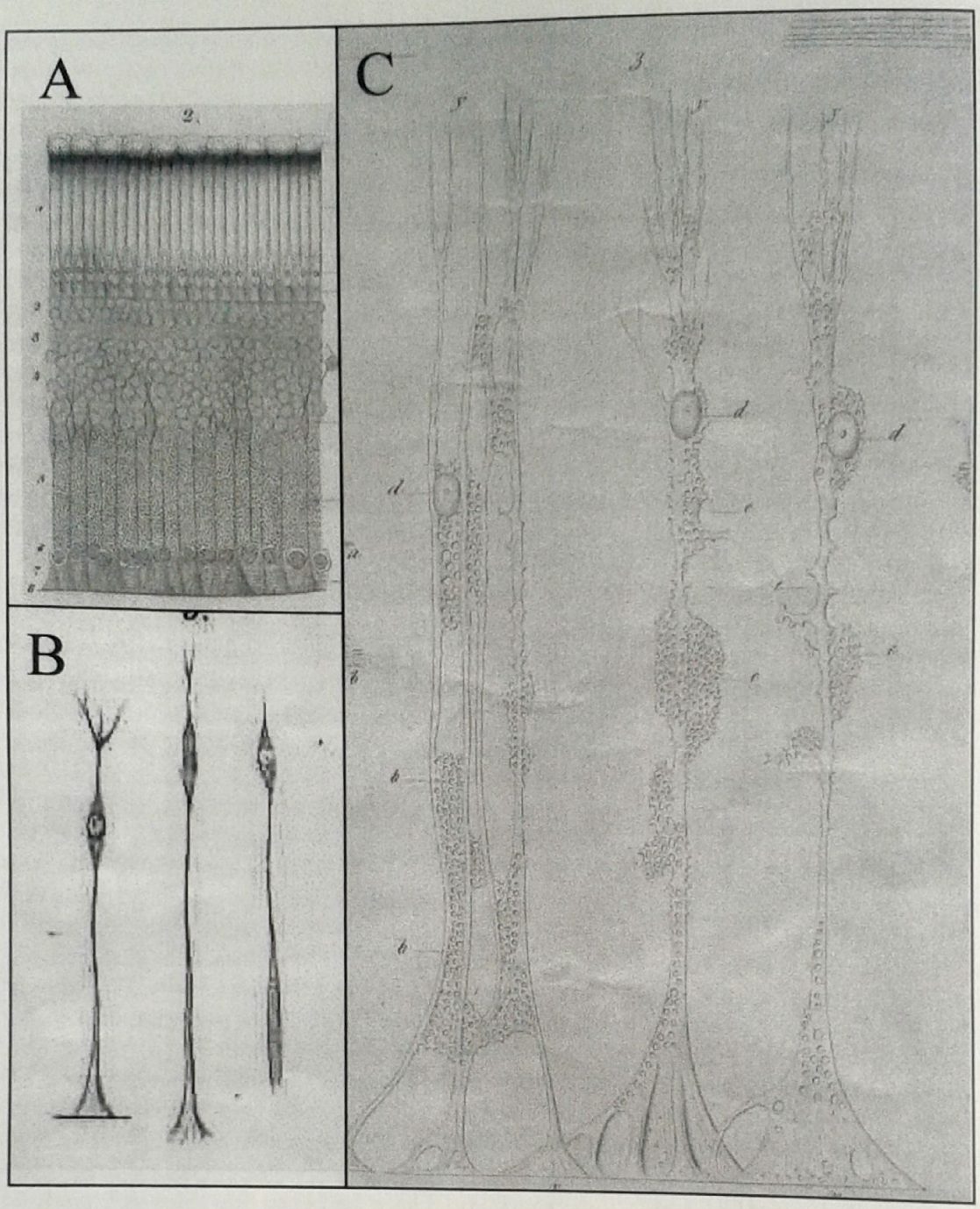

FIGURE 1.2 Retinal neuroglial cells. *A*. Cross section of frog retina. Note the radial (i.e., Müller) cells with their characteristic endfeet in the layer numbered "8." *B*. Isolated radial fibers from the frog retina. *C*. Müller fibers of the sheep retina. Brush-like processes extend from the Müller fiber in the outer granular layer (labeled *y*); *b*. very delicate network of fenestrated membranes similar to those in the ganglion cell layer; *c*. network in the molecular layer; *d*. nuclei shown as part of the Müller fibers; *e*. cavity in which the nuclei or the cells of the internal granular layer are located. *A* and *B* from Müller (1856). *C* from Schultze (1859).

STELLATE CELLS ARE FOUND IN WHITE AND GRAY MATTER

Otto Deiters (1834–1863) is considered the first to provide illustrations of a cell type that resembles our modern notion of an astrocyte (Cajal, 1909, 1911). In fact, in the chapter on neuroglia in his exhaustive neurohistology tome *Histology of the Nervous System* (1909), Santiago Ramon y Cajal (1852–1934) refers to Deiters as "the scholar who discovered them." As a consequence, authoritative textbooks (e.g., Ferguson, 1905; Cajal, 1909–1911) for many years used the term *Deiter's cell* synonymously with *astrocyte*. The story of Deiters' contribution is of interest, and we offer a small amendment to the historical record that strengthens his claims.

Deiters died at 29 of typhoid fever and left his crucial observations in the form of a draft manuscript. His friend Max Schultze (see above) finalized the manuscript and published it in 1865, two years after Deit-

Scanned by CamScanner

ers' death (Deiters, 1865). Deiters clearly described cells in white matter that were not neurons; he believed these were component parts of brain connective tissue, following the lead of Virchow. He described them as follows: "The shiny nucleus which lacks a nucleolus, is the origin of many fibers. They have a firm, but slender appearance and project in all directions . . . they are not only found in all forms of white matter, but also in grey matter" (Deiters, 1865). An apparent error in the labeling of his illustrations in 1865, never publicly corrected as far as we can tell, has led to questions about his observations (e.g., Somjen, 1988). Deiters illustrated two cells: as published, the one recognizable as a typical white matter fibrous astrocyte, using today's terminology, is *labeled* as located in gray matter (i.e., the hypoglossal nucleus). Unfortunately, the printer mixed up the legend and the picture. When one carefully reads the original text, it is clear that what Deiters saw in white matter was the cell in panel *A*, not the cell in panel *B*. Thus, the authenticity of his description rings true when one compares his picture (i.e., Fig. 1.3*A*) to modern images of dye-filled fibrous astrocytes (e.g., figure 9 in Butt and Ransom, 1993). The nature of the cell he illustrates in panel B (the cell from gray matter) is less certain, the confusion arising in part because of the admixture of neurons and neuroglia in this area. Deiters' posthumous 1865 publication is also famous for the exceptionally clear illustrations of axons having direct continuity with neuron cell bodies; this addressed the controversy of whether axons and neurons were connected.

Four years later, in 1869, Jakob Henle (1809–1885), together with his son-in-law Friedrich Merkel, published the first figure of a network of star-shaped cells in white matter (Fig. 1.3*C*). The stain he used was carmine red after fixation with chromic acid. Henle was an influential anatomist, and he opposed from the beginning Virchow's view that the brain contains connective tissue. Henle and Virchow knew each other from their time as students in Berlin, both completing a doctoral thesis in Müller's department. Virchow writes about Henle in his description of neuroglia in 1856: "Henle took efforts in his own interest to delay this insight (connective tissue in the brain). Moreover, he had the impudence to maintain, that I mixed up granules with nuclei and fine nerve fibers with connective tissue." While Henle's pictures enhanced the documentation of macroglia, his written interpretations were confusing and he argued against Virchow's concept of neuroglia.

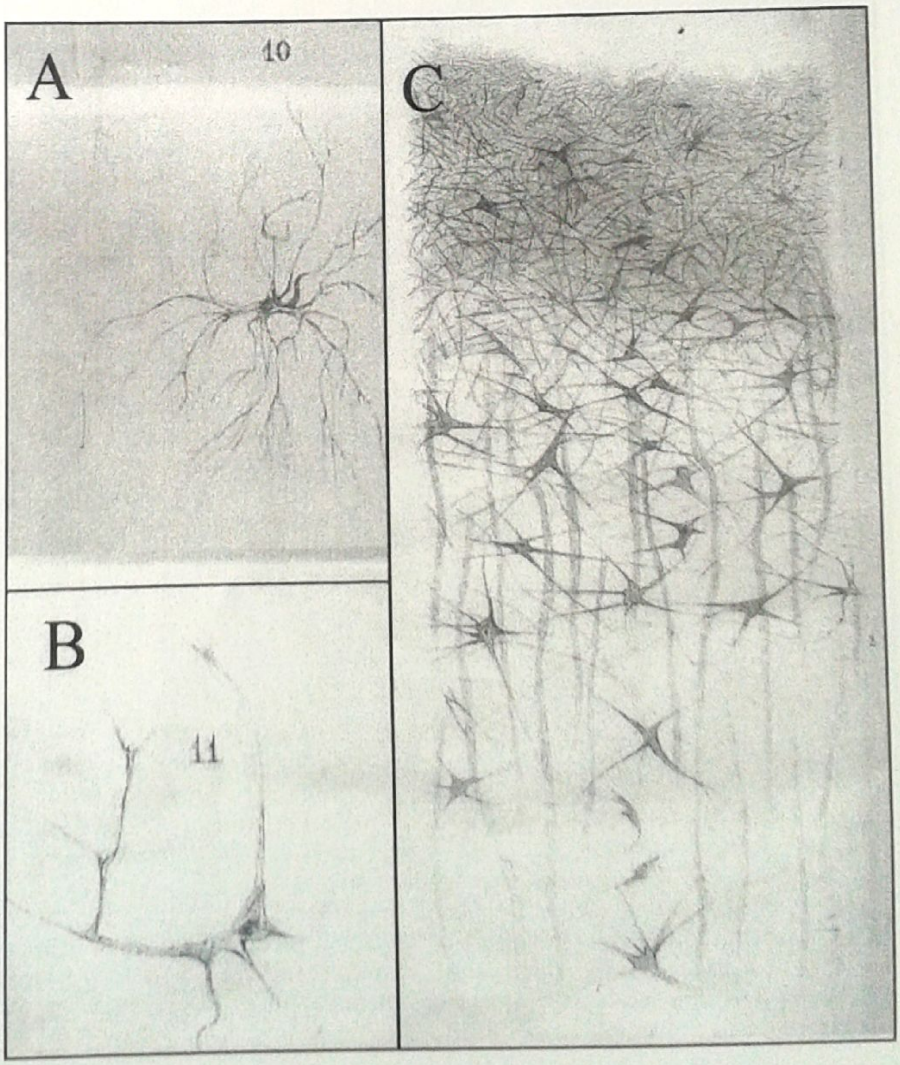

FIGURE 1.3 Deiters' illustrations of connective tissue cells. *A*. Connective tissue cell from white matter. *B*. Connective tissue cell from gray matter (hypoglossal nucleus). (From Deiters, 1865.) See text for details. *C*. Section from the spinal cord of the ox stained by carmine after chromic acid preparation. *1*. gray matter; *2*. white matter with exposed axons; multipolar connective tissue cells (magnification 400×). (From Henle and Merkel, 1869.)

Scanned by CamScanner

GOLGI DESCRIBES CELLS WITH CHARACTERISTIC FEATURES OF ASTROCYTES AND OLIGODENDROCYTES

Camillo Golgi's (1843–1926) study of neuroglia began with papers in 1870 and 1871 using hematoxylin and carmine staining or no staining at all. Neither neurons nor neuroglia were stained completely by these techniques, but his publications suggested a diversity of glial cells in gray and white matter (Fig. 1.4). He also noted that blood vessels are contacted by glial cell processes (Fig. 1.4*B*). This passage is taken from his famous book *Contribuzione alla fina Anatomia degli organi centrali del sistema nervosos*, published in 1871: "Studying thin slices of treated cortical substance (osmium treated for 4 to 6 h) with addition of glycerin with the microscope, revealed numerous, roundish, oval or star-shaped cells, from which numerous, long, fine and never arborized prolongations originate. . . . Many (prolongations) extend to the vessel walls, including capillaries, vessels of medium size (particularly to those) and directly attach to the walls of the capillaries or to the lymphatic border of vessels with larger diameter. . . . The surround of the vessels is demarcated by a dense, regular network of fibers." That some of his cells contacted blood vessels is strong evidence that these represented astrocytes. In studying white matter, he may have recognized oligodendrocytes and specifically pointed out that processes of his white matter cells appeared to contact axons (Fig. 1.4*C*). His observation of cells aligned in a row, a characteristic feature of oligodendrocytes in white matter, is convincing: "In carmine-stained parallel slices, after carefully brushing and rinsing with water and watching them under the microscope in glycerin or water and glycerin, one can recognize the above mentioned cells in between the nerve fibers, which are

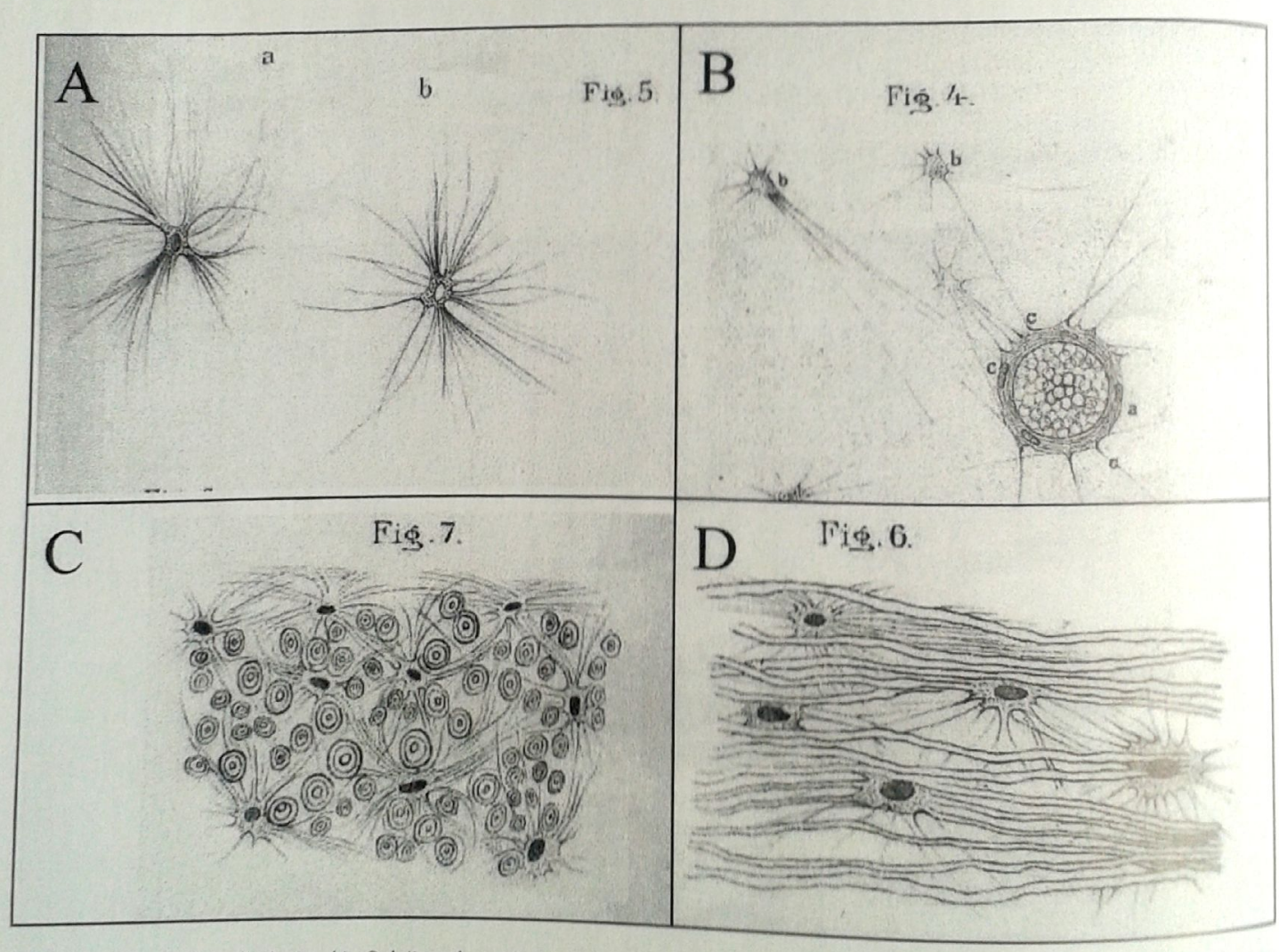

FIGURE 1.4 Neuroglial cells depicted in Golgi's early work. *A. a.* Neuroglial cell from the superficial layer of the cerebral cortex; *b.* neuroglial cell from the deeper cortical layer of the cerebrum from a 2-month-old child. The cell bodies and proximal processes contain fat droplets. *B.* Slice of the cerebral cortex hardened in osmium; *a.* blood vessel; *b.* neuroglial cells with multiple thread-like processes; *c.* processes from neuroglial cells terminating on the vessel wall. *C.* Section through deep white matter tracts. Between the axons and directly attached are several flattened neuroglial cells. Neuroglial processes project in all directions among the axons and attach to their ensheathments. *D.* Neuroglial cells in white matter. Longitudinal view of neuroglial cells showing their relationship to axons. All panels from Golgi (1894).

Scanned by CamScanner

single or in groups or in rows of 3 to 4 or more; the thin processes are combined into bundles and run preferentially parallel with the nerve fibers and attach to them. Where these cells are numerous, they almost form an ensheathment of the fiber" (Fig. 1.4C,*D*).

Golgi's greatest contribution, some would argue, was his famous *reaziona nera*, or black reaction, that permitted entire neurons and glial cells to be stained (Fig. 1.5). While this method (potassium dichromate-silver) did not *distinguish* between neurons and neuroglia, it allowed them to be visualized better than ever before and in their entirety. Only later would specific stains for neuroglia appear (Cajal, 1913; Rio-Hortega, 1919). In the meantime, neuroglia were identified by a process of elimination. Reider (1906) quotes Carl Weigert (the German pathologist who introduced a specific stain for myelin) on this point: "one recognized neuroglia as the structure that one could not or would not call neuronal." Nevertheless, in the hands of workers like Golgi, Andriezen, and Cajal, the Golgi technique was a powerful tool that accelerated the understanding and classification of neuroglia. So impressive were the gains in knowledge that by 1909 Cajal could say (Cajal, 1995): "We have emphasized that two special elements, which are really abstractions derived from many examples, form all neural tissue: the neuron with its various processes and the glial cell."

In most of his beautiful drawings from hippocampus or cortex, Golgi depicts glial cells as a part of the tissue. One of his most intriguing pictures shows the glial populations of the cerebellum (Fig. 1.5). He recognized that the fibers in the molecular layer, originally discovered in 1857 by the German Karl Bergmann (1814–1865) (Bergmann, 1857), are processes of glial cells. For many years these cells were called *Golgi epithelial cells* for this reason (the term *Bergmann glia* has more recently become popular again).

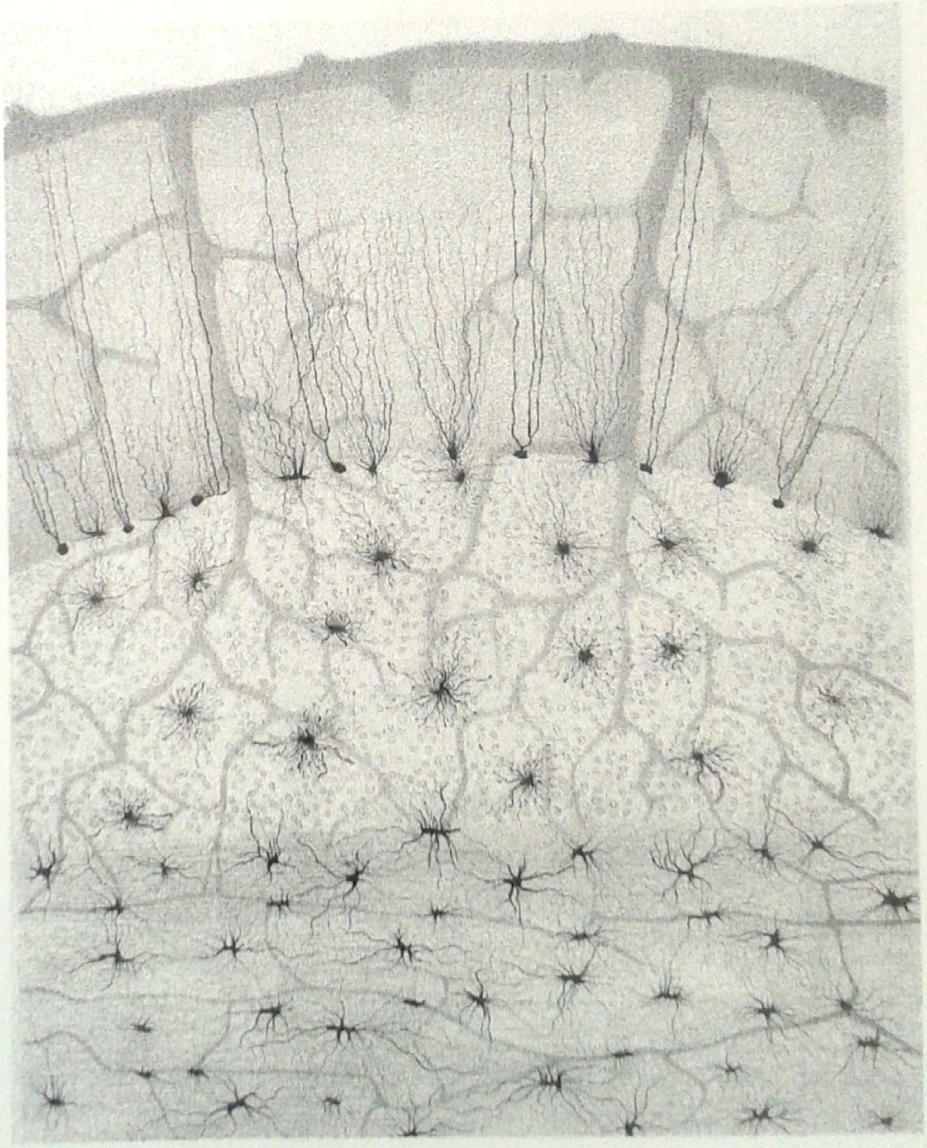

FIGURE 1.5 Vertical slice from the human cerebellum showing the glial cells in this structure, including the Golgi epithelial cells (also known as *Bergmann glial cells*). (From Golgi (1894).

Scanned by CamScanner

A point of contention about glial fibers should be mentioned. Golgi's studies indicated that glial fibers existed as component parts of each glial cell. This was diametrically opposed to the view of Weigert (1895), supported by others including Ranvier (1883). Weigert contended that glial fibers were "neither branches of the cell nor identical in composition with the cytoplasm of the cell—they were therefore not cell branches but independent fibres" (Glees, 1955). In spite of this position, he seems to have believed that glial cells made the fibers and perhaps helped to maintain them. Cajal (1995) discussed this carefully and concluded that the results of the silver chromate staining method strongly favored Golgi's conclusion.

THE WORD *ASTROCYTE* IS INVENTED

In 1893 Michael von Lenhossek (1863–1937) from Würzburg introduced the term *astrocyte* to refer to star-shaped neuroglial cells. He wrote the first extensive review on glial cells in a textbook on the fine structure of the nervous system focusing on spinal cord. He states that what people had considered glial cells were a mixture of more than one cell type. He explained the need to use more specific terms in dealing with these cells (Leuhossek, 1893): "I would suggest that all supportive cells be named spongiocytes, and the most common form in vertebrates be named spider cells or astrocytes, and use the term neuroglia only cum grano salis (with a grain of salt), at least until we have a clearer view. . . . Astrocytes are the small elements, which form the supportive system of the spinal cord. They are star shaped and indeed no other comparison describes their form so clearly. While the term spider cell introduced by Jastrowitz has become popular and gives a proper impression of the cells, one should regard Gierke's note, namely that nobody has seen a spider with so many feet as these cells have processes." The cells he was describing are shown in Figure 1.6*A*.

The term *astrocyte* was used variably thereafter. Robertson did not use the term in his review of neuroglia in 1897 nor does Cajal in his general chapter on neuroglia in *Histology of the Nervous System* (1909–1911). Curiously, he employs the term regularly in later sections of these books. Andriezen (1893) and Koelliker (1889) divided glia (i.e. astrocytes, although they did not use this term) into two groups. Fibrous glia or *Langstrahler* (long projectors) had long processes and were found mainly in white matter, while protoplasmic astrocytes or *Kurzstrahler* (short projectors) either had only short processes or lacked obvious fibers and were more common in gray matter.

Because Virchow thought that neuroglia constituted connective tissue, it was assumed that these cells must arise from mesoderm. This idea died slowly. The failure of connective tissue stains, increasingly specific for mesoderm, to stain these cells was one line of evidence refuting the idea that they were mesodermal, but it left open the defense that negative results might only mean that neuroglial cells were a special type of connective tissue. Wilhelm His (1831–1904) studied early development and recognized that neuroblasts and spongioblasts, which formed radial glia, are both of ectodermal origin (His, 1889). Lenhossek (1893) showed that the radially aligned spongioblasts transformed into astrocytes (Fig. 1.6*B*) (later confirmed by Cajal [1913]). These findings were finally accepted as definitive proof that astrocytes were of ectodermal origin.

Another long-standing misimpression was that neuroglial cells formed a physical syncytium, often called the *neurospongium* (His, 1889). In retrospect, this mistake was mainly a consequence of limited microscopic resolution and misleading staining techniques. It was seriously questioned by many, including Lenhossek (Fig. 1.6) and Cajal, whose studies using the Golgi technique showed separate glial cells that transitioned from radial glial cells to typical astrocytes during development. The syncytium theory also came under attack when it became apparent that a normal glial cell could exist immediately adjacent to a glial cell showing marked pathological change; this did not make sense if the cells were continuous with one another. Unassailable evidence, however, was not provided until the 1950s, when the newly developed electron microscope showed that glial cells are always separated from each other by a thin layer of extracellular space.

THE SCHWANN CELL AND MYELIN

A comprehensive and insightful review of the history of myelin and the cells that produce it can be found in Jacobson's book (1993). This was an area of neuroscience that remained mired in controversy for more than a century. The questions being pondered, such as what cell makes myelin and how myelin forms on axons, simply could not be answered definitively until the invention of the electron microscope, a major technological leap of the mid-twentieth century. In other words, the history of this topic reveals the consequences of a persistent, unsolvable riddle: Contradictory theories flourished and became entrenched because no one point of view could gain the upper hand. The tale of myelin also teaches a humbling precept about scientific theories; theories most consistent with available evidence are not always destined to be right (for example, the highly plausible theory that myelin is secreted by axons).

Robert Remak (1815–1865) was the first to state that some nerve fibers in the peripheral nervous system had a distinct sheath and were thicker than fibers without this sheath (Fig. 1.7*A*,*B*) (1838). He called the fibers

Scanned by CamScanner

FIGURE 1.6 Astrocytes and radial glia in material prepared by Lenhossek in 1893. *A*: Supportive cells (i.e. astrocytes) from the spinal cord of a 9-month-old child; Golgi impregnation. *B*. Spinal cord of a 14 cm human embryo; Golgi impregnation of the supportive cells. *Left*: ependymal (i.e., radial glial) scaffold. *Right*: precursors of spider cells (astroblasts). (From Lenhossek, 1893.)

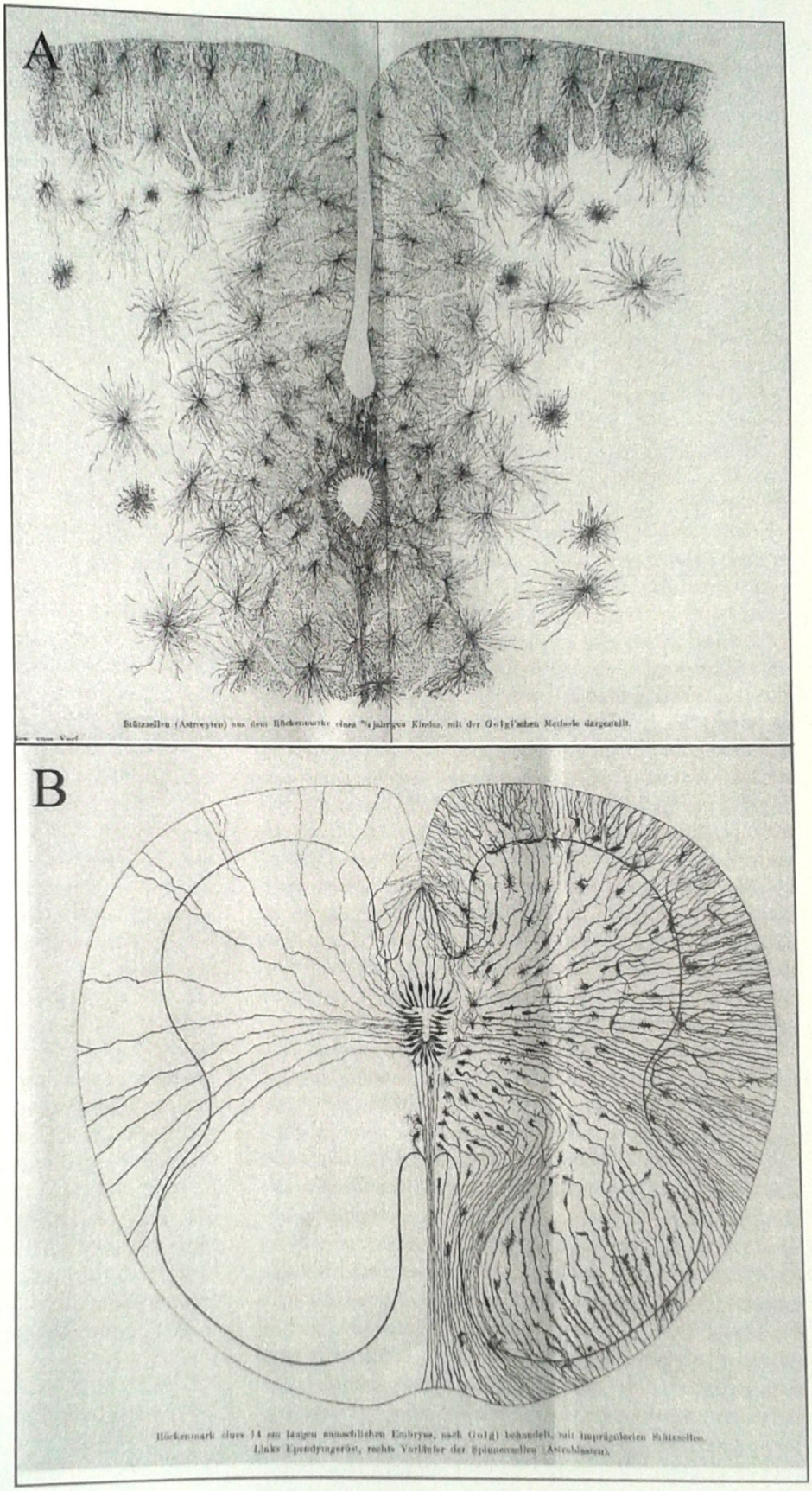

Scanned by CamScanner

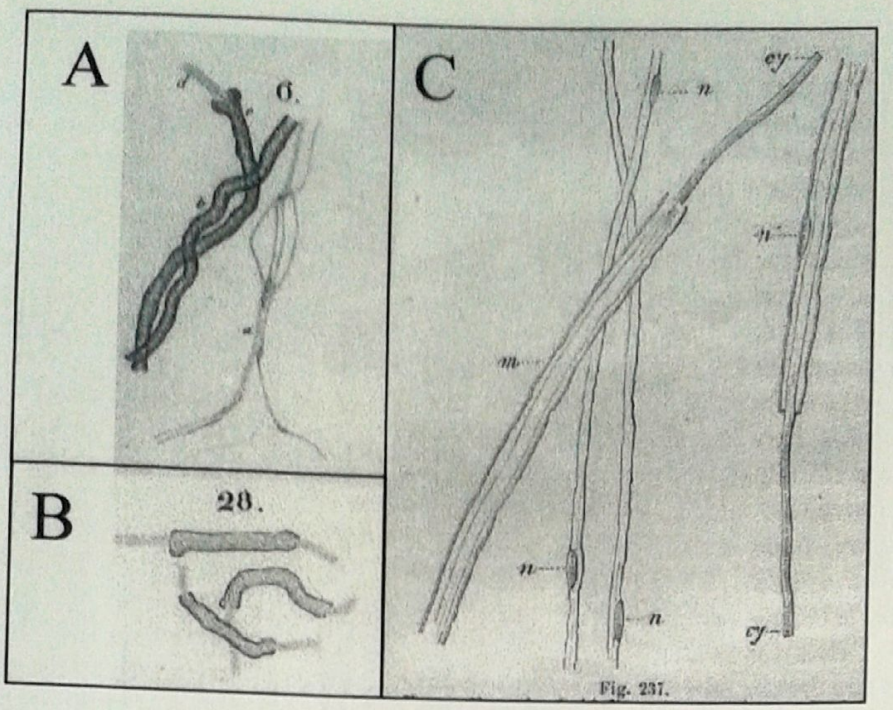

FIGURE 1.7 Illustrations of nerve fibers and their myelin sheaths. *A*. From the posterior root of the nervus alicujus lumbalis (magnification 200×). Organic fibers labeled *b* and *c*; primitive tubes labeled *a*. At *d*, the primitive fiber appears unsheathed. *B*. Fiber from rabbit cerebellum (magnification 110×). One can recognize the delicate sheath and the transparent fiber. *C*. Nerve fibers from the sciatic nerve of rabbit: *cy*: axon; *m*: myelin sheath; *n*: nuclei of the segments. *A* and *B* from Remak (1838). *C* from Ranvier (1875)

with sheaths *tubulus primitivus* (i.e., primitive tubes) and illustrated the nuclei associated with the sheaths. He called the nonmedullated fibers, that is, those without a sheath, *organic fibers*. His careful description of nonmedullated fibers in the sympathetic nervous system led to the practice of calling these *Remak fibers* (e.g., Cajal, [1995]). Schwann, in 1839, confirmed Remak's observation of medullated fibers with nuclei. He proposed that individual sheath nuclei were a remnant of an earlier stage when the nuclei formed a continuous chain of cells that coalesced to form the nerve fibers. Despite subsequent observations suggesting that axons grew independently of the sheath nuclei, Schwann's incorrect *cell-chain* or *catenary* theory held sway until the early twentieth century.

The medullary sheath came to be distinguished as a separate structure from a second sheath immediately external to it. This external covering was considered a "special investment of connective tissue, constituting the so-called sheath of Schwann" (Schultze, 1870). Although Schwann's name had gradually become attached to the external sheath, the term *Schwann cell* came much later. Illustrations in Ranvier's (1872) and Stricker's textbooks (1871) showed that Schwann sheaths contained or were associated with nuclei (Fig. 1.7*C*). To understand why the connection was not immediately made that the medullary sheath arose from a cell, one must recall that some scientists, like Jakob Henle, argued that the nervous system contained free nuclei. The term *Schwann cell* appears to have been first used by Louis-Antoine Ranvier (1835–1922) in 1871, but it may not have come into common usage until Cajal's treatise was published in 1909. It is not entirely clear why Schwann's name, and not Remak's, became associated with the sheath cells. Remak's clear illustration of the sheath with a nucleus in 1838 constitutes, at least technically, the first image of a glial cell.

Virchow enters the picture again in the story about peripheral glia. He introduced the term *myelin* in 1858 to refer to the fatty sheath surrounding some axons: "It is this substance, for which I have proposed the name of medullary matter (Markstoff), or *myeline*, that in extremely large quantity fills up the interval between the axis-cylinder and the sheath in primitive nerve-fibers" (Virchow, 1978). He, like many of his contemporaries, felt that myelin was secreted by the axon, not made by the Schwann cell. For example, in 1909 Cajal states: "Also, many writers, including ourselves, view myelin itself as nothing more than a secretory product of axons, rather than the contents of a cell that the axon passes through." This concept endured as long as it did, in part, because central nervous system (CNS) myelin appeared not to be associated with nuclei; in the apparent absence of a cell to make myelin, it seemed logical that the axon must make it. Ranvier was not the first to see interruptions in the myelin covering axons, but he was the first to realize that these interruptions were not artifacts. He correctly perceived that the axon was passing through a series of independent myelin segments and that each segment was associated with a single Schwann cell (Ranvier, 1872).

SPECULATIONS ON FUNCTION

In *Histology of the Nervous System*, Cajal (1995) summarized what was known about the functions of glia. He did not consider Schwann cells glia, and microglia and oligodendrocytes were not yet discovered, so his discussion was exclusively about astrocytes. He begins

Scanned by CamScanner

with these prescient remarks: "What is the function of glial cells in neural centers? The answer is still not known, and the problem is even more serious because it may remain unsolved for many years to come until physiologists find direct methods to attack it."

He first addressed the suggestion by Golgi and his students that glial cells carry important nutritional fluids from capillaries to neuronal cell bodies. This idea was spawned by Golgi's observation that most astrocytes contact capillaries with their processes. Cajal raised objections to this hypothesis: (*1*) Glial cells that surround neurons often lack processes that contact capillaries. He may have been referring, without realizing it, to perineuronal oligodendrocytes. However, he illustrates protoplasmic astrocytes from adult human gray matter with processes "never appearing to end near capillaries." In retrospect, limitations imposed by available staining methods and microscopes probably caused him to overestimate this population. (2) Amphibian and fish white matter does not contain glia. Subsequent studies have at least partially refuted this statement. Nevertheless, Cajal's disregard for this theory was echoed nearly 60 years later in Kuffler and Nicholl's review (1966). Only in the past 15 years has the nutritional theory of Golgi experienced an evidence-based renaissance (see Chapter 29, this volume).

Cajal carefully considered the *filling theory* of Weigert: "According to the celebrated neurologist, Weigert, glia serve an entirely passive role, filling spaces not occupied by neurons." Cajal strongly denigrated this notion based on careful reasoning. Despite his disdain, however, similar ideas have persisted and are sometimes encountered even today (Ransom et al., 2003).

The *isolation theory* developed by his brother, P. Ramon y Cajal, received strong support. The premise was that astrocytes act as physical insulation against the passage of neuronal impulses. "These processes are always arranged so as to prevent contact between either unmyelinated axons or dendrites, or between axons and dendrites, but only at points where these two different kinds of neuronal process should not lie immediately adjacent to one another" (Cajal, 1995). In white matter, he and others of this period intuitively assigned insulating function to myelin, which posed a nasty riddle: Why are there astrocytes in white matter? Cajal had no answer. Ironically, he failed to appreciate the glial origin of myelin and so was denied the key insight that makes the isolation theory credible today, at least in regard to the oligodendrocyte.

RIO-HORTEGA AND THE RECOGNITION OF OLIGODENDROGLIA AND MICROGLIA

Cajal introduced an improved staining technique for neuroglial cells (gold chloride-sublimate) in 1913 (Cajal, 1913). This stained astrocytes more completely than was previously possible and led him to recognize other nonnervous cells that were distinct from astrocytes. Although these other cells were poorly stained, they were clear enough to warrant naming, and he called them the *third element* of the CNS. Undoubtedly, others had seen such nonnervous cells, but previously they had only constituted a "group of cells with indefinite characteristics" variably described as "naked nuclei, round, indifferent, cuboidal or preameboid cells and apolar elements" (Rio-Hortega, 1932).

Cajal's understudy, Pio del Rio-Hortega (1882–1945), took up the problem of glial cells and developed his own stain (silver carbonate) that selectively stained the third element cells (Rio-Hortega, 1921). Two distinct cell populations emerged, which he named *oligodendroglia* (and later called *oligodendrocytes* to make the nomenclature consistent for the two forms of macroglia) and *microglia* (Fig. 1.8). Oligodendrocytes, so named because they exhibited fewer and smaller branches than astrocytes, were felt to be true classical neuroglial cells of ectodermal origin (Rio-Hortega, 1928). These findings put him painfully at odds with his mentor, Cajal, who could not reproduce Rio-Hortega's observations and therefore distrusted the existence of oligodendrocytes. This disagreement ruptured their close relationship.

William Ford Robertson (1867–1923), a Scotsman, probably stained third element cells earliest of all (Fig. 1.9). In experiments with platinous oxide he stained cells that had only a few short processes, none of which associated with blood vessels (Robertson, 1897, 1899). Robertson called these cells *mesoglia* to distinguish them from neuroglia and indicate his belief that they were derived from mesoderm. Penfield apparently looked at some of Robertson's histological preparations and felt that some of the stained cells were oligodendrocytes (Penfield, 1932). Robertson probably also stained microglial cells with his technique because he stated that "the mesoglia cells seem to have a phagocyte action in certain pathological conditions" (Fig. 1.9) (Robertson, 1900).

Rio-Hortega recognized that oligodendrocytes were most common in white matter. He considered the oligodendroglia to be a member of the macroglial or classical neuroglial family. Because these cells had a relationship to myelin sheaths that bore a striking resemblance to the relationship between Schwann cells and the myelin sheaths of peripheral fibers, he proposed that oligodendrocytes made and sustained CNS myelin (Fig. 1.8, left panel). While the idea that oligodendrocytes made myelin gained in popularity, it was not proven unequivocally until the electron microscope came on the scene.

Microglia were viewed by Rio-Hortega as distinct from all other neuroglial cells because his studies showed them to be of mesodermal origin and to have migratory and phagocytic capabilities (Fig. 1.8, right panel). Rio-Hortega sumed up his position on the mi-

Scanned by CamScanner

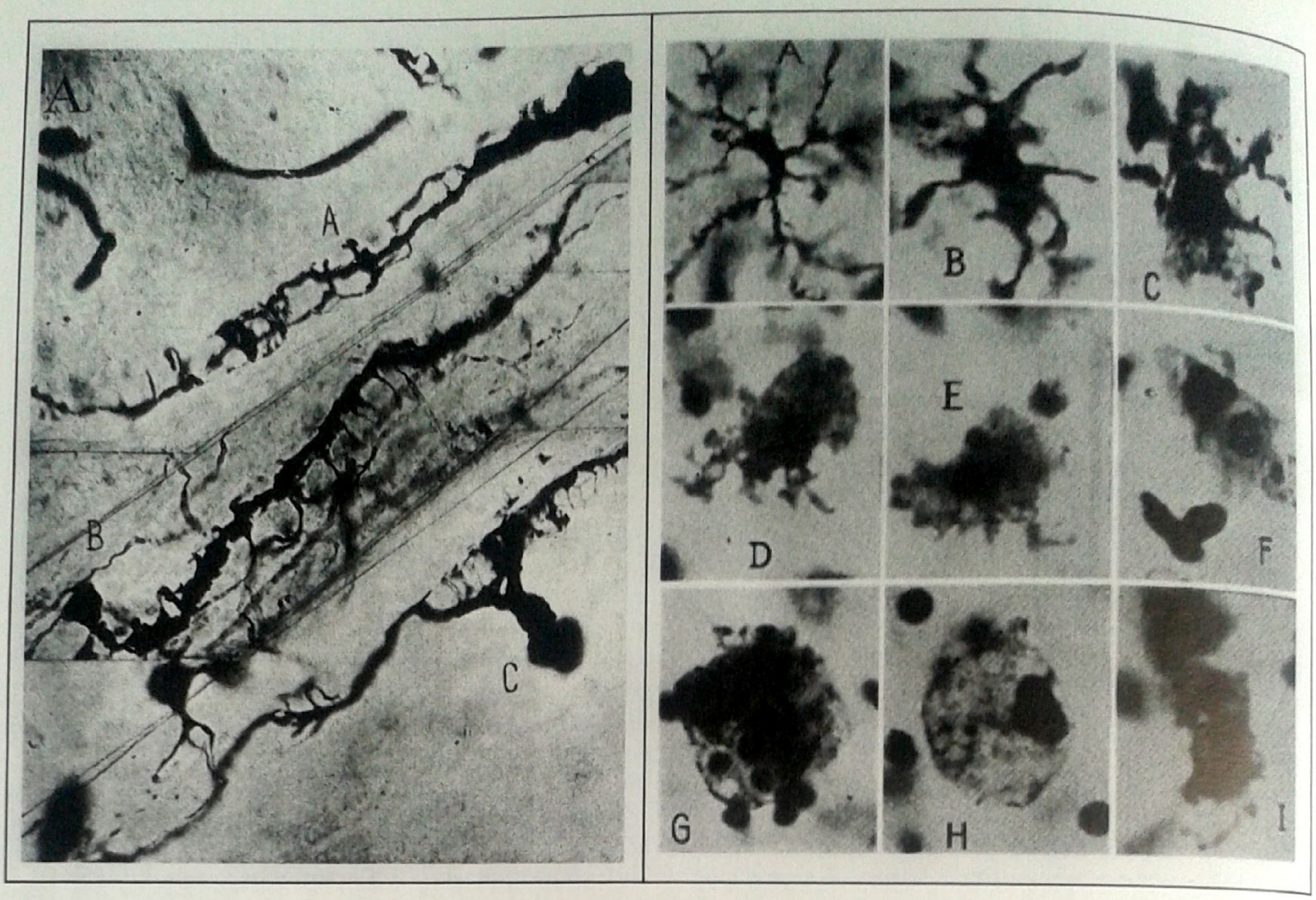

FIGURE 1.8 Early photomicrographs of oligodendrocytes and microglia. *Left panel*: interfascicular oligodendrocytes form a sheath about the myelin segments. *Right panels, A–I.* Evolution of microglial cells during phagocytic activity. *A.* Cell with thick, rough processes; *B.* cells with short processes and an enlarged cell body; *C.* hypertrophic cell with pseudopodia; *E.* ameboid form; *F.* cell with phagocytosed leukocyte; *G.* cell with numerous phagocytosed red cells; *H.* fat granule cell: *I.* cell in mitotic divisions. Left panel from Rio-Hortega (1928). *A-I* from Rio-Hortega (1932).

croglial cell as follows: "Since it is of different ancestry and its characteristics differ from those of the nerve cells (first element) and the neuroglial astrocytes (second element*), the microglia constitutes the *true* third element of the central nervous system" (Rio-Hortega, 1932). He acknowledged that microglia were the same cells, or closely related cells, as seen earlier by pathologists such as Nissl (1899; i.e., rod cells). In fact, Nissl and Alzheimer had argued that the glial cells seen under pathological conditions were of mesodermal origin.

Rio-Hortega's accomplishments in rigorously defining the final two members of the CNS glial family and in deducing their functions are impressive. Unfortunately, he is rarely accorded the credit he deserves for these accomplishments. He was the first to describe the two types of microglia: ameboid and ramified. He recognized that the ameboid form was mobile and phago-

*Rio-Hortega considered the oligodendroglia to be a member of the macroglial or classical neuroglial family.

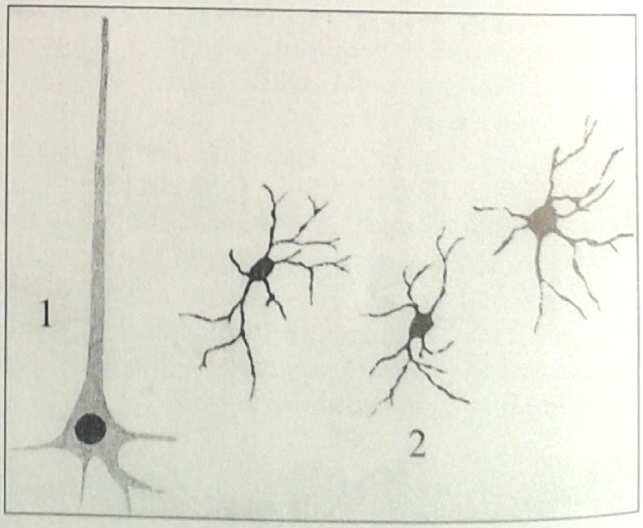

FIGURE 1.9. Illustration of cells stained with the platinum method of Robertson. Composite diagram showing (*1*) "large pyramidal nerve cell of cerebral cortex of sheep" and (*2*) "Three branching cells in cerebral cortex of dog." The cells labeled *2* were either microglia or oligodendrocytes. (From Robertson, (1899.)

Scanned by CamScanner

cytic and was similar to a blood macrophage. In fact, he believed, as is believed today, that microglial cells originate from peripheral macrophages. He understood that the microglial cell can transform from its relatively inactive ramified form into the phagocytic ameboid form in response to a threat like infection. "In historical perspective we see that what Cajal is to the neuron, Rio-Hortega is to the neuroglia" (Jacobsen, 1993).

GLIAL CELLS RESPOND TO PATHOLOGY

Paralleling the development of knowledge about normal glial cells was the growing recognition that these same cells can alter their appearance in pathological states. In studying brains from deceased multiple sclerosis patients, Carl Frommann (1831–1892) noted that glial cells underwent changes in the demyelinated plaques (Frommann, 1864). He believed that the cells in the areas of fiber degeneration were glial cells that had undergone morphological changes. He stated that the cells became larger and had fewer processes compared to normal glia. It was also clear to him that glial cells were still present in the degenerated areas despite the fiber loss (Fig. 1.10*A*,*B*). He also claimed that some of the glial cells lacked a nucleus. In retrospect, it is likely that he observed activated microglia in these areas of fiber degeneration.

Franz Nissl (1860–1919) noted two new cell types that appeared in the pathological brain. One form was elongated and bipolar in shape, and he called such cells *Stäbchenzellen* (rod cells) (Fig. 1.10*D*). He described this cell type in brains of demented patients but found them also in animals. He originally described these cells as glial elements (Nissl, 1899) but later considered the possibility that they were of mesodermal origin (Nissl, 1904). A second cell type was found mainly in pathological tissue associated with disruption of the blood–brain barrier. These cells were round, without processes, and he termed them *Körnerzellen* (granule cells) or *Gitterzellen* (lattice cells) (Fig. 1.10*E*). Nissl speculated that they were infiltrating blood cells.

In 1910, Alois Alzheimer (1864–1915) published a book chapter summarizing the responses of neuroglia to different pathologies. It was clear to him and his contemporaries that any type of pathology is accompanied by a glial response. He described ameboid glial cells, or ameboid change, in response to both acute and

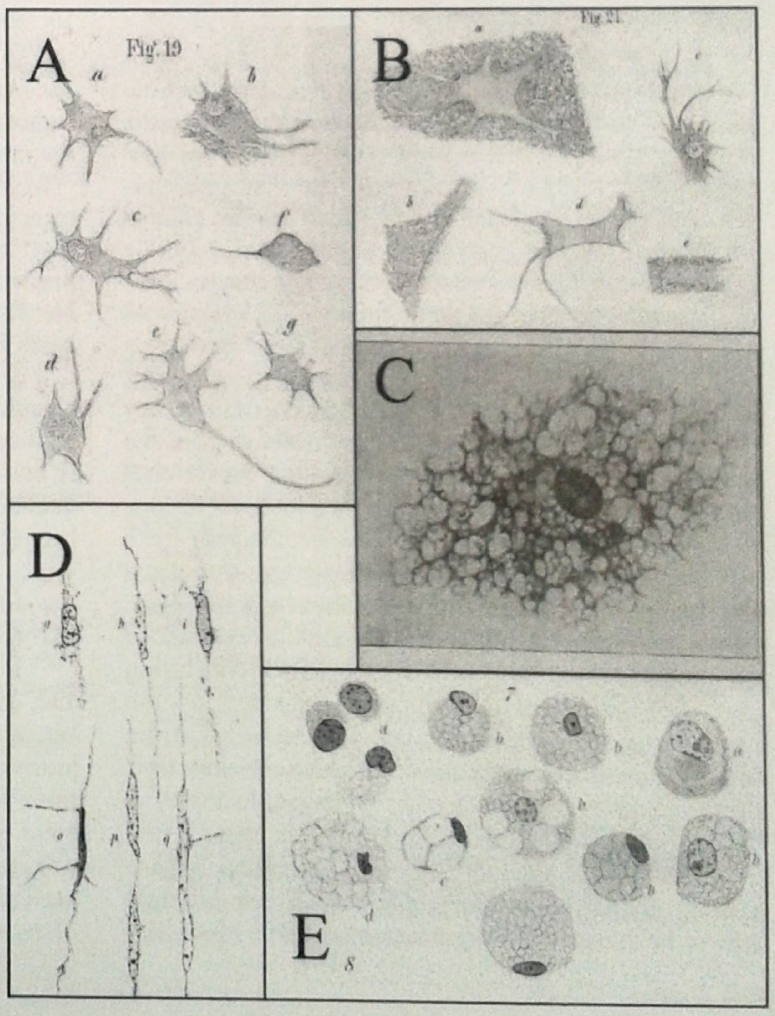

FIGURE 1.10 Neuroglial cells in pathological situations. *A*,*B*. Different types of glial cells found in multiple sclerosis plaques of human cortex. *C*. Glial cell close to a 14-day-old hemorrhage in human white matter. Axons pass through the network of the cell. *D*. Rod cells stained with toluidin blue. *E*. Gitter cells stained with toluidin blue. *A* and *B* from Frommann (1878). *C* from Alzheimer (1910). *D* and *E* from Alzheimer (1904).

Scanned by CamScanner

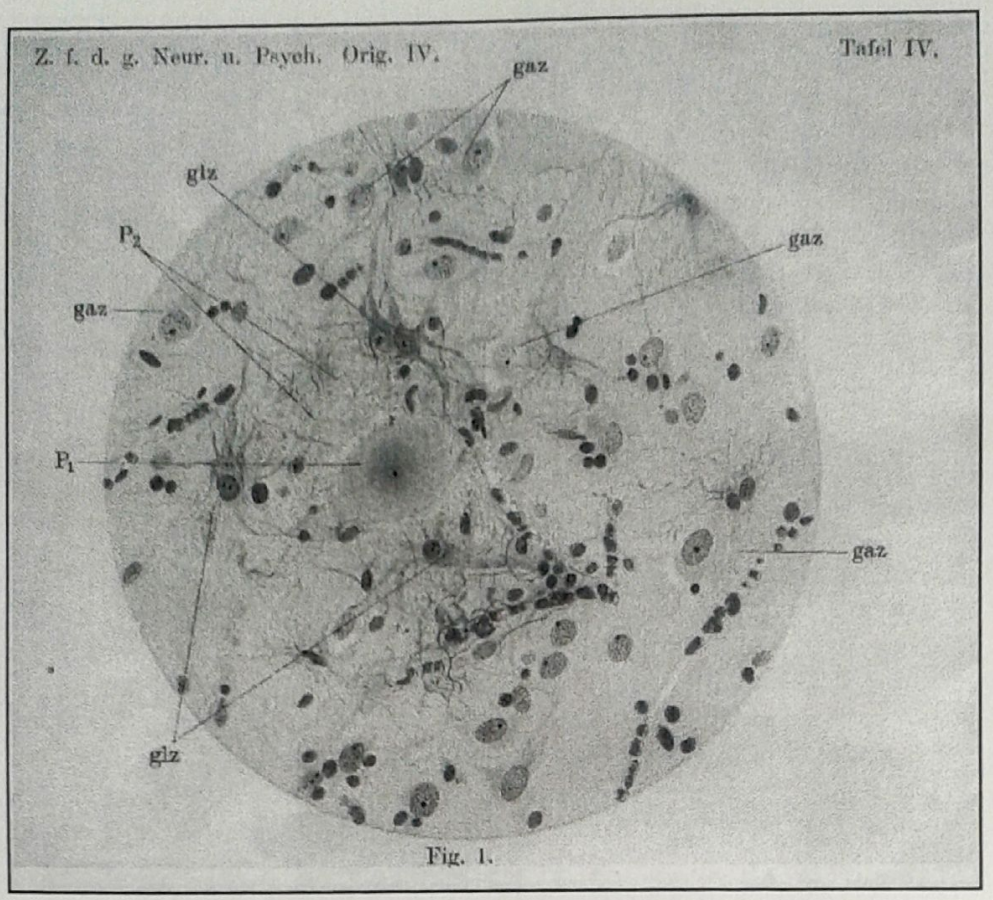

FIGURE 1.11 Relationship between (Alzheimer) plaque and glial cells; *gaz*: neuron; *glz*: glial cell; P_1: central part of the plaque; P_2: peripheral part of the plaque. (From Alzheimer, 1911.)

chronic diseases of the nervous system. The ameboid glial cell was believed to be a transformed astrocyte (swollen, with granular cytoplasm and fragmented processes) (Fig. 1.10C). Unfortunately, these cells were often, and easily, confused with Gitterzellen, as alluded to above. Alzheimer's discussion about these cells is a good example of how static microscopic images were used to draw conclusions about function. "The ameboid glial cells do not share the task of glia to provide structural support. They do not form fibers and networks, but they appear at areas of neuronal degeneration. They develop probably in response to a stimulus from the degradation products. Since we did not observe that they take up neuronal structures, we have to assume that they help to liquefy them. This we conclude from our observations on ganglion cells. Over time they grow in size and replace the ganglion cells which will completely disappear and they can be found everywhere in the (degenerating) tissue. This leads to the conclusion that they assimilate the products generated by the degradation of the ganglion cell and neuronal structures. After reaching the peak of their development, they undergo regressive changes while producing various granula and deteriorate rapidly. Their degradation products move to the lymphatic and perivascular space as fluid phase and are there taken up by mesodermal cells to be converted to lipoid matter. Thus, they clean the nervous tissue from waste, transform it to a substance harmless to ectodermal tissue and deliver it to the mesodermal tissue" (Alzheimer, 1910).

In addition to relating the occurrence of ameboid glia to neuronal degeneration, as in the case of acute postmortem change, Alzheimer realized that they could be present in chronic diseases such as epilepsy and syphilis. He also confirmed their presence in the disease that bears his name. His histopathological analysis of the first dementia patient illustrated activated glial cells surrounding the plaques (Fig. 1.11). His insights promoted glial cells to the status of important cellular elements in brain pathology. It was, however, Rio-Hortega who defined these pathological cell types and distinguished between astrocytes and microglia.

CONCLUSIONS

The early historical path to understanding neuroglia was circuitous. Penfield's general comment about the journey is telling: "Knowledge of the form and function of neuroglia is the result of progressive improvement in histological technique in the hands of careful workers. . . . Insight into the principles involved has been made difficult by numerous uncritical publications of men who, although doubtless sincere, are oppor-

Scanned by CamScanner

tunists rather than cytologists" (Penfield, 1932). The essence of his sentiments continues to be valid today.

The history of discoveries about neuroglia highlights a major obstacle to rapid scientific progress. Scientists become so attached to their theories that contradictory evidence fails to modify their viewpoint. When conflicting data appear, new arguments are concocted to preserve the attacked notion. When evidence emerged that myelin was formed by cells, and not by axons, these contrary findings failed to convince the faithful committed to the older idea. It is provocative to ask ourselves what evidence would be necessary for us to abandon our own pet theories. Historians of our own era will, undoubtedly, have many examples to choose from to illustrate this point.

REFERENCES

Alzheimer, A. (1904) Histologische Studien zur Differenzial diagnose der progressiven Paralyse. In: Nissl, F., ed. *Histologische unsd histopathologische Arbeiten über die Grosshirnrinde mit besonderer Berücksichtigung der pathologischen Anatomie der Geisteskrankheiten*, Vol. 1. Jena: Gustav Fischer, pp. 18–314.

Alzheimer, A. (1910) Beiträge zur Kenntnis der pathologischen Neuroglia und ihrer Beziehungen zu den Abbauvorgängen im Nervengewebe. In: Nissl, F. and Alzheimer, A., eds. *Histologische unsd histopathologische Arbeiten über die Grosshirnrinde mit besonderer Berücksichtigung der pathologischen Anatomie der Geisteskrankheiten*, Vol. 3. Jena: Gustav Fischer, pp. 401–562.

Alzheimer, A. (1911) Über eigenartige Krankheitsfälle des späten Alters. *Z Neurol Psychiatrie* 4:356–385.

Andriezen, W.L. (1893) The neuroglia elements of the brain, *Br. Med. J.* 2:227–230.

Bergmann, K. (1857) Notiz über einige Strukturverhältnisse des Cerebellums und Rückenmarks. *Z. Med.* 8:360–363.

Butt, A.M. and Ransom, B.R. (1993) Morphology of astrocytes and oligodendrocytes during development in the intact optic nerve. *J. Comp. Neurol.* 338:141–158.

Cajal, S. Ramony (1995) *Histology of the Nervous System*. N. Swanson and L. Swanson, trans. New York: Oxford University Press.

Cajal, S. Ramon y (1909–1911) *Histologie de Systeme Nerveux de l'Homme et des Vertebres*. 2 vol. L. Azouloy, Trans. Paris: Maloine.

Cajal, S. Ramon y (1913) Contribucion al conocimiento de la neuroglia del cerebro humano. *Trab. Lab. Invest. Biol.* 11:255–315.

Deiters, O. (1865) *Untersuchungen über Gehirn und Rückenmark des Menschen und der Säugethiere*. Braunschweig: Vieweg.

Ferguson, J.S. (1905) *Normal Histology and Microscopical Anatomy*. New York: Appleton.

Frommann, C. (1864, 1877) *Untersuchung über die normale und pathologische Anatomie des Rückenmarks Teil I, II*. Jena.

Frommann, C. (1878) *Untersuchungen über die Gewebsveränderungen bei der Multiplen Sklerose des Gehirns*. Jena: Gustav Fischer.

Garrison, F.H. (1929) *History of Medicine*, 4th ed. Philadelphia: Saunders.

Glees, P. (1955) *Neuroglia Morphology and Function*. Oxford: Blackwell.

Golgi, C. (1871) Contribuzione alla fina Anatomia degli organi centrali del sistema nervosos. Bologna: Rivista clinica di Bologna

Golgi, C. (1894) *Untersuchungen über den feineren Bau des centralen und peripherischen Nervensystems*. Jena: Gustav Fischer.

Held, H. (1903) *Über den Bau der Neuroglia und über die Wand der Lymphgefässe in Haut und Schleimhaut*. Leipzig: Teubner.

Henle, J. and F. Merkel (1869) Ueber die sogenannte Bindesubstanz der Centralorgane des Nervensystems. Z. Med. 34:49–82.

His, W. (1889) Die Neuroblasten und deren Entstehung im embryonalen Mark. *Arch. Anat. Physiol.* 5:249–300.

Jacobson, M. (1993) *Foundations of Neuroscience*. New York: Plenum Press.

Kölliker, A. (1852) *Zur Anatomie und Physiologie der Retina, Verh. Physikal.-Med. Ges. Würzburg* 3:316–336.

Kölliker, A. (1889) *Handbuch der Gewebelehre des Menschen*. Leipzig: Wilhelm Engelmann.

Kuffler, S.W. and Nicholls, J.G. (1966). The physiology of neuroglial cells. *Ergeb. Physiol.* 57:1–90.

Lenhossék, M. von (1893) *Der feinere Bau des Nervensystems im Lichte neuester Forschung*. Berlin: Fischer's Medicinische Buchhandlung H. Kornfield.

Müller, H. (1856) Observations sur la structure de la rétine de certains animaux. Comptes Rendus de l'Académie der Sciences de Paris. 43:743–745.

Müller, H. (1851) Zur Histologie der Netzhaut, *Z. Wissenschaft. Zool.* 3:234–237.

Nedergaard, M., Ransom, B.R., Goldman, S.A. (2003) New roles for astrocytes: redefining the functional architecture of the brain. *TINS.* 26:523–530.

Nissl., F. (1899) Ueber einige Beziehungen zur Nervenzellenerkrankungen und gliosen Erscheinungen bei verschiedene Psychosen. *Arch. Psychiatrie.* 32:656–676.

Nissl, F. (1904) Die Histopathologie der paralytischen Rindenerkrankung. In: Nissl, F., ed. *Histologische unsd histopathologische Arbeiten über die Grosshirnrinde mit besonderer Berücksichtigung der pathologischen Anatomie der Geisteskrankheiten*, Vol. 1. Jena: Gustav Fischer, pp. 315–494.

Penfield, W. (1932) Neuroglia, normal and pathological. In: *Cytology and Cellular Pathology of the Nervous System*, Vol. 2. (W. Penfield, ed.) New York: Hafner, pp. 421–479.

Rand, C.W. (1953) The role of the astrocyte in the formation of cerebral scars with an introduction to Cajal's contribution to our knowledge of neuroglia. *Bull. Los Angeles Neurol. Soc.* 17:57–70.

Ransom, B., Goldman, S.A., and Nedergaard, M. (2003) New roles for astrocytes (stars at last). *TINS* 26:520–522.

Ranvier, L.-A. (1872) Recherche sur l'histologie et la physiologie des nerfs. *Arch. Physiol. Norm. Pathol.* 4:129–149.

Ranvier, L.A. (1875) Traité technique d'histologie, Figure from the German translation: *Technisches Lehrbuch der Histologie*. Leipzig: Vogel (published 1888).

Ranvier, L.-A. (1883) De la néuroglie. *Arch. de Physiol.* 3:177–185.

Remak, R. (1838) Observationes anatomicae et microscopicae de systematis nervosi structura, Dissertation, University of Berlin.

Retzius, G. (1893) Studien über Ependym und Neuroglia. *Biol. Untersuch.* 5:2–26.

Rieder, R. (1906) *Carl Weigert und seine Bedeutung fur die medizinische Wissenschaft unserer Zeit*. Berlin: Springer.

Rio-Hortega, P. del (1919) El tercer elemento de los centros nerviosos. *Bol. Soc. Esp. Biol.* 9:69–120.

Rio-Hortega, P. del (1921) Estudios sobre la neuroglia. La glia de escasas radiaciones oligodendroglia. *Bol. Soc. Esp. Biol.* 21:64–92.

Rio-Hortega, P. del (1928) Tercera aportacion al conocimiento morfologico e interpretacion functional de la oligodendroglia. *Mem. Real Soc. Esp. Hist. Nat.* 14:5–122.

Rio-Hortega, P. del (1932) Microglia. In: *Cytology and Cellular Pathology of the Nervous System*, Vol. II. (W. Penfield, ed.) New York: Hafner, pp. 483–534.

Robertson, W.F. (1897) The normal histology and pathology of the neuroglia. *J. Ment. Sci.* 43:733–752.

Scanned by CamScanner

Robertson, W.F. (1899) On a new method of obtaining a black reaction in certain minute elements of the central nervous system (platinum method). *Scot. Med. Surg. J.* 4:23.

Robertson, W.F. (1900) A macroscopic demonstration of the normal and pathological histology of microglial cells. *J. Ment. Sci.* 46:733–752.

Schultze, M. (1859) Observationes de retinae structura penitiori. Published lecture at the University of Bonn.

Schwann, T. (1839) *Mikroskopische Untersuchungen über die Übereinstimmung in der Struktur und dem Wachstum der Tiere und Pflanzen.* Berlin: Sandes.

Somjen, G. (1988) Neuroglia: Notes on the history of the concept of glia. *Glia* 1:2–9.

Stricker, S. (1871) *Handbuch der Lehre von den Geweben der Menschen und der Thiere.* Leipzig: Wilhelm Engelmann.

Virchow, R. (1978) *Cellular Pathology.* 2nd ed. Chance, F., trans. Birmingham, AL: Gryphon Editors.

Virchow, R. (1846) Über das granulierte ansehen der Wandungen der Gehirnventrikel. *Allg. Z. Psychiatr.* 3:242–250.

Virchow, R. (1856) Gesammelte Abhandlungen zur wissenschaftlichen Medizin. Frankfurt: Verlag von Meidinger Sohn & Comp.

Virchow, R. (1858) Die Cellularpathologie in ihrer Begründung auf physiologische und pathologische Gewebelehre. Berlin: Verlag von August Hirschwald.

Weigert, K. (1895) *Beiträge zur Kenntnis der normalen menschlichen Neuroglia.* Frankfurt: Diesterweg.

Scanned by CamScanner