Retinal Disease Classification Using a Multi-Stage Deep Learning Model on OCT C8 Dataset with Grad-CAM Support

T. G. Ramnadh Babu, Bathula Timothi, Kannekanti Teja Vardhana Chari, Kurra Vamsi Krishna, Sireesha Moturi
Department of CSE, Narasaraopeta Engineering College, Narasaraopet, Andhra Pradesh, India
Emails: baburamnadh@gmail.com, btt6303273@gmail.com, tejavardhanachari99@gmail.com,
kurravamsikrishna555@gmail.com, sireeshamoturi@gmail.com
Y. Sri Lalitha
Department of CSE, GRIET, Bachupally, Hyderabad, Telangana, India
Email: lalitha_ysl@griet.ac.in
Y. Sravani Devi
Department of CSE, GNITS, Shaikpet, Hyderabad, Telangana, India
Email: y.sravanidevi@gnits.ac.in

***Abstract*—Early diagnosis of retinal-related disorders is paramount in ensuring from causing significant vision loss, especially where access is limited specialist medical treatment. The following study offers a short, multi-step procedure. Convolutional model assisting in the identification of different disorders of the retina on the Retinal OCT C8 dataset. This includes eight prominent categories that are widely employed by physicians in real scenarios. The model consists of a sequence of convolutional layers with special modules which assist in recognizing fine textures as well as large ones. These modules consist of different filters which are signs for potential retinal problems. The data set was were thoroughly cleaned and divided, and the model was trained only on these samples to ensure the results are reliable in a given real medical setting. On the test section of the data, The accuracy achieved by the model was 95.07%, with precision, recall, and F1-score all tend to be very close to each other, which is better than models such as it. The model has been designed to be lightweight, so that it A model such as it can perform well even on system with low computing capabilities. To in order to make the model more trustworthy, it also includes visual tools those that emphasize what aspects of the retina were most significant in arriving at a diagnosis, assisting physicians in employing it effectively in their practice.**

***Index Terms*—Clinical diagnosis, convolutional neural networks, deep learning, eye disease detection, medical image classification, OCT imaging, retinal OCT.**

I. Introduction

Conditions like Age-related Macular Degeneration (AMD), Diabetic Retinopathy (DR), Diabetic Macular Edema (DME), and Drusen continue to remain key causes of vision impairment world-wide [1]. In fact, early diagnosis is crucial since early treatment is known to dramatically reduce the risk of sustaining irreparable damage to the retinal tissue [2]. Today, OCT has become a principal resource in retinal imaging based on the capacity of this technology to offer cross-sectional images of high resolution [3].

Despite its importance for diagnosis, the analysis of these scans is time-consuming, with potential variability between observers, especially when processing relatively large volumes of scans [4]. Deep learning algorithms, particularly Convolutional Neural Networks (CNNs), have demonstrated their potential in the task of classifying scans in oct scans [5]. Recent studies propose the utilization of multiscale analysis with attention methods to detect subtle changes in the retina [6], although the problem with many current approaches is their computational intensity, posing them as inefficient tools for practical applications in a clinical environment [7].

Gradient-Weighted Class Activation Mapping (Grad-CAM) can be utilized for the explanation of deep neural network predictions and has been shown to improve trust [8]. Although the precision of methods such as ensembling and transformers can be increased, there might be constraints for their utilization in real-time applications due to increased inference times [9]. Data augmentation techniques have emerged as critical components for enhancing robustness, particularly when dealing with a reduced dataset in the medical field [12], and recent literature reviews emphasize the importance of efficient explanation in OCT-related classifiers [13].

In this study, the application of an efficient multi-stage CNN is proposed for trading-off accuracy, computational complexity, as well as interpretability. The proposed solution is targeted towards three important requirements. These requirements include the identification of fine-grained as well as high-level details of retinal images. Additionally, the method is expected to provide explanations while being computationally efficient. The application is targeted towards medical settings.

II. Related Work

Deep learning has seen numerous applications in the diagnosis of retinal diseases automatically through OCT im-

979-8-3315-4970-1/26/$31.00 ©2026 IEEE

ages. Some of the earliest examples of its use include the demonstrations of the application of AI in the medical field for expert levels of performance by De Fauw et al. [1], as well as the accomplishment of a baseline in the field of OCT image classification by Kermany et al. with the use of large datasets for transfer learning [2]. Esteva et al. also stressed the need for diagnostic accuracy, interpretability, and the degree ofclinical integration in medical AI models

Further research concentrated on enhancing the representation of features using multiscale CNNs [4], attention-based models [5], and residual learning models [6]. Models with multi-level CNNs have demonstrated enhanced generalization capabilities for a variety of OCT data sources, especially with established standards such as Retinal OCT C8 [7], [8]. Interpretability tools such as Grad-CAM have been researched and applied in a variety of applications for improving medical credence with region-of-interest-focused explanations [9].

Current work includes the use of ensemble learning, segmentation assistance, and light-weight CNN techniques [10]–[15] for enhancing robustness and deployability. Though more complex models like multiscale, attention-based, and transformer-powered models perform well on the accuracy front, they are computationally expensive. Nevertheless, light-weight CNNs are more frugal and efficient but might not capture the finest details like retinas because of the lack of depth associated with a light-weight architecture. This reveals an existing gap for a model that is both light and interpretable.

III. Methodology

The proposed solution recommends a lightweight two-stage CNN with residual blocks for automatic classification of retinal diseases from OCT images. The proposed solution consists of four main steps: preprocessing of images, augmentation of data for increased volume, feature extraction through a two-stage CNN, and explanation of results through Grad-CAM.

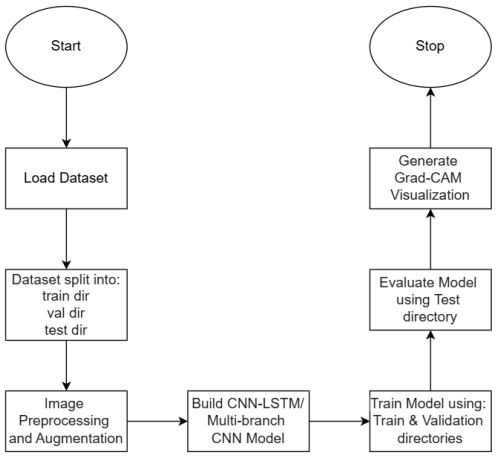

Fig. 1. Cumulative processing pipeline for the proposed OCT system for retinal disease classification system.

As illustrated in Fig. 1, the process begins by collecting publicly available datasets of OCT images. These datasets are then transformed to have a standardized spatial resolution to ensure that images of all sizes will conform to a standard size. Some minor preprocessing of the images has been implemented to crop the images, removing areas that do not contain crucial information, to better expose the layers of the retina in the images. Methods such as image flipping, rotation, and contrast adjustment are implemented to prevent the model from relying on particular images too heavily.

The proposed CNN model consists of a multi-step approach. It is intended for the detection of simple textures as well as complex patterns within diseased retinal images. In the initial phases of detection, the network begins with simple feature extractions such as edges and layers. In the advanced phase of detection, the algorithm relies on a unique module known as the residual correlation module to analyze complex patterns found within the retinal images. The extracted features are then passed through a fully connected classifier to make a prediction. For better insight into how the model is making its final decisions, Grad-CAM is applied to the last convolutional layers. This emphasizes the regions in the image that have the most weight in determining the prediction in the model's output, which assists in analyzing and interpreting the results in relation to medical scenarios.

A. Dataset Description

The Retinal OCT C8 dataset has been released by gathering clinical OCT images from different ophthalmology centers. Before making it public, all the images were made anonymous. The dataset includes 21,200 grayscale images, spread equally across eight diagnostic categories, with 2,650 images in each category. It serves as a fair and relevant benchmark for evaluating the performance of models accurately.

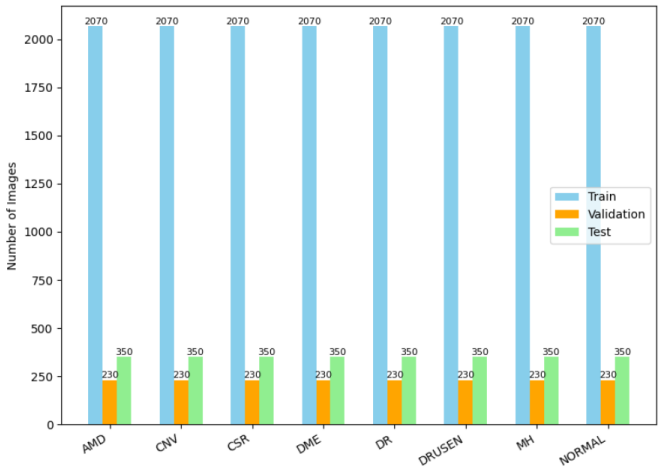

Fig. 2. Distribution of the eight retinal disease categories in the OCT C8 dataset.

As shown in Fig. 2, each category is divided into 2,070 training images, 230 validation images, and 350 test images. The dataset covers the following classes:

- Age-related Macular Degeneration (AMD)
- Choroidal Neovascularization (CNV)
- Central Serous Retinopathy (CSR)
- Diabetic Macular Edema (DME)
- Diabetic Retinopathy (DR)
- Drusen
- Macular Hole (MH)
- Normal (Healthy Retina)

B. Image Preprocessing and Augmentation

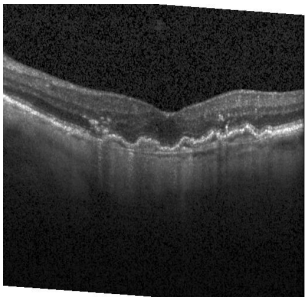

Fig. 3. Example OCT scan before preprocessing.

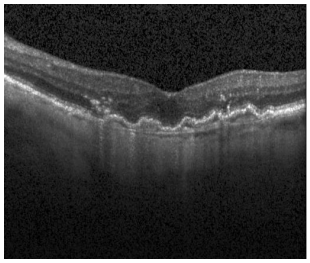

Fig. 4. OCT scan after preprocessing and augmentation.

Figures 3 and 4 give a representation of the preprocessing that takes place to the OCT images. These raw images are likely to suffer from brightness, shadow, and speckle patterns created during the clinical imaging process. To guarantee the input images are of equal quality, all images are resized to 224×224 pixels and are rescaled to values between $[0, 1]$, ensuring that all input intensities are equally scaled to the neural network architecture. The image resampling also filters out the unwanted high frequency noise, without diminishing the relevant information found in the drusen deposits and the retinal layers.

During the training phase, the controlled augmentation techniques horizontal flip, small-angle rotations, and zoom variations are added to simulate natural variations in patient positioning as well as device positioning. In addition, the training data are periodically assessed as validation data to verify the stability of training as a function of early signs of overfitting.

C. Model Architecture

This proposed architecture will be able to efficiently achieve both the local details and the global features present within the OCT scans. This is because the OCT scans performed will allow the observation of the layered structure of the retina, while the lesions will also be present at levels that are depicted as a series of textures. The early signs of a potential problem will require the ability to achieve the global features.

The conventional CNN architectures based on a branch normally capture either fine detail textures or global structural information, sometimes failing to capture subtle early changes of the retina. In this regard, the proposed architecture employs a dual-branch concept that enables the image to be processed through two different branches at the same time. In this way, it becomes possible for the system to analyze both the minute textures as well as the bigger spatial patterns of the image without adding complexity to the system. In this way, the system becomes more capable of classifying retinal diseases correctly.

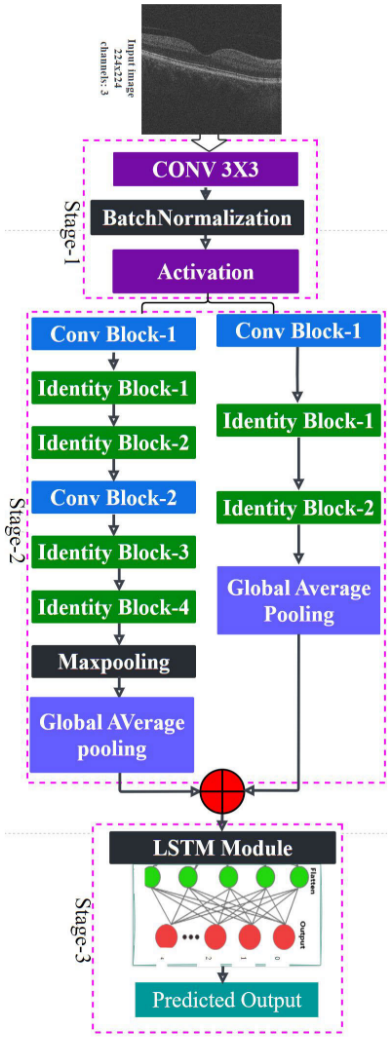

Fig. 5. Dual-Branch CNN Architecture with Residual Links for OCT Classification.

As depicted in Fig. 5, the architecture uses two convolutional branches. One emphasizes local textural information, which is related to irregularities in retinal layers, while the other is used for general structural information, which is relevant for disease detection. This architecture enables incorporating both detailed pathologies and global retinal structural information in a very efficient, minimal system. Within these two branches, residual learning assists in ensuring that the flow of gradients is not disrupted and also prevents overfitting during training. This approach also enables incorporating learned feature reuse, ensuring efficient performance regardless of scan quality and anatomies. This architecture is far more efficient

compared to transformer or ensemble architectures since it is able to capture details at multiple levels yet is computationally inexpensive. The output from both convolutional branches is then put through global average pooling and fully connected layers for generating final output. This simplistic approach ensures low computational expense, making it apt for real-time applications at clinical setups.

D. Experimental Setup

The experiment took place solely on the OCT C8 dataset with the training, development, and test data split already provided. The source code is written in Python version 3.8 or later and using the library PyTorch version 1.10 or later and is meant to be run with a single NVIDIA GPU.

Training was performed using cross entropy loss along with the Adam optimizer, starting with an initial learning rate of 1×10^{-4}, a weight decay of 1×10^{-5}, and a batch size of 32. The model was trained for 30 epochs, and a learning rate scheduler along with early stopping were implemented. Data augmentation was only applied to the training set, while the validation and test sets were resized and normalized.

The model that achieved the highest validation F1-score was chosen for final evaluation. The same fixed random seed was used across all libraries. Then, the model's inference speed and size were measured to evaluate its performance in resource-constrained environments.

E. Evaluation Metrics

The accuracy, precision, recall, and F1-score were used to test the models on the test set because it is important in medical image classification to classify images correctly with accurate precision. The confusion matrix is used to analyze the predictions made by the models since it may be possible that the models classify two classes with very similar characteristics in retinal images incorrectly.

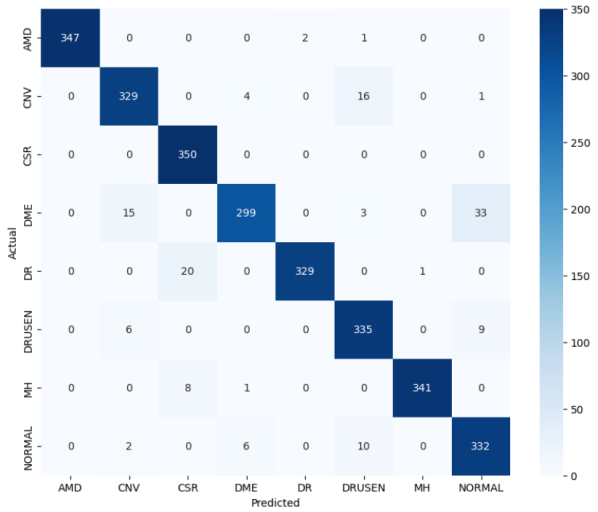

Fig. 6. Confusion matrix of model predictions on the test set.

From the above figure 6, it is clear that most of the results lie on the diagonal, thereby identifying the eight diseases correctly. Also, the low values on the other diagonal indicate that there is little confusion between the diseases that look alike on the retinas.

IV. Results and Discussion

The proposed model is evaluated using the test set of the OCT C8 dataset. The accuracy of classification is satisfactory since Precision, Recall, and F1 measurements are relatively equal for all eight categories. The classification of the model is correct for samples of CNV, DME, Drusen, and Normal. The Confusion Matrix includes accurate classifications along the diagonal; hence, there is no classification of similar structural patterns of categories amongst them.

Generally, the classifier performs well on distinguishing the classes from each other, in addition to employing less computational power than other models.

The Grad-CAM technique was utilized to determine whether the model was concentrating on critical areas of the retina to provide a diagnosis. Activation maps pointed out regions corresponding to known disease manifestations such as cysts, boundary irregularities, and drusen deposition. Such correspondences between predictions and already known manifestations indicate that they are reliable and interpretable.

A. Model Accuracy and Training Performance

TABLE I
Performance of the proposed model on the OCT C8 test set.

Metric	Value
Test Accuracy	95.07%
Precision	95.24%
Recall	95.07%
F1 Score	95.06%

As can be seen in Table I, the accuracy of the model on the test set was 95.07%. The values of precision, recall, and F1 measure are very close to each other, and this clearly identifies that the model is performing equally well on all types of cases of retinal disorders. It is quite essential in medical testing to be able to detect all cases of various disorders.

TABLE II
Comparison of the proposed model with standard baseline architectures on the OCT C8 test set.

Model	Accuracy	Precision	Recall	F1-score
Simple CNN	88.40%	87.90%	87.60%	87.70%
MobileNetV2	90.80%	90.40%	90.10%	90.20%
ResNet-18	93.20%	92.70%	92.50%	92.60%
Proposed Model	**95.07%**	**95.24%**	**95.07%**	**95.06%**

As highlighted in Table II, our dual-branch model performs better compared to popular models such as Simple CNN, MobileNetV2, and ResNet-18. This enhancement proves the effectiveness of combining dual-branch feature extraction with residual learning. This increases the capacity of the network to correctly classify while minimizing the hardware and power constraints even with a lightweight design.

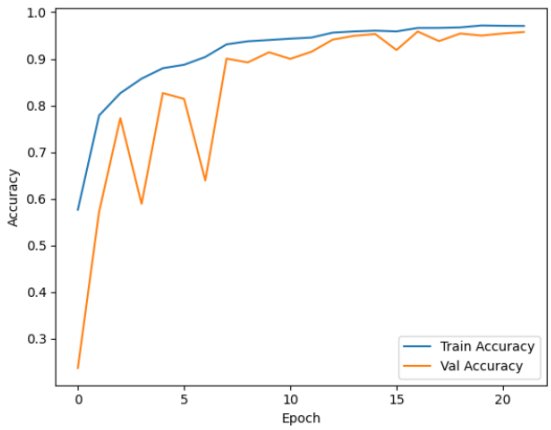

Fig. 7. Training and validation accuracy over 20 epochs.

Figure 7 shows how accuracy changes during training. Both the training and validation curves rise gradually and follow a very similar pattern throughout all 20 epochs. This suggests that the model is converging steadily without major overfitting. The smooth difference between the two curves also shows that the model generalizes well to new data, thanks to the learning rate setup and the regularization techniques used. This outcome reinforces the effectiveness of the proposed architecture for classifying multiple types of retinal diseases.

B. Training Loss Behavior

Training and validation loss curves were examined to assess convergence and to identify any signs of overfitting or instability.

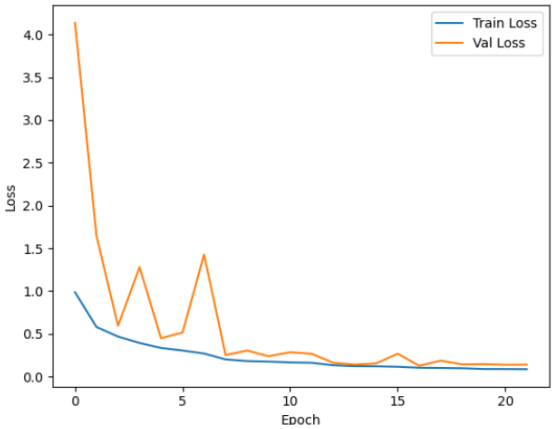

Fig. 8. Training and validation loss over 20 epochs.

As shown in Fig. 8, the loss values for both the training and validation datasets keep decreasing and stay similar throughout. The close match between the training and validation loss values shows that the model is generalizing well and the training is proceeding smoothly. The use of a learning rate scheduler and early stopping helped avoid overfitting and made sure the training stopped exactly when the artificial neural network reached its best performance. The steady decrease in loss over the epochs also confirms that the two-branch structure does not add extra instability to the training process.

C. Grad-CAM Visualizations for Interpretability

Interpretability is very important in medical image analysis because the model's predictions need to be linked to specific parts of the image that have clinical significance. To understand how the model makes its decisions, Grad-CAM visualizations were used to show which areas of the retina had the most influence on the classification results.

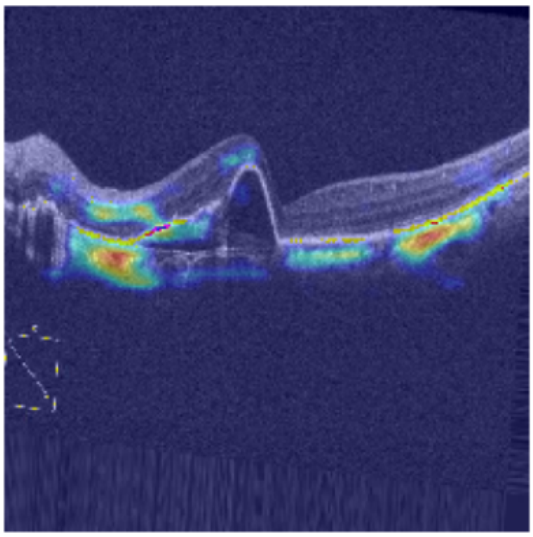

Fig. 9. Grad-CAM heatmaps indicating regions influencing model predictions.

As shown in Figure 9, the highlighted areas match structures in the retina that doctors look at during diagnosis, such as fluid buildup, layer disruptions, and drusen deposits. These are the kinds of features that ophthalmologists focus on when assessing eye conditions, which means the model is paying attention to the right parts and not just random background details. This connection to standard medical practices supports the model's reliability and real-world usefulness.

Although Grad-CAM offers useful insights into how the model works, the interpretability could be improved with more quantitative checks. In future work, we could compare the highlighted regions with areas marked by experts to see how well they match. This would allow for a more detailed comparison with other methods used to explain model decisions.

D. Overall Evaluation

Looking at the results, the proposed model appears to work equally well on all types of retinal disease studies. It maintains consistent performance during the whole training process. In addition, using Grad-CAM displays which parts of the retinal images the model pays attention to while making predictions. According to these results, we can conclude that since the model has been performing similarly among all categories, it stands out to be quite useful for those situations where classification tasks are needed. articulation class over others,

for the reason that they are rather alike. This is particularly important in health screening applications, where a model Missing a certain class may fail to diagnose a condition.

V. Conclusion and Future Work

The paper proposed an efficient dual-branch convolutional neural network for OCT images that can classify retinal disease.

By employing parallel paths for feature extraction, incorporating the aspect of residual learning, and including interpretability, the approach is able to learn both fine details and global retinal morphology well. The implementation of Grad-CAM also enables visualization of the prediction process, which is essential for establishing trust in AI-driven diagnosis tools. Compared with other approaches, it balances well the three aspects of accuracy, efficiency, and interpretability.

Future Work: There are a few key areas in which one could explore to better optimize the framework. Blending OCT images with data from other sources such as fundus photographs or medical texts may allow better accuracy of diagnosis. OCT scans analysis on different time periods may shed some light on the progression of various diseases. Optimizing the model to better support mobile and edge computing may facilitate large-scale screening of patients in an area that lacks plenty of resources. On the other hand, examining self-supervised or contrastive learning approaches may allow leveraging large-scale OCT data lacking labels.

References

[1] A. De Fauw, J. R. Ledsam, B. Romera-Paredes, *et al.*, "Clinically applicable deep learning for diagnosis and referral in retinal disease," *Nature Medicine*, vol. 24, pp. 1342–1350, 2018.

[2] D. Kermany, M. Goldbaum, W. Cai, *et al.*, "Identifying medical diagnoses and treatable diseases by image-based deep learning," *Cell*, vol. 172, no. 5, pp. 1122–1131, 2018.

[3] A. Esteva, A. Robicquet, B. Ramsundar, *et al.*, "A guide to deep learning in healthcare," *Nature Medicine*, vol. 25, pp. 24–29, 2019.

[4] H. Wang, H. Shi, L. Chen, *et al.*, "Multiscale deep neural network for retinal OCT classification," *IEEE Access*, vol. 8, pp. 160563–160574, 2020.

[5] L. Huang, Q. Gan, Y. Lin, *et al.*, "Retinal disease classification via attention-guided deep learning," *Medical Image Analysis*, vol. 73, 2021.

[6] K. He, X. Zhang, S. Ren, and J. Sun, "Deep residual learning for image recognition," in *Proc. IEEE Conf. Comput. Vis. Pattern Recognit. (CVPR)*, 2016, pp. 770–778.

[7] S. Muntaqim, M. Islam, and K. Ahmed, "Multi-stage deep learning for robust retinal disease classification with Grad-CAM visualization," *Computers in Biology and Medicine*, vol. 150, p. 106040, 2022.

[8] Retinal OCT C8 Dataset Repository, "OCT C8 Public Dataset," Online. Available: https://public-octc8-dataset.org. Accessed: Jan. 2025.

[9] R. R. Selvaraju, M. Cogswell, A. Das, *et al.*, "Grad-CAM: Visual explanations from deep networks via gradient-based localization," in *Proc. IEEE Int. Conf. Comput. Vis. (ICCV)*, 2017, pp. 618–626.

[10] D. Burlina, D. E. Freund, N. Joshi, *et al.*, "Automated grading of age-related macular degeneration from color fundus images using deep convolutional neural networks," *JAMA Ophthalmology*, vol. 135, no. 11, pp. 1170–1176, 2017.

[11] C. Fang, Y. Wu, X. Jiang, *et al.*, "Automatic segmentation of OCT retinal layers via deep learning and visual explanation," *IEEE Journal of Biomedical and Health Informatics*, vol. 26, no. 1, pp. 179–189, 2022.

[12] A. Shorten and T. M. Khoshgoftaar, "A survey on image data augmentation for deep learning," *Journal of Big Data*, vol. 6, no. 1, pp. 1–48, 2019.

[13] S. Muchuchuti and S. Viriri, "Retinal disease detection using deep learning techniques: A comprehensive review," *J. Imaging*, vol. 9, no. 4, p. 84, 2023.

[14] M. Elkholy and M. A. Marzouk, "Deep learning-based classification of eye diseases using convolutional neural network for OCT images," *Frontiers in Computer Science*, vol. 6, 2024.

[15] A. P. Sunija, J. P. Subashini, A. A. Sree, and V. S. A., "A lightweight CNN for retinal disease classification from optical coherence tomography images," *Computers in Biology and Medicine*, vol. 130, p. 104210, 2021.

[16] Z. Li, Y. Han, and X. Yang, "Multi-fundus diseases classification using retinal OCT images with Swin Transformer V2," *J. Imaging*, vol. 9, no. 10, p. 203, 2023.

[17] M. Chetoui and M. A. Akhloufi, "Deep retinal diseases detection and explainability using OCT images," in *Proc. Int. Conf. Image Anal. Recognit. (ICIAR)*, 2020, pp. 1–22.

[18] T. Tsuji, Y. Hirose, K. Fujimori, *et al.*, "Classification of optical coherence tomography images using a capsule network," *BMC Ophthalmology*, vol. 20, no. 1, pp. 1–17, 2020.

[19] S. Kaymak and A. Serener, "Automated AMD and DME detection on OCT images using deep learning," in *Proc. IEEE Int. Conf. Intell. Comput. Commun. Process. (ICCP)*, 2018, pp. 265–269.

[20] G. Huang, Z. Liu, L. van der Maaten, and K. Q. Weinberger, "Densely connected convolutional networks," in *Proc. IEEE Conf. Comput. Vis. Pattern Recognit. (CVPR)*, 2017, pp. 4700–4708.