BONES

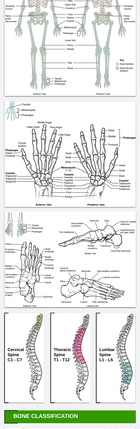
Skull
Mandible
Hyoid bone
Sternum
Ribs
Vertebrae
Sacrum
Coccyx
Clavicle
Scapula
Humerus
Radius
Ulna
Carpals
Metacarpals
Phalanges
Ischium
Pubis
Femur
Patella
Tibia
Fibula
Tarsals
Metatarsals
Phalanges
Anterior view
Posterior view
Cervical vertebrae
Thoracic vertebrae
Lumbar vertebrae
Sacrum
Coccyx
Ischium
Pubis
Ischial tuberosity
Pubic symphysis
Obturator foramen
Acetabulum
Femur
Patella
Tibia
Fibula
Medial view
Lateral view
Cervical vertebrae
Thoracic vertebrae
Lumbar vertebrae
Sacrum
Coccyx
Ischium
Pubis
Ischial tuberosity
Pubic symphysis
Obturator foramen
Acetabulum
Femur
Patella
Tibia
Fibula
Medial view
Lateral view
Cervical vertebrae
Thoracic vertebrae
Lumbar vertebrae
Sacrum
Coccyx
Ischium
Pubic symphysis
Obturator foramen
Acetabulum
Femur
Patella
Tibia
Fibula
Medial view
Lateral view
Cervical vertebrae
Thoracic vertebrae
Lumbar vertebrae
Sacrum
Coccyx
Ischium
Pubis
Ischial tuberosity