García-Azorín *et al. The Journal of Headache and Pain* (2026) 27:62
https://doi.org/10.1186/s10194-026-02301-6

The Journal of Headache and Pain

REVIEW Open Access

Hallmarks of headache disorders: part 5 - secondary headaches

David García-Azorín[1,2*], Alba Perez-de-la-Parte[2], Claudio Tana[3], Adriana Della Pietra[4], Raffaele Ornello[5], Dilara Onan[5,6], Marta Waliszewska-Prosół[7], Wei Wang[8], Roberta Messina[9,10], Doga Vuralli[11], Igor Petrusic[12], William Wells-Gatnik[13], Chia-Chung Chiang[14], Lanfranco Pellesi[15], Francesca Puledda[16], Bianca Raffaelli[17], Eloisa Rubio-Beltran[16†] and Alejandro Labastida-Ramirez[18,19†]

Abstract

Background and aim Headache is a common symptom that can be frequently caused by multiple secondary causes. Every person with headache fears to have a severe cause, and healthcare providers must be trained to identify which patients may suffer from these. This manuscript continues the series of hallmarks of headache disorders describing the state of the art regarding the pathophysiology, clinical aspects, diagnosis, red flags, biomarkers, acute treatment, and preventive therapies of secondary headache disorders.

Main results Identification of secondary headache disorders is challenging, due to the large number of different causes and varied phenotypic presentations. Prompt recognition and targeted treatment can save patients' lives and prevent chronic sequelae. Changes in the headache phenotype or new-onset neurological or systemic symptoms may reflect the occurrence of a subsequent complication and require further investigation. In patients who develop a persistent headache following to the secondary cause a phenotypic-based acute and preventive treatment is usually recommended.

Conclusions Secondary headache disorders are major contributors to the global burden of headache. Their true prevalence is the hidden part of the iceberg, but their consequences are evident. Research on secondary headache disorders could be key in the understanding of primary headache disorders pathophysiology.

Introduction

Headache is a common manifestation of many systemic and neurological diseases. The International Classification of Headache Disorders, 3rd edition (ICHD-3) [1], recognizes seven categories of conditions where headache may be a secondary symptom. These represent the following headache categories: 5) traumatic injuries of the head and/or neck; 6) cranial and/or cervical vascular disorders; 7) non-vascular intracranial disorders; 8) certain substances or withdrawal to drugs or substances; 9) infection; 10) disorders of homeostasis; 11) disorders of the cranium, neck, eyes, ears, nose, sinuses, teeth, mouth, or other facial or cervical structures; and 12) psychiatric disorders [1].

Many of these injuries, disorders, and diseases are highly prevalent [2], and in some of these, such as subarachnoid haemorrhage, bacterial meningitis or cerebral venous sinus thrombosis, headache is the most prevalent symptom [3–5]. Primary headache disorders are among

†Eloisa Rubio-Beltran and Alejandro Labastida-Ramirez contributed equally to this work.

*Correspondence:
David García-Azorín
dgazorin@ucm.es

Full list of author information is available at the end of the article

© The Author(s) 2026. **Open Access** This article is licensed under a Creative Commons Attribution-NonCommercial-NoDerivatives 4.0 International License, which permits any non-commercial use, sharing, distribution and reproduction in any medium or format, as long as you give appropriate credit to the original author(s) and the source, provide a link to the Creative Commons licence, and indicate if you modified the licensed material. You do not have permission under this licence to share adapted material derived from this article or parts of it. The images or other third party material in this article are included in the article's Creative Commons licence, unless indicated otherwise in a credit line to the material. If material is not included in the article's Creative Commons licence and your intended use is not permitted by statutory regulation or exceeds the permitted use, you will need to obtain permission directly from the copyright holder. To view a copy of this licence, visit http://creativecommons.org/licenses/by-nc-nd/4.0/.

the most prevalent disorders [2, 6], but patients affected by a primary headache can also suffer from a secondary headache and are more likely to develop persistent headache after the resolution of the acute phase of the disease [7–9]. Epidemiological data on secondary headache disorders is limited, however, data on incidence or prevalence of the causes of many secondary headache disorders is available, and taking into account the prevalence of headache in these disorders, it can be extrapolated that the number of people suffering from secondary headaches is remarkable. In addition, the clinical phenotype of many secondary headache disorders can mimic that of primary headache disorders [10, 11]. This could reflect a common pathophysiology and represents a perfect opportunity to offer new perspectives on primary headaches. Diagnosis of secondary headaches is challenging, because diagnostic criteria are often unspecific and rely on the presence of a secondary cause.

In the present review we revisit the concept of secondary headache disorder and updated overview of the pathophysiology, clinical aspects, diagnosis and red flags, biomarkers, acute treatment, and preventive therapies of secondary headache disorders is provided. Given the wide scope of the study and the various topics that are covered, a scoping but not systematic review was conducted, without critical appraisal to the risk of bias of each study.

Pathophysiology of secondary headache disorders

Due to the heterogeneity and complexity of secondary headaches, it is not possible to pinpoint a unique mechanism that explains the pathophysiology of all types. As in many other disciplines, the gap between the pre-clinical and clinical fields has not been bridged. In this section, some of the possibly involved mechanisms are mentioned, however, the degree of knowledge surrounding the different secondary headache disorders is heterogeneous, and the robustness and direct applicability of the findings is also variable.

Pain is a defensive system that may alert us to a noxious stimulus. This is the main basis of the head pain in secondary headache disorders. However, not all intracranial structures are pain-sensitive [12]. The scalp, periosteum, dura mater, the falx, arteries, veins, and cranial nerves V, VII, IX, X and C1–C3 are pain-sensitive, while the *pia mater*, brain parenchyma, ependyma and choroid plexus are considered to be pain-insensitive [12, 13]. This has been linked with the pathophysiology of some well-known clinical syndromes, such as meningeal irritation syndrome—where bacteria, inflammatory cells, malignant cells, or blood may stimulate meningeal afferents [14, 15]. The meningeal contribution to migraine has been well recognized [16]. In addition to the irritation from the above-mentioned causes, certain cerebrovascular disorders, such as Moyamoya, are known to have formation of leptomeningeal collateral blood vessels. The physical irritation and accompanying neuroinflammatory responses could also contribute to migraine-like headaches [17]. Another example is intracranial hypertension syndrome, frequently observed in space occupying lesions [18]. Fig. 1 shows the connection between the activation of the trigeminocervical complex by a secondary cause, and the activation of efferent connections responsible for the symptoms that may mimic a primary headache disorders and the features that result atypical for primary headache patients. In many secondary causes, the activation of certain pathways seems common, while some specific secondary causes may show specific features due to the systems that are involved in the pathophysiology.

Recent research indicates that in addition to the classical pathophysiological models and syndromes, novel factors are being progressively recognized. Studies suggest an interplay among several factors, including the activation of the trigeminovascular system (TVS), impairment of the descending modulatory pathways, metabolic and homeostatic responses to pathophysiological events, glymphatic dysfunction, cortical spreading depression, and neuroinflammatory processes (Fig. 2). Secondary headaches represent an opportunity to better understand the role of many structures involved in headache pathophysiology, since in some of them, the impaired structures are localised and well-known.

Activation of the trigeminovascular system

The TVS plays a fundamental role not only in craniofacial nociception [19], but also in the control of the cerebrovascular tone [20]. The trigeminovascular reflex is considered a mechanism of defence that activates to compensate for cerebral vasospasms via the release of calcitonin gene-related peptide (CGRP) [21]. In line with this, studies have shown that following subarachnoid haemorrhage (SAH) there is an immediate, excessive release of CGRP in the cranial venous blood flow [22–24], in parallel with the sudden, severe headaches observed in patients. Increased levels of CGRP have also been reported in blood and cerebrospinal fluid (CSF) of patients with bacterial meningitis, with preclinical models suggesting an increase of cerebral blood flow and intracranial pressure as one of the mechanisms behind this phenomenon [25, 26]. Furthermore, stenosis of cerebral venous sinuses is commonly observed in patients with idiopathic intracranial hypertension (IIH), and despite the stenoses may be more functional than structural, these may result in a dysregulation of the cerebral venous outflow [27–29]. In this regard, increased levels of CGRP have been reported in patients with IIH, with higher levels observed in patients with sustained

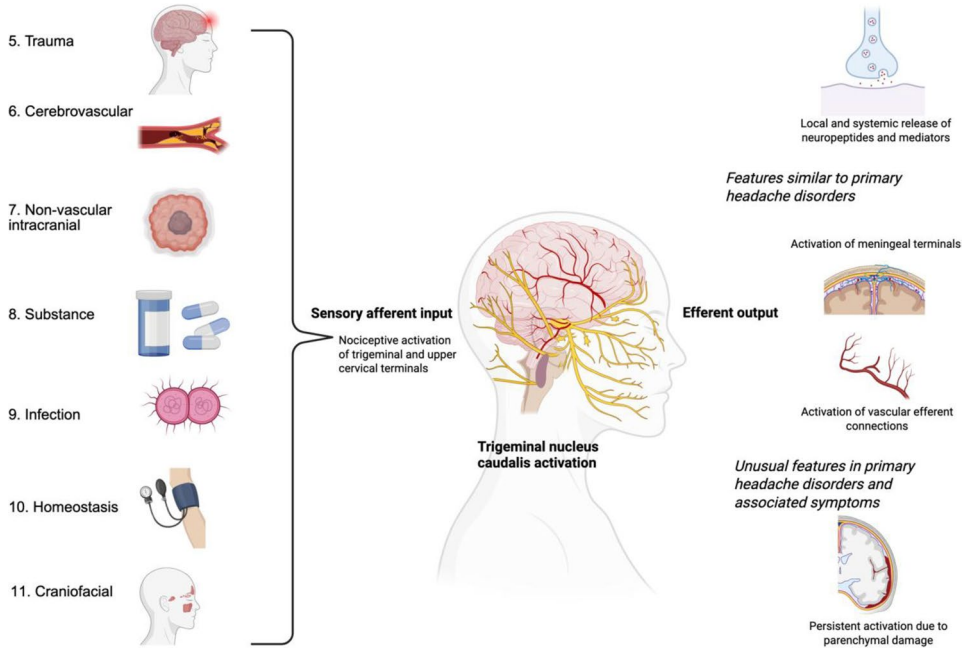

Fig. 1 Connection between secondary causes and trigeminovascular system activation

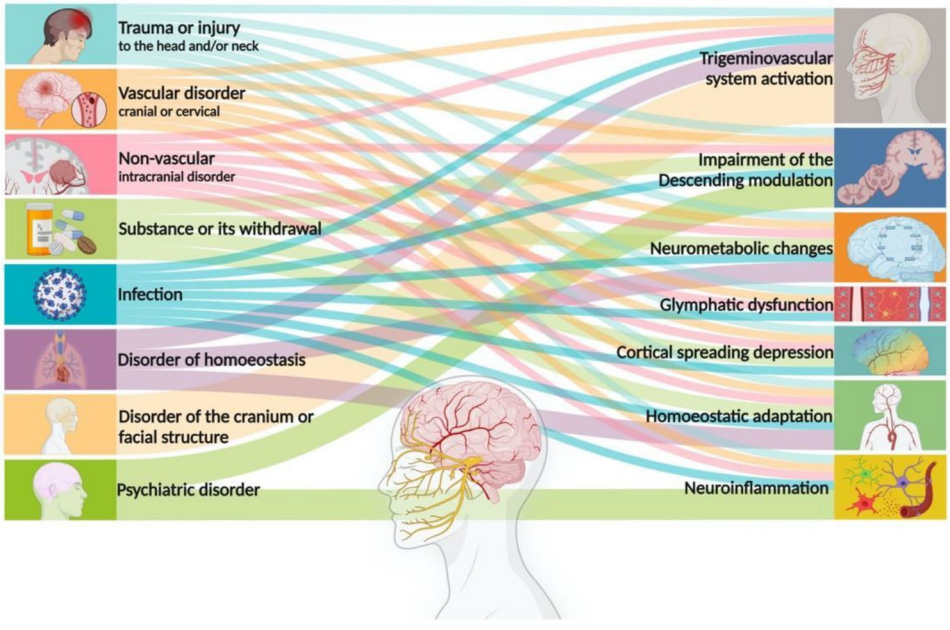

Fig. 2 Mechanisms underlying secondary headaches. Studies suggest an interplay among several factors, including the activation of the trigeminovascular system (TVS), impairment of the descending modulatory pathways, metabolic and homeostatic responses to pathophysiological events, glymphatic dysfunction, cortical spreading depression, and neuroinflammatory processes. Connecting lines show which systems are known to be associated with each secondary headache category

headache even after normalization of intracranial pressure [30]. In spontaneous intracranial hypotension (SIH), the decrease of CSF volume is compensated by hypervolemia of the venous plexus causing venous engorgement, resulting in activation of the TVS and orthostatic headaches [31, 32].

Activation of the TVS system can also be caused after traumatic brain injury (TBI), since CGRP has been shown to have a neuroprotective role [33, 34]. In patients with persistent post-concussion symptoms (such as headache), increased serum levels of CGRP have been reported in the first months after injury [35], whereas low

levels of CGRP have been associated with increased mortality after TBI [36]. Interestingly, levels of CGRP seem to decrease with time, even in patients with persistent post-traumatic headache (PTH), which could be associated with the development of central sensitization [33, 37–39]. Additionally, in TBI calvarial periosteal afferents could also be activated, resulting in sensitization and headache [40].

Modulatory pathways abnormalities

As previously mentioned, impairment of the descending modulatory pathways can be one of the factors driving secondary headaches. For example, patients with multiple sclerosis with demyelinating lesions in the spinal cord, pons or the periaqueductal gray area (PAG), have a higher risk of developing headache when compared to patients without lesions in those structures [41–49]. This has also been observed in patients with tumours, or ischemic lesions in these structures [50]. Furthermore, in patients with PTH, studies show evidence of axonal damage [51–53], with a clear association between white matter abnormalities and post-concussion symptoms [52, 54], as well as changes in gray matter in the midbrain, thalamus and cerebellum [54, 55]. Animal studies suggest a decrease of diffuse noxious inhibitory controls (i.e., conditioned pain modulation) [56], suggesting that impairment of the descending pain circuits promote central sensitization, and as such, chronification [57]. Moreover, preclinical studies in models of TBI, SAH and medication overuse headache have shown a sustained neuronal activation, and an increase of CGRP levels in the brainstem [58–60].

Neurometabolic changes

Secondary headaches have also been associated with (neuro)metabolic changes. In patients with IIH, metabolic disturbances in CSF, serum, and urine have been reported [61–63]. In particular, elevated levels of acetate in CSF have been shown to correlate with headache morbidity [61]. Additionally, an elevated lactate:pyruvate ratio in CSF has been reported in IIH, TBI and SAH [60, 64, 65].

Besides its protective role in the regulation of cerebral blood flow, CGRP has also been described to have a role in the maintenance of (cardio)vascular homeostasis [33]. In patients with arterial dissection, it is suggested that the distension of the vessel stimulates the CGRPergic sensory fibers that innervate the arterial wall [66, 67]. Of note, considering that the carotid plexus of the internal carotid converges within the trigeminocervical complex, case reports suggest a direct activation of the TVS after arterial dissection [68, 69]. Further, during an ischemic event, both CGRP and pituitary adenylate cyclase activating polypeptide (PACAP) have been described to have a cardioprotective function [33, 70], therefore, release of these neuropeptides into the circulation could result in migraine-like headaches.

Glymphatic system

Most recently, the glymphatic system, a brain-wide network of perivascular spaces that supports the rapid exchange of cerebrospinal and interstitial fluid via aquaporins, has attracted attention in secondary headaches pathophysiology [71]. Indeed, glymphatic system impairment has been linked to IIH. For instance, the disruption of the glymphatic flow could cause an accumulation of CSF in the perivascular and subarachnoid spaces, ultimately increasing intracranial pressure, as is typical in IIH [27]. Moreover, transverse sinus (TS) stenoses, prevalent in over 90% of IIH cases, impair the venous CSF outflow pathway, exacerbating symptoms by increasing cerebral venous pressure [27]. Understanding the interplay between TS stenoses and CSF flow dynamics, including the role of the glymphatic system in CSF clearance, is crucial for advancing diagnostic and therapeutic strategies for IIH. Furthermore, it has been shown that TBI can impair glymphatic function in animal models [72], suggesting a potential link between TBI, sleep disturbances, and post-traumatic headaches. Glymphatic system dynamics show an increased activity during sleep and decreased during awake time. Its dysfunction may go beyond purely intracranial pressure regulation, including a decreased clearance of neurotoxic metabolites.

Cortical spreading depolarization

Secondary headaches can also be linked to cortical spreading depolarization (CSD), a wave of neuronal depolarization followed by prolonged suppression of neuronal activity. For instance, in a rat model of medication overuse headache (MOH), chronic exposure to acetaminophen altered the function of the nucleus raphe magnus (NRM), a brainstem modulating system, contributing to cortical hyperexcitability and facilitating trigeminal nociception [73]. This study provides insight into how alterations in brainstem modulation may exacerbate cortical and trigeminal hyperexcitability, contributing to the pathophysiology of secondary headaches like MOH [73]. Similarly, chronic administration of acetaminophen in rats led to an increase in CSD frequency, as well as trigeminal nucleus caudalis (TNC) activation, indicating an increase in cortical excitability and facilitation of trigeminal nociception [74]. In conditions like TBI, CSD may be triggered by the initial injury or subsequent neuroinflammatory processes [75], leading to prolonged elevated cortical CGRP levels, contributing to post-traumatic headache development [76]. Additionally, conditions like SAH disrupt cerebral blood flow responses to CSD, leading to prolonged alterations in local field potential

activity and cognitive deficits in mice, suggesting a potential mechanism for delayed cerebral ischemia in SAH patients [77].

Inflammation

Neuroinflammation or inflammatory reactions in central and peripheral parts of the TVS in response to neuronal activity may link TBI to persistent headaches through mechanisms involving CSD, which activates the TVS [78]. Glial cell activation after TBI, which is also involved in migraine, plays a key role in neuroinflammatory processes by producing inflammatory mediators. Indeed, post-mortem studies show elevated inflammatory mediators mRNA in the brain shortly after TBI [79]. Moreover, CSD may open neuronal pannexin 1 mega-channels, triggering an inflammatory response that activates trigeminal nociceptive fibres linked to headaches [80]. Animal studies show that CSD activates macrophages and dendritic cells, and head injury triggers dural mast cells degranulation and trigeminal nociception [81]. A human study indicated more pronounced cephalic cutaneous allodynia in PTH patients [82], suggesting central sensitization due to peripheral nerve damage and neuroinflammation. Additionally, evidence from animal studies shows neuroinflammatory processes and vascular damage in acute TBI [83], supporting the role of neuroinflammation in PTH. In line with injury-related neuroinflammation in PTH, anti-inflammatory treatments like N-acetyl cysteine (NAC) show promise, with a study in US service members indicating that early NAC administration significantly reduced clinical symptoms after blast-related TBI [84]. Other well-known examples of inflammation-mediated pain is infective meningitis, where the pathogen invasion of the peri-meningeal space and/or the immune response may activate meningeal nociceptors [85].

Clinical pearls

Clinical phenotype of commonest secondary headaches

This section reviews the clinical phenotype of the commonest secondary headaches, starting from the features that may be specific to some secondary headache disorders. Few of these are mentioned in the ICHD-3 [1], however, some secondary headache disorders may have specific features, while others may present a clinical overlap with primary headache disorders. The classification of secondary headache disorders is not based on the clinical phenotype but on the diagnosis of a secondary cause [1]. In many cases, the most specific features are other symptoms and/or signs that are suggestive or typical of the secondary cause, being the headache unspecific or similar to a primary headache syndrome.

Headache attributed to trauma or injury to the head or neck

PTH is a common consequence of cranial trauma. Its prevalence does not correlate with the severity of the trauma [86]. According to the ICHD-3 classification, PTH can be classified as a "secondary headache that occurs within seven days following a trauma or injury, or within seven days after recovering consciousness, or within seven days after recovering the ability to sense and report pain" [1]. Headache can manifest alone or in association with other symptoms such as fatigue, dizziness, brain fog, insomnia, anxiety, irritability, personality changes and reduced concentration [87]. There are some risk factors that can be recognized, such as female sex, young age, depression, previous history of migraine and/or resistant headache [88, 89]. Also, insomnia and vertigo have been found as other risk factors of PTH in a one-year follow up study [88]. Why the course is persistent and often resistant to the most common treatment has not been explained yet. It has been hypothesized to be a mix of pathophysiological mechanisms such as persistent neuroinflammation and CGRP release, altered modulation of descending pain and neurometabolic changes [87, 90, 91].

Clinical features of PTH can resemble those of primary headache disorders. In both adults and children, a tension-type-like pattern is often described, followed in percentage by a migraine-like pattern [92, 93]. Interestingly, a migraine-like pattern, with pulsating and unilateral pain, exacerbation by physical activities, nausea or vomiting, photophobia and/or phonophobia as accompanying symptoms occurs most often after trauma in athletes and after a blast trauma [94]. The persistence of symptoms is typical in subjects with a post-traumatic stress disorder or comorbidities of anxiety and depression [92]. Headache can follow also after moderate or severe injuries such as concussion and laceration and lasts some minutes or days until resolution of the injury or configure a persistent headache over the following months or years as described above [95].

Headache attributed to cranial or cervical vascular disorder

According to the ICDH-3 classification, headache attributed to cranial and/or cervical vascular disorders can be the first manifestation of a vascular disease as a new-onset headache or a worsening of a previous primary headache [1]. Aneurysm rupture, haemorrhagic or ischemic strokes, arteriovenous malformation or fistula, arterial dissection, cerebral venous sinus thrombosis, cavernous angioma and arteritis can be some of the conditions which can be associated with moderate-to-severe headache. The link with most of the vascular diseases can be identified by the acute onset of headache accompanied by other focal neurological symptoms and/or signs

[1]. Stroke-related headache frequency ranges from 7% to 65% and pain may be acute or delayed [96]. Overall, for patients with acute ischemic stroke, headache can occur in approximately 6–44% of patients. In around 23% of patients, the headache may persist beyond three months after the stroke, lasting months, or years for some [97]. In haemorrhagic or ischemic strokes, the predominant clinical manifestations are altered consciousness and focal signs, respectively, while in subarachnoid haemorrhage, dissections, cerebral venous thrombosis, and arteritis, headache is the most common warning symptom at the onset [96]. Temporal arteritis, or giant cell arteritis, is an important differential diagnosis for new onset headache in someone older than 65 years old. Patients often also report vision changes, and systemic symptoms such as fever or night sweats. Checking serum inflammatory markers, empirically starting oral steroids, and a temporal artery biopsy for diagnostic confirmation is often indicated, as untreated temporal arteritis could lead to blindness [98].

The most important red flag which can reveal the presence of an underlying vascular disorder can be the onset of sudden headache, or the transformation of a previous headache with migraine or tension type-like characteristics [1]. It is important to evaluate the presence of thunderclap headache, defined as a headache that went from zero to ten, maximum pain within 60 seconds for at least five minutes. Thunderclap headache is the most typical presentation of subarachnoid haemorrhage from aneurysm rupture, and also reversible cerebral vasoconstriction syndrome. Both could lead to devastating consequences if unrecognized. Other vascular and non-vascular conditions, such as cerebral venous sinus thrombosis, cervical artery dissection, or pituitary apoplexy could also present as thunderclap headache [96].

Headache attributed to a cranial or cervical vascular disorder may change over time, with different features that may correlate with the underlying phenomena that occurs in the patient, and may reflect the occurrence of certain complications, such as arterial or venous infarctions or haemorrhagic transformation of an ischemic infarct.

An uncommon vascular cause of headache can be the cerebral autosomal dominant arteriopathy with subcortical infarcts and leukoencephalopathy (CADASIL), which can manifest with migraine-like headache preceded by typical or atypical (prolonged) aura, small deep infarcts revealed by magnetic resonance imaging (MRI), mood disturbances and subcortical dementia [99]. The diagnosis, however, can be made only by screening for NOTCH-3 mutation, immunostaining of NOTCH-3 antibodies from skin tissue or by assessing the extracellular granular osmiophilic deposition at the arterial media [99].

Headache attributed to non-vascular intracranial disorder

Non-vascular disorders which can manifest with headache can be secondary to an altered (low or high) pressure of CSF, inflammatory (non-infectious) diseases such as neurosarcoidosis (NS), aseptic meningitis, tumours, and Chiari malformation type 1. Also, seizures can be associated with headache, both during the crisis (ictal epileptic headache) or after (post-ictal headache) [1].

Symptoms of spontaneous intracranial hypotension include orthostatic headache associated with photophobia, vomit, neck pain, dizziness, and less frequently radicular symptoms involving the upper limbs or face weakness [100]. SIH is caused usually by a spontaneous spinal CSF leak that can be revealed by imaging. Typical brain MRI features are diffuse pachymeningeal gadolinium enhancement and brain sinking and spinal MRI can reveal the typical CSF leakage. In addition, SIH can manifest with engorged cerebral venous sinuses or subdural fluid collections [101].

On the other hand, raised intracranial pressure may manifest as a headache that is precipitated and/or aggravated by lying down. In these patients, headache is maximal in the morning and may wake-up the patient [102]. Migraine-like headache phenotype may be common in patients with idiopathic intracranial hypertension. In a cross-sectional study that assessed 68 patients, 63% of them fulfilled phenotypic migraine criteria [103]. This has been associated with a worse clinical prognosis in other studies [104].

Papilledema may not be present, however, in large studies > 95% of patients exhibited it [105]. In some patients, papilledema can be notably asymmetric [106]. MRI can reveal findings such as optic nerve protrusion, tortuosity and/or sheath distension, empty *sella turcica*, posterior globe flattening and stenosis of the transverse sinus [107]. Diagnosis is supported by the absence of a symptomatic cause of the intracranial hypertension, including cerebral venous sinus thrombosis, space occupying lesions or infections, among others, and an elevated CSF pressure [108].

Headache is also common in patients with sarcoidosis and represents a challenge to the physician. It may exhibit different clinical patterns, from the comorbidity of a primary headache disorder to a manifestation of the disease, such as brain masses or diffuse brain granulomatous inflammation [109]. The issue of the differential diagnosis is even more complex because the diagnosis of sarcoidosis can be overlooked in patients with extrapulmonary disease, especially if it is isolated [110]. Imaging may disclose signs of organ involvement, but the definitive diagnosis is only made by revealing the typical granulomatous pattern at biopsy [111].

Headache attributed to a substance or its withdrawal

Several substances can be associated with headache including nitric oxide donors, phosphodiesterase inhibitors, carbon oxide, alcohol, cocaine, histamine, or CGRP [112]. In most cases, in the case of exposure to substances, headache occurs shortly after the exposure to the substance, and should cease once that the substance is discontinued [113, 114]. The headache phenotype may resemble a primary headache disorder [112], but its new-onset, or the abrupt worsening of a pre-existing headache should alert about its occurrence [115].

Medication overuse headache is one of the commonest secondary headache disorders, but its diagnosis requires the presence of a pre-existing primary headache disorder [1]. Different treatment approaches exist, with regional differences, but most management protocols agree on the need of evaluation and patient education [116]. There is no agreement about the clinical phenotype of MOH. The ICHD-3 does not require any specific characteristics, however, a pre-existing primary headache disorder is necessary. In some patients, the primary headache disorder becomes chronic and with less prominent features [116].

Headache attributed to infection

Headache attributed to infection comprises a wide variety of manifestations which only have in common the previous exposure to an infectious agent [1]. This subgroup is subdivided into two major categories, depending on whether the infection occurs within the central nervous system (CNS) or if the infection is initially systemic [1]. Exposure to an agent which is capable of invading the central nervous system usually leads to focal clinical symptoms and other neurological manifestations such as seizures and alterations of consciousness [117]. The headache symptoms that may occur with infectious agents not invading the central nervous system are less clearly defined. Headache attributed to viral infection may mimic a primary headache phenotype, such as tension-type headache or migraine-like phenotype [118, 119]. In many cases, the presence of systemic symptoms or signs, such as cough, dyspnoea, fever, myalgia, odynophagia or arthralgia, should alert about its presence [120, 121].

Headache attributed to disorder of homeostasis

This tenth category includes a very heterogeneous set of conditions, spanning from hypoxia or hypercapnia to dialysis, arterial hypertension, hypothyroidism, fasting, and cardiac ischemia [1]. Interesting subtypes of headache attributed to disorders of homeostasis include the form associated with airplane travel and that associated with diving. The first one is a short-lasting, mostly unilateral headache typically associated with take-off and landing [122] and with potential response to triptans [123], while the second one worsens with prolonged diving [124]. Notably, all headache types associated with variations of the external air pressure, including airplane travel or diving, are more prevalent in individuals suffering from primary headaches such as migraine compared with individuals without headache [125, 126]. Sleep apnoea headache has no specific features and occurs in up to one third of patients with sleep apnoea [125]. Notably, sleep apnoea headache should be differentiated from primary headaches occurring at night such as hypnic headache or nocturnal episodes of cluster headache [1]. Those headache disorders have specific clinical features; however, their clinical manifestations might overlap, and neurophysiological studies of sleep are useful to screen patients with headaches occurring at night or presenting with snoring, obesity, or other clinical characteristics suggestive of obstructive sleep apnoea disorders. Referring to dialysis headache, it usually has a throbbing quality, moderate intensity, and frontotemporal location and might therefore resemble migraine [122, 123]. Therefore, the situation in which headache occurs is key to the diagnosis. Hypothyroidism can also cause a headache disorder resembling migraine; patterns such as new-onset chronic daily headache might enhance the suspicion of a secondary headache together with systemic and laboratory signs [127]. Referring to hypertension, it should be noted that only systolic blood pressure values > 180 mmHg or diastolic blood pressure values > 120 mmHg can cause headache [128, 129]. Headache associated with hypertensive crises should always lead clinicians to the suspicion of secondary hypertension such as renal causes or tumours of the adrenal glands. Regarding other headaches attributed to disorders of homeostasis, fasting headache has features similar to tension-type headache and increases with increasing time of fasting [130]. Cardiac cephalalgia can be the only manifestation of a heart attack in up to 14–27% of patients and has no specific features; older age at onset, no past medical history of headache, presence of vascular risk factors, and onset of headache under stress or exertion are elements aiding the diagnosis [131, 132]. Despite the own classification mentions that the clinical phenotype may be a "migraine-like" one [1], recent studies have provided evidence that this may not be the case, and no patients presented all phenotypic migraine criteria [133].

Headache or facial pain attributed to disorder of the cranium, neck, eyes, ears, nose, sinuses, teeth, mouth or other facial or cervical structure

These kinds of headache disorders require careful history taking as they can be mistaken for a primary headache, while on the other hand some primary headache disorders such as migraine can be mistaken for secondary

headache attributed to facial or cervical structures. It has been shown that most patients coming to medical attention because of a suspect diagnosis of sinus headache actually have migraine [134]. Migraine might also be misdiagnosed as cervicogenic headache if the clinical examination of patients is focused on location of pain. To diagnose a secondary headache, clear demonstration of pathology in one of the affected structures is required [1]. The diagnosis of those conditions can be difficult if based on clinical grounds only, as cervicogenic headache might present with nausea, photophobia, phonophobia, and even trigeminal symptoms thus resembling migraine [135]. Together with pain location, other clues to a diagnosis of secondary headaches due to disorders of the cervical spine or temporomandibular joint include the onset of headache in older age, as alterations of bone structures can develop or worsen in response to osteoarthritis. Referring to questionnaires, the Sino-Nasal Outcome Test-22 (SNOT-22) can aid the diagnosis of headache attributed to acute rhinosinusitis [136], even if its validity is not universally accepted [134, 137]. A useful clue to diagnosis of cervicogenic headache or headache attributed to dysfunction of the temporomandibular joint is worsening of headache with movement [1, 135, 138]. In the case of cervicogenic headache, pharmacological testing can also be useful, as that subtype of headache disorders responds well to anaesthetic blocks. The Cervicogenic Headache International Study Group criteria even consider response to anaesthetic blocks as a diagnostic criterion for cervicogenic headache [135]. Imaging tests of the neck, facial region, and/or paranasal sinuses are important to confirm or rule out the diagnosis of these headache groups. Vascular imaging can also be useful to rule out other diagnoses such as vertebral arterial dissection [135].

Table 1 Main categories of red flags

Group A: Red flags related to the prior history of patients	Group B: Red flags related to the phenotype of the headache
Neoplasms in history [143, 144]	*Thunderclap onset* [145, 146]
Immunosuppression [147]	*Positional headache* [102, 148]
Cranial or cervical trauma [149]	*Wake-up headache* [106, 150]
Drug (including illicit) use [151, 152]	*Pattern change* [153–155]
Old age [156]	*Recent onset* [4, 155, 157]
Increased risk of bleeding or thrombosis [156]	*Worst headache ever* [158]
Pregnancy or puerperium [159]	*Progressive headache* [160, 161]
	Treatment resistant [162, 163]
	Strictly unilateral [164]
	Precipitated by sneezing, coughing, or exercise [165]
Group C: Red flags related to the presence of associated symptoms	**Group D: Red flags related to the presence of abnormal signs in the examination**
Fever [166]	*Papilledema* [167]
Weight loss [168]	*Painful eye with autonomic features* [169, 170]
Altered consciousness [171]	*Focal neurological signs (e.g., paresis, hypoesthesia, ataxia)* [172, 173]
Abnormal behaviour [174]	
Abnormal movements [175]	
Unexplained vomiting [176]	
Neurophthalmological symptoms (e.g., visual loss, diplopia) [177]	
Focal neurological symptoms (e.g., weakness, hypoesthesia, gait disturbances) [178]	

Headache attributed to psychiatric disorders

This last group includes headache manifestations occurring in individuals with either somatization disorder or psychotic disorders [1]. Patients can be delusional about the aetiology or circumstances of their headache attacks or be convinced that there is some pathology in their brain or body [139]. The diagnosis of headache attributed to psychiatric disorders can be extremely difficult given the low reliability of individuals with psychiatric disorders and the strong comorbidity between primary headache disorders and psychiatric conditions [140]. Careful history taking and clinical examination might help in the diagnosis. Headache attributed to psychiatric disorders is ultimately a diagnosis of exclusion for which primary and other secondary headaches should be ruled out so as not to miss potentially useful treatments. A changing clinical phenotype, not suggestive of any primary or secondary headache, with inconsistent features, or abrupt improvement or worsening may occur in patients with this difficult disorder.

Secondary headaches and red flags

Red flags are pieces of information whose presence increases the likelihood of having a secondary headache disorder [141, 142]. Red flags can be associated with either the prior history of the patient, to an atypical headache pattern, to the presence of unusual symptoms or to an abnormal neurological examination. Despite widely known, a striking problem with red flags is the lack of consensus on which red flags should be used, with differing proposals and lists. In addition, few of them have been properly validated, decreasing their validity, and forcing physicians to interpret and use them cautiously. The Table 1 summarizes the main categories of red flags.

Red flags present a series of pitfalls. First, none of them is fully specific to a single disorder, and can be associated with various diseases [115, 142]. Second, none of the red flags is 100% specific, being necessary the combination of multiple red flags and a close monitoring of the patient [115, 179]. For instance, not all patients with

cerebral venous sinus thrombosis refer to worsening of the headache when lying down [154, 160]. Third, patients with primary headache disorders may also present some of these, such as treatment resistance or wake-up, which may occur in patients with migraine [180, 181]. Fourth, not all secondary headache disorders are equally menacing, with some diseases that may compromise patients' life or cause persistent disability, the so-called life-threatening secondary headache disorders or high-risk headaches [120]. In the ICHD-3, a total of 118 different causes of life-threatening disorders are listed (Table 2), including some primary headache disorders whose clinical presentation requires the exclusion of a secondary cause, prior to the assumption that the headache is caused by the primary headache [1]. This is very important in the case of primary headache disorders, which are not life-threatening by definition but that may mimic multiple secondary causes. Healthcare providers should never consider a diagnosis of these primary headache disorders without ruling out a secondary cause, and without taking into account that many of these syndromes require, as per classification, that the patient experiences multiple episodes.

To increase the complexity, some disorders may have various clinical presentations, and symptoms may change and/or evolve, in parallel with the disorder pathophysiology, such as the occurrence of intracranial hypertension, parenchymal lesions, meningeal irritation, ischemia, or inflammation, among others [157]. The clinical expression of the same injury or insult may be variable between individuals. This may be associated with the individual predisposition, the presence of a pre-existing headache disorder or a predisposing biology [114, 121].

Different authors have proposed lists of red, green, and orange flags [115, 142, 182, 183], however most of these are based on expert opinion and validation studies are scarce and with inconsistent results [179, 184–191]. In these studies, with retrospective or prospective, mostly based in the emergency department setting, the red flags that resulted more frequently associated with a secondary cause were abnormal examination, acute onset of the headache, age over 50/55 years, occipital headache, papilledema, muscle weakness, confusion or memory impairment, or immunological disorders [181–191]. In this regard, the high number of possible causes of secondary headache and the notable number of possible red flags make validation studies complex and may contribute to the differing results. Studies providing further evidence on diagnostic accuracy of red flags are truly necessary, given the magnitude of the secondary headaches problem. The Table 3 lists some of the SNNOOP10 items that are associated with each of the secondary headache categories [115].

Hence, healthcare providers must be cautious when evaluating a patient with headache, remembering that the presence of red flags warrants further investigation and/or vigilance to the patient. A primary headache diagnosis should be given only if the patient has the typical cyclic, phenotypic presentation of the suspected disease, and there is no better explanation of the headache, after a proper evaluation and study of it [1].

Diagnostic biomarkers in secondary headache disorders

Diagnosis of headache relies on the verbal description of the patient and a thorough neurological and cranial examination. In primary headache disorders there are no biomarkers that can be routinely used in clinical practice yet, but in secondary headache disorders there are biomarkers that may point to the secondary cause, allowing the diagnosis of the secondary headache disorder. In this section we critically appraise the existing diagnostic biomarkers, including also clinical symptoms and/or signs that may be useful for diagnosis in certain specific cases. Importantly, most biomarkers are linked to the secondary disorder, rather than to the secondary headache disorder, and few of them serve as prognostic features. Novel and emergent biomarkers are needed to differentiate patients with secondary headache disorders, specially these causes that if untreated, may compromise patients' lifes and that are time-sensitive.

Biomarkers in headache attributed to trauma injury to the head and/or neck

Post-traumatic headache is increasingly being recognized as a heterogeneous headache disorder, which makes it challenging to determine specific biomarkers [192]. Brain imaging is key, since the presence of fractures, haemorrhages and/or concussions differentiate headache attributed to trauma injury into mild or moderate to severe [1]. Persistent headache attributed to traumatic injury to the head can be divided into two groups: persistent headache attributed to moderate or severe traumatic injury to the head (such as whiplash injury) and persistent headache attributed to mild traumatic injury to the head [193]. Moreover, the bilateral presence of arcuate foramen is associated with an increased frequency of acute headache after suffering a whiplash [194]. In addition, individuals with post-traumatic headache have reduced values of N-acetyl aspartate and increased values of choline in the white matter of the frontal and parietal lobes [195]. Also, acute mild post-traumatic headache has been associated with iron accumulation in multiple brain regions [196]. Moreover, patients had less cortical thickness in frontal and parietal areas, and less spinothalamic tract volume [197]. There were also differences in the connectivity of the corpus callosum, spinothalamic tract, and

Table 2 Major groups and/or subgroups of the ICHD-3 classification that include high-risk and life-threatening headache disorders

Part One: The Primary Headaches	
Group 1	1.2.2 Migraine with brainstem aura 1.2.3 Hemiplegic migraine 1.2.4 Retinal migraine 1.4.2 Persistent aura without infarction 1.4.4 Migraine aura-triggered seizure
Group 2	None
Group 3	None*
Group 4	4.1 Primary cough headache 4.2 Primary exercise headache 4.3 Primary headache associated with sexual activity 4.4 Primary thunderclap headache 4.9 Hypnic headache 4.10 New daily persistent headache (NDPH)
Part Two: The Secondary Headaches	
Group 5	5.1.1 Acute headache attributed to moderate or severe traumatic injury to the head
Group 6	6.1 Headache attributed to cerebral ischemic event 6.2 Headache attributed to non-traumatic intracranial haemorrhage 6.3 Headache attributed to unruptured vascular malformation 6.4 Headache attributed to arteritis 6.5 Headache attributed to cervical carotid or vertebral artery disorder 6.6 Headache attributed to cranial venous disorder 6.7 Headache attributed to other acute intracranial arterial disorder 6.8 Headache and/or migraine-like aura attributed to chronic intracranial vasculopathy 6.9 Headache attributed to pituitary apoplexy
Group 7	7.1 Headache attributed to increased cerebrospinal fluid (CSF) pressure 7.2 Headache attributed to low CSF pressure 7.3 Headache attributed to non-infectious inflammatory intracranial disease 7.4 Headache attributed to intracranial neoplasia
Group 8	8.1.3 Carbon monoxide (CO)-induced headache 8.1.5 Cocaine-induced headache
Group 9	9.1 Headache attributed to intracranial infection 9.2 Headache attributed to systemic infection
Group 10	10.1 Headache attributed to hypoxia and/or hypercapnia 10.3 Headache attributed to arterial hypertension 10.6 Cardiac cephalalgia
Group 11	11.3.1 Headache attributed to acute angle-closure glaucoma 11.3.3 Headache attributed to ocular inflammatory disorder 11.5.1 Headache attributed to acute or recurring rhinosinusitis
Group 12	12.1 Headache attributed to somatization disorder 12.2 Headache attributed to psychotic disorder
Part Three: Painful Cranial Neuropathies, Other Facial Pain and Other Headaches	
Group 13	13.1.1.2 Secondary trigeminal neuralgia 13.1.2 Painful trigeminal neuropathy 13.2.1.2 Secondary glossopharyngeal neuropathy 13.2.2 Painful glossopharyngeal neuropathy 13.3.1.2 Secondary nervus intermedius neuralgia 13.3.2.3 Painful nervus intermedius neuropathy attributed to other disease 13.6 Painful optic neuritis 13.7 Headache attributed to ischemic ocular motor nerve palsy 13.8 Tolosa-Hunt syndrome 13.9 Paratrigeminal oculosympathetic (Raeder's) syndrome 13.10 Recurrent painful ophthalmoplegic neuropathy 13.13 Central neuropathic pain
Group 14	14.2 Headache unspecified

* A symptomatic cause must be ruled out in every patient with trigeminal autonomic cephalalgia. NDPH: new-daily persistent headache; CSF: cerebrospinal fluid; CO: carbon monoxide

Table 3 Red flags that are associated with each of the different secondary headache disorders categories

Secondary headache group	Specific/typical red flags
5. Trauma	-Posttraumatic onset of headache -Sudden or abrupt onset -Neurologic deficit or dysfunction (including decreased consciousness) -Precipitated by sneezing, coughing, or exercise -Pattern change or recent onset of new headache
6. Vascular	-Sudden or abrupt onset -Neurologic deficit or dysfunction (including decreased consciousness) -Progressive headache and atypical presentations
7. Non-vascular	-Neoplasm history -Pattern change or recent onset of new headache
8. Substance	-Painkiller overuse or new drug at onset of headache -Neurologic deficit or dysfunction (including decreased consciousness)
9. Infection	-Systemic symptoms including fever, neck stiffness -Neurologic deficit or dysfunction (including decreased consciousness) -Older age (onset after 65 years) -Pathology of the immune system such as HIV
10. Homeostasis	-Pregnancy or puerperium pathology of the immune system such as HIV -Neoplasm history -Pattern change or recent onset of new headache -Wake-up headache
11. Craniofacial	-Positional headache -Painful eye with autonomic features -Sudden or abrupt onset (neck) -Painful eye with autonomic features (glaucoma) -Systemic symptoms including fever
12. Psychiatric	-Posttraumatic onset of headache -Pattern change or recent onset of new headache

periaqueductal gray matter [198, 199]. There are also suggestions of existing imaging predictors of post-traumatic headache becoming persistent, such as less thickness or volume and higher curvature of superior, middle, and inferior temporal, fusiform, inferior parietal, and lateral occipital regions, as well as the baseline connectivity between right ventrolateral periaqueductal gray with the right inferior parietal lobule and right precuneus [200–202]. Further, using quantitative sensory testing and a light stimulation device to measure cutaneous heat pain thresholds and light-induced discomfort thresholds, it has been found that those with posttraumatic headache have lower light-induced pain thresholds and lower cutaneous pain thresholds [202, 203]. Anyhow, objective biomarkers for post-traumatic headache diagnosis and prognosis still need to be validated and then used to refine and optimize the diagnostic criteria and prognosticate outcomes [204].

Biomarkers in headache attributed to cranial or cervical vascular disorders

The diagnosis of cerebrovascular diseases is clinical, but its confirmation is usually radiological. Most of the conditions included into this group require an imaging confirmation of the stroke, haemorrhage, vascular malformation, dissection, venous thrombosis, vasoconstriction or angiopathy [1]. Many of these conditions require an urgent conventional imaging, such as non-contrast, contrast-enhanced computed tomographic (CT) scans, CT perfusion and CT angiography (CTA), and MRI with fluid-attenuated inversion recovery (FLAIR), gradient-echo T2-weighted and magnetic resonance angiography (MRA) images [205]. In addition, in some cases, digital subtraction angiography continues to be the gold standard in cases of diagnostic ambiguity and is increasingly utilized with advances in endovascular treatments [206]. Depending on the etiopathogenesis of the vascular disorders that caused the headache, several radiological findings could be identified, including signs of cerebral infarction, subdural haemorrhage, intracerebral haemorrhage, arteriovenous malformation, aneurysm, dural arteriovenous fistula, artery dissection, cerebral venous thrombosis, reversible cerebral vasoconstriction syndrome, pituitary apoplexy, etc. When patients present with thunderclap headache, even if the initial CTA or MRA is negative, it is important to ensure a repeated CTA or MRA is done in a few weeks. The vasoconstriction from reversible cerebral vasoconstriction syndrome (RCVS) often does not show up in the very first imaging but might be captured in subsequent vascular imaging [206]. In addition, cerebrospinal fluid may be collected when subarachnoid haemorrhage is suspected without radiological signs for evaluation of xanthochromia [1]. The presence of acute lesions in the MRI has been associated with an increased risk of headache, and interestingly, patients with persistent headache attributed to past ischemic stroke showed higher gray and white matter volumes, higher thalamus volumes and better microstructural integrity than stroke survivors without headache, exhibiting also better cognitive outcomes [207].

Biomarkers in headache attributed to non-vascular intracranial disorders

This secondary headache subgroup, includes a series of disorders of varied aetiologies, including increased or low cerebrospinal fluid pressure, non-infectious inflammatory intracranial disease, non-infectious inflammatory diseases, neoplasia, Chiari malformation type I, etc. Diagnostic criteria are based on clinical, laboratory, and neuroimaging findings, as well as the cerebrospinal fluid pressure and composition. The existing guidelines recommend the exclusion of a secondary cause [108, 208]. The Modified Dandy criteria for intracranial hypertension,

updated by Friedman in 2013, provides a structured approach to diagnosing idiopathic intracranial hypertension [209]. The presence of papilledema is a significant clinical sign. Also, lumbar puncture must demonstrate elevated opening pressure. Brain imaging, typically MRI with MR venography or CT scan, should show no evidence of mass lesion, hydrocephalus, or structural abnormalities that could explain increased intracranial pressure [210]. However, MRI might show features suggestive of idiopathic intracranial hypertension, such as flattening of the posterior aspect of the globe, empty *sella tucica*, and transverse venous sinus stenosis [108, 210]. Unfortunately, MRI features of idiopathic intracranial hypertension are not prognostic of visual and headache outcomes [211]. Novel technologies may facilitate intracranial pressure monitoring, with devices that provide continuous monitoring. First-line imaging in spontaneous intracranial hypotension should be MRI of the brain with contrast and the whole spine. Typical MRI findings are enlargement of the pituitary, decreased mamillopontine distance, sagging of the brainstem and cerebellar tonsillar descent, smooth dural thickening and pachymeningeal contrast enhancement, distension of the dural venous sinuses and ventral spinal longitudinal epidural collection [208]. In the case of headache attributed to brain neoplasm, brain imaging may be highly specific of the underlying aetiology, however, in some cases, pathology is still necessary to set the final diagnosis and the presence of specific mutations that may guide the treatment [212]. In other cases, the presence of headache in some tumours may suggest the presence of certain complications, such as intracranial haemorrhage, or the presence of bone-invasion and/or oedema [213, 214].

Biomarkers in headache attributed to a substance or its withdrawal

Brain imaging is not usually necessary to establish the diagnosis of a secondary headache disorder of this subgroup, except for cases where the substance may have caused intracranial complications [1]. This may be the case of cocaine-induced headache or carbon monoxide-induced headache [215, 216]. Alcohol consumption and intoxication may cause various structural brain changes, such as osmotic myelinolysis, Wernicke encephalopathy, Marchiafava-Bignami, or brain atrophy [217].

In the case of MOH, there are potential candidates for neuroimaging biomarkers such as decreased gray matter volume and neurovascular coupling in the orbitofrontal cortex [218, 219]. In addition, serum lipopolysaccharide, VE-Cadherin, CGRP, HIF-1α, and interleukin (IL)-6 levels are significantly higher in the MOH [220], as well as increased L-PGDS and decreased VDBP and APOE serum concentrations [221], compared to patients who have episodic migraine and healthy controls. Moreover, cutaneous pain thresholds are significantly lower in MOH patients [221]. None of these is yet accepted to be incorporated in the routine clinical practice, but in a near future, these may guide which patients have a higher risk of developing MOH or require a more intensive therapy to revert its effects.

Biomarkers in headache attributed to infection

The prompt and accurate diagnosis of infection-related headache is fundamental for facilitating the implementation of targeted therapeutic interventions, thereby potentially precluding the development of potential complications. The evaluation of a patient presenting with a headache suspected to be of infectious origin necessitates a meticulous two-pronged approach: a comprehensive clinical history and physical examination followed by targeted diagnostic investigations. The collection of a detailed history aims to elicit crucial information pertaining to the headache itself, including its onset, location, and severity. Additionally, inquiring about the presence of fever, recent infections, and any pertinent medical history is essential. Factors influencing immune status, such as chronic illnesses or medications, travel history, particularly to regions endemic for certain pathogens, and recent surgical procedures should also be explored. Physical examination looking at vital signs, neurological function, and meningeal signs serves to corroborate the information gleaned from the history [222].

In the case of systemic infections, a mild headache may be accompanied by other infectious symptoms such as fever, myalgia, fatigue and malaise or a prominent headache may be present as in the case of influenza or coronavirus disease 2019 (COVID-19) [223]. Elevated C-reactive protein (CRP), erythrocyte sedimentation rate (ESR) and leukocytes may be mildly elevated in viral infections whereas a more prominent increase is observed in bacterial infections [224]. Lymphocytosis or lymphopenia may be detected in viral infections [225] and increase in absolute neutrophil count is observed in bacterial infections [226]. The infectious agent may be detected via microscopy, culture, serological or polymerase chain reaction (PCR) molecular tests.

Intracranial infections are within the main life-threatening causes of headache. The presence of neurological symptoms and/or signs is of great help in diagnosis, but their absence does not exclude it. While the classic triad of fever, neck stiffness, and altered mental status occurs in only 44% of cases of bacterial meningitis, at least two of these symptoms are present in 95% [227]. Viral meningitis, in contrast, typically features headaches with less prominent meningeal irritation compared to bacterial infection [228]. Encephalitis, involving brain dysfunction due to parenchymal inflammation, can overlap with meningoencephalitis [229]. Initial evaluation or

suspected intracranial infection involves laboratory tests, including a complete blood count to assess for leucocytosis, and inflammatory markers like CRPC or ESR [228, 229]. Lumbar puncture remains essential for diagnosing meningitis or encephalitis, providing crucial information on cell count, protein levels, and potential pathogens. CSF analysis in bacterial intracranial infection reveals elevated opening pressure, marked neutrophilic pleocytosis, elevated protein levels, and decreased glucose concentration in the CSF compared to serum levels. The CSF appearance is typically turbid or opalescent, with a colour ranging from xanthochromic to yellow green [230]. In contrast, viral infections present with clear CSF, normal or slightly elevated opening pressure, mildly elevated protein levels, normal glucose concentrations, and increased inflammatory cells predominantly composed of lymphocytes [230]. Furthermore, CSF analysis enables the identification of the bacterial or viral pathogen. Neuroimaging should precede lumbar puncture in patients with suspected increased intracranial pressure due to herniation risk. MRI is also often considered in specific settings, particularly when suspicion of brain abscess or encephalitis is high [231]. MRI findings in meningitis can be subtle, with up to 50% of cases demonstrating failed CSF suppression on FLAIR sequences, restricted diffusion within the sulci on diffusion-weighted imaging (DWI), and leptomeningeal enhancement. In encephalitis, MRI may reveal T2/FLAIR hyperintensity involving the brain parenchyma, with or without contrast enhancement, and a characteristic cystic lesion with marked central restricted diffusion should be highly suggestive for cerebral abscess [222, 231]. Electroencephalography (EEG) can be a supportive tool in diagnosing acute encephalitis. However, it lacks specificity, and abnormal EEG findings can occur in various other encephalopathy aetiologies [232].

Biomarkers in headache attributed to disorder of homeostasis

Disorders of homeostasis include a range of systemic and metabolic disorders affecting various organ systems such as altered arterial blood gases (hypoxia, hypercapnia), sleep apnoea syndrome, systemic arterial pressure, volume disturbances caused by dialysis and endocrine disorders. Headache attributed to hypoxia and hypercapnia occurs as a result of disturbances in arterial blood gas concentrations. In both of these disorders, arterial blood gases determination is key to prove that either hypoxia and/or hypercapnia are occurring, and therefore can be corrected [233]. Sleep apnoea syndrome with apnoea-hypopnea index ≥ 5 must be diagnosed with overnight polysomnography [234]. Dialysis headache (DH) occurs during haemodialysis (HD) and resolves within 72 hours after the dialysis and is associated with hypotension and disequilibrium syndrome [1]. Elevated levels of CGRP before dialysis have been shown in DH patients without a prior headache history compared to HD patients without headache, whereas substance P levels were not different between the two groups [235]. CGRP decreased with dialysis in both groups while substance P increased in DH patients and decreased in headache patients without headache after dialysis. These data suggest that these two neuropeptides may have a role in DH [235].

Headache attributed to arterial hypertension occurs during an acute increase in systolic blood pressure to ≥180 mmHg and/or diastolic pressure to 120 mmHg. Headache attributed to pheochromocytoma (PCC) diagnosis requires the investigations of plasma free metanephrin level, 24-hour urinary testing for metanephrine and normetanephrine, vanillyl-mandelic acid and total catecholamines and CT or MRI is recommended for tumour localization [236]. [^{131} I] or [^{123} I] MIBG or [^{111}In] Pentetreotide scan or [^{18}F] DOPA PET functional imaging modalities can be used to diagnose PCC [236, 237]. Headache attributed to pre-ecclampsia or eclampsia requires the urinary evaluation for proteinuria [1]. Headache attributed to hypothyroidism depends on evidence of causation along with headache that is bilateral and/or constant over time and the diagnosis of hypothyroidism with the evaluation of serum thyroid-stimulating hormone and free T4 levels [238]. Cardiac headache diagnosis relies on multiple examinations during headache attacks involving electrocardiography (ECG), 24-hour holter-ECG monitoring, myocardial enzymes, myocardial damage markers [239] or demonstration of co-occurrence of headache and cardiac ischemia during nuclear cardiac stress testing or treadmill [1].

Biomarkers in headache or facial pain attributed to disorder of the cranium, neck, eyes, ears, nose, sinuses, teeth, mouth or other facial or cervical structure

Disorders of the cervical spine and of other structures of the neck and head have been regarded as common causes of headache, since many headaches seem to originate from the cervical, nuchal or occipital regions, or are localised there [1]. Any evidence of clinical and/or imaging evidence of a disorder or lesion within the cranium, neck, eyes, ears, nose, sinuses, teeth, mouth or other facial or cervical structure can be used as a diagnostic basis for headache or facial pain [240]. However, large-scale controlled studies have shown that such changes are equally widespread among people with and people without headache. Degenerative changes in the cervical spine can be found in virtually all people over 40 years of age [241]. In this subgroup, biomarkers are specific to the structure that is suspected to be involved in the headache. In many cases, the evaluation of a physical therapist, ophthalmologist, otorhinolaryngologist, or odontologist may

be required to properly evaluate whether a local disorder is responsible for the headache [1].

Biomarkers in headache attributed to psychiatric disorders

Headache attributed to psychiatric disorders is defined as the headache that develops simultaneously with a psychiatric disorder or worsens significantly after the psychiatric disorder becomes obvious [1]. Psychiatric disorders also usually accompany primary headache disorders such as migraine and tension type headache [242]. Definite biomarkers or clinical proof to establish a causal relationship with the psychiatric disorder is difficult to achieve therefore it is a diagnosis of exclusion. In many cases, the atypical description of the headache that may not fulfil criteria for any ICHD-3 disorder, or the presence of unusual features, symptoms or signs may require brain imaging to reassure the physician that the headache is not caused by any atypical disorder.

The Table 4 summarizes the main biomarkers related to each of the different secondary headache categories. To be noted that many of these biomarkers are related to the secondary cause, rather than the headache itself. In the ICHD-3, no headache-specific biomarkers are listed and the diagnosis still relies on the diagnosis of the secondary cause. However, in patients where no specific secondary cause is suspected, a step-wise approach is recommended (Fig. 3). Some biomarkers may be related with prognosis too, however, if the number of headache-specific biomarkers is limited, the availability of biomarkers linked to headache prognosis is still lower.

Secondary headache disorders are prevalent in resource-constrained settings too. In these, clinical examination is even more important, with vital signs monitoring and close-up evaluations being the basis of the diagnosis. The diagnostic certainty of many disorders, such as intracranial neoplasms may not be reached without imaging or with less accurate tests, such as CT instead of MRI. Table 5 summarizes the diagnostic options for resource constraint settings.

Acute treatment of secondary headache disorders

Although acute treatment is frequently needed by patients with secondary headache disorders, evidence regarding the optimal therapies is scarce. In many cases, conducting randomized controlled trials is highly challenging and many of the employed therapies are supported by series of cases or expert opinion only. This section will revisit the existing evidence supporting the use of the different available acute treatments for each of the major secondary headache disorders subgroups. Neither the acute treatment section nor the preventive treatment section represents a treatment guideline and the evidence supporting these therapies has not been assessed critically. The source of the evidence for each treatment is referenced but the scope of this manuscript is not providing an evidence-grading system list. Nevertheless, given the limited amount of existent data, the quality of the studies, the small sample sizes, and the heterogeneity in the design of the studies, a formal appraisal would probably conclude that the degree of evidence is very low in most of the cases, and the risk of biases is very high. This should be taken into account when reading the therapies that could result effective, except for the few cases where the evidence is stronger, which are specifically referenced.

Acute treatment of headache attributed to trauma or injury to the head and/or neck

The acute management of headache attributed to traumatic injury of the head and/or neck (PTH) predominantly involves simple analgesics, phenotype specific medications, and antiemetics [243]. While scarce clinical data is available, simple analgesics such as acetaminophen, aspirin, and nonsteroidal anti-inflammatory drugs (NSAIDs) are recommended as the first-line therapy for all patients with PTH, including PTH attributed to whiplash or craniotomy [192, 244, 245]. In the case of therapeutic inefficacy, a phenotype specific approach is recommended [246]. While patients assigned to the TTH-like phenotype are generally limited to simple analgesics, patients assigned to the migraine-like phenotype may benefit from caffeine combined drugs, triptans, ditans, or gepants [192, 243]. While generally not recommended, opioids are often used in the acute treatment of PTH attributed to craniotomy [245, 246]. Due to the high frequency of PTH episodes, patient education is necessary to reduce the risk of developing MOH [247, 248]. In addition to analgesics, antiemetics should be considered in all cases of PTH associated nausea [243, 246].

Acute treatment of headache attributed to cranial or cervical vascular disorders

Headaches attributed to cranial or cervical vascular disorders are generally treated according to their underlying aetiology and specific headache phenotype. For acute headaches that are attributed to an evolving ischemic, haemorrhagic, inflammatory, or metabolic pathology, aetiology specific medical and/or surgical therapy targeting the underlying pathology is recommended [205, 249–251]. In contrast, persistent headaches attributed to prior vascular events are longstanding and may require further therapeutic intervention according to the presenting headache phenotype. While there is a scarce lack of available data exploring possible therapeutic options, persistent headaches attributed to cranial or cervical vascular disorders are generally assigned to a migraine-like headache or TTH-like headache phenotype and treated as such [205, 252].

Table 4 Diagnostic biomarkers that have been identified in differentiating various forms of secondary headaches

		General laboratory (CRP, ESR, Leukocytes …)	CGRP, PACAP …	Conventional imaging	Advanced imaging	CSF	EEG	Others
Trauma	Mild	/	/	/	1) reduced N-acetyl aspartate and increased choline 2) iron accumulation 3) less cortical thickness in frontal and parietal areas 4) differences in the connectivity of the corpus callosum, spinothalamic tract, and periaqueductal gray matter	/	/	lower light-induced pain thresholds and lower cutaneous pain thresholds
	Moderate or severe	Increased inflammatory biomarkers	/	Tissue injury	/	Increased inflammatory biomarkers	/	/
Vascular		Increased inflammatory biomarkers, D-dimer	/	1) cerebral infarction 2) subdural haemorrhage 3) intracerebral haemorrhage 4) arteriovenous malformation, aneurysm and dural arteriovenous fistula 5) artery dissection 6) cerebral venous thrombosis 7) reversible cerebral vasoconstriction syndrome 8) pituitary apoplexy	/	Increased inflammatory biomarkers, xanthochromia	/	/
Non-vascular	Intracranial hypertension	/	/	Tumour	/	Increased pressure	/	Papilledema
	Intracranial hypotension	/	/	Enlargement of the pituitary, decreased mamillo-pontine distance, sagging of the brainstem and cerebellar tonsillar descent, smooth dural thickening and pachymeningeal contrast enhancement, distension of the dural venous sinuses and ventral spinal longitudinal epidural collection	/	Decreased pressure	/	/

Table 4 (continued)

	General laboratory (CRP, ESR, Leukocytes …)	**CGRP, PACAP …**	**Conventional imaging**	**Advanced imaging**	**CSF**	**EEG**	**Others**
Substance	lipopolysaccharide, VE-Cadherin, CGRP, HIF-1α, and IL-6, L-PGDS, VDBP and APOE.	/	/	Decreased gray matter volume and neurovascular coupling in the orbitofrontal cortex	/	/	Decreased cutaneous pain thresholds
Infection	Elevated CRP, ESR and leukocytes (more pronounced elevation in bacterial infections) Lymphocytosis or lymphopenia in viral infections Increase in absolute neutrophil count in bacterial infections Microscopy, culture, serological or PCR molecular tests to detect the infectious agent		T2/FLAIR hyperintense parenchymal signal abnormality, leptomeningeal enhancement, ring enhancing lesions suggestive of brain abscess		<u>Bacterial infection:</u> -Appearance: turbid, purulent -Pressure: raised - WBC concentration (cells/uL): Raised (>100), predominantly neutrophils - Protein (g/L): raised (>1.0) CSF:serum glucose ratio: Very low <u>Viral infection:</u> -Appearance: clear -Pressure: normal or mildly raised - White blood cell concentration: Raised (<1000), predominantly lymphocytes - Protein: mildly raised (0.5–1.0) CSF:serum glucose ratio: Normal or slightly low		

Table 4 (continued)

		General laboratory (CRP, ESR, Leukocytes …)	CGRP, PACAP …	Conventional imaging	Advanced imaging	CSF	EEG	Others
Homeostasis	Sleep apnea syndrome							Overnight polysomnography is the gold standard (apnea-hypopnea index ≥ 5)
	Dialysis headache	Predialysis hypomagnesemia, hypernatremia may be present	Elevated basal plasma CGRP levels before dialysis and increased plasma substance P levels after dialysis					
	Headache attributed to pheochromocytoma (PCC)	Plasma free metanephrin level, 24 hour urinary testing for metanephrine and normetanephrine, vanillyl-mandelic acid and total cathecolamines		CT or MRI for tumour localization	[^{131} I] or [^{123} I] MIBG or [^{111}In] Pentetreotide scan or [^{18}F] DOPA PET to diagnose PCC			
	Headache attributed to pre-ecclampsia or ecclampsia	Urinary evaluation for proteinuria						
	Headache attributed to hypothyroidism	High serum thyroid-stimulating hormone and low free T4 levels						
	Cardiac headache	Myocardial enzymes, myocardial damage markers (Myoglobin, troponin I, CK-MB, B-type natriuretic peptide, N-terminal pro BNP)						Electrocardiography (ECG), 24-hour holter-ECG monitoring, nuclear cardiac stress testing or treadmill (to show the co-occurrence of headache and cardiac ischemia)
Craniofacial				Imaging evidence of lesions within the affected anatomical areas				
Psychiatric	There is no definite diagnostic biomarker							

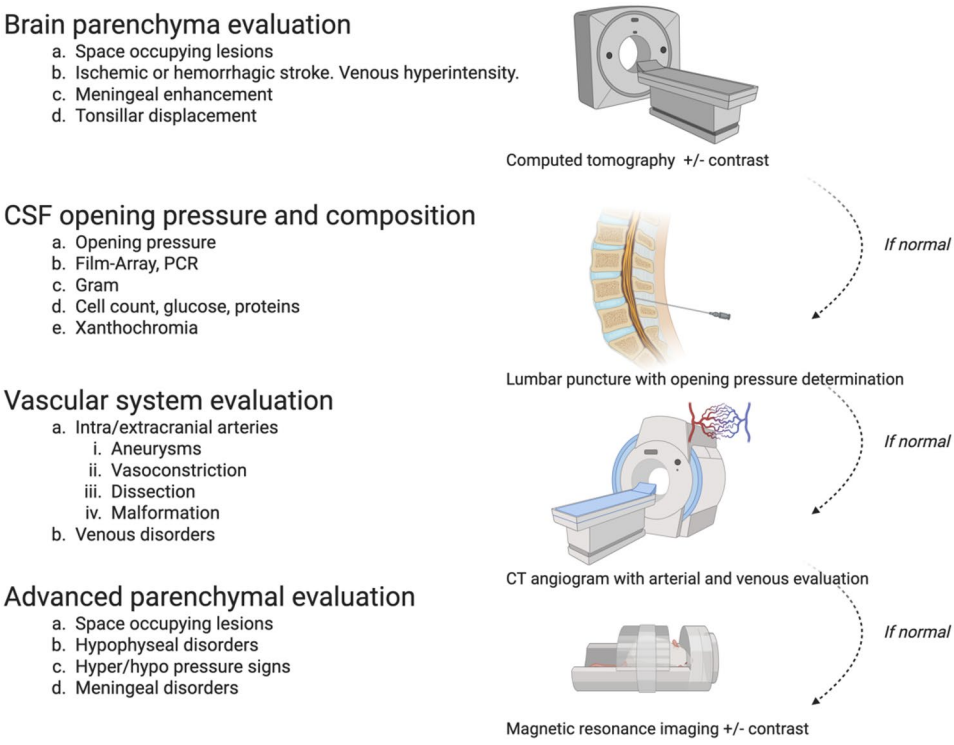

Fig. 3 Stepwise approach in secondary headache suspicion evaluation

Table 5 Diagnostic biomarkers for resource constrained settings

		Diagnostic biomarker
Trauma	Mild	Skull fractures on X-ray, periocular or retroauricular hematoma.
Vascular		Focal neurological symptoms and/or signs. Sudden onset
Non-vascular	Intracranial hypertension	Papilledema
	Intracranial hypotension	Precipitation of the headache following jugular vein compression
Substance		
Infection		Elevated CRP, ESR and leukocytes (more pronounced elevation in bacterial infections) Lymphocytosis or lymphopenia in viral infections Increase in absolute neutrophil count in bacterial infections Microscopy, culture, serological or PCR molecular tests to detect the infectious agent
Homeostasis	Sleep apnea syndrome	
	Dialysis headache	Predialysis hypomagnesemia, hypernatremia may be present
	Headache attributed to pheochromocytoma (PCC)	Blood
	Headache attributed to pre-eclampsia or ecclampsia	Urinary evaluation for proteinuria, blood pressure
	Headache attributed to hypothyroidism	High serum thyroid-stimulating hormone and low free T4 levels
	Cardiac headache	Myocardial enzymes, myocardial damage markers (Myoglobin, troponin I, CK-MB) , echocardiogram
Craniofacial		X-ray, otoscopy

In general, migraine is acutely managed in a step-up system involving simple analgesics, triptans, ditans, and gepants [253]. However, due to the vasoconstrictive properties of triptans, debate regarding their safety in individuals with vascular comorbidities continues [254]. This is especially true within the US market, where triptans remain contraindicated for individuals with significant vascular comorbidities [255]. Overall, triptans and ergots should be avoided in patients with a history of ischemic stroke, or high-risk vascular disorders, such as patients with high-grade cervical or intracranial artery stenosis, or coronary artery disease [255]. When accounting for this potential risk, alternative acute medications that are not associated with vasoconstriction such as lasmiditan

and gepants may be more suitable within this population [256–258]. Antiemetics could also be very helpful to manage acute headache in this population. In contrast, acute TTH-like headache is managed with simple analgesics [259]. For patients with subarachnoid haemorrhage from aneurysm rupture, headache is often acute and severe even if the aneurysm is secured. Studies have shown that gabapentin and pregabalin, when given in the hyperacute phase, could reduce the need for future acute headache medications during the recovery phase [260].

Acute treatment of headache attributed to non-vascular disorders

As there are no drugs specifically designed for headaches attributed to non-vascular intracranial disorders, regular use of analgesic medications has been recorded [261]. However, MOH is frequent in over a third of idiopathic intracranial hypertension (IIH) patients, therefore these patients will likely benefit from drug withdrawal [262]. Triptans are not recommended for headaches attributed to increase CSF pressure as they can further increase intracranial pressure (ICP) [263]. Secondary headaches attributed to low CSF pressure are initially treated conservatively, followed by pharmacological agents such as simple analgesics, corticosteroids, or caffeine [264], although the available evidence of efficacy remains limited. Acute specific treatment for secondary headaches attributed to non-infectious inflammatory conditions, intracranial neoplasms, and epileptic seizures has also been unexplored, thus treating the underlying cause should be considered the main goal in managing these conditions.

Acute treatment of headache attributed to a substance or its withdrawal

Optimal treatment often entails discontinuing the substance triggering the headache [113]. For acute symptomatic relief, NSAIDs may be employed if the headache is severe. Various acute medications with different mechanisms, like prednisolone, sodium valproate, and sumatriptan, have effectively stopped nitroglycerine-induced migraine as models of drug-induced headache [113, 265–267]. Management of MOH necessitates discontinuing the overused medication [268]. Outpatient detoxification may suit highly motivated individuals with brief overuse of simple analgesics and supportive familial surroundings. Inpatient withdrawal is advised for those overusing complex analgesics, enduring prolonged overuse, having prior outpatient withdrawal failures, or with psychiatric comorbidities. After detoxification, patients should receive clear instructions on the prudent use of acute medications [248], advising use solely during severe headaches and cautioning against anticipation. NSAIDs like naproxen and paracetamol are preferable due to their lower likelihood of inducing MOH [248].

Acute treatment of headache attributed to infection

Management of intracranial infection-related headaches involves infection-specific therapy, supportive measures, and analgesics [269]. Immediate antibiotic treatment is imperative for bacterial meningitis, with high-dose amoxicillin often adequate for community-acquired cases. While dexamethasone significantly reduces mortality and neurologic sequelae in bacterial meningitis, its impact on acute or chronic post-infection headaches remains uncertain [270]. Herpes simplex encephalitis necessitates prompt acyclovir administration (10 mg/kg body weight every 8 hours) [271], typically resulting in swift headache resolution. Simple analgesics like paracetamol, or nonsteroidal anti-inflammatory drugs (NSAIDs), are usually sufficient for intracranial infection-associated headaches, while specific migraine or cluster headache treatments are generally not recommended. In systemic infection-related headaches, targeted antimicrobial therapy is crucial, alongside antipyretics and NSAIDs. Patients predisposed to primary headache disorders experiencing infection-induced headaches should receive specific headache therapy. There's no established treatment for HIV-associated headaches [272], with the impact of highly active antiretroviral therapy (HAART) on headaches remains underexplored. Symptomatic relief with analgesics or NSAIDs is advised for HAART-related headaches. Long COVID syndrome often manifests with headaches, but treatment strategies rely on existing guidelines for primary headaches [273].

Acute treatment of headache attributed to homeostasis

For secondary headaches attributed to homeostatic disorders, pharmacological treatment involves simple analgesics such as paracetamol or NSAIDs [274]. There is a lack of evidence for specific acute treatments beyond addressing the underlying cause. For high-altitude headaches, antiemetics agents and acetazolamide are also recommended [274]. Triptans have been found to be effective when administered 30–60 min prior to travel in patients with risk of developing airplane headaches [274]. However, due to their established vasoconstrictive profile [275], triptans are not recommended for secondary headaches attributed to dialysis or arterial hypertension [276].

Acute treatment of headache or facial pain attributed to disorder of the cranium, neck, eyes, ears, nose, sinuses, teeth, mouth or other facial or cervical structure

Initial treatment for secondary headaches attributed to craniofacial disorders often involves the use of paracetamol and NSAIDs [277]. The evidence for using specific acute medications also remains limited.

However, preclinical research has shown that a CGRP receptor antagonist was effective in attenuating temporomandibular nociceptive transmission [278], which suggests that targeting CGRP signalling may be an efficacious approach to treat secondary headaches of craniofacial origin [278, 279].

Acute treatment of headache attributed to psychiatric disorders

The management of patients experiencing headaches related to psychiatric disorders typically involves a protracted journey characterized by the exploration of various medications through trial and error [280]. Initial attempts often involve the use of commonplace medications such as paracetamol and NSAIDs, while subsequent steps may entail the consideration of alternative medications tailored to address the underlying psychiatric condition [139].

The Table 6 summarizes the main therapies that can be beneficial in the acute treatment of secondary headache disorders.

Preventive treatment of secondary headache disorders

Pharmacological preventive interventions for secondary headaches are often based on what is recommended for primary headache disorders with similar phenotypes. However, evidence remains limited, encompassing small cohorts, varying observation periods, and mostly uncontrolled designs. In addition, treating the underlying cause should be considered the main goal in managing these conditions, whenever possible.

Preventive treatment of headache attributed to trauma or injury to the head and/or neck

Persistent posttraumatic headache, lasting beyond three months following head trauma, is commonly managed akin to migraine or tension-type headache, depending on the underlying phenotype [246, 281]. Pharmacotherapies explored in research include antidepressants such as amitriptyline or nortriptyline, anticonvulsants like topiramate, valproate or gabapentin, melatonin, and antihypertensive medications such as beta-blockers or calcium-channel blockers [282–285]. Preventive treatment is typically recommended if headache frequency exceeds eight days per month and significantly impacts the individual despite acute management [192]. Cumulative findings suggest that a 50% reduction in headache frequency can be achieved by 35–64% of patients after three months of treatment [192, 284]. Topiramate demonstrated the most favourable treatment response among US soldiers in one study [282], while melatonin and amitriptyline yielded the most promising outcomes in a paediatric study [284]. However, another study failed to observe any difference in outcomes with gabapentin or amitriptyline when compared to the absence of preventive treatment [283].

Expert recommendations also include CGRP(–receptor) monoclonal antibodies or onabotulinumtoxinA for migraine phenotype [192, 243]. Indeed, monoclonal antibodies targeting CGRP or its receptor, as well as onabotulinumtoxinA, have been tested for posttraumatic headache prevention. In a small randomized, placebo-controlled trial, participants receiving onabotulinumtoxinA according to the PREEMPT protocol experienced a decrease of −2.24 headache attacks per week compared to +1.28 with placebo over 16 weeks [286]. An open-label study involving 100 patients reported a reduction of −2.8 days with moderate or severe pain with erenumab during the third month of treatment [287]. Additional uncontrolled studies and case series have reported improvements in headache frequency, headache intensity and quality of in patients with persistent posttraumatic headache treated with CGRP(–receptor) antibodies or onabotulinumtoxinA [288–291]. Recent guidelines from the International Headache Society advocate for controlled clinical trials to establish evidence-based

Table 6 Summary of possible acute therapies for of secondary headache disorders

	Paracetamol	NSAIDs	Triptans	Lasmiditan	Gepants	Opioids	Other
5. Trauma	+	+	+	+	+	+	
6. Vascular	+	Av	Av	+	+	Av	
7. Non-vascular	+	+	-	-	-	-	Caffeine Corticosteroids
8. Substance	+	+	+	-	+	-	Prednisolone Valproate
9. Infection	+	+	-	-	-	-	Acyclovir, antibiotics
10. Homeostasis	+	+	-	-	-	-	Antiemetics Acetazolamide
11. Craniofacial	+	+	-	-	+	-	Physical therapy
12. Psychiatric	+	+	-	-	-	-	Psychotherapy

Av: Should be avoided. +: Have shown some possible benefit, -: have not shown benefit as of now. In the case of MOH, drugs are responsible for the disorder. The listed drugs in that category have been reported in some detoxification protocols.

approaches in the preventive treatment of posttraumatic headache [292].

Preventive treatment of headache attributed to cranial or cervical vascular disorders

Persistent secondary headaches following cranial or cervical vascular events are prevalent but understudied [293–296]. For instance, up to half of patients report headaches one year after ischemic or haemorrhagic stroke [297, 298]. Despite their common occurrence, evidence-based guidelines and randomized clinical trials for this type of headache are lacking. Recommendations for preventive treatment typically rely on the underlying phenotype [296, 299]. However, it should be noted that the use of CGRP(–receptor)-targeting therapies in patients with cerebrovascular disease should be carefully evaluated [293]. Although vascular disorders are not listed as a contraindication for CGRP-targeting therapies, given CGRP is a potent vasodilator, blocking CGRP could potentially affect vascular autoregulation if one were to have a stroke or myocardial infarction while being on CGRP targeting therapies. An animal study showed that mice pre-treated with olcegepant had higher risk of developing ischemic stroke syndrome (rather than having transient ischemic attack) and larger infarct volume after middle cerebral artery occlusion compared to mice treated with placebo [300]. Although no such evidence exists in humans, it has been reported that worsening or new onset hypertension and Raynaud's syndrome are potential side effects of CGRP monoclonal antibodies [301]. Currently, the consensus from experts is that CGRP targeting therapies should be avoided immediately after an acute vascular event, such as a major ischemic stroke or heart attack. However, it would be reasonable to consider CGRP-targeting therapies 6 months after the vascular event if the patient remains stable from a vascular perspective. It is imperative to contemplate treating the underlying disease whenever feasible, such as through surgical or endovascular interventions or pharmacotherapy. This includes for example glucocorticoids or steroid-sparing agents in giant cell arteritis [302], or surgical revascularization for moyamoya or other vascular malformations [17]. Interestingly, interventions for unruptured arteriovenous malformations did not demonstrate superiority over medical management in reducing headache occurrence over a 5-year observation period [303, 304].

Preventive treatment of headache attributed to non-vascular disorders

Preventive pharmacotherapies targeting the headache phenotype may also be considered for headaches attributed to non-vascular intracranial disorders. Based on consensus guidance, persistent headaches attributed to high CSF pressure (e.g., idiopathic intracranial hypertension, IIH) may be treated with topiramate, candesartan or onabotulinumtoxinA [262]. Topiramate may have additional advantages in IIH as it reduces intracranial pressure, however it should be avoided in pregnancy as it has been linked to higher rates of foetal abnormalities [305]. Moreover, the carbonic anhydrase inhibitor acetazolamide is often used to reduce the production of CSF and may have positive effects on IIH headache [306].

Recently, monoclonal antibodies targeting the CGRP receptor and glucagon-like-peptide-1 (GLP-1) agonists have been tested in IIH. An open-label study involving 55 patients reported a reduction of −8.0 monthly headache days with moderate or severe pain with erenumab during the third month of treatment [307]. Similarly, in a small randomized, placebo-controlled trial, participants receiving exenatide, a GLP-1 receptor agonist, experienced a significant decrease of −7.7 monthly headache days compared to −1.5 with placebo, nonetheless there was no significant difference between arms at 12 weeks [308].

The pharmacological preventive treatment of persistent secondary headaches attributed to low CSF pressure, non-infectious inflammatory conditions, intracranial neoplasms, and epileptic seizures is unexplored. Thus, treating the underlying cause remains the main goal in managing these secondary headaches.

Preventive treatment of headache attributed to a substance or its withdrawal

Secondary headaches attributed to exposure or abuse of a substance can also be caused by withdrawal [1]. They are defined as a headache caused by exposure to a substance, the onset of which occurs immediately or within hours after exposure [132, 231]. Some substances can lead to headache regardless of the presence or absence of an underlying headache disorder. Caffeine, nicotine, oestrogen, and opioid withdrawal are the most well-known factors in the development of headache [112, 132, 309, 310]. In this context, we can also consider MOH, which is a complex entity associated with overuse of pain medications by patients with primary headaches [311].

The most effective treatment is to stop exposure to the substance that is responsible for the headache. In some cases - particularly those associated with psychological addiction - additional therapy is required to speed up the recovery process, which should be purely symptomatic and tailored to the headache phenotype [311]. Simultaneous cessation of substance use, and prophylactic therapy with extensive education on the harmful consequences of addiction is considered the cornerstone of management of this type of headache [311–321].

Preventive treatment of headache attributed to infection

Headache associated with infection occurs in close temporal relationship with the infectious disease and it usually resolves after effective treatment or spontaneous resolution of an infection [1]. Most often, headache of a tension-type or migraine phenotype resolves after emergency treatment. However, prophylactic treatment may be necessary when headaches associated with the infection persist after the infection has resolved [312]. The most clinical observations in this regard have been provided by the COVID-19 pandemic and observations on the effect of the severe acute respiratory syndrome coronavirus 2 (SARS-CoV2) virus on headaches [313, 314]. When a long-COVID headache develops, treatment is dependent on the headache phenotype and includes known groups of antidepressants, antiepileptic drugs and, in refractory cases, even trials of other advanced therapies [315]. The effectiveness of treatment also depends on whether or not the infection-related headaches have developed in patients with pre-existing primary headaches [273].

Preventive treatment of headache attributed to homeostasis

For secondary headaches attributed to homeostatic disorders, there is a lack of evidence for specific preventive treatments beyond addressing the underlying cause. For dialysis headache, potential preventive treatments include chlorpromazine before dialysis, angiotensin-converting enzyme inhibitors like lisinopril, nortriptyline, and magnesium oxide [316].

Preventive treatment of headache or facial pain attributed to disorder of the cranium, neck, eyes, ears, nose, sinuses, teeth, mouth or other facial or cervical structure

The evidence for using preventive medications for secondary headaches attributed to craniofacial disorders is also restrictive. However, based on the shared sensory innervation of the craniofacial region, drugs targeting CGRP in the trigeminal ganglion could represent a common denominator for headache and craniofacial pain processing [317]. Therefore, the use of CGRP(–receptor) monoclonal antibodies or CGRP receptor antagonists should be explored on secondary headaches originating from the oral and craniofacial structures, such as temporomandibular disorders (TMD) [279].

Preventive treatment of headache attributed to psychiatric disorders

Headache attributed to psychiatric disorders is one of the newest categories of secondary headache [1]. In the past, the contribution of psychological factors to headache disorders was identified only as "psychiatric comorbidity." The current conceptualization of the term suggests an association, more than coincidental, but probably not causal [280]. However, it is difficult to delineate the direct cause of headaches especially in patients whose primary headaches coexist with a psychiatric illness. In such cases, a multidisciplinary approach to treatment is important, which should safeguard both psychiatric and neurological conditions. Preventive treatment - ideally based on as few drugs as possible - should be supported by psychological therapy [318, 319].

The Table 7 summarizes the therapies that could be considered for treating patients with persistent headache attributed to a secondary cause.

Outlook, future directions, and conclusion

Secondary headache disorders can represent an important challenge for the clinician and demand thorough evaluation and proper recognition. Ruling out a secondary cause of a headache is the first step in the evaluation of every headache patient, including those with prior history of primary headache disorders. There are many different causes of secondary headache, with variable clinical presentations, biomarkers, prognosis, and treatment, and therefore, establishing the right diagnosis is key. Research on secondary headache disorders is still more limited than primary headache disorders, however, they open a window of opportunity to better understand the pathophysiology of some primary headache disorders, as they show what are the consequences of the lesions of each of the different parts of the neuroanatomical pathways involved in pain modulation and processing. The contribution of secondary headache disorders to the global burden of headache is usually eclipsed by primary headache disorders; notwithstanding, these represent the only cause of headache-associated mortality and a largely prominent part of the headache-related morbidity [320]. Besides mortality, disability attributed to secondary headache disorders and its economic impact in the society are probably within the hidden part of the iceberg. Promising technologies and therapies are about to arrive, and in many cases these may cover existing gaps in secondary headache diagnosis and management. More research is needed in the secondary headache area, in order to improve their phenotypic characterization, develop effective and applicable biomarkers and identify potential treatments that may alleviate the suffering of patients and avoid negative consequences.

Table 7 Treatments with (potential) evidence in the prevention of secondary headaches

	Proportion of patients who become chronic	Preventive treatments (specific or unspecific)	Oral treatments	Local treatments (blockades & botulinumtoxin)	Anti-CGRP	Others
Trauma	23–58%	Unspecific	Based on phenotype	Onabotulinumtoxin A?	CGRP(–receptor) mAbs?	—
Vascular	Post-stroke: 10–51% Post-SAH: 30% Post-cerebral venous thrombosis: 59% Post-RCVS: 44–53%	Both specific and unspecific	Based on phenotype	—	—	Interventional/surgical procedures Treatment of underlying disease
Non-vascular	IIH: 57%	Both specific and unspecific	Based on phenotype		CGRP(–receptor) mAbs and antagonists?	Exenatide Treatment of underlying cause
Substance	—	Both specific and unspecific	—	—	—-	Cessation of substance exposure
Infection	—	Both specific and unspecific	Based on phenotype	—	—	Treatment of underlying disease
Homeostasis	—	—	–	—	—	Treatment of underlying disease
Craniofacial	TMD: 6–29%	—	—	—	CGRP(–receptor) mAbs and antagonists?	Treatment of underlying cause
Psychiatric	—	Both specific and unspecific	—	—	—-	Treatment of underlying disease

SAH: Subarachnoid haemorrhage. RCVS: Reversible cerebral vasoconstriction syndrome. IIH: Idiopathic intracranial hypertension. TMD: Temporomandibular disorders.

Abbreviations

CADASIL	Cerebral autosomal dominant arteriopathy with subcortical infarcts and leukoencephalopathy
CGRP	Calcitonin gene-related peptide
COVID-19	Coronavirus disease 2019
CRP	C-reactive protein
CSD	Cortical spreading depolarization
CSF	Cerebrospinal fluid
CT	Computed tomographic
CTA	Computed tomographic angiography
DH	Dialysis headache
DWI	Diffusion weighted imaging
ECG	Electrocardiography
EEG	Electroencephalography
ESR	Erythrocyte sedimentation rate
FLAIR	Fluid-attenuated inversion recovery
GLP-1	Glucagon-like-peptide-1
HAART	Highly active antiretroviral therapy
ICHD	International Classification of Headache Disorders
ICP	Intracranial pressure
IIH	Idiopathic intracranial hypertension
IL	Interleukin
MOH	Medication overuse headache
MRA	Magnetic resonance angiography
MRI	Magnetic resonance imaging
NAC	N-acetyl cisteine
NDPH	New daily persistent headache
NRM	Nucleus raphe magnus
NS	Neurosarcoidosis
NSAID	Non-steroidal anti-inflammatory drugs
PACAP	Pituitary adenylate cyclase activating polypeptide
PAG	Periaqueductal gray area
PCC	Pheochromocytoma
PCR	Polymerase chain reaction
PTH	Posttraumatic headache
RCVS	Reversible cerebral vasoconstriction syndrome
SAH	Subarachnoid hemorrhage
SARS-COV2	Severe acute respiratory syndrome coronavirus 2
SIH	Spontaneous intracranial hypotension
SNOT-22	Sino-Nasal Outcome Test-22
TBI	Traumatic brain injury
TMD	Temporomandibular disorders
TNC	Trigeminal nucleus caudalis
TVS	Trigeminovascular system

Acknowledgements
The authors are thankful to prof. Martelletti for their confidence and support as junior editorial board members.

Authors contributions
DGA designed the manuscript outline. All authors contributed to the conception of the work. All authors drafted the work and reviewed it critically for important intellectual content and approved the final version. All authors agreed to be accountable for all aspects of the work in ensuring that questions related to the accuracy or integrity of any part of the work are appropriately investigated and resolved.

Funding
Not applicable.

Data availability
No datasets were generated or analysed during the preparation of the present manuscript.

Declarations

Ethics approval and consent to participate
Not applicable.

Consent for publication
Not applicable.

Competing interests
The authors declare no competing interests.

Author details
[1]Department of Neurology, Hospital Universitario del Río Hortega, Calle Dulzaina 2, Valladolid 47012, Spain
[2]Department of Medicine, Toxicology and Dermatology, Faculty of Medicine, University of Valladolid, Valladolid, Spain
[3]Internal Medicine Unit, Eastern Hospital, ASL Taranto, Taranto, Italy
[4]Department of Molecular Physiology and Biophysics, University of Iowa, Iowa City, IA 52242, USA
[5]Department of Biotechnological and Applied Clinical Sciences, University of L'Aquila, L'Aquila, Italy
[6]Department of Physiotherapy and Rehabilitation, Faculty of Health Sciences Yozgat Bozok University, Yozgat, Türkiye
[7]Department of Neurology, Wroclaw Medical University, Wroclaw, Poland
[8]Headache Center, Department of Neurology, Sir Run Run Shaw Hospital, School of Medicine, Zhejiang University, Hangzhou, China
[9]Neuroimaging Research Unit and Neurology Unit, Division of Neuroscience, IRCCS San Raffaele Scientific Institute, Milan, Italy
[10]Vita-Salute San Raffaele University, Milan, Italy
[11]Department of Neurology and Algology, Neuroscience and Neurotechnology Center of Excellence (NÖROM), Neuropsychiatry Center, Gazi University Faculty of Medicine, Ankara, Türkiye
[12]Laboratory for Advanced Analysis of Neuroimages, Faculty of Physical Chemistry, University of Belgrade, Belgrade, Serbia
[13]School of Health, Unitelma Sapienza University of Rome, Rome, Italy
[14]Department of Neurology, Mayo Clinic, Rochester, MN, USA
[15]Clinical Pharmacology, Pharmacy and Environmental Medicine, Department of Public Health, University of Southern Denmark, Odense, Denmark
[16]Headache Group, Wolfson Sensory, Pain and Regeneration Centre, IoPPN, King's College London, London, UK
[17]Department of Neurology, Charité-Universitätsmedizin Berlin, corporate member of Freie Universität Berlin and Humboldt-Universität zu Berlin, Berlin, Germany
[18]Division of Neuroscience, Faculty of Biology, Medicine, And Health; University of Manchester, Manchester, UK
[19]Geoffrey Jefferson Brain Research Centre, Manchester Academic Health Science Centre, Northern Care Alliance NHS Foundation Trust, University of Manchester, Manchester, UK

Received: 2 May 2025 / Accepted: 12 February 2026
Published online: 02 March 2026

References

1. Headache Classification Committee of the International Headache Society (2018) The International classification of headache disorders, 3rd edition. Cephalalgia 38(1):1–211. https://doi.org/10.1177/0333102417738202.
2. GBD, 2021 Diseases and Injuries Collaborators et al (2024) Global incidence, prevalence, years lived with disability (YLDs), disability-adjusted life-years (DALYs), and healthy life expectancy (HALE) for 371 diseases and injuries in 204 countries and territories and 811 subnational locations, 1990-2021. a systematic analysis for the Global Burden of Disease Study 2021. Lancet 403(10440): 2133-2161. https://doi.org/10.1016/S0140-6736(24)00757-8.
3. Brouwer MC, Coutinho JM, van de Beek D (2014) Clinical characteristics and outcome of brain abscess: systematic review and meta-analysis. Neurology 82(9):806–813. https://doi.org/10.1212/WNL.0000000000000172.
4. Harriott AM, Karakaya F, Ayata C (2020) Headache after ischemic stroke: a systematic review and meta-analysis. Neurology 94(1):e75–e86. https://doi.org/10.1212/WNL.0000000000008591.
5. Herrero Babiloni A, Bouferguene Y, Exposto FG et al (2023) The prevalence of persistent post-traumatic headache in adult civilian traumatic brain injury: a systematic review and meta-analysis on the past 14 years. Pain 164(12):2627–2641. https://doi.org/10.1097/j.pain.0000000000002949
6. Stovner LJ, Hagen K, Linde M et al (2022) The global prevalence of headache: an update, with analysis of the influences of methodological factors on prevalence estimates. J Headache Pain 23(1):34. https://doi.org/10.1186/s10194-022-01402-2.
7. Garcia-Azorin D, Layos-Romero A, Porta-Etessam J et al (2022) Post-COVID-19 persistent headache: a multicentric 9-months follow-up study of 905 patients. Cephalalgia 42(8):804–809. https://doi.org/10.1177/03331024211068074.
8. Ashina H, Dodick DW, Barber J et al (2023) Prevalence of and risk factors for post-traumatic headache in civilian patients after mild traumatic brain injury: a TRACK-TBI study. Mayo Clin Proc 98(10):1515–1526. https://doi.org/10.1016/j.mayocp.2023.02.026.
9. de Oliveira FAA, Dourado-Filho MG, Sampaio Rocha-Filho PA (2024) Persistent headache attributed to past ischemic stroke: a prospective cohort study. Headache 64(1):48–54. https://doi.org/10.1111/head.14668.
10. López JT, García-Azorín D, Planchuelo-Gómez Á et al (2020) Phenotypic characterization of acute headache attributed to SARS-CoV-2: an ICHD-3 validation study on 106 hospitalized patients. Cephalalgia 40(13):1432–1442. https://doi.org/10.1177/0333102420965146.
11. García-Azorín D, Santana-López L, Lozano-Alonso JE et al (2023) InfluenCEF study: clinical phenotype and duration of headache attributed to influenza infection. Cephalalgia 43(11):3331024231212900. https://doi.org/10.1177/03331024231212900.
12. Robertson CE, Benarroch EE (2023) The anatomy of head pain. Handb Clin Neurol 198:41–60. https://doi.org/10.1016/B978-0-12-823356-6.00001-9.
13. Fontaine D, Almairac F, Santucci S et al (2018) Dural and pial pain-sensitive structures in humans: new inputs from awake craniotomies. Brain 141(4):1040–1048. https://doi.org/10.1093/brain/awy005.
14. Levy D (2012) Endogenous mechanisms underlying the activation and sensitization of meningeal nociceptors: the role of immuno-vascular interactions and cortical spreading depression. Curr Pain Headache Rep 16(3):270–277. https://doi.org/10.1007/s11916-012-0255-1.
15. Ebersberger A (2001) Physiology of meningeal innervation: aspects and consequences of chemosensitivity of meningeal nociceptors. Microsc Res Tech 53(2):138–146. https://doi.org/10.1002/jemt.1078.
16. Khan S, Amin FM, Christensen CE et al (2019) Meningeal contribution to migraine pain: a magnetic resonance angiography study. Brain 142:93–102. https://doi.org/10.1093/brain/awy300.
17. Chiang CC, Shahid AH, Harriott AM et al (2022) Evaluation and treatment of headache associated with moyamoya disease - a narrative review. Cephalalgia 42:542–552. https://doi.org/10.1177/03331024211056250.
18. Canac N, Jalaleddini K, Thorpe SG et al (2020) Pathophysiology of intracranial hypertension and noninvasive intracranial pressure monitoring: a review. Fluids Barriers CNS 17(1):40. https://doi.org/10.1186/s12987-020-00201-8.
19. Edvinsson L et al (2017) The trigeminovascular pathway: role of CGRP and CGRP receptors in migraine. Headache 57(S2):47–55.
20. White TG, Powell K, Shah S et al (2021) Trigeminal nerve control of cerebral blood flow: a brief review. Front. Neurosci 15:649910.
21. McCulloch J, Uddman R, Kingman T et al (1986) Calcitonin gene-related peptide: functional role in cerebrovascular regulation. Proc Natl Acad Sci U S A 83(15):5731–5735.
22. Juul R, Edvinsson L, Jansen I et al (1994) Calcitonin gene-related peptide (human α-CGRP) counteracts vasoconstriction in human subarachnoid haemorrhage. Neurosci Lett 170(1):67–70.
23. Schebesch KM, Wendl C, Brawanski A et al (2013) Calcitonin-gene related peptide and cerebral vasospasm. J Clin Neurosci 20(4):584–586.
24. Juul R, Edvinsson L, Jansen I et al (1990) Calcitonin gene-related peptide-LI in subarachnoid haemorrhage in man: signs of activation of the trigemino-cerebrovascular system? Br J Neurosurg 4(3):171–179.
25. Hoffmann O, Weber JR, Bendszus M et al (2002) Triptans reduce the inflammatory response in bacterial meningitis. J Cereb Blood Flow Metab 22(8):988–996.
26. Berg RM, Møller K, Hansen JM et al (2009) Circulating levels of vasoactive peptides in patients with acute bacterial meningitis. Intensive Care Med 35(9):1604–1608.
27. Nicholson P, Mollan SP, Sinclair AJ et al (2021) Idiopathic intracranial hypertension: glymphedema of the brain. J Neuroophthalmol 41(1):93–97.
28. Fargen KM, Spiotta AM, Turner RD et al (2023) "Idiopathic" intracranial hypertension: an update from neurointerventional research for clinicians. Cephalalgia 43(4):03331024231161323.
29. De Simone R, Mariani S, Ranieri A et al (2022) The putative role of trigemino-vascular system in brain perfusion homeostasis and the significance of the migraine attack. Neurol. Sci 43(9):5665–5672.
30. Ak AK, Yildiz B, Demirci A et al (2024) Calcitonin gene-related peptide (CGRP) levels in peripheral blood in patients with idiopathic intracranial hypertension and migraine. Clin Neurol Neurosurg 237:108136.
31. Nowak DA, Takano B, Topka H (2006) Spontaneous cerebrospinal fluid hypovolaemia: a therapeutic dilemma? Eur J Neurol 13(10):1128–1138.

32. Chen HC, Fuh JL, Lirng JF et al (2017) Quantitative measurement of CSF in patients with spontaneous intracranial hypotension. Am J Neuroradiol 38(5):1061.
33. Deen M, Correnti E, Kamm K et al (2017) Blocking CGRP in migraine patients - a review of pros and cons. J Headache Pain 18(1):96.
34. Tian J, Shi X, Wang Y et al (2020) Exogenous CGRP regulates apoptosis and autophagy to alleviate traumatic brain injury through Akt/mTOR signalling pathway. Neurochem Res 45(12):2926–2938.
35. Eggertsen PP, Kristoffersen ES, Sand T et al (2024) Serum calcitonin gene-related peptide in patients with persistent post-concussion symptoms, including headache: a cohort study. J Neurol 271(5):2458–2472.
36. Chen LX, Qiu T, Lu CX et al (2018) Relationship of calcitonin gene-related peptide with disease progression and prognosis of patients with severe traumatic brain injury. Neural Regen Res 13(10):1782–1786.
37. Ashina H, Schytz HW, Ashina M et al (2020) Low plasma levels of calcitonin gene-related peptide in persistent post-traumatic headache attributed to mild traumatic brain injury. Cephalalgia 40(12):1276–1282.
38. Navratilova E, Rau J, Manjavachi MN et al (2019) CGRP-dependent and independent mechanisms of acute and persistent post-traumatic headache following mild traumatic brain injury in mice. Cephalalgia 39(14):1762–1775.
39. Leung A (2020) Addressing chronic persistent headaches after MTBI as a neuropathic pain state. J Headache Pain 21(1):77.
40. Zhao J, Levy D (2014) The sensory innervation of the calvarial periosteum is nociceptive and contributes to headache-like behavior. PAIN 155(7).
41. La Mantia L, Prone V (2015) Headache in multiple sclerosis and autoimmune disorders. Neurol. Sci 36(1):75–78.
42. Gentile S, Ferrero M, Vaula G et al (2007) Cluster headache attacks and multiple sclerosis. J Headache Pain 8(4):245–247.
43. González-Quintanilla V, Oterino A, Toriello M et al (2012) Cluster-tic syndrome as the initial manifestation of multiple sclerosis. J Headache Pain 13(5):425–429.
44. Pelikan JB, McCombe JA, Kotylak T et al (2016) Cluster headache as the index event in MS: a case report. Headache 56(2):392–396.
45. Donat J (2012) A patient with cluster headache-due to a brainstem lesion. Headache 52(6):1035–1036.
46. Mijajlović MD, Aleksić VM, Covičković Šternić NM (2014) Cluster headache as a first manifestation of multiple sclerosis: case report and literature review. Neuropsychiatr Dis Treat 10:2269–2274.
47. Fiore A, Franzini A, Messina G et al (2021) Secondary cluster headache due to a contralateral demyelinating periaqueductal gray matter lesion. Headache 61(7):1136–1139.
48. Gee JR, Chang J, Davenport E et al (2005) The association of brainstem lesions with migraine-like headache: an imaging study of multiple sclerosis. Headache 45(6):670–677.
49. Lin GY, Wang CW, Chiang TT et al (2013) Multiple sclerosis presenting initially with a worsening of migraine symptoms. J Headache Pain 14(1):70.
50. Jansem P, Duprez T, Maillard L et al (2024) A SUNCT-like headache associated with lateral pontine infarction - case series and systematic review. Eur J Pain 8:1402–1410. https://doi.org/10.1002/ejp.2261.
51. Messé A, Caplain S, Paradot G et al (2013) Specific and evolving resting-state network alterations in post-concussion syndrome following mild traumatic brain injury. PLoS One 8(6):e65470.
52. Alhilali LM, Delic J, Fakhran S (2017) Differences in callosal and forniceal diffusion between patients with and without postconcussive migraine. Am J Neuroradiol 38(4):691–695.
53. Mac Donald CL, Johnson AM, Cooper D et al (2011) Detection of blast-related traumatic brain injury in U.S. military personnel. N Engl J Med 364(22):2091–2100.
54. Miller DR, Hayes JP, Lafleche G et al (2016) White matter abnormalities are associated with chronic postconcussion symptoms in blast-related mild traumatic brain injury. Hum Brain Mapp 37(1):220–229.
55. Schwedt TJ, Chong CD, Peplinski J et al (2017) Persistent post-traumatic headache vs. migraine: an MRI study demonstrating differences in brain structure. J Headache Pain 18(1):87.
56. Obermann M, Nebel K, Schumann C et al (2009) Gray matter changes related to chronic posttraumatic headache. Neurology 73(12):978–983.
57. Kopruszinski CM, Navratilova E, Vagnerová B et al (2021) CGRP monoclonal antibody prevents the loss of diffuse noxious inhibitory controls (DNIC) in a mouse model of post-traumatic headache. Cephalalgia 41(6):749–759.
58. Ossipov MH, Morimura K, Porreca F (2014) Descending pain modulation and chronification of pain. Curr Opin Support Palliat Care 8(2):143–151.
59. Elliott MB, Johnson KM, Taylor SE et al (2012) Nociceptive neuropeptide increases and periorbital allodynia in a model of traumatic brain injury. Headache 52(6):966–984.
60. Dagistan Y, Kilinc E, Balci CN (2019) Cervical sympathectomy modulates the neurogenic inflammatory neuropeptides following experimental subarachnoid hemorrhage in rats. Brain Res 1722:146366.
61. Buonvicino D, Ranieri G, Lazzeri G et al (2018) Trigeminal ganglion transcriptome analysis in 2 rat models of medication-overuse headache reveals coherent and widespread induction of pronociceptive gene expression patterns. Pain 159(10).
62. Grech O, Sinclair AJ, Davies B et al (2022) Nuclear magnetic resonance spectroscopy metabolomics in idiopathic intracranial hypertension to identify markers of disease and headache. Neurology 99(16):e1702–e 1714.
63. Ball AK, Sinclair AJ, Brock K et al (2009) Elevated cerebrospinal fluid (CSF) leptin in idiopathic intracranial hypertension (IIH): evidence for hypothalamic leptin resistance? Clin Endocrinol (Oxf) 70(6):863–869.
64. Lampl Y, Eshel Y, Sviri G et al (2002) Serum leptin level in women with idiopathic intracranial hypertension. J Neurol, Neurosurg Psychiatry 72(5):642–643.
65. Belli A, McGinn MJ, Finn T et al (2008) Metabolic failure precedes intracranial pressure rises in traumatic brain injury: a microdialysis study. Acta Neurochir (Wien) 150(5):461–470.
66. Nagel A, Graupner T, Schubert GA et al (2009) Relevance of intracranial hypertension for cerebral metabolism in aneurysmal subarachnoid hemorrhage: clinical article. J Neurosurg 111(1):94–101.
67. Biousse V, Woimant F, Touboul PJ et al (1994) Head pain in non-traumatic carotid artery dissection: a series of 65 patients. Cephalalgia 14(1):33–36.
68. Kamtchum Tatuene J, Noubiap JJ, Bigna JJ et al (2015) Putative pathophysiological mechanisms in recurrent hemicrania from aortic dissection: a case report. BMC Res Notes 8(1):246.
69. Stöllberger C, Finsterer J, Slany J et al (1998) Headache as the initial manifestation of acute aortic dissection type a. Cephalalgia 18(8):583–584.
70. Reglodi D, Tamas A, Somogyvari-Vigh A et al (2008) Protective effects of PACAP in ischemia. J Headache Pain 19(1):19.
71. Vittorini MG, Marini C, Rossi C et al (2024) The glymphatic system in migraine and other headaches. J Headache Pain 25(1):34.
72. Iliff JJ, Wang M, Liao Y et al (2014) Impairment of glymphatic pathway function promotes tau pathology after traumatic brain injury. J Neurosci 34(49):16180–16193.
73. Potewiratnanond P, Srikiatkhachorn A, le Grand SM et al (2019) Altered activity in the nucleus raphe magnus underlies cortical hyperexcitability and facilitates trigeminal nociception in a rat model of medication overuse headache. BMC Neurosci 20(1):54.
74. Supornsilpchai W, le Grand SM, Srikiatkhachorn A (2010) Cortical hyperexcitability and mechanism of medication-overuse headache. Cephalalgia 30(9):1101–1109.
75. Hartings JA, Strong AJ, Dreier JP et al (2016) The continuum of spreading depolarizations in acute cortical lesion development: examining Leão's legacy. J Cereb Blood Flow Metab 37(5):1571–1594.
76. Wang Y, Zhao J, Chen JY et al (2019) Induction of calcitonin gene-related peptide expression in rats by cortical spreading depression. Cephalalgia 39(3):333–341.
77. Yan J, Zhang X, Wang Y et al (2023) Dynamic measurements of cerebral blood flow responses to cortical spreading depolarization in the murine endovascular perforation subarachnoid hemorrhage model. Transl Stroke Res 14(4):530–544.
78. Zhang X, Levy D, Noseda R et al (2011) Activation of central trigeminovascular neurons by cortical spreading depression. Ann Neurol 69(5):855–865.
79. Frugier T, Morganti-Kossmann MC, O'Reilly D et al (2010) In situ detection of inflammatory mediators in post mortem human brain tissue after traumatic injury. J. Neurotrauma 27(3):497–507.
80. Gursoy-Ozdemir Y, Yemisci M, Dalkara T (2004) Cortical spreading depression activates and upregulates MMP-9. J. Clin. Invest 113(10):1447–1455.
81. Levy D, Burstein R, Kainz V et al (2016) Responses of dural mast cells in concussive and blast models of mild traumatic brain injury in mice: potential implications for post-traumatic headache. Cephalalgia 36(10):915–923.
82. Defrin R, Ohry A, Blumen N et al (2010) Quantitative somatosensory testing of subjects with chronic post-traumatic headache: implications on its mechanisms. Eur J Pain 14(9):924–931.
83. Roth TL, Nayak D, Atanasijevic T et al (2014) Transcranial amelioration of inflammation and cell death after brain injury. Nature 505(7482):223–228.

84. Hoffer ME, Balaban C, Slade MD et al (2013) Amelioration of acute sequelae of blast-induced mild traumatic brain injury by N-acetyl cysteine: A double-blind, placebo-controlled study. PLoS One 8(1):e54163.
85. Pinho-Ribeiro FA, Deng L, Neel DV et al (2023) Bacteria hijack a meningeal neuroimmune axis to facilitate brain invasion. Nature 615(7952):472–481. https://doi.org/10.1038/s41586-023-05753-x.
86. Lucas S, Hoffman JM, Bell KR, Dikmen S (2014) A prospective study of prevalence and characterization of headache following mild traumatic brain injury. Cephalalgia 34:93.
87. Mavroudis I, Ciobica A, Luca AC, Balmus IM (2023) Post-traumatic headache: a review of prevalence, clinical features, risk factors, and treatment strategies. J Clin Med 12(13):4233.
88. Kraemer Y, Mäki K, Marinkovic I et al (2022) Post-traumatic headache after mild traumatic brain injury in a one-year follow-up study - risk factors and return to work. J Headache Pain 23(1):27.
89. Yilmaz T, Roks G, de Koning M et al (2017) Risk factors and outcomes associated with post-traumatic headache after mild traumatic brain injury. Emerg Med J 34:800.
90. Vanderploeg RD, Belanger HG, Horner RD et al (2012) Health outcomes associated with military deployment: mild traumatic brain injury; blast; trauma; and combat associations in the Florida National guard. Arch Phys Med Rehabil 93:1887–1895.
91. Maleki N, Finkel A, Cai G et al (2019) Post-traumatic headache: epidemiology and pathophysiological insights. Nat Rev Neurol 15:607.
92. Benemei S, Labastida-Ramírez A, Abramova E et al (2020) European headache Federation School of Advanced studies(EHF-SAS). Persistent post-traumatic headache: a migrainous loop or not? The preclinical evidence. J Headache Pain 21(1):90.
93. Kjeldgaard D, Forchhammer H, Teasdale T, Jensen RH (2014) Chronic post-traumatic headache after mild head injury: a descriptive study. Cephalalgia 34:191–200.
94. Seifert T (2016) Post-traumatic headache therapy in the athlete. Curr Pain Headache Rep 20(6):41.
95. Elkind AH (1989) Headache and facial pain associated with head injury. Otolaryngol Clin N Am 22(6):1251–1271.
96. Carolei A, Sacco S (2010) Headache attributed to stroke, TIA, intracerebral haemorrhage, or vascular malformation. Handb Clin Neurol 97:517–528.
97. Harriott AM, Karakaya F, Ayata C (2020) Headache after ischemic stroke: a systematic review and meta-analysis. Neurology 94:e75–e86. https://doi.org/10.1212/WNL.0000000000008591.
98. Ling ML, Yosar J, Lee BW et al (2020) The diagnosis and management of temporal arteritis. Clin Exp Optom 103:572–582. https://doi.org/10.1111/cxo.12975.
99. Wang MM (2018) CADASIL. Handb Clin Neurol 148:733–743.
100. Mokri B (2015) Spontaneous intracranial hypotension. Continuum (Minneap Minn) 21(4 Headache):1086–1108.
101. Tana C, Caulo M, Tafuri E et al (2014) Teaching neuroimages: a dangerous complication of spontaneous intracranial hypotension. Neurology 82(11):e94–e95.
102. Raoof N, Hoffmann J (2021) Diagnosis and treatment of idiopathic intracranial hypertension. Cephalalgia 41(4):472–478. https://doi.org/10.1177/0333102421997093.
103. Sina F, Razmeh S, Habibzadeh N et al (2017) Migraine headache in patients with idiopathic intracranial hypertension. Neurol Int 9(3):7280. https://doi.org/10.4081/or.2017.7280.
104. Bsteh G, Macher S, Krajnc N et al (2023) Idiopathic intracranial hypertension presenting with migraine phenotype is associated with unfavorable headache outcomes. Headache 63(5):601–610. https://doi.org/10.1111/head.14478.
105. Digre KB, Nakamoto BK, Warner JE et al (2009) A comparison of idiopathic intracranial hypertension with and without papilledema. Headache 49(2):185–193. https://doi.org/10.1111/j.1526-4610.2008.01324.x.
106. Wall M, Kupersmith MJ, Kieburtz KD et al (2014) NORDIC idiopathic intracranial hypertension study Group. The idiopathic intracranial hypertension treatment trial: clinical profile at baseline. JAMA Neurol 71(6):693–701. https://doi.org/10.1001/jamaneurol.2014.133.
107. Barkatullah AF, Leishangthem L, Moss HE (2021) MRI findings as markers of idiopathic intracranial hypertension. Curr Opin Neurol 34(1):75–83.
108. Mollan SP, Davies B, Silver NC et al (2018) Idiopathic intracranial hypertension: consensus guidelines on management. J Neurol, Neurosurg Psychiatry 89(10):1088–1100. https://doi.org/10.1136/jnnp-2017-317440.
109. Tana C, Azorin DG, Cinetto F et al (2023) Common clinical and molecular pathways between migraine and sarcoidosis. Int J Mol Sci 24(9):8304.
110. Tana C, Wegener S, Borys E et al (2015) Challenges in the diagnosis and treatment of neurosarcoidosis. Ann Med 47(7):576–591.
111. Tana C, Donatiello I, Caputo A et al (2021) Clinical features, histopathology and differential diagnosis of sarcoidosis. Cells 11(1):59.
112. Obermann M, Katsarava Z (2024) Headache attributed to a substance or its withdrawal. Neurol Clin 42(2):497–506. https://doi.org/10.1016/j.ncl.2023.12.005.
113. Toom K, Braschinsky M, Obermann M, Katsarava Z (2021) Secondary headache attributed to exposure to or overuse of a substance. Cephalalgia 41(4):443–452. https://doi.org/10.1177/0333102420942238.
114. García-Azorín D, Aparicio-Cordero L, Talavera B et al (2020) Clinical characterization of delayed alcohol-induced headache: a study of 1, 108 participants. Neurology 95(15):e2161–e2169. https://doi.org/10.1212/WNL.0000000000010607.
115. Do TP, Remmers A, Schytz HW et al (2019) Red and orange flags for secondary headaches in clinical practice: SNNOOP10 list. Neurology 92(3):134–144. https://doi.org/10.1212/WNL.0000000000006697.
116. Gosalia H, Moreno-Ajona D, Goadsby PJ (2024) Medication-overuse headache: a narrative review. J Headache Pain 25(1):89. https://doi.org/10.1186/s10194-024-01755-w.
117. Berkowitz AL (2021) Approach to neurologic infections. Continuum (Minneap Minn) 27(4):818–835.
118. García-Azorín D, Santana-Lopez L, Ordax-Diez A et al (2024) Incidence and prevalence of headache in influenza: a 2010–2021 surveillance-based study. Eur J Neurol e16349.
119. Mitsikostas DD, Caronna E, De Tommaso M et al (2024) Headaches and facial pain attributed to SARS-CoV-2 infection and vaccination: a systematic review. Eur J Neurol 31(6):e16251.
120. García-Azorín D, Trigo J, Talavera B et al (2020) Frequency and type of red flags in patients with covid-19 and headache: a series of 104 hospitalized patients. Headache 60(8):1664–1672. https://doi.org/10.1111/head.13927.
121. Garcia-Azorin D, Santana-Lopez L, Lozano-Alonso JE et al (2023) InfluenCEF study: clinical phenotype and duration of headache attributed to influenza infection. Cephalalgia 43(11):3331024231212900.
122. Mainardi F, Maggioni F, Zanchin G (2019) Headache attributed to aeroplane travel: an historical outline. Headache 59(2):164–172.
123. Mainardi F, Maggioni F, Zanchin G (2023) Efficacy of a long-term acting triptan for headache attributed to aeroplane travel: a case report. Neurol. Sci 44(7):2547–2549.
124. Burkett JG, Nahas SJ (2019) Diving headache. Curr Pain Headache Rep 23(7):46.
125. Shen C, Ou Y, Ouyang R, Zong D (2023) Prevalence and characteristics of pain in moderate-to-severe obstructive sleep apnea patients and effect of CPAP treatment. Sci Rep 13(1):15758.
126. Sousa Melo E, Carrilho Aguiar F, Sampaio Rocha-Filho PA (2017) Dialysis headache: a narrative review. Headache 57(1):161–164.
127. Tepper DE, Tepper SJ, Sheftell FD, Bigal ME (2007) Headache attributed to hypothyroidism. Curr Pain Headache Rep 11(4):304–309.
128. Arca KN, Halker Singh RB (2019) The hypertensive headache: a review. Curr Pain Headache Rep 23(5):30.
129. Finocchi C, Sassos D (2017) Headache and arterial hypertension. Neurol. Sci 38(Suppl 1):67–72.
130. Torelli P, Evangelista A, Bini A et al (2009) Fasting headache: a review of the literature and new hypotheses. Headache 49(5):744–752.
131. Bini A, Evangelista A, Castellini P et al (2009) Cardiac cephalgia. J Headache Pain 10(1):3–9.
132. Navarro-Pérez MP, Espinosa-Rueda J, Ballesta-Martínez S et al (2023) Prevalence, clinical characteristics and associated factors of cardiac cephalalgia: a prospective study. Cephalalgia 43(4):3331024231160743. https://doi.org/10.1177/03331024231160743.
133. Navarro-Pérez MP, Santos-Lasaosa S, Olesen J (2023) Evaluation of the ICHD-3 diagnostic criteria for cardiac cephalalgia and new proposal. Cephalalgia 43(11):3331024231202243. https://doi.org/10.1177/03331024231202243.
134. Robblee J, Secora KA (2021) Debunking myths: sinus headache. Curr Neurol Neurosci Rep 21(8):42.
135. Piovesan EJ, Utiumi MAT, Grossi DB (2024) Cervicogenic headache - how to recognize and treat. Best Pract Res Clin Rheumatol 101931.
136. Gray ST, Phillips KM, Hoehle LP et al (2017) The 22-item Sino-Nasal Outcome Test accurately reflects patient-reported control of chronic rhinosinusitis symptomatology. Int Forum Allergy Rhinol 7(10):945–951.

137. Farhood Z, Schlosser RJ, Pearse ME et al (2016) Twenty-two-item Sino-Nasal Outcome Test in a control population: a cross-sectional study and systematic review. Int Forum Allergy Rhinol 6(3):271–277.
138. List T, Jensen RH (2017) Temporomandibular disorders: old ideas and new concepts. Cephalalgia 37(7):692–704.
139. Smitherman TA, Baskin SM (2008) Headache secondary to psychiatric disorders. Curr Pain Headache Rep 12(4):305–310.
140. Dresler T, Caratozzolo S, Guldolf K et al (2019) Understanding the nature of psychiatric comorbidity in migraine: a systematic review focused on interactions and treatment implications. J Headache Pain 20(1):51.
141. Lance JW (1981) Headache. Ann Neurol 10(1):1–10.
142. Cady RK (2014) Red flags and comfort signs for ominous secondary headaches. Otolaryngol Clin N Am 47(2):289–299. https://doi.org/10.1016/j.otc.2013.10.010.
143. Lassman A, DeAngelis L (2003) Brain metastases. Neurol Clin 21(1):1–23.
144. Nelson S, Taylor LP (2014) Headaches in brain tumor patients: primary or secondary? Headache 54(4):776–785.
145. Fang X, Liang Y, Chen D et al (2017) A study on clinicoradiological characteristics and pregnancy outcomes of reversible posterior leukoencephalopathy syndrome in preeclampsia or eclampsia. Hypertens Res 40(12):982–987.
146. García-Azorín D, González-García N, Abelaira-Freire J et al (2021) Management of thunderclap headache in the emergency room: a retrospective cohort study. Cephalalgia 41(6):711–720. https://doi.org/10.1177/0333102420981721.
147. Martín-Dávila P, Blanes M, Fortún J (2007) Immunosuppression and infection in transplant recipients. Enferm Infecc Microbiol Clin 25(2):143–154.
148. Mea E, Savoiardo M, Chiapparini L et al (2007) Headache and spontaneous low cerebrospinal fluid pressure syndrome. Neurol. Sci 28(Suppl 2):S232–S234.
149. Andersen AM, Ashina H, Iljazi A et al (2020) Risk factors for the development of post-traumatic headache attributed to traumatic brain injury: a systematic review. Headache 60(6):1066–1075.
150. Pfund Z, Szapáry L, Jászberényi O, Nagy F, Czopf J (1999) Headache in intracranial tumors. Cephalalgia 19(9):787–790.
151. Farooque U, Okorie N, Kataria S et al (2020) Cocaine-induced headache: a review of pathogenesis, presentation, diagnosis, and management. Cureus 12(8):e10128.
152. Fofi L, Orlandi V, Vanacore N et al (2014) Headache in chronic cocaine users: a cross-sectional study. Cephalalgia 34(9):671–678.
153. Tentschert S, Wimmer R, Greisenegger S, Lang W, Lalouschek W (2005) Headache at stroke onset in 2196 patients with ischemic stroke or transient ischemic attack. Stroke 36(2):e1–e3.
154. Mehta A, Danesh J, Kuruvilla D (2019) Cerebral venous thrombosis headache. Curr Pain Headache Rep 23(7):47.
155. Rushton JG, Rooke ED (1992) Brain tumor headache. Headache 2:147–152.
156. Ing EB, Lahaie Luna G, Pagnoux C et al (2019) The incidence of giant cell arteritis in Ontario, Canada. Can J Ophthalmol 54(1):119–124.
157. Christiaans MH, Kelder JC, Arnoldus EPJ et al (2002) Prediction of intracranial metastasis in cancer patients with headache. Cancer 94(7):2063–2068.
158. Morgestern LB, Luna-Gonzales H, Huber JC et al (1998) Worst headache and subarachnoid hemorrhage: prospective, modern computed tomography and fluid analysis. Ann Emerg Med 32(3):297–304.
159. Komro J, Findakly D (2020) Cerebral venous sinus thrombosis in adults with prothrombotic conditions: a systematic review and a case from our institution. Cureus 12(4):e 7654.
160. Sparaco M, Feleppa M, Bigal ME (2015) Cerebral venous thrombosis and headache - a case series. Headache 55(6):806–814.
161. Wakerley BR, Tan MH, Ting EY (2015) Idiopathic intracranial hypertension. Cephalalgia 35(3):248–261.
162. Pfund Z, Szapáry L, Jászberényi O et al (1999) Headache in intracranial tumors. Cephalalgia 19(9):787–790.
163. Capizzano AA, Lai L, Kim J et al (2016) Atypical presentations of intracranial hypotension: comparison with classic spontaneous intracranial hypotension. AJNR Am J Neuroradiol 37(7):1256–1261.
164. Prakash S, Rathore C, Makwana P, Dave A (2016) A cross-sectional clinic-based study in patients with side-locked unilateral headache and facial pain. Headache 56(7):1183–1193.
165. González-Quintanilla V, Madera J, Pascual J (2023) Update on headaches associated with physical exertion. Cephalalgia 43(3):3331024221146989. https://doi.org/10.1177/03331024221146989.
166. Limper M, Eeftinck Schattenkerk D, de Kruif MD et al (2011) One-year epidemiology of fever at the emergency department. Neth J Med 69(3):124–128.
167. Sergott RC (2012) Headaches associated with papilledema. Curr Pain Headache Rep 16(4):354–358. https://doi.org/10.1007/s11916-012-0283-x.
168. Marrodan M, Bensi C, Alessandro L et al (2018) Chronic and subacute meningitis: differentiating neoplastic from non-neoplastic etiologies. Neurohospitalist 8(4):177–182.
169. Jin D, Lian YJ, Zhang HF (2016) Secondary SUNCT syndrome caused by dorsolateral medullary infarction. J Headache Pain 17:12.
170. Rodríguez S, Calleja S, Morís G (2008) Cluster-like headache heralding cerebral venous thrombosis. Cephalalgia 28(8):906–907.
171. Wang JZ, Vyas MV, Saposnik G, Burneo JG (2017) Incidence and management of seizures after ischemic stroke: systematic review and meta-analysis. Neurology 89(12):1220–1228.
172. de Bruijn SF, de Haan RJ, Stam J (2001) Cerebral venous sinus thrombosis study Group. Clinical features and prognostic factors of cerebral venous sinus thrombosis in a prospective series of 59 patients. J Neurol, Neurosurg Psychiatry 70(1):105–108.
173. Fugate JE, Rabinstein AA (2015) Posterior reversible encephalopathy syndrome: clinical and radiological manifestations, pathophysiology, and outstanding questions. The Lancet Neurol 14(9):914–925.
174. Zoons E, Weisfelt M, de Gans J et al (2008) Seizures in adults with bacterial meningitis. Neurology 70(22 Pt 2):2109–2115.
175. Amanat M, Thijs RD, Salehi M, Sander JW (2019) Seizures as a clinical manifestation in somatic autoimmune disorders. Seizure 64:59–64.
176. Wilne SH, Ferris RC, Nathwani A, Kennedy CR (2006) The presenting features of brain tumours: a review of 200 cases. Arch Dis Child 91(6):502–506.
177. Hermann R, Debeaupte M, Durbec M (2017) Headache and diplopia. Eur Ann Otorhinolaryngol Head Neck Dis 134(1):55–56. https://doi.org/10.1016/j.anorl.2016.09.001.
178. Shinohara Y (2009) Hemorrhagic stroke syndromes: clinical manifestations of intracerebral and subarachnoid hemorrhage. Handb Clin Neurol 93:577–594.
179. García-Azorín D, Abelaira-Freire J, González-García N et al (2022) Sensitivity of the SNNOOP10 list in the high-risk secondary headache detection. Cephalalgia 42(14):1521–1531. https://doi.org/10.1177/03331024221120249.
180. Im HJ, Baek SH, Yun CH, Chu MK (2019) Time preference of headache attack and chronotype in migraine and tension-type headache. Chronobiol Int 36(11):1528–1536. https://doi.org/10.1080/07420528.2019.1658202.
181. Kamourieh S, Rozen T, Anderson JM (2024) Status migrainosus. Handb Clin Neurol 199:413–439. https://doi.org/10.1016/B978-0-12-823357-3.00017-3.
182. Filler L, Akhter M, Nimlos P (2019) Evaluation and management of emergency department headache. Semin Neurol 39(1):20–26.
183. Pohl H, Do TP, García-Azorín D et al (2021) Green flags and headache: a concept study using the delphi method. Headache 61(2):300–309. https://doi.org/10.1111/head.14054.
184. Wijeratne T, Wijeratne C, Korajkic N et al (2023) Secondary headaches - red and green flags and their significance for diagnostics. eNeurologicalsci 32:100473. https://doi.org/10.1016/j.ensci.2023.100473.
185. Ramirez-Lassepas M, Espinosa CE, Cicero JJ et al (1997) Predictors of intracranial pathologic findings in patients who seek emergency care because of headache. Arch Neurol 54(12):1506–1509.
186. Sobri M, Lamont AC, Alias AN, Win MN (2003) Red flags in patients presenting with headache: clinical indications for neuroimaging. The Br J Radiol 76(908):532–535.
187. Locker TE, Thompson C, Rylance J, Mason SM (2006) The utility of clinical features in patients presenting with nontraumatic headache: an investigation of adult patients attending an emergency department. Headache 46(6):954–961.
188. Bo SH, Davidsen EM, Gulbrandsen P, Dietrichs E (2008) Acute headache: a prospective diagnostic work-up of patients admitted to a general hospital. Eur J Neurol 15(12):1293–1299.
189. Singh Rai G, Rai T, Jain L et al (2016) Evaluation of CT and MRI findings among patients presented with chief complaint of headache in central India. J Clin Diagn Res 10(2):TC21–TC25.
190. Young NP, Elrashidi MY, McKie PM, Ebbert JO (2018) Neuroimaging utilization and findings in headache outpatients: significance of red and yellow flags. Cephalalgia 38(12):1841–1848. https://doi.org/10.1177/0333102418758282.
191. Munoz-Ceron J, Marin-Careaga V, Peña L, Mutis J, Ortiz G (2019) Headache at the emergency room: etiologies, diagnostic usefulness of the ICHD 3 criteria, red and green flags. PLoS One 14(1):e0208728.
192. Ashina H, Eigenbrodt AK, Seifert T et al (2021) Post-traumatic headache attributed to traumatic brain injury: classification, clinical characteristics, and treatment. The Lancet Neurol 20:460–469.

193. Maas AIR, Menon DK, Manley GT et al (2022) Traumatic brain injury: progress and challenges in prevention, clinical care, and research. The Lancet Neurol 21:1004–1060.
194. Ríos L, Mata-Escolano F, Blanco-Pérez E et al (2017) Acute headache attributed to whiplash in arcuate foramen and non-arcuate foramen subjects. Eur Spine J 26:1262–1265.
195. Sarmento E, Moreira P, Brito C et al (2009) Proton spectroscopy in patients with post-traumatic headache attributed to mild head injury. Headache 49:1345–1352.
196. Nikolova S, Schwedt TJ, Li J et al (2022) T2 reduction in patients with acute post-traumatic headache. Cephalalgia 42:357–365.
197. Ofoghi Z, Dewey D, Barlow KM (2020) A systematic review of structural and functional imaging correlates of headache or pain following mild traumatic brain injury. J. Neurotrauma 37:907–923.
198. Alhilali LM, Delic J, Fakhran S (2017) Differences in callosal and forniceal diffusion between patients with and without postconcussive migraine. Am J Neuroradiol 38:691–695.
199. Niu X, Bai L, Sun Y et al (2019) Disruption of periaqueductal grey-default mode network functional connectivity predicts persistent post-traumatic headache in mild traumatic brain injury. J Neurol, Neurosurg Psychiatry 90:326–332.
200. Burrowes SAB, Rhodes CS, Meeker TJ et al (2020) Decreased grey matter volume in mTBI patients with post-traumatic headache compared to headache-free mTBI patients and healthy controls. Brain Imag Behav 14:1651–1659.
201. Mao L, Li J, Schwedt TJ et al (2023) Questionnaire and structural imaging data accurately predict headache improvement in patients with acute post-traumatic headache attributed to mild traumatic brain injury. Cephalalgia 43:3331024231172736.
202. Starling AJ, Jarvis N, Schwedt TJ (2019) Cutaneous head pain and light-induced pain thresholds in post-traumatic headache attributed to mild traumatic brain injury. Abstract OR14. Headache 59:13–14.
203. Starling AJ, Cortez MM, Jarvis NR et al (2022) Cutaneous heat and light-induced pain thresholds in post-traumatic headache attributed to mild traumatic brain injury. Headache 62:726–736.
204. Schwedt TJ (2021) Post-traumatic headache due to mild traumatic brain injury: current knowledge and future directions. Cephalalgia 41:464–471.
205. Kapoor S (2013) Headache attributed to cranial or cervical vascular disorders. Curr Pain Headache Rep 17:334.
206. Jadhav AP, Jovin TG (2012) Vascular imaging of the head and neck. Semin Neurol 32:401–410.
207. Molad J, Hallevi H, Korczyn AD et al (2021) The interrelation between chronic headache, cognitive scores, and MRI markers among stroke survivors. J Alzheimers Dis 81(4):1555–1566. https://doi.org/10.3233/JAD-210077.
208. Cheema S, Anderson J, Angus-Leppan H et al (2023) Multidisciplinary consensus guideline for the diagnosis and management of spontaneous intracranial hypotension. J Neurol, Neurosurg Psychiatry 94:835–843.
209. Friedman DI, Liu GT, Digre KB (2013) Revised diagnostic criteria for the pseudotumor cerebri syndrome in adults and children. Neurology 81:1159–1165.
210. Rehder D (2020) Idiopathic intracranial hypertension: review of clinical syndrome, imaging findings, and treatment. Curr Probl Diagn Radiol 49(3):205–214. https://doi.org/10.1067/j.cpradiol.2019.02.012.
211. Bsteh G, Marik W, Krajnc N et al (2023) MRI features of idiopathic intracranial hypertension are not prognostic of visual and headache outcome. J Headache Pain 24:97.
212. Palmieri A, Valentinis L, Zanchin G (2021) Update on headache and brain tumors. Cephalalgia 41(4):431–437. https://doi.org/10.1177/03331024209743 51.
213. Schankin CJ, Krumbholz M, Sostak P et al (2010) Headache in patients with a meningioma correlates with a bone-invasive growth pattern but not with cytokine expression. Cephalalgia 30(4):413–424. https://doi.org/10.1111/j.1468-2982.2009.01945.x.
214. Valentinis L, Tuniz F, Valent F et al (2010) Headache attributed to intracranial tumours: a prospective cohort study. Cephalalgia 30(4):389–398. https://doi.org/10.1111/j.1468-2982.2009.01970.x.
215. Rendon LF, Malta S, Leung J et al (2023) Cocaine and ischemic or hemorrhagic stroke: a systematic review and meta-analysis of clinical evidence. J Clin Med 12(16):5207. https://doi.org/10.3390/jcm12165207.
216. Wang T, Zhang Y, Gu Y et al (2022) Neurological sequelae in acute carbon monoxide poisoning: a prospective observational study with MRI data. Acta Neurol Scand 145(5):590–598. https://doi.org/10.1111/ane.13587.
217. Geibprasert S, Gallucci M, Krings T (2010) Alcohol-induced changes in the brain as assessed by MRI and CT. Eur Radiol 20(6):1492–1501. https://doi.org/10.1007/s00330-009-1668-z.
218. Lai TH, Chou KH, Fuh JL et al (2016) Gray matter changes related to medication overuse in patients with chronic migraine. Cephalalgia 36:1324–1333.
219. Li X, Liu M, Fan W et al (2023) Altered cerebral neurovascular coupling in medication-overuse headache: a study combining multi-modal resting-state fMRI with 3D PCASL. Front. Neurosci 17:1139086.
220. Vuralli D, Akgor MC, Dagidir HG et al (2024) Lipopolysaccharide, VE-cadherin, HMGB1, and HIF-1α levels are elevated in the systemic circulation in chronic migraine patients with medication-overuse headache: evidence of leaky gut and inflammation. J Headache Pain 25:23.
221. Pellesi L, Bellei E, Guerzoni S et al (2019) Exploration of candidate serum biomarkers potentially related to the chronic pain condition in medication-overuse headache. BMC Neurol 19:239.
222. Marchioni E, Minoli L (2010) Headache attributed to infections: nosography and differential diagnosis. Handb Clin Neurol 97:601–626. https://doi.org/10.1016/s0072-9752(10)97052-8.
223. Gladstone J, Bigal ME (2010) Headaches attributable to infectious diseases. Curr Pain Headache Rep 14(4):299–308. https://doi.org/10.1007/s11916-010-0125-7.
224. Melbye H, Hvidsten D, Holm A et al (2004) The course of C-reactive protein response in untreated upper respiratory tract infection. Br J Gen Pract 54(506):653–658.
225. Guo Z, Zhang Z, Prajapati M et al (2021) Lymphopenia caused by virus infections and the mechanisms beyond. Viruses 13(9). https://doi.org/10.3390/v13091876.
226. Al-Gwaiz LA, Babay HH (2007) The diagnostic value of absolute neutrophil count, band count and morphologic changes of neutrophils in predicting bacterial infections. Med Princ Pract 16(5):344–347. https://doi.org/10.1159/000104806.
227. van de Beek D, de Gans J, Spanjaard L et al (2004) Clinical features and prognostic factors in adults with bacterial meningitis. N Engl J Med 351(18):1849–1859. https://doi.org/10.1056/NEJMoa040845.
228. Logan SA, MacMahon E (2008) Viral meningitis. BMJ 336(7634):36–40. https://doi.org/10.1136/bmj.39409.673657.AE.
229. Kumar R (2020) Understanding and managing acute encephalitis. F1000Res 9. https://doi.org/10.12688/f1000research.20634.1.
230. McGill F, Heyderman RS, Panagiotou S et al (2016) Acute bacterial meningitis in adults. Lancet 388(10063):3036–3047. https://doi.org/10.1016/s0140-6736(16)30654-7.
231. McCullagh K, Castillo M, Zamora C (2022) Headache attributed to non-vascular intracranial disorder: neoplasms, infections, and substance abuse. Neurol Clin 40(3):531–546. https://doi.org/10.1016/j.ncl.2022.02.005.
232. Ellul M, Solomon T (2018) Acute encephalitis: Diagnosis and management. Clin Med (Lond)18(2):155–159. https://doi.org/10.7861/clinmedicine.18-2-155.
233. Breen PH (2001) Arterial blood gas and pH analysis: clinical approach and interpretation. Anesthesiol Clin N Am 19(4):885–906, x. https://doi.org/10.1016/s0889-8537(01)80014-6.
234. Laratta CR, Ayas NT, Povitz M et al (2017) Diagnosis and treatment of obstructive sleep apnea in adults. CMAJ 189(48):E1481–E1488. https://doi.org/10.1503/cmaj.170296.
235. Alessandri M, Massanti L, Geppetti P et al (2006) Plasma changes of calcitonin gene-related peptide and substance P in patients with dialysis headache. Cephalalgia 26(11):1287–1293. https://doi.org/10.1111/j.1468-2982.2006.01217.x.
236. Pappachan JM, Raskauskiene D, Sriraman R et al (2014) Diagnosis and management of pheochromocytoma: a practical guide to clinicians. Curr Hypertens Rep 16(7):442. https://doi.org/10.1007/s11906-014-0442-z.
237. Ilias I, Pacak K (2004) Current approaches and recommended algorithm for the diagnostic localization of pheochromocytoma. J Clin Endocrinol Metab 89(2):479–491. https://doi.org/10.1210/jc.2003-031091.
238. Chaker L, Bianco AC, Jonklaas J et al (2017) Hypothyroidism. Lancet 390(10101):1550–1562. https://doi.org/10.1016/s0140-6736(17)30703-1.
239. Xu J, Mao N, Wang C et al (2022) Clinical analysis of 30 cases of cardiac cephalalgia. Cephalalgia 42(9):926–932. https://doi.org/10.1177/03331024221088993.
240. Zhu K, Born DW, Dilli E (2020) Secondary headache: current update. Headache 60(10):2654–2664. https://doi.org/10.1111/head.13986.

241. Nouri A, Tetreault L, Singh A et al (2015) Degenerative cervical myelopathy: epidemiology, genetics, and pathogenesis. Spine (Phila Pa 1976) 40(12):E675–E693. https://doi.org/10.1097/brs.0000000000000913.
242. Green MW (2011) Headaches: psychiatric aspects. Neurol Clin 29(1):65–80. https://doi.org/10.1016/j.ncl.2010.10.004 vii.
243. Ashina H, Dodick DW (2022) Post-traumatic headache: pharmacologic management and targeting CGRP signaling. Curr Neurol Neurosci Rep 22:105–111.
244. Minen MT, Mahmood N, Khan F et al (2024) Treatment options for posttraumatic headache: a current review of the literature. Curr Pain Headache Rep 28:205–210.
245. Bello C, Andereggen L, Luedi MM Beilstein CM(2022) postcraniotomy headache: etiologies and treatments. Curr Pain Headache Rep 26:357–364.
246. Larsen EL, Ashina H, Iljazi A et al (2019) Acute and preventive pharmacological treatment of post-traumatic headache: a systematic review. J Headache Pain 20:98.
247. Schwedt TJ, Buse DC, Argoff CE et al (2021) Medication overuse and headache burden: results from the CaMEO study. Neurol Clin Pract 11:216–226.
248. Ashina S, Terwindt GM, Steiner TJ et al (2023) Medication overuse headache. Nat Rev Dis Primers 9:5.
249. Rothrock JF, Diener HC (2021) Headache secondary to cerebrovascular disease. Cephalalgia 41:479–492.
250. Suri H, Dougherty C (2019) Presentation and management of headache in pituitary apoplexy. Curr Pain Headache Rep 23:61.
251. Lu J, Liu W, Zhao H (2020) Headache in cerebrovascular diseases. Stroke Vasc Neurol 5:205–210.
252. Lebedeva ER, Ushenin AV, Gurary NM et al (2022) Persistent headache after first-ever ischemic stroke: clinical characteristics and factors associated with its development. J Headache Pain 23:103.
253. Eigenbrodt AK, Ashina H, Khan S et al (2021) Diagnosis and management of migraine in ten steps. Nat Rev Neurol 17:501–514.
254. Benemei S, Cortese F, Labastida-Ramírez A et al (2017) Triptans and CGRP blockade - impact on the cranial vasculature. J Headache Pain 18:103.
255. Dodick DW, Shewale AS, Lipton RB et al (2020) Migraine patients with cardiovascular disease and contraindications: an analysis of real-world claims data. J Prim Care Community Health 11:2150132720963680.
256. Altamura C, Brunelli N, Marcosano M, Fofi L, Vernieri F (2022) Gepants - a long way to cure: a narrative review. Neurol. Sci 43:5697–5708.
257. Schwedt TJ, Lipton RB, Ailani J et al (2022) Time course of efficacy of atogepant for the preventive treatment of migraine: results from the randomized, double-blind ADVANCE trial. Cephalalgia 42:3–11.
258. Shapiro RE, Hochstetler HM, Dennehy EB et al (2019) Lasmiditan for acute treatment of migraine in patients with cardiovascular risk factors: post-hoc analysis of pooled results from 2 randomized, double-blind, placebo-controlled phase 3 trials. J Headache Pain 20:90.
259. Ashina S, Mitsikostas DD, Lee MJ et al (2021) Tension-type headache. Nat Rev Dis Primers 7:24.
260. Sorrentino ZA, Laurent D, Hernandez J et al (2022) Headache persisting after aneurysmal subarachnoid hemorrhage: a narrative review of pathophysiology and therapeutic strategies. Headache 62:1120–1132. https://doi.org/10.1111/head.14394.
261. Mollan SP, Grech O, Sinclair AJ (2021) Headache attributed to idiopathic intracranial hypertension and persistent post-idiopathic intracranial hypertension headache: a narrative review. Headache 61:808–816.
262. Hoffmann J, Mollan SP, Paemeleire K et al (2018) European headache Federation guideline on idiopathic intracranial hypertension. J Headache Pain 19:93.
263. Nilsson F, Nilsson T, Edvinsson L et al (1996) Sumatriptan-induced cerebral vasoconstriction as treatment of experimental intracranial hypertension. Acta Anaesthesiol Scand 40:612–620.
264. García-Ull J, González-García N, Torres-Ferrús M et al (2025) Diagnosis and treatment of disorders of intracranial pressure: consensus statement of the Spanish Society of Neurology's headache study Group. Neurologí(Engl Ed) 40:118–137. https://doi.org/10.1016/j.nrleng.2024.02.009.
265. Thomaides T, Karapanayiotides T, Kerezoudi E et al (2008) Intravenous valproate aborts glyceryl trinitrate-induced migraine attacks: a clinical and quantitative EEG study. Cephalalgia 28:250–256.
266. Luthringer R, Djupesland PG, Sheldrake CD et al (2009) Rapid absorption of sumatriptan powder and effects on glyceryl trinitrate model of headache following intranasal delivery using a novel bi-directional device. The J Pharm Pharmacol 61:1219–1228.
267. Tfelt-Hansen P, Daugaard D, Lassen LH et al (2009) Prednisolone reduces nitric oxide-induced migraine. Eur J Neurol 16:1106–1111.
268. Vandenbussche N, Laterza D, Lisicki M et al (2018) Medication-overuse headache: a widely recognized entity amidst ongoing debate. J Headache Pain 19:50.
269. Cocores AN, Monteith TS (2022) Headache as a neurologic manifestation of systemic disease. Curr Treat Options Neurol 24:17–40.
270. de Gans J, van de Beek D (2002) Dexamethasone in adults with bacterial meningitis. N Engl J Med 347:1549–1556.
271. Taylor SW, Smith RM, Pari G et al (2005) Herpes simplex encephalitis. Can J Neurol Sci 32:246–247.
272. Sheikh HU, Cho TA (2014) Clinical aspects of headache in HIV. Headache 54:939–945.
273. Tana C, Bentivegna E, Cho SJ et al (2022) Long COVID headache. J Headache Pain 23:93.
274. Lagman-Bartolome AM, Im J, Gladstone J (2024) Headaches attributed to disorders of homeostasis. Neurol Clin 42:521–542.
275. Rubio-Beltrán E, Labastida-Ramírez A, Villalón CM, MaassenVandenbrink A (2018) Is selective 5-HT(1F) receptor agonism an entity apart from that of the triptans in antimigraine therapy? Pharmacol Ther 186:88–97.
276. Antoniazzi AL, Bigal ME, Bordini CA, Speciali JG (2003) Headache associated with dialysis: the International headache Society criteria revisited. Cephalalgia 23(2):146–149.
277. Romero-Reyes M, Uyanik JM (2014) Orofacial pain management: current perspectives. J Pain Res 7:99–115.
278. Akerman S, Romero-Reyes M (2020) Preclinical studies investigating the neural mechanisms involved in the co-morbidity of migraine and temporomandibular disorders: the role of CGRP. Br J Pharmacol 177:5555–5568.
279. Romero-Reyes M, Klasser G, Akerman S (2023) An update on temporomandibular disorders (TMDs) and headache. Curr Neurol Neurosci Rep 23:561–570.
280. Guidetti V, Galli F, Sheftell F (2010) Headache attributed to psychiatric disorders. Handb Clin Neurol 97:657–662.
281. Blumenfeld A, McVige J, Knievel K (2022) Post-traumatic headache: pathophysiology and management - a review. J Concussion 6:20597002221093478.
282. Erickson JC (2011) Treatment outcomes of chronic post-traumatic headaches after mild head trauma in US soldiers: an observational study. Headache 51:932–944.
283. Cushman DM, Borowski L, Hansen C et al (2019) Gabapentin and tricyclics in the treatment of post-concussive headache: a retrospective cohort study. Headache 59:371–382.
284. Kuczynski A, Crawford S, Bodell L et al (2013) Characteristics of post-traumatic headaches in children following mild traumatic brain injury and their response to treatment: a prospective cohort. Dev Med Child Neurol 55:636–641.
285. Kothari SF, Eggertsen PP, Frederiksen OV et al (2022) Characterization of persistent post-traumatic headache and management strategies in adolescents and young adults following mild traumatic brain injury. Sci Rep 12:2209.
286. Zirovich MD, Pangarkar SS, Manh C et al (2021) Botulinum toxin type a for the treatment of post-traumatic headache: a randomized, placebo-controlled, cross-over study. Mil Med 186:493–499.
287. Ashina H, Iljazi A, Al-Khazali HM et al (2020) Efficacy, tolerability, and safety of erenumab for the preventive treatment of persistent post-traumatic headache attributed to mild traumatic brain injury: an open-label study. J Headache Pain 21:62.
288. Buture A, Tomkins EM, Shukralla A et al (2023) Two-year, real-world erenumab persistence and quality of life data in 82 pooled patients with abrupt onset, unremitting, treatment refractory headache and a migraine phenotype: new daily persistent headache or persistent post-traumatic headache in the majority of cases. Cephalalgia 43:3331024231182126.
289. VanderEnde J, Bateman EA, MacKenzie HM, Sequeira K (2020) Use of CGRP receptor blocker erenumab in the management of post-traumatic headache: a case series of 5 women. Brain Inj 34:1431–1434.
290. Ferguson LP, Abdukalikov R, Shbeeb D, Gray TK (2020) Shot in the dark: three patients successfully treated with onabotulinumtoxin a injections for relief of post-traumatic chronic headaches and dystonia induced by gunshot wounds. BMJ Case Rep 13.
291. Yerry JA, Kuehn D, Finkel AG (2015) Onabotulinum toxin a for the treatment of headache in service members with a history of mild traumatic brain injury: a cohort study. Headache 55:395–406.
292. Ashina H, Diener HC, Tassorelli C et al (2024) Guidelines of the International headache Society for controlled trials of pharmacological preventive treatment for persistent post-traumatic headache attributed to mild traumatic brain injury. Cephalalgia 44:3331024241234068.

293. Chan M, Thaler A (2023) Post-stroke headache. Curr Pain Headache Rep 27:673–678.
294. Gaastra B, Carmichael H, Galea I, Bulters D (2022) Duration and characteristics of persistent headache following aneurysmal subarachnoid hemorrhage. Headache 62:1376–1382.
295. Bossoni AS, Peres MFP, Leite CDC et al (2022) Headache at the chronic stage of cerebral venous thrombosis. Cephalalgia 42:1476–1486.
296. Ling YH, Chen SP (2020) Narrative review: headaches after reversible cerebral vasoconstriction syndrome. Curr Pain Headache Rep 24:74.
297. Hansen AP, Marcussen NS, Klit H et al (2015) Development of persistent headache following stroke: a 3-year follow-up. Cephalalgia 35:399–409.
298. Carvalho Dias M, Martins T, BasílioG et al (2020) Headache at the chronic stage of ischemic stroke. Headache 60:607–614.
299. Plecash AR, Chebini A, Ip A et al (2019) Updates in the treatment of post-stroke pain. Curr Neurol Neurosci Rep 19:86.
300. Mulder IA, Li M, de Vries T et al (2020) Anti-migraine calcitonin gene-related peptide receptor antagonists worsen cerebral ischemic Outcome in mice. Ann Neurol 88(4):771–784. https://doi.org/10.1002/ana.25831.
301. Murray AM, Stern JI, Robertson CE, Chiang CC (2022) Real-world patient experience of CGRP-Targeting therapy for migraine: a narrative review. Curr Pain Headache Rep 26:783–794. https://doi.org/10.1007/s11916-022-01077-z.
302. Mollan SP, Paemeleire K, Versijpt J et al (2020) European headache Federation recommendations for neurologists managing giant cell arteritis. J Headache Pain 21:28.
303. Mohr JP, Parides MK, Stapf C et al (2014) Medical management with or without interventional therapy for unruptured brain arteriovenous malformations (ARUBA): a multicentre, non-blinded, randomised trial. Lancet 383:614–621.
304. Ellis JA, Mejia Munne JC, Lavine SD et al (2016) Arteriovenous malformations and headache. J Clin Neurosci 23:38–43.
305. Goyal A, Zarroli K (2023) Should topiramate be initial therapy in the management of idiopathic intracranial hypertension?: a literature review. Med (Baltim) 102:e35545.
306. Wall M, McDermott MP, Kieburtz KD et al (2014) Effect of acetazolamide on visual function in patients with idiopathic intracranial hypertension and mild visual loss: the idiopathic intracranial hypertension treatment trial. JAMA 311(16):1641–1651. https://doi.org/10.1001/jama.2014.3312.
307. Yiangou A, Mitchell JL, Fisher C et al (2021) Erenumab for headaches in idiopathic intracranial hypertension: a prospective open-label evaluation. Headache 61:157–169.
308. Mitchell JL, Lyons HS, Walker JK et al (2023) The effect of GLP-1RA exenatide on idiopathic intracranial hypertension: a randomized clinical trial. Brain 146:1821–1830.
309. Relja G, Granato A, Bratina A et al (2006) Outcome of medication overuse headache after abrupt in-patient withdrawal. Cephalalgia 26:589–595.
310. Hajdusianek W, Żórawik A, Waliszewska-Prosół M et al (2021) Tobacco and nervous system development and function-new findings 2015-2020. Brain Sci 11(6):797.
311. Ashina S, Terwindt GM, Steiner TJ et al (2023) Medication overuse headache. Nat Rev Dis Primers 9(1):5.
312. Walter SM, Laderman M, Polk P (2021) Pediatric headache attributed to infection. Semin Pediatr Neurol 40:100923.
313. Straburzyński M, Kuca-Warnawin E, Waliszewska-Prosół M (2023) COVID-19-related headache and innate immune response: a narrative review. Neurol Neurochir Pol 57(1):43–52.
314. Straburzyński M, Nowaczewska M, Budrewicz S, Waliszewska-Prosół M (2022) COVID-19-related headache and sinonasal inflammation: a longitudinal study analysing the role of acute rhinosinusitis and ICHD-3 classification difficulties in SARS-CoV-2 infection. Cephalalgia 42(3):218–228.
315. García-Azorín D, García-Ruiz C, Sierra-Mencía Á et al (2017) Acute and preventive treatment of COVID-19-related headache: a series of 100 patients. Life (Basel). 2024, 14(7):910.
316. Sousa Melo E, Carrilho Aguiar F, Sampaio Rocha-Filho PA Dialysis headache: a narrative review. Headache 57:161–164.
317. Edvinsson JCA, Viganò A, Alekseeva A et al (2020) The fifth cranial nerve in headaches. J Headache Pain 21:65.
318. McCracken HT, Lee AA, Smitherman TA (2023) Headache and psychological variables as predictors of disability in individuals with primary headache disorders. Headache 63(9):1259–1270.
319. ElGizy N, Khoweiled A, Khalil MA et al (2023) Migraine in bipolar disorder and schizophrenia: the hidden pain. Int J Psychiatry Med 58(6):605–616.
320. Raggi A, Leonardi M, Arruda M et al (2024) Hallmarks of primary headache: part 1 - migraine. J Headache Pain 25:189.
321. Carlsen LN, Munksgaard SB, Nielsen M et al (2020) Comparison of 3 treatment strategies for medication overuse headache: a randomized clinical trial. JAMA Neurol 77(9):1069–1078.

Publisher's Note

Springer Nature remains neutral with regard to jurisdictional claims in published maps and institutional affiliations.