CNN-RNN Hybrid Model for Intracranial Hemorrhage Detection and Subtype Classification

Naman Dhaval Desai
Chalmers
namand@chalmers.se

Jan Marten Winkler
Chalmers
janmarte@chalmers.se

***Abstract*—Intracranial hemorrhage (ICH) is a critical / life threatening condition that requires prompt and accurate diagnosis. This project focuses on ICH subtype classification across five categories, epidural, subdural, subarachnoid, intraventricular and intraparenchymal hemorrhages using a hybrid deep learning model trained on a subset of the Radiological Society of North America (RSNA) ICH dataset. A dedicated preprocessing pipeline was developed to generate 3D volumes from the available 2D computed tomography (CT) slices followed by selecting all 3 consecutive slices (triplets) which share the same label within these generated volumes. The proposed hybrid deep learning model follows a convolutional–recurrent architecture that integrates a ResNet backbone for spatial feature extraction with a Long Short-Term Memory (LSTM) network to capture sequential inter-slice dependencies within the triplets. The model was then trained and evaluated appropriately, where it demonstrated a strong classification performance as it achieved an average accuracy of approximately 91% and a mean Receiver Operating Characteristic (ROC) Area Under the Curve (AUC) value of 0.95 across the five subtypes.**

***Index Terms*—Intracranial hemorrhage (ICH), 3D computed tomography (CT) volumes, CNN-RNN hybrid model, ResNet-LSTM hybrid model, Multi-label classification**

I. Introduction

Intracranial hemorrhage (ICH) is a critical / life threatening condition that is caused by bleeding within the skull. It can result from trauma, hypertension, stroke, etc. and demands rapid and accurate diagnosis to reduce the patient's risk from developing severe complications and facing death. Moreover, different subtypes such as epidural, subdural, subarachnoid, intraventricular and intraparenchymal need distinct treatment strategies. Hence, it is not only important to accurately identify the presence of ICH, but it is also equally or even more important to classify its subtype.

Conventionally, ICH diagnosis relies on manual interpretation of computed tomography (CT) data, performed by expert radiologists which can be time consuming, prone to observer variability and naturally prone to human error, especially in high pressure emergency settings. With the increasing availability of medical imaging data, the advancements in deep learning have shown promising results in automating medical image analysis and providing accurate diagnosis, offering the potential to assist radiologists make better decisions.

This project focuses on ICH subtype classification across the five aforementioned subtypes using a hybrid deep learning model trained on a pre-processed subset of the Radiological Society of North America (RSNA) ICH dataset [1]. The RSNA ICH dataset, released as part of the RSNA 2019 Brain CT Hemorrhage Kaggle Challenge is one of the most comprehensive publicly available collections for this task. It contains over 800,000 labeled computed tomography (CT) slices obtained from more than 25,000 unique head CT scans and was developed through a multi-institutional effort involving expert neuroradiologists where each slice is annotated for the presence or absence of ICH and its five aforementioned subtypes. Due to its size and expert labeling, it serves as a strong benchmark for automated ICH detection and subtype classification, making it highly suitable for training and evaluating the proposed deep learning model.

A. Related Work

In recent years, numerous approaches have been proposed to address the ICH detection challenge using this dataset. Among the top approaches developed using this dataset is the then winning solution by Wang et al. [2] which introduced a hybrid deep learning architecture that closely mimics a radiologist's interpretation workflow. Their model combined a 2D convolutional neural network with two sequential models to capture intra-slice and inter-slice dependencies. Their model achieved near-expert performance (AUCs > 0.98 across all subtypes) and showed strong generalization on external datasets.

Burduja et al. [3] developed a more lightweight approach using a CNN-LSTM architecture, reducing image resolution and selecting key features to improve efficiency. Despite its simplicity, their method ranked in the top 2% while balancing speed and accuracy.

Recently transformer-based models have also shown promise. Shang et al. [4] introduced a Swin Transformer-based architecture that surpassed the RSNA challenge winner in performance, while requiring only a fraction of the parameters and computation. They also incorporated semi-supervised learning to enhance generalization.

Another proposed solution used a simple deep learning approach for ICH detection based on a standard 2D ResNet-50 [5]. The model processes slices individually, relying only on ResNet's residual connections for feature extraction, without sequence modeling or attention. Though its performance was lower than more advanced methods, it remains efficient and easy to implement.

We incorporate ideas from these approaches and rather than working directly on individual 2D CT slices, this project uses a 3D representation to better capture spatial continuity and anatomical context. The available 2D slices are grouped into volumetric sequences, from which triplets of consecutive

slices sharing the same label are selected. Each triplet thus provides a richer representation of the hemorrhage region, enhancing the model's ability to recognize relevant patterns, thus improving performance.

Using these triplets as input, each slice within a triplet is first passed through a feature extractor based on a pretrained [6] ResNet architecture [7], which captures the spatial and textural patterns from individual CT slices. The extracted features from the three slices are then aggregated using a Long Short-Term Memory (LSTM) network, enabling the model to learn sequential dependencies and inter-slice relationships that may indicate hemorrhagic patterns.

This hybrid convolutional–recurrent design allows the model to leverage both the spatial precision of convolutional neural networks and the temporal awareness of recurrent networks offering a more comprehensive understanding and thus a more reliable automated ICH diagnosis.

II. Method

Given the large dataset of about 460 GB of raw CT slices collected from multiple hospitals in DICOM format, we first carried out data selection, balancing and preprocessing to make the data manageable and consistent for analysis.

A. Preprocessing

We began by grouping the 800,000 individual slices into their corresponding 3D volumes using the `SeriesInstanceUID` metadata available in each slice. An example of such a volume is shown in Fig. 1.

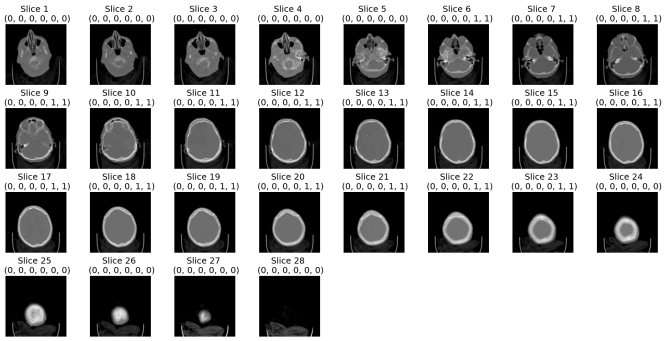

Fig. 1. Individual slices of one CT scan grouped into a volume by the `SeriesInstanceUID`.

The 21,744 reconstructed volumes are observed to vary significantly in quality and level of detail as volumes contain substantially more slices than others.

Each slice is labeled independently for the five hemorrhage subtypes, epidural, intraparenchymal, intraventricular, subarachnoid and subdural with multiple subtypes able to be present in a single slice. The dataset also includes an additional binary label indicating the presence of any hemorrhage, which we exclude as it is redundant and can be inferred from the subtype labels. Moreover, hemorrhages are typically present in only a subset of slices within a volume, leading to significant label variation across slices, as seen by the labels in Fig. 1.

These characteristics make it challenging to model hemorrhage presence at the volume level. Hence to address this, we constrained the dataset to three consecutive slices that share identical labels (triplets) sampled from the constructed volumes. This approach reduces the dataset to a manageable size while ensuring label consistency within each sample.

Additionally the distribution of hemorrhage subtypes is highly imbalanced. The majority of slices do not contain any hemorrhage, while others may include multiple subtypes. In particular, the epidural subtype is underrepresented, with only 86 triplets sharing only this label in the raw dataset. To create our final dataset we decided to sample:

- 300 triplets for each subtype, where only that subtype is present (the exception being epidural with 86 triplets),
- 500 triplets where no hemorrhage is detected and
- 500 triplets where a combination of multiple subtypes being present.

On each slice we applied windowing, which is a common technique in processing CT images to extract details at different tissue densities. Using the metadata of the slices we extracted raw Hounsfield Units (HU) that measure these densities in a now generalized range. Windowing narrows this range of HU values to a specific window centered around a particular tissue type [8]. In our approach, following prior work on this dataset, we applyed three window settings that focus on:

- Brain tissue (centered around -40 with a width of 120)
- Subdural regions (centered around -120 with a width of 280)
- Bone structures (centered around -2200 with a width of 3400)

As a result we get three distinct images per slice as seen in Fig. 2.

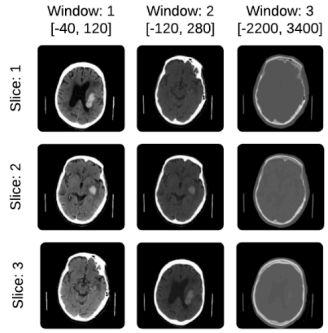

Fig. 2. Raw input to our model containing three slices each three different windows for focusing on different tissue densities.

Penultimately, each of the 9 slices per example were normalized using the mean and standard deviation values from ImageNet and then resized to 224×224, which is the standard input dimension for ImageNet based pre-trained architectures.

Lastly, the dataset was then split in a stratified manner into training (80%), validation (10%) and test (10%) sets to ensure balanced class representation across all splits. During training, data were streamed in batches of 32 and the training set was augmented on the fly with random horizontal flips,

slight translations and small rotations to improve model generalization.

B. Model Architecture

Our deep learning model is composed of two main components, as illustrated in Fig. 3, a per-slice feature extractor and a sequential bidirectional aggregator. Each slice within a triplet is independently passed through a ResNet-50 feature extractor, pretrained on ImageNet, with most of the layers frozen other than the ones in the final batch of layers. This yields a 2048-dimensional feature vector per slice.

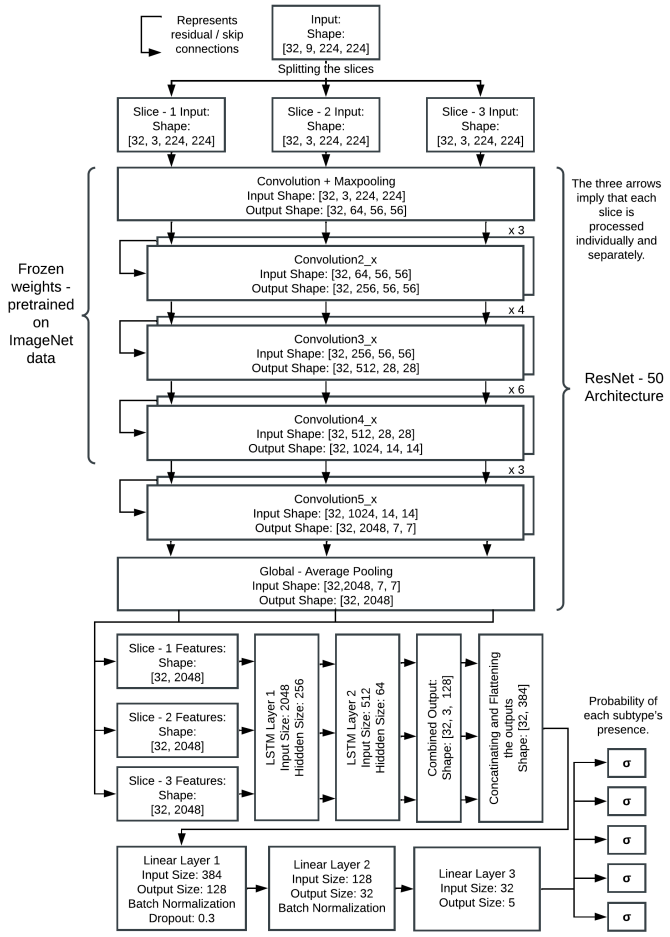

Fig. 3. Visual representation of the employed hybrid architecture. Each slice is processed individually by a pretrained ResNet-50 CNN and the resulting feature vectors are aggregated using two LSTM layers.

The resulting sequence of features is then passed to a two-layer LSTM network, which models inter-slice dependencies and captures contextual patterns that may indicate hemorrhage. The LSTM output is fed through a stack of three fully connected layers, ultimately producing five logits corresponding to the presence of each ICH subtype.

Since this is a multi-label classification task, each of the five logit values is passed through a sigmoid activation function and the resulting probabilities are thresholded independently to obtain binary predictions for each subtype.

While we use fixed-length sequences of three consecutive slices in our current setup, the architecture is inherently flexible and can accommodate variable-length inputs. This makes it well-suited for future extensions involving longer sequences or full 3D volumes.

C. Training

We used a conventional mini-batch training approach with the Adam Optimizer with a learning rate of 0.001 and a weight decay of 1×10^6 as regularization and early-stopping to combat overfitting.

For the loss we decided on a weighted binary cross entropy loss with logits directly involving the outputs of the network. We weighed the loss according to $w_i = \log\left(1 + \frac{N_{\text{neg},i}}{N_{\text{pos},i}}\right)$ where $N_{\text{pos},i}$ and $N_{\text{neg},i}$ are the number of positive and negative samples for class i, respectively. This ensures proper training of all subtypes even with the previously mentioned imbalance from the source data.

During training, we evaluated the model on the validation data after each epoch. Out of a total of 100 possible epochs, we observed no further improvement in the validation loss after 62 epochs of training the LSTM head and the last convolutional block of the ResNet-50 feature extractor, and therefore stopped the training at 72 epochs based on a patience value of 10.

The training and validation loss and accuracy can be seen in Fig. 4. Overall we observe a relatively stable convergence and no overfitting or underfitting with a similarly high training and validation accuracy of around 90%.

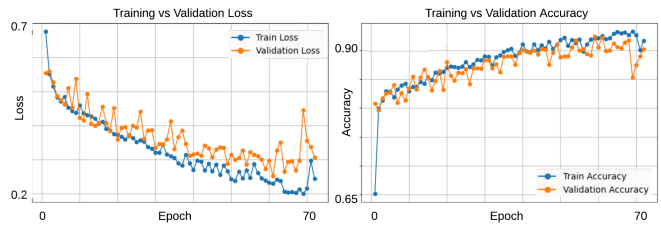

Fig. 4. Loss and accuracy on the training and validation data for each epoch.

III. Results

We evaluate our model individually per subtype using common binary classification metrics like accuracy, sensitivity, specificity, precision and negative predictive value (NPV). The results are displayed in Table I below:

TABLE I
PER-CLASS PERFORMANCE METRICS FOR THE FIVE INTRACRANIAL HEMORRHAGE SUBTYPES ON THE TEST SET

Metric	Epidural	Subdural	Subarac -hnoid	Intraven -tricular	Intrapare -nchymal
Accuracy	0.948	0.930	0.918	0.884	0.884
Sensitivity	0.727	0.857	0.923	0.667	0.787
Specificity	0.959	0.954	0.915	0.969	0.917
Precision	0.471	0.857	0.762	0.898	0.774
NPV	0.986	0.954	0.976	0.878	0.922
F1 Score	0.574	0.857	0.834	0.767	0.781

To further assess model performance, average ROC curves along with the corresponding AUC values were computed across all hemorrhage subtypes, as shown in Fig. 5. A higher area under the curve (AOC) generally indicates better classification performance.

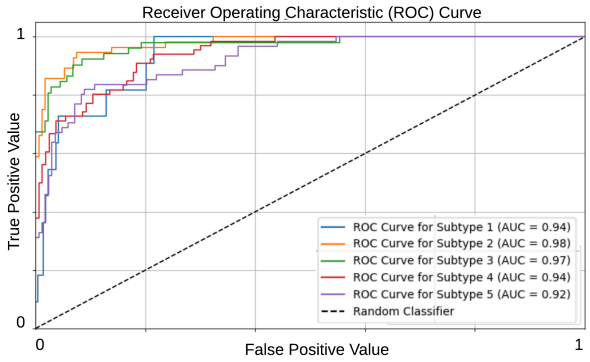

Fig. 5. Receiver Operating Characteristic Curves for each hemorrhage subtype.

To assess model interpretability, we applied Grad-CAM [9] to visualize the decision-relevant regions in CT scans as seen in Fig. 6. Each column corresponds to one hemorrhage subtype, within each column, the first three rows show the actual bleeding regions in the triplets, while the next three rows display the Grad-CAM heatmaps, highlighting the areas the model focuses on when making predictions.

The sampled highlighted regions produced by Grad-CAM closely correspond to the actual hemorrhage locations in the CT scans, indicating that the model attends to meaningful features when making predictions. Such interpretability is also valuable in clinical decision-making, as it allows radiologists to visualize and verify the basis of the model's outputs

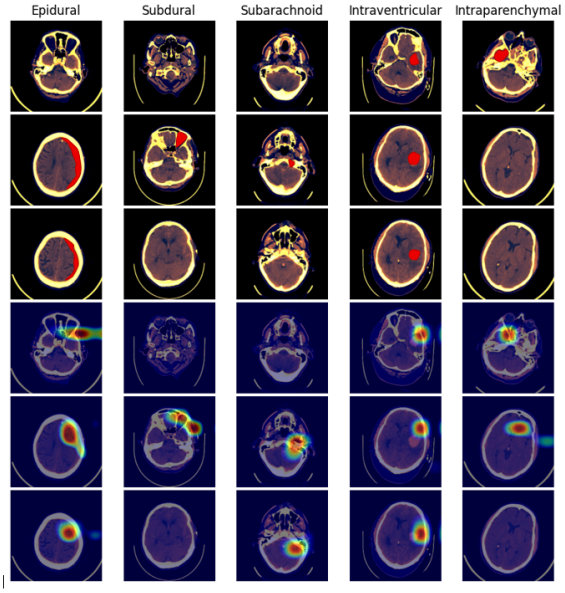

Fig. 6. Actual hemorrhage regions (top) and Grad-CAM visualizations (bottom) across hemorrhage subtypes highlighting the most influential regions in the model's prediction.

IV. Conclusion

In this project, we developed a hybrid deep learning model for automatic classification of five intracranial hemorrhage subtypes using triplets of CT slices from the RSNA 2019 dataset. By combining a pretrained ResNet-50 feature extractor with a two-layer bidirectional LSTM network, our architecture effectively captures both the spatial and sequential patterns indicative of hemorrhagic events.

Through careful preprocessing, label balancing and windowing, we prepared a compact yet diverse dataset that preserved inter-slice context while ensuring consistent labels across samples. We trained and evaluated our model on carefully selected and balanced triplets of CT slices. The model achieved strong performance across all five subtypes, with an average accuracy of 91.1% and a mean ROC AUC of 0.954, even under class imbalance.

These results show that deep learning has the potential to meaningfully assist clinicians in detecting and classifying ICH. While our current approach uses fixed-length triplets, the architecture can be extended to variable-length sequences or full volumes, making it suitable for future clinical applications that demand flexibility, efficiency and interpretability.

References

[1] A. E. Flanders *et al.*, "Construction of a Machine Learning Dataset through Collaboration: The RSNA 2019 Brain CT Hemorrhage Challenge," *Radiology: Artificial Intelligence*, vol. 2, no. 3, p. e190211, May 2020, doi: 10.1148/ryai.2020190211.

[2] X. Wang *et al.*, "A deep learning algorithm for automatic detection and classification of acute intracranial hemorrhages in head CT scans," *NeuroImage: Clinical*, vol. 32, p. 102785, 2021, doi: 10.1016/j.nicl.2021.102785.

[3] M. Burduja, R. T. Ionescu, and N. Verga, "Accurate and Efficient Intracranial Hemorrhage Detection and Subtype Classification in 3D CT Scans with Convolutional and Long Short-Term Memory Neural Networks," *Sensors*, vol. 20, no. 19, p. 5611, Oct. 2020, doi: 10.3390/s20195611.

[4] F. Shang, S. Wang, X. Wang, and Y. Yang, "An Effective Transformer-based Solution for RSNA Intracranial Hemorrhage Detection Competition." Accessed: Oct. 22, 2025. [Online]. Available: http://arxiv.org/abs/2205.07556

[5] T. Lewick, M. Kumar, R. Hong, and W. Wu, "Intracranial Hemorrhage Detection in CT Scans using Deep Learning," in *2020 IEEE Sixth International Conference on Big Data Computing Service and Applications (BigDataService)*, Oxford, United Kingdom: IEEE, Aug. 2020, pp. 169–172. doi: 10.1109/BigDataService49289.2020.00033.

[6] S. J. Pan and Q. Yang, "A Survey on Transfer Learning," *IEEE Transactions on Knowledge and Data Engineering*, vol. 22, no. 10, pp. 1345–1359, Oct. 2010, doi: 10.1109/TKDE.2009.191.

[7] K. He, X. Zhang, S. Ren, and J. Sun, "Deep Residual Learning for Image Recognition," in *2016 IEEE Conference on Computer Vision and Pattern Recognition (CVPR)*, June 2016, pp. 770–778. doi: 10.1109/CVPR.2016.90.

[8] Z. Xue, S. Antani, L. R. Long, D. Demner-Fushman, and G. R. Thoma, "Window Classification of Brain CT Images in Biomedical Articles," *AMIA Annual Symposium Proceedings*, vol. 2012, pp. 1023–1029, Nov. 2012, Accessed: Oct. 22, 2025. [Online]. Available: https://www.ncbi.nlm.nih.gov/pmc/articles/PMC3540547/

[9] R. R. Selvaraju, M. Cogswell, A. Das, R. Vedantam, D. Parikh, and D. Batra, "Grad-CAM: Visual Explanations from Deep Networks via Gradient-Based Localization," *International Journal of Computer Vision*, vol. 128, no. 2, pp. 336–359, Oct. 2019, doi: 10.1007/s11263-019-01228-7.