Laser Vision Correction in Treating Myopia

Germano Leal Ehlke, MD, and Ronald R. Krueger, MD†*

Abstract: Myopia is a generally benign refractive error with an increasing prevalence worldwide. It can be corrected temporarily with glasses and contact lenses and permanently with laser vision correction. The 2 main procedures currently being performed for myopia correction are photorefractive keratectomy and laser-assisted in situ keratomileusis. Each technique has its advantages, but they appear to yield similar visual outcomes 1 year after surgery. Laser vision correction for myopia was considered a paradigm shift because healthy eyes could now undergo a surgical procedure to permanently and safely correct the error by altering the center of the cornea, which was previously off limits because of the potential for loss of transparency. Customized ablation using wavefront aberrometry and its optimized profiles were created to correct higher-order aberrations and give more vision quality to patients. Topography-guided ablation, initially used for complex retreatments, shows potential to make vision even better than glasses and contact lenses in a recent study on previously untreated eyes. One major concern is to identify corneas that are at risk of developing ectasia after the procedure. Topographic and tomographic screening indices have been implemented clinically, but there is still much to learn about corneal biomechanics. A more recently developed procedure for myopia correction is small-incision lenticule extraction, in which a lenticule is created in the cornea's stroma with a femtosecond laser and extracted through a small corneal incision. Long-term outcomes and new complication risks need to be better understood as this procedure develops.

Key Words: laser vision correction, myopia, refractive error

(*Asia Pac J Ophthalmol* 2016;5: 434–437)

Myopia (near-sightedness) is a refractive error that, for most people, is considered a benign disorder in which images come into focus anterior to the retina. It can usually be corrected with glasses or contact lenses, and when associated with normal corneal thickness, shape, and stability, myopia can be corrected with refractive surgery. Myopia is a global public health problem, which is recognized by the World Health Organization as the major cause of visual impairment for those who are uncorrected[1] (Fig. 1). It can have a big impact on quality of life because of the increased difficulty in performing vision-related tasks.[2] When pathologic, it can also lead to blinding complications.[3]

The prevalence of myopia has rapidly increased in recent years in developed countries, especially in East and Southeast Asia.[4] Recent data have shown a similar tendency in the United States.[5] The annual direct cost of correcting distance vision impairment, calculated in 2006 by Vitale et al,[6] was at least US $3.8 billion in the United States. A recent study projects close to 1 billion people in the world with high myopia [spherical equivalent of ≥5 diopters (D)] by 2050, 7.5 times more than in 2000, which will have significant implications for planning comprehensive eye care services globally.[7]

From *Cole Eye Institute, Cleveland Clinic Foundation, and †Department of Ophthalmology, Cleveland Clinic Lerner College of Medicine, Cleveland, OH.
Received for publication August 26, 2016; accepted September 19, 2016.
The authors have no funding or conflicts of interest to declare.
Reprints: Germano Leal Ehlke, MD, Av Sete de Setembro 5621 Apt 1401, Curitiba, Paraná, Brazil. E-mail: germanoehlke@yahoo.com.br.
Copyright © 2016 by Asia Pacific Academy of Ophthalmology
ISSN: 2162-0989
DOI: 10.1097/APO.0000000000000237

Although the causes of the disorder are still not fully understood, most theories center on the association between genetic and environmental factors.[8] Treatments proposed on the prevention of axial elongation or in decreasing the progression of myopic refractive errors are still controversial.[8]

The history of the excimer laser in ophthalmology starts in 1983, when it was first demonstrated to precisely remove organic tissue without producing collateral damage in both a human hair and bovine cornea.[9] After years of research and experiments trying to determine the ablation threshold, optimal ablation rate, detailed histopathology, and healing process, the first clinical applications started in 1985 with corneal incisions and phototherapeutic keratectomy.[9] The first successful photorefractive keratectomy (PRK) procedure was performed in 1988 in a nonsighted myopic eye with optic neuropathy, which later was found to have hysterical blindness due to unexpected recovery to an uncorrected distance visual acuity (UDVA) of 20/20.[9]

The 2 main laser vision correction procedures currently being performed for myopia are PRK and laser-assisted in situ keratomileusis (LASIK).[10] In PRK, the laser is applied on the surface of the cornea after its epithelium is removed, whereas in LASIK a flap is created within the cornea's stroma, either by a blade or a femtosecond laser. The flap is then lifted and reflected away from the corneal center, where the excimer laser is applied onto the stromal bed (Fig. 2). After the treatment, the flap is repositioned in its site.

Photorefractive keratectomy was the first procedure to gain US Food and Drug Administration (FDA) approval in 1995 and was widely performed internationally, but in the late 1990s LASIK became the dominant method based on factors such as earlier posttreatment stabilization, faster improvement of visual acuity, less patient discomfort, less stromal haze formation, higher predictability, and easier enhancement procedures.[11] Despite these advantages with LASIK, the 2 techniques seem to give similar visual outcomes 1 year after surgery,[10] so PRK remains an important laser vision correction option.

The initial use of the excimer laser for visual correction generated some patient dissatisfaction with the quality of vision after surgery, despite having 20/20 Snellen uncorrected visual acuity. The solution to this problem, both diagnostically and therapeutically, was wavefront aberrometry, which highlighted the importance of higher-order aberrations (HOAs) in the visual system, revolutionizing refractive surgery with wavefront-guided and wavefront-optimized (WFO) treatments.[12] This technology, in addition to scanning spot ablation directed by eye tracking (Fig. 3), created customized ablation profiles for individual eyes based on the complex aberration pattern measured by wavefront sensing.[13]

Using wavefront aberrometry to guide excimer laser ablation can theoretically correct not only spherocylindrical errors but also the HOAs and minimize induction of aberrations by the laser ablation.[14] The WFO ablation profile maintains a more prolate corneal shape, reducing the induction of spherical aberration compared with the standard treatment. It compensates for the loss in ablation energy, because of the angle of incidence of pulses in the periphery, by increasing the pulse energy in this area. Unlike WFO, the wavefront-guided profile proposes the correction of all HOAs measured, which needs

Copyright © 2016 Asia Pacific Academy of Ophthalmology. Unauthorized reproduction of this article is prohibited.

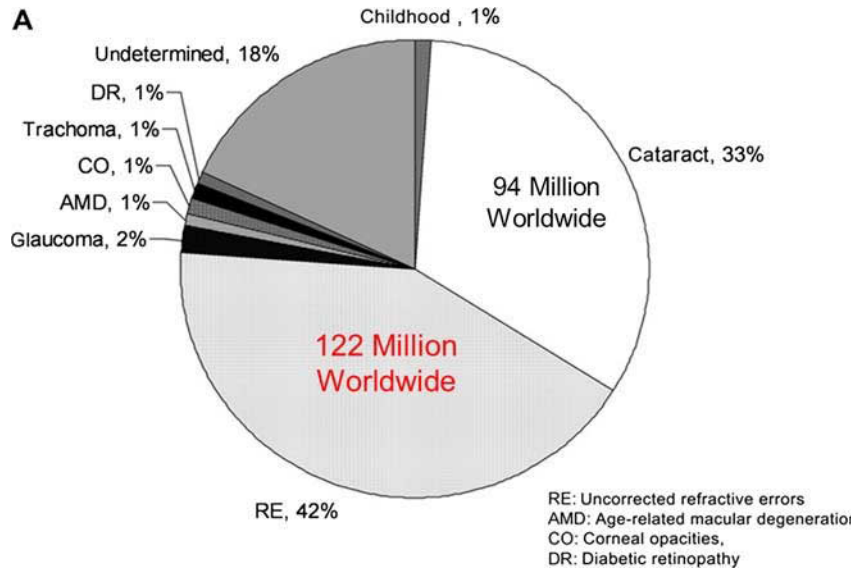

FIGURE 1. Of the 285 million people in the world with visual impairment (visual acuity ≤ 20/120), 42% (122 million) are due to uncorrected refractive error, of which myopia is the greatest source. Reprinted with permission from *BJO* 2012;96:614–618.

perfect centration of the eye[15] and high precision and reproducibility of the wavefront map. Most myopic candidates for refractive surgery have low HOAs (<0.35 μm root mean square error over a 6.0-mm pupil) and would probably not benefit from a wavefront-guided treatment profile.[16,17] This profile does benefit normal myopic eyes with a higher magnitude of HOAs, which report similar visual outcomes but with more effective aberration correction.[16]

Laser-assisted in situ keratomileusis and PRK with a topography-guided ablation profile were introduced initially for complex retreatments of highly aberrated eyes[18,19] as a "repair procedure." However, a recent study[20] conducted by the US FDA in myopic and myopic astigmatic eyes with no prior refractive surgery and good-quality topographic maps shows the potential to improve vision beyond that of glasses and contact lenses. In that study, 29.6% of eyes at 3 months and 30.9% at 12 months gained 1 or more lines of postoperative UDVA compared with preoperative corrected distance visual acuity (CDVA). When comparing preoperative and postoperative CDVA, 39.3% of eyes at 3 months and 40.4% at 12 months gained 1 or more lines. These results are promising, as they demonstrate that laser vision correction has the potential to provide vision not only as good as glasses and contact lenses, but better. Postmarket studies are underway to confirm and ultimately refine this improvement in quality of vision (Fig. 4).

The inception of laser vision correction for myopia was considered a paradigm shift because otherwise healthy eyes, correctable with spectacles or contact lenses, could now undergo a surgical procedure to permanently and safely correct the visual consequences of myopia by altering the central cornea without inducing a scar.

However, because it is an elective procedure, the preoperative refractive surgery screening process is of great importance. One major concern is identifying corneas with a risk of developing iatrogenic ectasia after the procedure. Although its prevalence is low, estimated between 0.04%[21] and 0.6%,[22] postoperative ectasia is a severe complication that compromises the visual prognosis and could lead to corneal transplantation.[23]

Subclinical keratoconus identification is a challenging process because its topographic and tomographic indices for detection overlap with those of normal eyes in most of the parameters.[24] Many screening methods have been proposed for

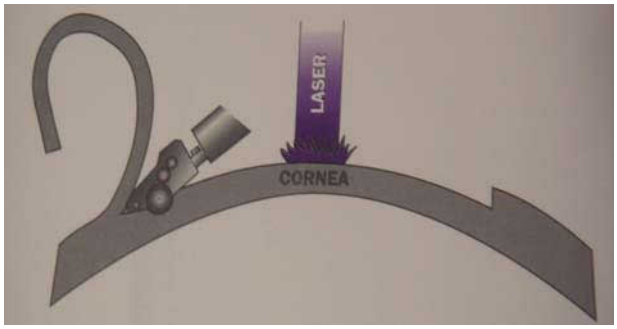

FIGURE 2. Laser-assisted in situ keratomileusis involves the creation of a corneal flap, which is then reflected away from the corneal center to allow for internal exposure and reshaping by an excimer laser.

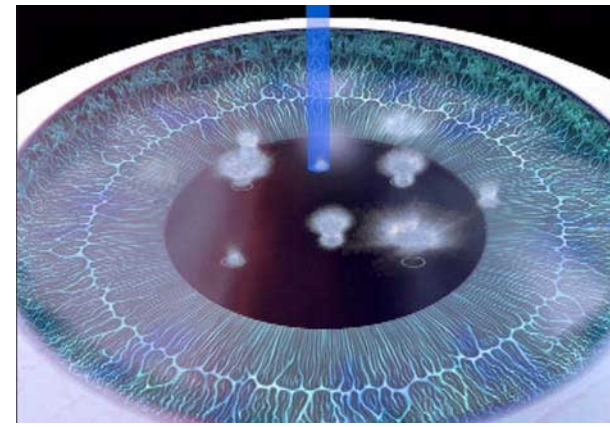

FIGURE 3. Scanning spot laser delivery, which with robust eye tracking facilitates customized laser vision correction.

Copyright © 2016 Asia Pacific Academy of Ophthalmology. Unauthorized reproduction of this article is prohibited.

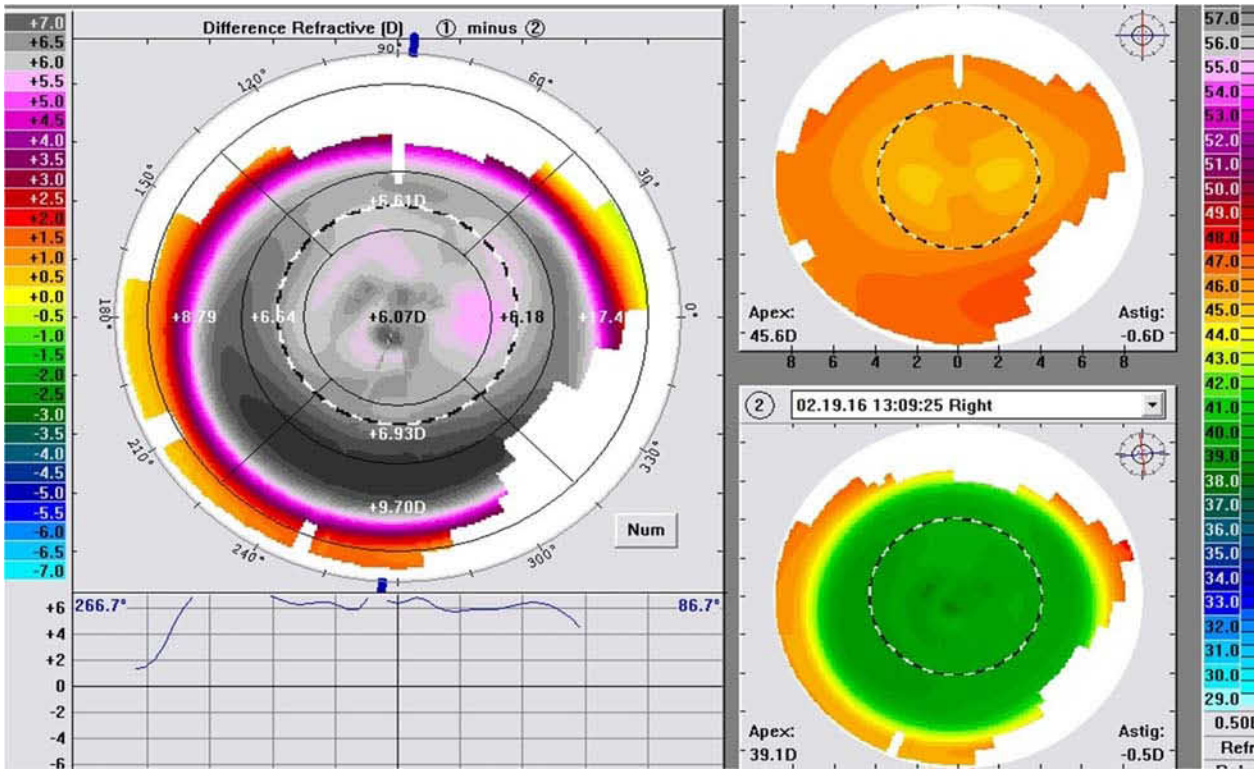

FIGURE 4. Topography-guided LASIK demonstrates postoperative flattening and greater uniformity of central curvature (lower right), which when subtracted from the preoperative map (upper right) reveals the complexity of the treatment profile (left).

early detection and have been of great help in the clinical practice of refractive surgery, but there is still much to learn about corneal biomechanics before and after laser vision correction, and further studies need to be done on this subject.

Laser vision correction, and specifically LASIK, is today the most frequently performed elective surgical procedure in the world, with nearly a million procedures performed annually in the United States and several million each year around the world. The safety and efficacy achieved by this technology have made it possible for the US military to approve its use in naval pilots.[25] Studies show a marked improvement in quality of life and patient satisfaction after surgery.[26,27]

A recent addition to the refractive surgeon's menu of procedures is small-incision lenticule extraction (SMILE), where a lenticule is created inside the cornea's stroma by a femtosecond laser and is then extracted through a small corneal incision (Fig. 5). This technique eliminates the use of an excimer laser in corneal shaping and creating a flap and could reduce the risk of flap-related complications such as a free cap, buttonhole, and epithelial ingrowth. The small incision could also preserve more nerve fibers and corneal biomechanical strength, possibly reducing dry eye symptoms and the risk of ectasia.

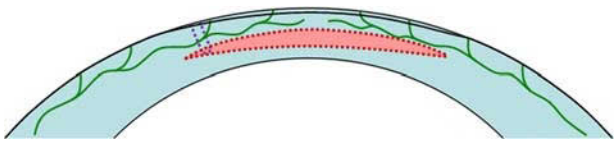

FIGURE 5. Small-incision lenticule extraction involves the creation of an intrastromal lenticule, which is then dissected and removed through a small incision.

Although at the time of writing more than half a million SMILE procedures have been done worldwide, the published literature on SMILE outcomes is still limited and lacking sufficient time for long-term follow-up. Recent studies demonstrate comparable safety and efficacy between SMILE and LASIK, with SMILE showing fewer dry eye symptoms.[28] Reinstein et al[29] reported in patients with low to moderate myopia a UDVA of 20/20 or better in 96% of treated eyes and 9% with a loss in CDVA of 1 Snellen line or more after 1 year. Similar results were found by Sekundo et al[30] in the same follow-up period, 88% with UDVA of 20/20 or better and 12% with loss of 1 Snellen line.

A 3-year follow-up study conducted by Pedersen et al[31] on patients with high myopia showed a UDVA of 20/20 or better in 72% of treated eyes and 12% with loss of 1 or more Snellen lines. In a recently approved US FDA study,[32] 336 eyes from −1 to −10 D with maximum cylinder of −0.5 D were treated at 5 different sites with a 12-month follow-up. Of the eyes treated, 88% achieved 20/20 or better vision; 93.9% were in the ±0.5 D interval, whereas 99.6% were in the ±1.0 D interval.

However, SMILE will have a new set of complications and challenges, so further studies and longer follow-up should be pursued to fully characterize its place in the future of laser vision correction of myopia.

REFERENCES

1. Resnikoff S, Pascolini D, Mariotti SP, et al. Global magnitude of visual impairment caused by uncorrected refractive errors in 2004. *Bull World Health Organ*. 2008;86:63–70.

© 2016 Asia Pacific Academy of Ophthalmology

Copyright © 2016 Asia Pacific Academy of Ophthalmology. Unauthorized reproduction of this article is prohibited.

2. Vu HT, Keeffe JE, McCarty CA, et al. Impact of unilateral and bilateral vision loss on quality of life. *Br J Ophthalmol*. 2005;89:360–363.
3. Saw SM, Gazzard G, Shih-Yen EC, et al. Myopia and associated pathological complications. *Ophthalmic Physiol Opt*. 2005;25:381–391.
4. Pan CW, Ramamurthy D, Saw SM. Worldwide prevalence and risk factors for myopia. *Ophthalmic Physiol Opt*. 2012;32:3–16.
5. Vitale S, Sperduto RD, Ferris FL 3rd. Increased prevalence of myopia in the United States between 1971–1972 and 1999–2004. *Arch Ophthalmol*. 2009;127:1632–1639.
6. Vitale S, Cotch MF, Sperduto R, et al. Costs of refractive correction of distance vision impairment in the United States, 1999–2002. *Ophthalmology*. 2006;113:2163–2170.
7. Holden BA, Fricke TR, Wilson DA, et al. Global prevalence of myopia and high myopia and temporal trends from 2000 through 2050. *Ophthalmology*. 2016;123:1036–1042.
8. Morgan IG, Ohno-Matsui K, Saw SM. Myopia. *Lancet*. 2012;379: 1739–1748.
9. Krueger RR, Rabinowitz YS, Binder PS. The 25th anniversary of excimer lasers in refractive surgery: historical review. *J Refract Surg*. 2010;26: 749–760.
10. Shortt AJ, Allan BD, Evans JR. Laser-assisted in-situ keratomileusis (LASIK) versus photorefractive keratectomy (PRK) for myopia. *Cochrane Database Syst Rev*. 2013;1:CD005135.
11. Sutton GL, Kim P. Laser in situ keratomileusis in 2010—a review. *Clin Exp Ophthalmol*. 2010;38:192–210.
12. Mello GR, Rocha KM, Santhiago MR, et al. Applications of wavefront technology. *J Cataract Refract Surg*. 2012;38:1671–1683.
13. Krueger RR. Technology requirements for Summit-Autonomous Custom Cornea. *J Refract Surg*. 2000;16:S592–S601.
14. Seiler T, Dastjerdi MH. Customized corneal ablation. *Curr Opin Ophthalmol*. 2002;13:256–260.
15. Ciccio AE, Durrie DS, Stahl JE, et al. Ocular cyclotorsion during customized laser ablation. *J Refract Surg*. 2005;21:S772–S774.
16. Stonecipher KG, Kezirian GM. Wavefront-optimized versus wavefront-guided LASIK for myopic astigmatism with the ALLEGRETTO WAVE: three-month results of a prospective FDA trial. *J Refract Surg*. 2008;24:S424–S430.
17. George MR, Shah RA, Hood C, et al. Transitioning to optimized correction with the WaveLight ALLEGRETTO WAVE: case distribution, visual outcomes, and wavefront aberrations. *J Refract Surg*. 2010;26:S806–S813.
18. Toda I, Yamamoto T, Ito M, et al. Topography-guided ablation for treatment of patients with irregular astigmatism. *J Refract Surg*. 2007;23:118–125.
19. Lin DT, Holland SR, Rocha KM, et al. Method for optimizing topography-guided ablation of highly aberrated eyes with the ALLEGRETTO WAVE excimer laser. *J Refract Surg*. 2008;24: S439–S445.
20. Stulting RD, Fant BS, T-CAT Study Group. Results of topography-guided laser in situ keratomileusis custom ablation treatment with a refractive excimer laser. *J Cataract Refract Surg*. 2016;42:11–18.
21. Randleman JB, Russell B, Ward MA, et al. Risk factors and prognosis for corneal ectasia after LASIK. *Ophthalmology*. 2003;110:267–275.
22. Pallikaris IG, Kymionis GD, Astyrakakis NI. Corneal ectasia induced by laser in situ keratomileusis. *J Cataract Refract Surg*. 2001;27:1796–1802.
23. Woodward MA, Randleman JB, Russell B, et al. Visual rehabilitation and outcomes for ectasia after corneal refractive surgery. *J Cataract Refract Surg*. 2008;34:383–388.
24. Smadja D, Touboul D, Cohen A, et al. Detection of subclinical keratoconus using an automated decision tree classification. *Am J Ophthalmol*. 2013; 156:237–246.
25. Tanzer DJ, Brunstetter T, Zeber R, et al. Laser in situ keratomileusis in United States Naval aviators. *J Cataract Refract Surg*. 2013;39:1047–1058.
26. Saragoussi JJ, Djadi-Prat J, Lebuisson DA, et al. Quality of life after LASIK: part II. Quality of life and satisfaction of a population of patients treated with LASIK [in French]. *J Fr Ophtalmol*. 2011;34:294–302.
27. Solomon KD, Fernández de Castro LE, Sandoval HP, et al. LASIK world literature review: quality of life and patient satisfaction. *Ophthalmology*. 2009;116:691–701.
28. Zhang Y, Shen Q, Jia Y, et al. Clinical outcomes of SMILE and FS-LASIK used to treat myopia: a meta-analysis. *J Refract Surg*. 2016;32:256–265.
29. Reinstein DZ, Carp GI, Archer TJ, et al. Outcomes of small incision lenticule extraction (SMILE) in low myopia. *J Refract Surg*. 2014;30: 812–818.
30. Sekundo W, Gertnere J, Bertelmann T, et al. One-year refractive results, contrast sensitivity, high-order aberrations and complications after myopic small-incision lenticule extraction (ReLEx SMILE). *Graefes Arch Clin Exp Ophthalmol*. 2014;252:837–843.
31. Pedersen IB, Ivarsen A, Hjortdal J. Three-year results of small incision lenticule extraction for high myopia: refractive outcomes and aberrations. *J Refract Surg*. 2015;31:719–724.
32. Steve S. Presented at: European Society of Cataract and Refractive Surgery Meeting; September, 2016: Copenhagen, Denmark.

There are two ways of spreading light: to be the candle or the mirror that reflects it.
— Edith Wharton

Copyright © 2016 Asia Pacific Academy of Ophthalmology. Unauthorized reproduction of this article is prohibited.