Suspect pulmonary fibrosis (PF)?

No time to wait – refer to an interstitial lung disease (ILD) specialist centre today

A devastating, life-changing and potentially fatal condition

- PF is a serious lung condition that might lead to irreversible lung damage.[1] It is potentially life-threating, and as of now, incurable.[2]
- PF affects about 400,000 people in Europe.[3]
- PF survival is only 3–7 years post-diagnosis,[4] while idiopathic pulmonary fibrosis (IPF), the most common fibrotic interstitial lung disease (ILD),[5] has a poor prognosis, with survival of just 2 to 5 years[6] – deadlier than some cancers.[4]
  Progressive pulmonary fibrosis (PPF) includes any non-IPF progressive fibrotic ILD.[6]
- PF has short- and long-term consequences,[7] including the risk of developing other serious conditions like heart failure and pulmonary hypertension.[2,4]
- Early recognition is crucial, as lung damage can be irreversible, yet misdiagnosis and delayed diagnosis are common.[1,3,5,7,8]
- Up to 55% of ILD patients are misdiagnosed.[1,2]

5-year survival rate for IPF, PPF and various cancers[1,4,5,6,9]

Potentially avoidable consequences of PF

In PF, prolonged inflammation in the lungs can lead to lung scarring and stiffness.[1,7] This progressive disease can be unpredictable and unforgiving, compromising lung function over time.[1,8,10]

Early identification, ILD specialist referral and initiation of effective antifibrotic therapy are key to preserving lung function and slowing disease progression.[4,10,11,17,18]

Without this, PF has significant short- and long-term consequences for your patients:[7,8]

Short-term[7,8,11,18,20]

Lack of efficient oxygen exchange	Decreased oxygen saturation and exercise tolerance
Decline in lung function	

Long-term[8,9,11]

Heart failure Pulmonary hypertension	5-10% reduction in forced vital capacity (FVC) is associated with increased risk of death

ILDs can strike alongside connective tissue diseases (CTDs)

ILDs can develop in patients with existing CTDs, like rheumatoid arthritis (RA) and systemic sclerosis (SSc).[21]

These patients face the risk of progressive fibrosis, regardless of their underlying CTD.[22]

CTD-ILDs pose a serious threat to patient health

67% of patients with SSc-ILD experience pulmonary progression within 5 years, with nearly one-third developing PPF.[23]

RA-ILD is associated with a 2- to 10-fold increase in mortality vs RA alone.[24]

PF: Know the risk factors, spot the red flags

IPF

- **Age[25]**
  1 in 200 people over the age of 70 have PF
- **Smoking history[26]**
  Common among patients with IPF
- **Family history[27,28]**
  Up to 20% of patients have a family history of PF
- **Exposures[25,29–31]**
  Includes work hazards like coal, silica and asbestos

CTD-ILDs

- **Having a CTD[21]**
  RA, SSc, idiopathic inflammatory myopathies (IIM), mixed connective tissue disease (MCTD) and Sjögren disease (SjD) all have an increased risk of progressive ILD compared to the general population
- **Age and gender[24]**
  More common in older men
- **Smoking history[24]**
  Smoking is a major risk in RA

Download detailed risk factors for ILDs

PF signs and symptoms

Recognising patients with red flag signs and symptoms of PF is vital.

Screening CTD patients before symptoms start is recommended.[32] Unexplained symptoms in your patients with CTD, such as breathlessness and dry cough, should prompt suspicion of ILD.[32–34]

Below are the signs to look out for:[11,14,34,35]

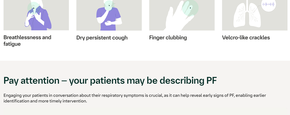

Breathlessness and fatigue | **Dry persistent cough** | **Finger clubbing** | **Velcro-like crackles**

Pay attention – your patients may be describing PF

Engaging your patients in conversation about their respiratory symptoms is crucial, as it can help reveal early signs of PF, enabling earlier identification and more timely intervention.

- "can't get that deep inhale"
- "trouble getting a deep breath in"
- "losing your breath"
- "chest tightening (with inspiration)"
- "wind/breath is cut/caught (with inspiration)"
- "too big of a breath... the bottom of my lungs will cramp"
- "it's like a catch inside"
- "it hurts (to take a deep breath)"
- "can't breathe in without it squeezing my chest"

Zoom

Time to screen and assess

Timely assessment of patients with red flag signs and symptoms of PF is vital – here's how you can identify changes that may indicate PF.

IPF

- **Auscultation[36–37]**
  Detects bilateral fine crackles ("Velcro-like"), heard during mid-to-late inspiration, which may be indicative of fibrotic lung changes, including fibrosing CTD-ILDs.
- **Long-ultrasound[38,39]**
  Fast and non-invasive. Identifies B-lines, which may suggest PF by indicating thickened or scarred lung tissue.
- **Pulmonary functioning tests (PFTs)[11,35,38,39]**
  A low diffusing capacity is typically the first indication of an ILD. Decreased forced vital capacity and total lung capacity might suggest more fibrosis in the lungs.
- **High-resolution computed tomography (HRCT)[11,35,38,39]**
  The **gold standard for PF diagnosis** – a method that evaluates the entire lung. To be performed even when chest X-rays appear normal. Typically requires an ILD specialist centre to interpret the results. HRCT is recommended over relying solely on symptoms and PFTs.

Listen to the telt-tale sounds of PF

'VELCRO-LIKE' crackles on auscultation are a telling sign of ILD[36–37]

When your patient takes slow deep breaths, listen for 'velcro-like' crackles in the lungs

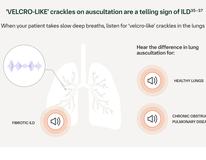

Learn the sounds of PF

Take the quiz now

Discover your local ILD specialist centre

Timely ILD specialist referral and multidisciplinary team involvement is vital to ensure accurate diagnosis and early treatment initiation.[1,10,40] These centres have access to the most accurate diagnostic tools and initiation of effective antifibrotic treatments to slow disease progression and preserve lung function.[10,40] Use the tool below to find your nearest centre.

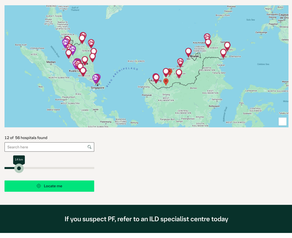

12 of 56 hospitals found

Search here

Filter

Locate me

If you suspect PF, refer to an ILD specialist centre today

Explore the variety of patient profiles

When should you suspect PF? Use our patient profiles to quickly identify individuals at risk.
Explore the profiles to learn about their symptoms, progression and risk factors, helping you to recognise and respond to PF more effectively. Start now to sharpen your detection skills.

WHAT COULD BE THREATENING HER LUNG FUNCTION?

PDF
Caroline - PF
Download patient profile

WHAT COULD BE THREATENING HER LUNG FUNCTION?

PDF
Ben - PF
Download patient profile

WHAT COULD BE THREATENING HER LUNG FUNCTION?

PDF
Julie - RA-ILD
Download patient profile

WHAT COULD BE THREATENING HIS LUNG FUNCTION?

PDF
Robert - Chronic hypersensitivity pneumonitis (cHP)
Download patient profile

WHAT COULD BE THREATENING HER LUNG FUNCTION?

PDF
Stephanie - SSc-ILD
Download patient profile

References

1. Sullivan DI, Faverio P, Sauty BG. BMJ Med 2023;2:e000427. doi.org/10.1136/bmjmed-2022-000427
2. Cottin V. Eur Respir Rev 2023;32:230021. doi.org/10.1183/16000617.0021-2023
3. European Pulmonary Fibrosis Federation. https://www.pfof.org/about-pulmonary-fibrosis/ Accessed July 2025.
4. Martinez-Molina MP, et al. Expert Rev Respir Med. 2019;13(7):637–646.
5. Hamblin M, et al. Eur Respir J. 2019;53(5):1800384. DOI.
6. Raghu G, et al. Am J Respir Crit Care Med. 2022;205(9):e18-e47.
7. Raghu G, et al. Lancet. 2022;399:1769–1780.
8. Pulmonary Fibrosis Foundation. Available at https://www.pulmonarydiseases.org/understanding-pf/about-pulmonary-fibrosis/symptoms-a-pulmonary-fibrosis. Accessed July 2025.
9. Pavagadhra AR, et al. Eur Respir Rev. 2017;26:160093.
10. Collard HR, Ref Manag Health Rev. 2015;2(1):18–20.
11. Cottingham MT, et al. BMJ Open Rheum. 2018;0:e000-10.
12. Cottin V, et al. Eur Respir Rev. 2018;27:170132.
13. Wangoo H, et al. Adv Ther. 2022;39(8):3736–3748.
14. Kern RC, et al. Respir Rev. 2021;2(138).
15. Chisholm A, et al. Front Pharmacol. 2021;12:654884.
16. Wells AU, et al. Respir Res. 2019;20:148.
17. Lancaster L, et al. Lancet Respir Med. 2023;11:772–790.
18. Kreuter M, et al. Respir Med. 2021;182:106374.
19. Pulmonary Fibrosis Foundation. Available at https://www.pulmonarydiseases.org/understanding-pf/about-pulmonary-fibrosis/symptoms. Accessed July 2025.
20. Wells AU, et al. Lancet Respir Med. 2020;8(7):708–711.
21. Lee P, et al. RMD Open. 2020;6:e001091.
22. European Lung Foundation. Available at https://www.pulmonaryfibrosis.org/docs/default-source/programs/educational-materials/pulmonary-fibrosis-work-handbook/ehb-pf-full-sheet---march-2021.pdf?sfvrsn=2a0a0a0a_2. Accessed July 2025.
23. Pulmonary Fibrosis Foundation. Available at https://www.pulmonarydiseases.org/understanding-pf/about-pulmonary-fibrosis/causes. Accessed July 2025.
24. Juge P, Lee JS, Ebstein E. N Engl J Med. 2023;388:1916–1928.
25. Raghu G, et al. Am J Respir Crit Care Med. 2018;198(3):e44–e68.
26. Ley B, et al. Ann Intern Med. 2012;157:199–203.
27. Oldham JM, et al. Eur Respir Rev. 2015;24(137):43–54.
28. Steele A, et al. Pulmonology. 2018;24(1):62–69.
29. Jaeger B, et al. Am J Respir Crit Care Med. 2019;200(7):890–897.
30. Sack C, et al. Radiol Cardiothorac Imaging. 2021;3(4):e200625.
31. Ever D, et al. Occup Environ Med. 2016;73(10):705–713.
32. Sparks JA, et al. BMJ Open Rheum. 2019;1:e000010.
33. Xaubet ER Velez J, Blanquet. 2021;35(Suppl 1):S88–S79.
34. Hoyt J, et al. Transl Immunol. 2021;10:e1309.
35. Pulmonary Fibrosis Foundation. https://www.pulmonarydiseases.org/sites/default-source/programs/educational-materials/pulmonary-function-tests/pdf_-pulmonary-function_-101_final-version-1.pdf?sfvrsn=2a0a0a0a_2. Accessed July 2025.
36. Ley B, et al. Ann Intern Med. 2012;157:199–203.
37. Wanamaker C, et al. Clin Chest Med. 2018;39:257–269.
38. Wakamatsu G, et al. Med Ultrasound. 2020;35:79–87.
39. Lichtenstein D, et al. Chest. 2008;134(1):117–125.
40. Lugt A, et al. Ann Rheum Dis. 2021;80:1267–1276.

Copyright © 2026 Boehringer Ingelheim Pharmaceuticals, Inc. All rights reserved. DOLPD-PF-RCV-252277