HUBS 191

Laboratory Manual

2017

Contents

Contact Information 1

Laboratory Practical Programmme 2

Impairment or Other Problems 2

Your Responsibilities 3

Code of Conduct 5

Laboratories:

1 Musculoskeletal Tissues & Movement 1* 7

2 Musculoskeletal Tissues & Movement 2* 31

3 Anatomy & Physiology of the Nervous System* 49

4 Sensory and Motor Physiology 67

5 Principles of Homeostasis 83

6 Immunology 103

Glossary 115

The Back Page 133

*Please note: During these labs, human cadaveric material will be on display and/or used as demonstration material..

HUBS 191: Human Body Systems I

HUBS191 provides the fundamental facts and concepts of the disciplines of anatomy, physiology, and immunology. HUBS191 is also designed to assist you to develop the learning skills necessary to advance to second year science, physical education, or health professional courses. HUBS 191 is a prerequisite for HUBS 192.

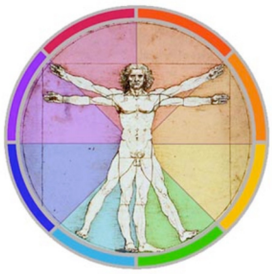

Contact Information

The HUBS Office is located in Room G01 of the Microbiology building (next to the HUBS lab, head to the right when you enter the building, instead of left to the lab). The office staff are your first line of contact for all matters related to HUBS papers.

HUBS Office:

Room G01, Ground Floor
Microbiology Building
720 Cumberland Street.

HUBS Reception:

Phone: (03) 479-7106
Email: HUBS@otago.ac.nz

HUBS Course Administrator/ Professional Practice Fellow:

Phone: (03) 479-7737
Email: hub-admin@otago.ac.nz

HUBS Teaching Fellows/ Academic Helpdesk Bookings

Email: HUBS-TF@otago.ac.nz



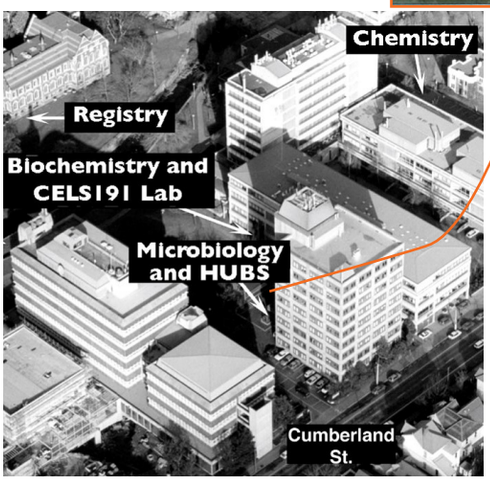

If you miss your laboratory session, you MUST CONTACT THE HUBS 191 OFFICE WITHIN 24 HOURS of your streamed time to arrange an alternative stream. Failure to do this may make you ineligible to do the lab. Do NOT leave notes on the Blackboard Discussion Board!

Laboratory Practical Programme

Each student will attend one 3-hour laboratory practical session once in two weeks. You will attend a total of six laboratory sessions in HUBS 191. You must wear a lab coat and enclosed shoes.

Laboratory sessions are held in room G.08 on the ground floor of the Microbiology building, 720 Cumberland Street. Lab times for HUBS 191 are as follows:

Morning labs:	9:00 am - 11:50 am
Afternoon labs:	2:00 pm - 4:50 pm
Evening labs:	6:00 pm - 8:50 pm

Laboratory attendance is compulsory for HUBS 191.

Contact the HUBS Office immediately if you are unable to attend at your scheduled time.

Arrive at least 10 minutes before your lab is to begin. If you arrive late to a lab you will be required to re-stream.

In order to pass the terms requirements for HUBS191, you must attend all laboratories and attend both terms tests. If you do not meet the terms requirements you will not pass HUBS 191. In the HUBS191 final examination you must achieve a minimum of 40% to pass the paper.

Impairment or Other Problems

Occasionally students encounter various difficulties that affect their ability to study (examples could include: bereavement, accidents, illness, depression, anxiety, or learning difficulties). If you do find that something is affecting your performance please contact the HUBS Course Administrator (**hub-admin@otago.ac.nz**) to discuss what assistance is available. All such discussions will be confidential. Please seek help as soon as you feel your performance is being affected to enable special arrangements to be made, if applicable.

If a longer-term absence is unavoidable, please contact the HUBS Course Administrator in order to organise ways of minimising your absence from labs and lectures. Obtain a note from an appropriate person, *e.g.* your coach. Be aware that the responsibility for catching up on missed work is your own.

Disabilities

If you have a disability that may require special consideration or facilities with respect to this course, please contact the HUBS Course Administrator (hub-admin@otago.ac.nz), or contact Disability Information & Support:

website: http://www.otago.ac.nz/disabilities

email: disabilities@otago.ac.nz

phone: (03) 479 8235

Timetable Changes

Any changes to lab or lecture streams should be arranged *via* the HUBS Office and will only be accepted for students with clear evidence of need. Acceptable reasons for stream changes include timetable clashes, documented evidence of unavoidable work or childcare arrangements, national or international sporting commitments, or unavoidable cultural or religious commitments. Some other reasons may be accepted if you can provide written evidence of why a change is needed.

Assistance with Understanding the Course Material

Teaching Fellows and Demonstrators are in labs to assist you with course content - it is suggested that you make the most of the time available in labs to understand the course material and to ask any questions you may have regarding course content with the Teaching Fellows and Demonstrators.

In addition, consultation sessions with a Teaching Fellow are available regarding the academic content of the course (the material taught in labs, lectures and GLMs). These sessions are held weekly on Wednesdays in the HUBS lab from 12.30pm-1.30pm. A Thursday session will be held in the last two weeks of the semester for Immunology questions. To book a 10-minute session during these times, please contact the HUBS Teaching Fellows (**HUBS-TF@otago.ac.nz**)

Your Responsibilities

☑ Regularly check your Otago Student email for communication from the HUBS Office.

Laboratory practical sessions offer an opportunity to engage with and apply information that you have read about in the textbook and learned about through lectures.

Check on eVision website and fill in the following:

I will attend a laboratory every two weeks and always on a _____(day of the week) at _____(time).

As a student of HUBS 191, I understand that for my six laboratory practical sessions I am expected to:

☑ Attend every session at the time allocated to me.

☑ Read the appropriate section in my lab manual before attending.

☑ Bring my lab manual, a lab coat, and shoes that enclose my feet to every practical session.

☑ Abide by the rules regarding safety and appropriateness when in the laboratory.

☑ Complete pre-lab tasks.

☑ Listen carefully to the introduction of the material to be covered.

☑ Use the resources available and the help of the demonstrators/facilitators to complete the tasks and answer the relevant questions.

☑ Scan your ID card on entering the lab AND log in to LabTutor to complete the summary quiz before leaving the laboratory at the end of the lab session (**this will register your attendance**).

☑ Look up the model answers to the laboratory manual questions on Blackboard after the end of the current lab cycle.

☑ Understand the material dealt with in the laboratories as this may feature in the final exam.

Student ID							

HUBS Lab Code of Conduct

All cadaveric human material in the HUBS lab has been obtained as a result of people generously bequeathing their bodies for teaching and research. Plastinated prosections and human bones are as much human material as bodies or body parts. All who study this material should do so with respect, realising the immense privilege of having access to such material. The HUBS courses comply with the Human Tissue Act, and are under the jurisdiction of the Inspector of Anatomy who is a senior police officer with legal obligations to carefully maintain and track all human material.

We expect you to act ethically and morally when handling human material. It is your responsibility to adhere to the following rules in the HUBS Lab.

Initial

- Students are not permitted to bring visitors to the HUBS laboratory, and must have their student ID card available when attending their scheduled labs for attendance purposes. _____
- The use of photographic devices (especially cellphones) is STRICTLY forbidden. _____
- Parts of individual bodies must be kept together. They must not be removed from the table to which they belong. Under no circumstances may any body part be removed from the classroom. _____
- Do not remove ANY equipment from the HUBS Laboratory e.g., models, instruments, laminated diagrams, dissection guides, gloves, protective equipment, etc. _____
- As a sign of respect, headwear (including sunglasses and hoods) must not be worn in the HUBS laboratory. A hat or headdress may be worn for religious or cultural purposes only. _____
- A clean white lab coat should be worn at all times when working with human material. Footwear in the lab should fully enclose the feet i.e. no jandals, sandals, etc. _____
- No food or drink is to be consumed within the HUBS laboratory – including chewing gum. _____
- Do not tamper with any files on the computers within the HUBS laboratory – including modifying the desktop. _____
- Students are required to comply with the proper directives of any and all HUBS staff as per the Otago University Code of Student Conduct. _____

Any breach of these rules is a potential disciplinary matter. Students found in breach of this code are liable to be excluded from practical classes, regardless of the consequences for their performance in the particular course.

I confirm that I have read and understood this Code of Conduct and I agree to abide by these rules.

Name (in capitals) _____

Student ID number: _____ **Paper code:** _____

Signature: _____ **Date:** _____ / _____ / _____

Lab 1: Musculoskeletal Tissues and Movement

This first laboratory session will be divided into four parts; orientation to laboratory and health and safety, then tissue types, followed by anatomical terminology and finally, a look at the human skeleton.

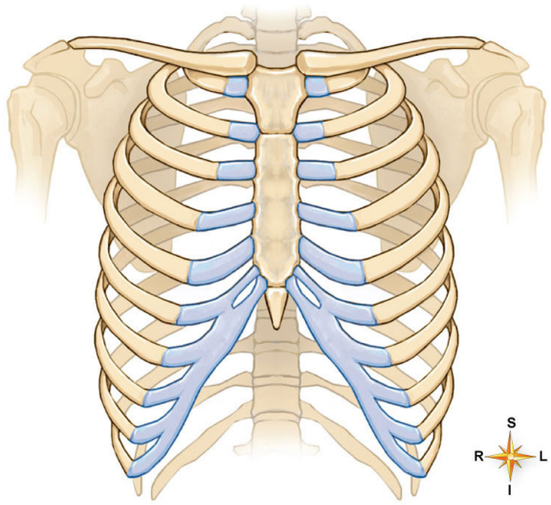

Fig. 1.1 *Thoracic cage (Fig. 9-15, Patton and Thibodeau 8th Edn., 2013)*

Pre-lab Preparation

All future labs require pre-lab preparation. You will get more out of labs if you prepare by reviewing related lectures and textbook material, and completing tasks where indicated.

Aim

This session will comprise an introduction to the course and laboratory protocols. The first steps in understanding human movement are to become familiar with both the structures involved and their relationships within the body. In this practical session you will be introduced to anatomical terminology including the terms used to describe movements. You will also be introduced to the structure and form of human bones and their function within the human skeleton.

Objectives

By the end of this lab you should be able to:

A. Understand and ensure a safe working environment in the laboratory for you and those around you.

B. Outline the legal, ethical, and moral considerations involved in using human and animal material.

C. Define and demonstrate the anatomical position. Use anatomical terms to describe direction and position.

D. Define the anatomical planes.

E. Identify 'types' of bones.

F. Use anatomical terms to describe movements.

Part A: Laboratory Safety

1. It is the responsibility of all of us to ensure a safe working environment for ourselves and also for those around us. In order to achieve this the following rules must be observed:

2. Closed shoes (heel to toe) must be worn in the laboratory at all times. Lab coats must be worn unless you are instructed otherwise.

3. Personal belongings must be stored in the storage units provided. Do not leave your coat or bag where someone may trip over it.

4. Do not put anything in your mouth while in the laboratory, including gum.

5. All accidents must be reported at once to a staff member. Do not attempt to clean up spills of body fluids. Alert a demonstrator immediately.

6. Pay attention to hazardous chemicals information. You will be made aware of all known hazards in your working environment before you begin work. It is your responsibility to listen and take any steps required to ensure your own safety. If you do not understand, ask!

7. All specimens of human origin must be considered as capable of transmitting infectious disease and treated accordingly (ask a demonstrator if you have any questions).

8. All cuts and abrasions on hands must be covered with an occlusive (not perforated) dressing.

9. Any skin puncture must be reported to a demonstrator immediately.

10. Familiarise yourself with the location and use of safety equipment such as safety kits, eye wash stations, fire extinguishers and fire exits.

11. Exercise care when disposing of material after laboratories. Do not endanger the health of staff by disposing of hazardous material in the wrong place. You will be informed where potentially dangerous material should go.

12. Report any unsafe practices or situations to the Red Coat.

13. Do not remove any material from the laboratory that you did not bring in yourself.

14. Wash your hands at the hand wash stations before leaving the laboratory.

In the Event of an Emergency

In the event of a FIRE ALARM, leave via the exit closest to you. Students on the Clocktower side of the laboratory should exit through the MAIN LAB EXIT. All others should leave by the CUMBERLAND ST EXIT (see Fig. 1.2). Follow the instructions given by staff at the time. Everyone should assemble over by the 'grassy knoll' to the east of the Microbiology Building.

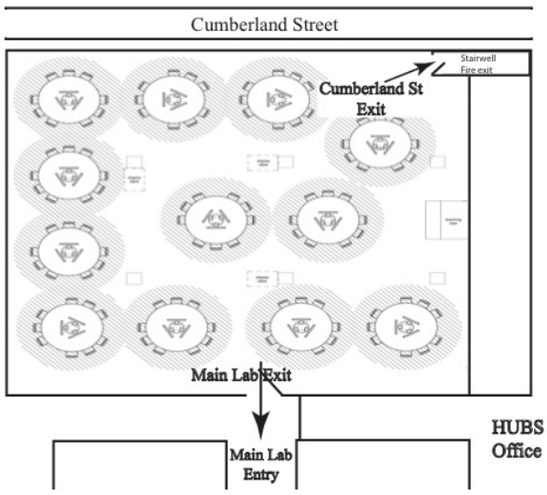

Fig. 1.2 *Location of emergency exits*

Legal and Ethical Issues

During some labs, both animal and human material will be used. This means that you will have access to both human and animal tissue along with other items such as bones and models in one room. In these instances you must be particularly vigilant in order to avoid any cross contamination between these elements. Different gloves must be used to handle each of them, and they must remain on their separate and allotted tables.

You must treat all human tissue with respect as access to this is a privilege. Please note, the wearing of hats and sunglasses is prohibited unless for religious, cultural or health reasons. You must handle all models with care as they are extremely expensive and difficult to replace. Any deliberate mistreatment of specimens or models will be taken seriously.

You will be given the opportunity to examine embalmed and plastinated human material. The use of such material is important for your understanding of anatomy. These prosections must be treated with respect. The use of such material is regulated by legal provisions (The Human Tissue Act, 2008). The most relevant of these for the HUBS 191 course is that under no circumstances is anything to be removed from the laboratory class. Any breach of these rules of conduct for handling prosected human parts will be dealt with by the University disciplinary authorities.

The use of animal material in research and teaching is regulated by the Animal Welfare Act (1999). The National Animal Ethics Advisory Committee has established guidelines to assist all institutions to comply with these regulations. These require Institutional Animal Ethics Committees (IAEC) to regularly review all studies involving the use of animal material. The IAEC is empowered to approve, defer, or decline proposed animal work and has the authority to inspect facilities, observe animal manipulations and terminate animal usage as necessary. The staff teaching this course can provide further details and explain the operation of the University of Otago's Animal Ethics Committee.

POST-LAB TASK

Why are open shoes inappropriate in a laboratory environment?

Why is a normal (perforated) dressing not sufficient?

Where can you go and what should you do if you accidentally splash something in your eyes?

In what two ways is cross contact (contamination) between human tissue and other items in the lab avoided?

Part B: Basic Human Tissues

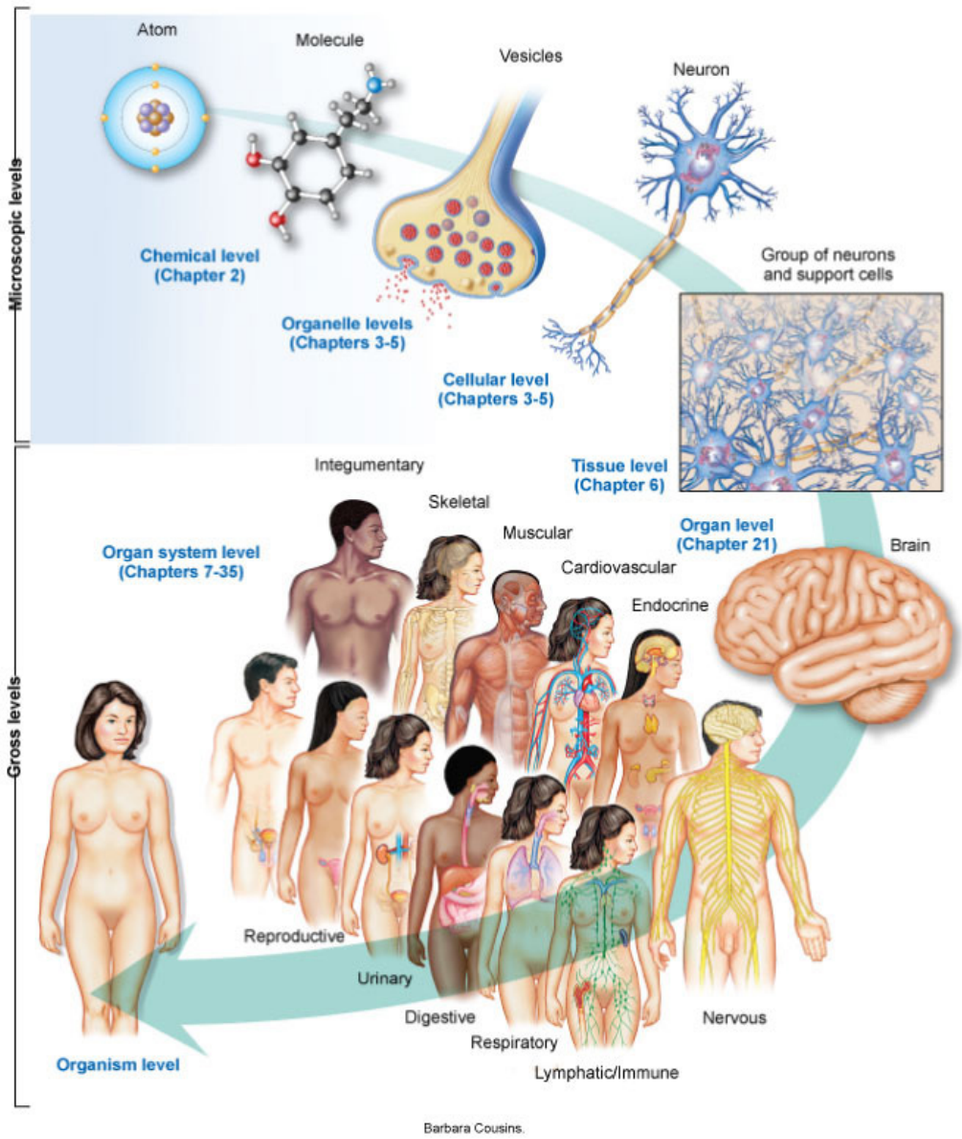

Fig. 1.3 *Levels of organisation (Fig. 1-3, Patton and Thibodeau, Anatomy & Physiology, 8th Edn, Elsevier, 2013)*

Levels of Organisation

The smallest parts of the body are **atoms**, which make up the chemicals, or molecules, of the body. Molecules make up parts called organelles that fit together to form **cells** of the body. Groups of similar cells are called **tissues**, which combine with other tissues to form **organs**. Groups of organs that work together are called **systems**. All the systems of the body together form an individual **organism**.

Tissues of the Body

A tissue is a group of cells that perform a common function. Tissues can be thought of as the fabric of the body, which is 'sewn together' to form organs and to hold the organs together as a functional unit.

The distinct forms of tissues in the body form early in the embryonic period of development (*i.e.* during gestation/pregnancy). Although there are several subtypes of tissues, all tissues can be classified into four basic types by their structure and function

The Four Basic Tissues

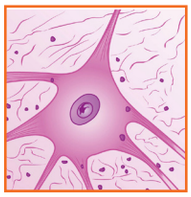

Nervous tissue is the most complex tissue of the body. Nervous tissue provides communication between various parts of the body, and integrates activities between them. This type of tissue is able to generate complex messages to control and coordinate most functions of the body. This tissue has many cell types including neurons (conducting cells) and neuroglia (support cells).

Examples in the body include: tissue of the brain and spinal cord, nerves, and sensory organs.



Muscle tissue produces movement of the body and its parts, and movement of organs. Muscles cells are contractile and produce movement by shortening. Muscle tissue is also responsible for producing most of the heat of the body.

Examples in the body include: muscles of the limbs and trunk, muscles in the walls of hollow organs (stomach, intestines), and heart muscle.

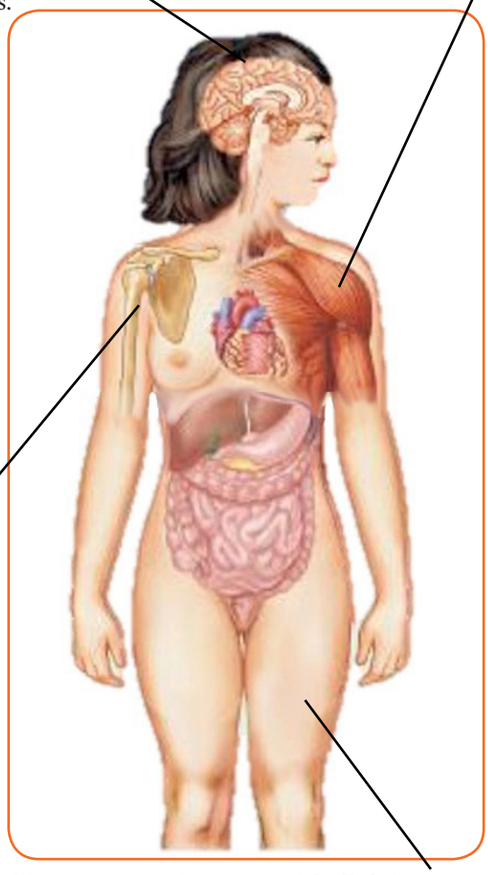



Connective tissue supports the body by holding parts together, transporting substances through the body and protecting the body from foreign invaders. The cells in connective tissue are relatively far apart with large quantities of matrix surrounding the cells.

Examples in the body include: bones, tendons, ligaments, cartilage, adipose (fat), and blood.

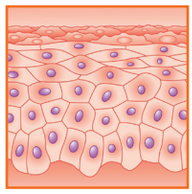

Epithelial tissue covers and protects the body surface, lines cavities, transports substances into & out of the body (or organs), and forms many glands. The cells in epithelial tissue are usually arranged in one or more layers, very close together and with very little extracellular matrix.

Examples in the body include: outer layer of skin, the lining of the respiratory, digestive, urinary and reproductive tracts, and glands of the body (pancreas, salivary, adrenal).

Fig. 1.4 *Basic tissues of the body (Adapted from Fig. 36-16, Patton & Thibodeau, Anatomy and Physiology 8th Edn, 2013)*

Task B.1

The following histology images (micrographs) are examples of the four basic tissue types. **Identify each tissue type and complete the following questions (there are files to help you with this on your desktop in the "Lab 1" folder).**

This tissue consists of one or more layers of densely arranged cells; covers and protects the body surface; lines body cavities/passage ways.

What basic tissue type is this?

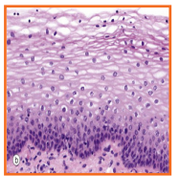

An example in the body is:

The lining of the oral cavity, pharynx and oesophagus

This type of tissue has long fibre-like cells, sometimes branched; capable of pulling loads. Produces body movements, organ movements, and heat.

What basic tissue type is this?

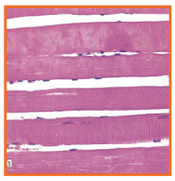
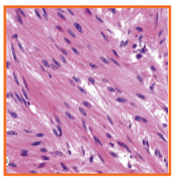
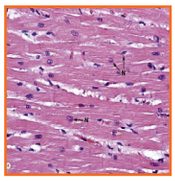

Three examples in the human body are:

1)

2)

3)

This tissue is a mixture of many cells types, which include conducting cells (neurons) and support cells (glia). It provides communication from a region of the body to other cells/tissues and integrates/regulates most functions in the body.

What basic tissue type is this?

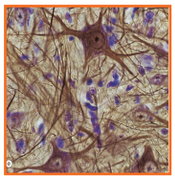

Three examples in the body are:

1)

2)

3)

Sparsely arranged cells surrounded by extracellular matrix (fibres and ground subctance). In some cases, the extracellular matrix contains structural fibres and mineral crystals.

What basic tissue type is this?

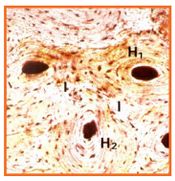

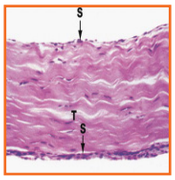

Three examples in the body are:

1)

2)

3)

Major Tissues of the Body *(figures adapted from Young B., Wheater's Functional Histology, 6th Edn., 2014)*

Part C: Anatomical Terminology and Skeletal Anatomy

The first steps in understanding human movement are to become familiar with both the structures involved and their relationships within the body. During this section of the lab you will be introduced to anatomical terminology, including the terms used to describe movements. You will also be introduced to the structure and form of human bones and their function within the human skeleton.

Anatomical terms are essential for the accurate description of the orientation and relationships of structures.

To avoid confusion the terms used to describe positions, relationships, and directions within the human body are always in reference to the **standard anatomical position**.

The **standard anatomical position** is standing upright, looking straight ahead with the feet and the palms (anterior surface) of the hands facing forwards. Directional terminology always refers to the body as if it were in this position, **regardless of its actual position**.

Planes are imaginary flat surfaces (see Fig. 1.5) along which the body can be sectioned (divided) to enable precise descriptions of relationships between structures. There are infinite sections along each of these planes.

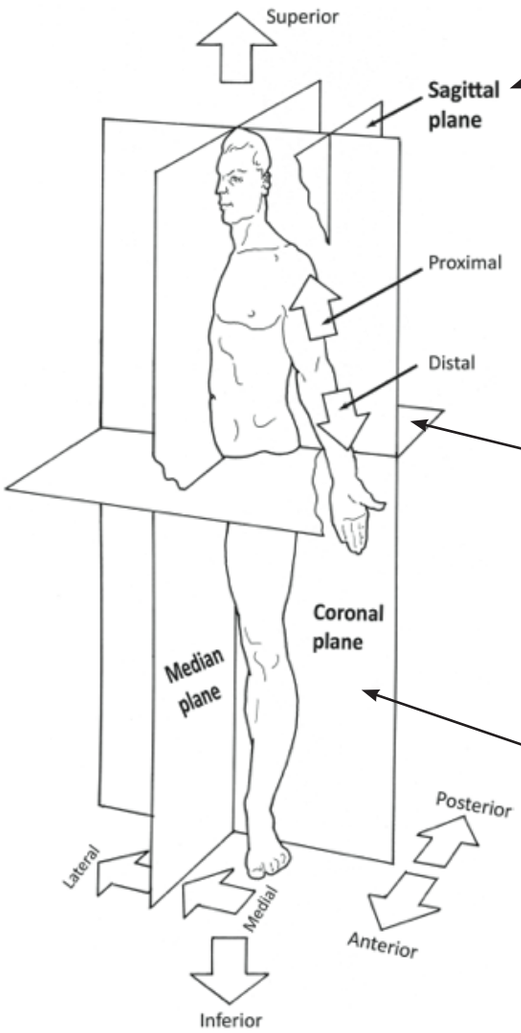

Sagittal Plane

A plane running vertically through the body, separating it into left and right parts.

*The **median** plane (or mid-sagittal plane) is the only sagittal plane that divides the body into equal left and right parts (also called the mid-sagittal plane).

Transverse Plane

A plane running horizontally through the body or a limb, separating it into superior (upper) and inferior (lower) parts.

Coronal Plane

A plane running vertically through the body, separating it into anterior (front) and posterior (back) parts. Also known as the frontal plane.

Fig. 1.5 *The anatomical position. (Adapted from Kapit & Elson, The Anatomy Colouring Book, Harper Collins, 1977).*

Question C.1

If you were in the standard anatomical position, the anterior surface (palms) of your hands are in the **coronal plane**.

Examine an articulated skeleton (on a stand). Is the skeleton demonstrating/positioned in the standard anatomical position? If not, which body parts are out of place?

Task C.1

On Fig. 1.6, draw lines that would section (portion) your own body into:

- two pieces along the median sagittal plane
- two pieces along another, more laterally positioned, sagittal plane.
- two pieces along a transverse plane

Demonstrate to your neighbour how you could section your own body into two pieces in the coronal plane.

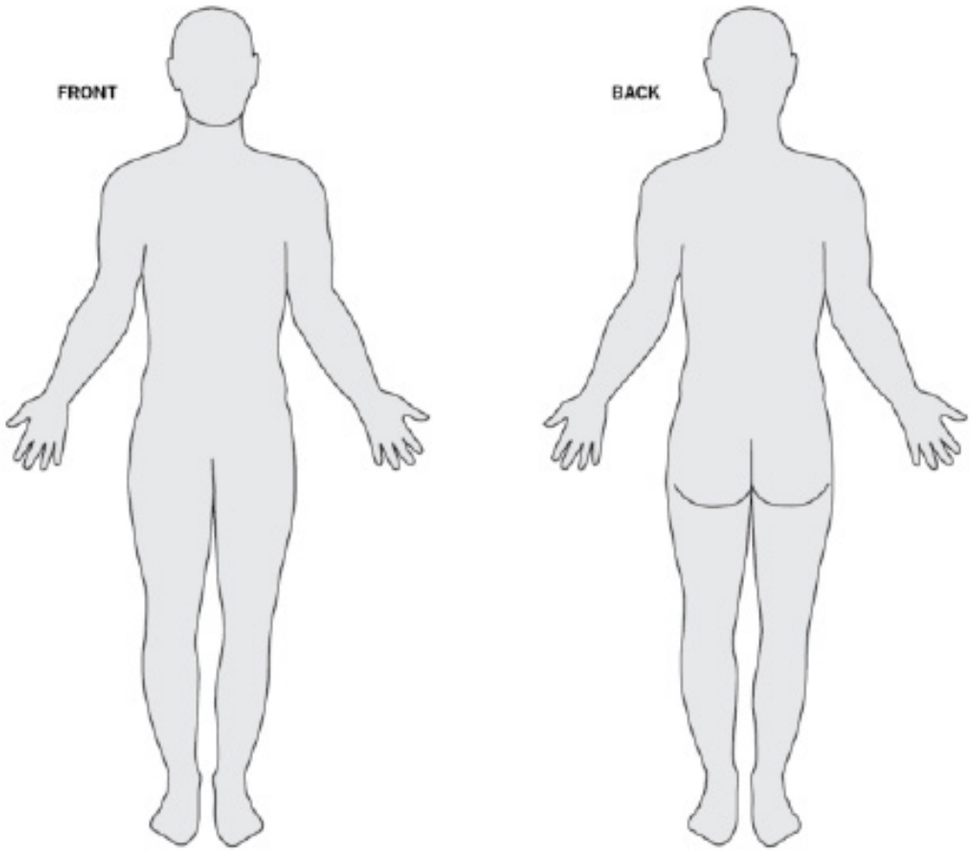

Fig. 1.6 *The standard anatomical position (Anatomy Teaching Resources).*

Task C.2

Use **Fig. 1.5**, and the glossary (at the end of your lab manual), to fill in the table below.

Directional Term	Description	Example
Superior	Closer to the head	The _____is superior to the chin.
Inferior	Closer to the feet	The thorax (chest) is inferior to the _____ .
Anterior	Closer to the front	The _____ are anterior to the heels of the feet.
Posterior	Closer to the back	The vertebral column (spine) is posterior to the _____ .

Task C.3

Use **Fig. 1.5**, and the glossary (at the end of your lab manual), to fill in the table below.

Directional Term	Description	Example
Medial	Closer to the median plane	The _____ is medial to the ear.
Lateral	Further away from the median plane	The elbow is lateral to the _____ .
Proximal	Nearer to where the limb attaches to the trunk	The shoulder is proximal to the _____ .
Distal	Further away from where the limb attaches to the trunk	The wrist is distal to the _____.

Question C.2

Which structure is more lateral, the vertebral column (spine) or the upper limb?

Question C.3

Proximal and distal are terms used especially for the limbs. Is it correct to say that the elbow is proximal to the wrist?

Task C.4

Now move out of the standard anatomical position by raising your upper limb above your head and flexing (bending) the elbow so that your hand is behind your head.

Is it still correct anatomical terminology to say that the wrist is distal to the elbow? Why?

Task C.5

Use the glossary, to fill in the table below.

Directional Term	Description	Example
Deep 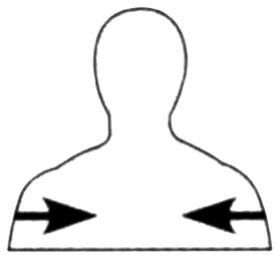	Further from the surface	The muscles are deep to the skin. The bones are deep to the _____. The stomach is deep to the _____.
Superficial 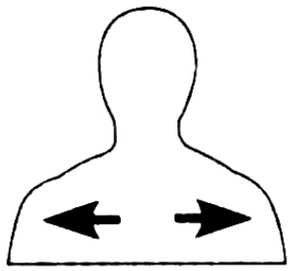	Closer to the surface	The skin is superficial to the muscles. The skin is superficial to the liver. The muscles in the thigh are superficial to the _____ (thigh _____).

Anatomical Terms Used to Describe Movements

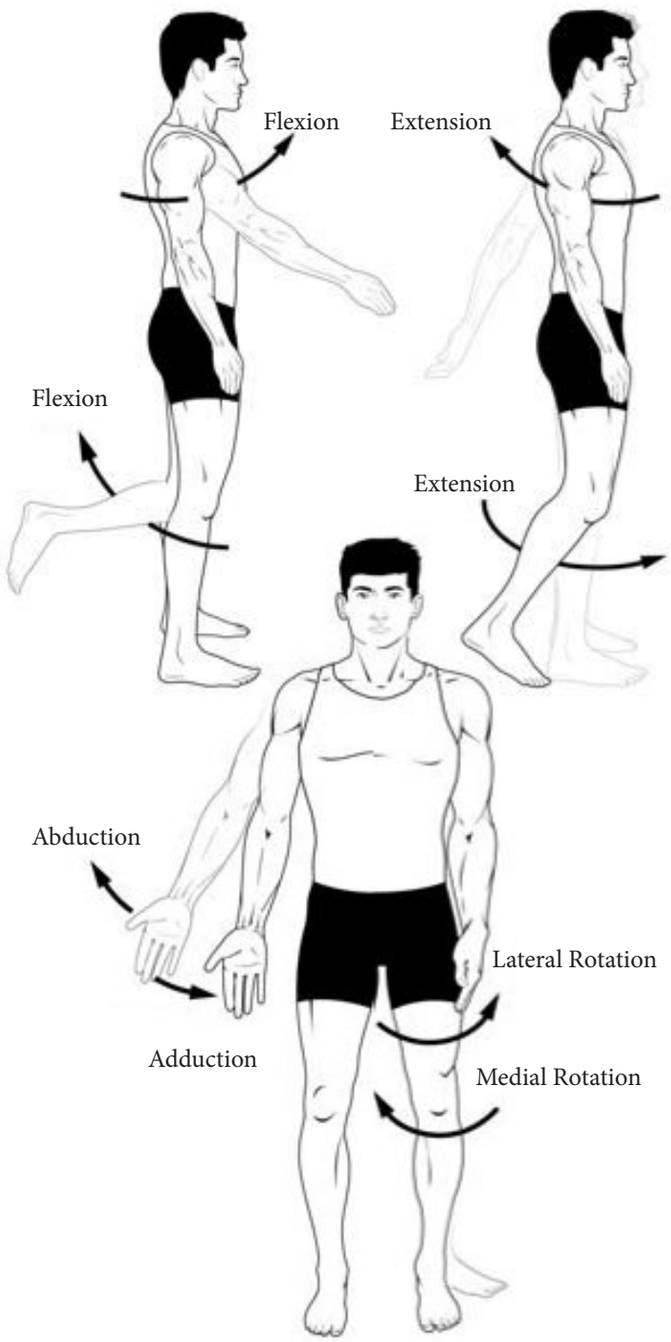

Fig. 1.7 *Anatomical terms for movement (Anatomy Teaching Resources).*

FLEXION

Decreases the angle between two bones at the joint. This movement is in the **sagittal** plane.

EXTENSION

The reverse of flexion at each joint, usually resulting in straightening the joint. This movement is in the _____ plane.

ABDUCTION

The movement away from the median plane of the body.

ADDUCTION

The reverse of abduction, *i.e.* towards the median plane. As for abduction, this movement is in the **coronal** plane.

CIRCUMDUCTION

This is combination of the four above movements; flexion, then abduction, then extension, then adduction.

ROTATION

The turning of a bone at the joint, around its long axis. This movement is in the **transverse** plane. Rotating your femur at the hip joint so that your toes are facing inwards is an example of lateral / medial (circle one) rotation.

Question C.4

How does circumduction of the shoulder joint differ to rotation of the shoulder joint?

Task C.6

Stand in the standard anatomical position and demonstrate flexion and extension at the following joints:

- ☐ **Elbow**
- ☐ **Wrist**
- ☐ **Hip**
- ☐ **Knee**

Task C.7

Demonstrate abduction and adduction at the following

- ☐ **Shoulder**
- ☐ **Wrist**
- ☐ **Hip**

Task C.8

Stand in the standard anatomical position and circumduct your shoulder and hip - remember this is a combination of flexion, then abduction, then extension, then adduction (or the same reversed).

Task C.9

Rotate your arm at your shoulder joint. It is important to ensure that it is your humerus that is rotating and not your forearm. You can also rotate your forearm. In this case the movement of turning the palm of your hand backwards (from the standard anatomical position) is **pronation** and the reverse movement is **supination**.

Task C.10

Pronate and supinate your forearm and the forearm of a skeleton. What happens to the radius (relative to the ulna) in full pronation?

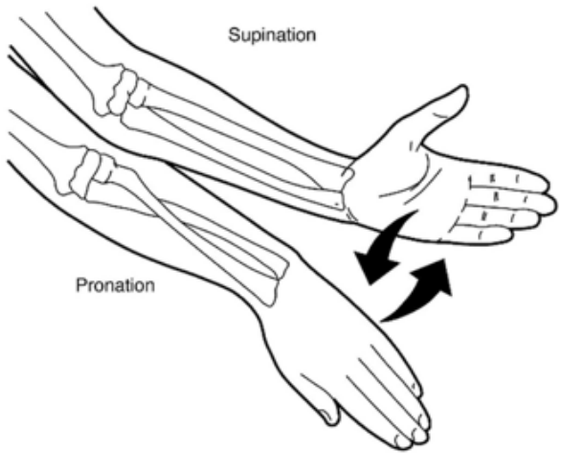

Fig. 1.8 *Pronation and supination. (Adapted from Marieb and Mallatt, Human Anatomy, 2nd Edn., Benjamin Cummings, 1997.)*

Task C.11

Imagine a door knob that turns anti-clockwise. A right-handed person opening that door would need to forcefully perform which movement of the forearm?

Opposition is the movement of the thumb that moves it across the palm of the hand to touch the tip of any finger. This is a special movement as it allows for the grasping and manipulation of objects.

Task C.12

Demonstrate opposition to your neighbour.

Question C.5

Do most other mammals have opposable thumbs?

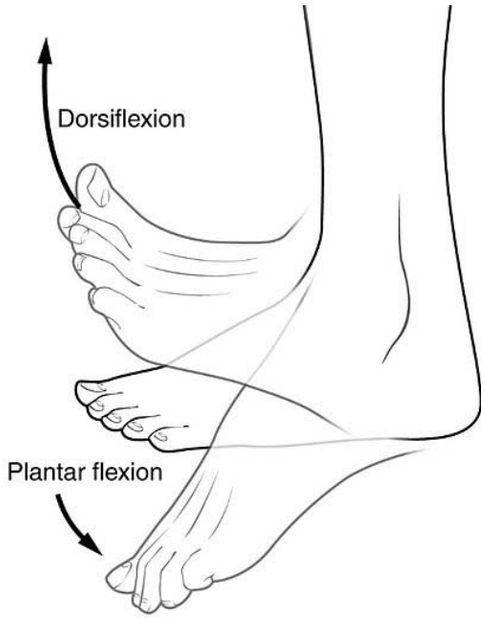

Fig. 1.9 *Dorsiflexion and Plantarflexion. (Adapted from Marieb and Mallatt, Human Anatomy, 2nd Edn., Benjamin Cummings, 1997.)*

Dorsiflexion is when the foot is lifted upwards, as is standing on the heel (also referred to as flexion). This movement is in the **sagittal** plane.

Plantarflexion occurs when the foot is pushed downwards, as in standing on tip-toes (also referred to as extension). This movement is in the **sagittal** plane.

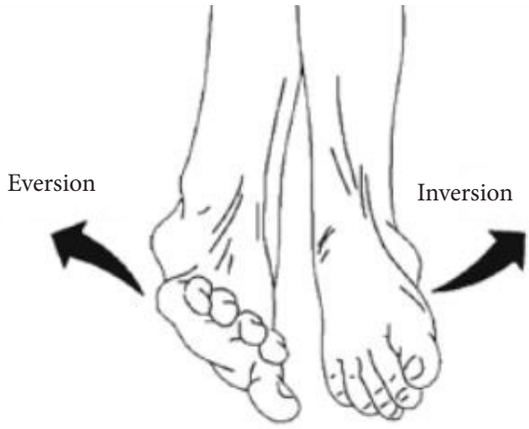

Fig. 1.10 *Inversion and eversion. (Adapted from Marieb and Mallatt, Human Anatomy, 2nd Edn., Benjamin Cummings, 1997.)*

Inversion is turning the sole of the foot inwards.

Eversion is turning the sole of the foot outwards.

Task C.13

Perform each of these four movements listed, demonstrating them to your neighbour.

- ☐ **Dorsiflexion**
- ☐ **Plantarflexion**
- ☐ **Inversion**
- ☐ **Eversion**

Question C.6

Dorsiflexion and plantarflexion occur at which joint of the lower limb?

Question C.7

Inversion and eversion occur at which joint of the lower limb?

Part D: The Skeleton

The five functions of the skeleton are: support, movement, protection, mineral storage and blood cell formation. The following section describes identifying and categorising major bones and bone groups of the skeleton.

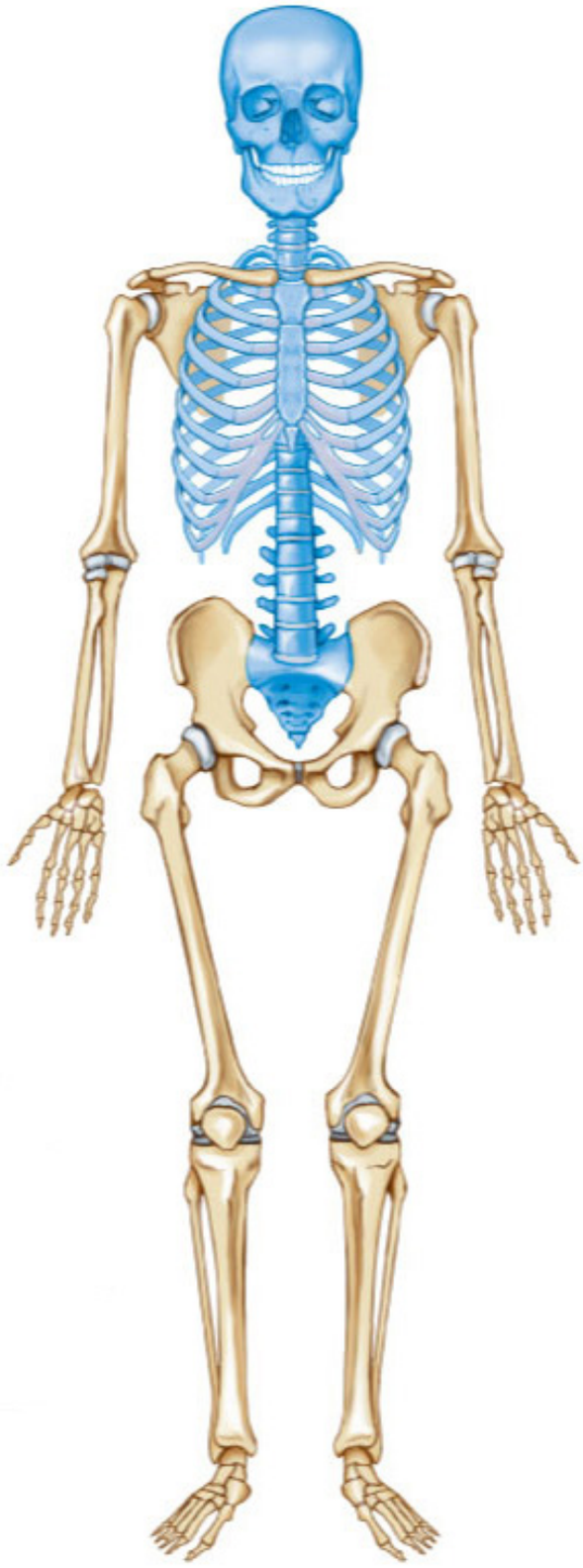

Fig. 1.11 *Anterior view of skeleton (Fig. 9-1A, Patton and Thibodeau 8th Edn, 2013)*

Identification and Types of Bones

The bones of the skeleton are grouped into broad categories of 'long', 'short', 'flat' and 'irregular' shapes. For the following tasks, examine one of the articulated skeletons (on stands) and the disarticulated bones (loose bones on each table) to become familiar with the range of sizes and shapes.

Long bones

These bones are longer than they are wide. Long bones consist of a shaft, and two expanded ends, which have articular surfaces forming joints. One end of a long bone is often termed the head. This can be identified by its relatively round shape compared with the other end.

Task D.1

Label the head, neck, and shaft of the humerus.

Fig. 1.12 *An example of a long bone (adapted from Marieb & Mallatt, Human Anatomy , 2nd Edn., Benjamin Cummings, 1997).*

Flat bones

These bones are mostly thin, flattened and usually curved.

Fig. 1.13 *A rib. An example of a flat bone (Patton & Thibodeau, Anatomy & Physiology, 8th Edn, 2013).*

Irregular bones

These are bones that do not fit into the other categories of bones. Generally, these types of bones will have a foramen (hole) through them.

Fig. 1.14 *The hip bone. An example of an irregular bone (Patton & Thibodeau, Anatomy & Physiology, 8th Edn, 2013).*

Short bones

These types of bones are roughly cube like or round.

Fig. 1.15 *The carpal bones of the wrist. An example of short bones (Patton & Thibodeau, Anatomy & Physiology, 8th Edn, 2013).*

Question D.1

Which categories would define the following bones? (e.g. long, flat, irregular or short?)

- **The femur (thigh bone) is a _____ bone.**
- **The phalanges (finger bones) are _____ bones.**
- **The scapula (shoulder blade) is a _____ bone.**
- **Vertebra(e) are _____ bones.**

Naming, Identification, and Description of Major Bones and Bone Groups

The skeleton may be subdivided into axial and appendicular parts.

For the following tasks, examine the articulated skeletons, the laminated sheet provided and the disarticulated bones. Also examine the bones and bone groups mentioned using your own bodies. It helps to fit the disarticulated bones into position on your own, or your neighbour's, body. Palpate (touch/feel) as much of the bone as you can in yourself.

Axial Skeleton

The bones of the axial skeleton comprise the main axis of the body, that is, the head, neck, and torso.

The cranium (cranial bones) and the facial bones make up the skull. All except the mandible (lower jaw) are fixed immovably together (except in infants).

Task D.2

Identify and examine the cranium and facial bones and then label the following bones on Figs. 1.16 & 1.17.

- ☐ frontal
- ☐ parietal
- ☐ occipital
- ☐ temporal
- ☐ facial bones (as a group)
- ☐ mandible (as part of the facial bones)

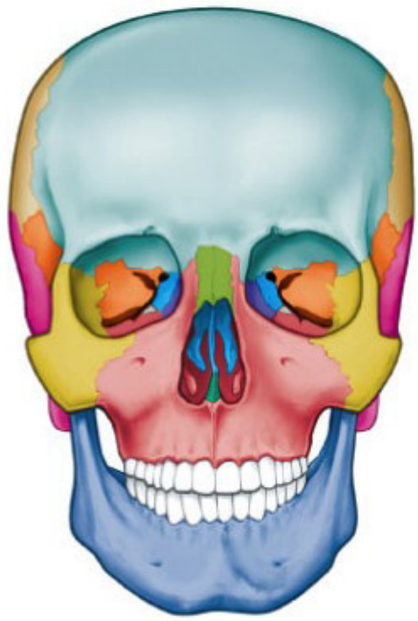

Fig. 1.16 *Anterior view of the skull (Fig. 9-2 Patton and Thibodeau 8th Edn., 2013).*

Fig. 1.17 *Rightside view of the skull (Fig. 9-2 Patton and Thibodeau 8th Edn., 2013).*

The Vertebral Column

The vertebral column (spine), is composed of vertebrae (singular = vertebra), the sacrum, and the coccyx (tailbone).

There are different regions of the vertebral column (from superior to inferior), composed of individual vertebrae, as well as some fused vertebrae.

Cervical - the seven smallest vertebrae in the neck, allowing a wide range of motion of the head and neck.

Thoracic - twelve vertebrae, allowing some movement and providing the sites of attachment for the ribs.

Lumbar - the five largest vertebrae, which support the trunk on the pelvic girdle, yet allow some movement.

Sacrum - five fused vertebrae that form the posterior wall of the pelvic girdle.

Coccyx – two to five fused vertebrae forming a single bone, located at the inferior region of the vertebral column.

Task D.3

Identify the vertebrae of these regions on the articulated skeletons and the disarticulated bones on your table. Label the regions on Fig. 1.18

Question D.2

A) How many individual, unfused vertebrae are there in total?

B) Note the differences in size and shape. Why might this be?

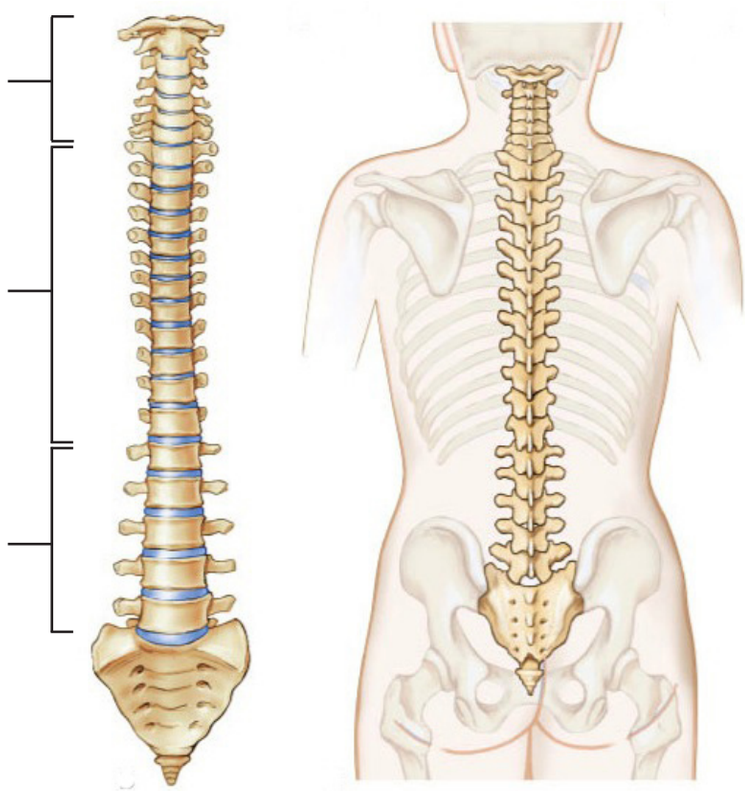

Fig. 1.18 *The vertebral column (Fig. 9-13, Patton and Thibodeau 8th Edn., 2013)*

The **thorax** (ribcage) is composed of ribs attached to the **sternum** (anteriorly, predominantly *via* cartilage) and vertebrae (posteriorly). The ribcage articulates posteriorly with the vertebral column and anteriorly with the sternum.

Question D.3

Examine the anterior and posterior aspects of the thorax of a standing skeleton.

A) How many ribs make up the ribcage?

B) How many of these ribs attach *via* costal cartilages to the sternum?

Appendicular Skeleton

These are the bones that comprise the appendages (or limbs). The limbs are identified as the: **upper limbs** and **lower limbs** (due to their location). Each limb has three major long bones, with groups of short bones and smaller long bones to make up the hand and foot.

The Upper Limb

The upper limb is the whole appendage, that is, from the shoulder to the fingers. It consists of several different regions. The **pectoral girdle** attaches the upper limb to the axial skeleton. The two bones of the pectoral girdle are the **clavicle** (collar bone) and the **scapula** (shoulder blade).

The **clavicle** acts as a strut to support the upper limb.

Task D.4

Identify and examine the clavicle and scapula and then label them on **Fig. 1.11.**

Question D.4

Which bone(s) does the clavicle articulate with?

Task D.5

Palpate (feel) your own clavicle. Notice that it can be palpated along its whole length.

Question D.5

Why is it possible to palpate the whole length of the clavicle?

The other bone of the pectoral girdle is the **scapula**, which is a flat, triangular shaped bone.

Task D.6

Examine the shape and bony projections of the scapula.

Question D.6

Which bone(s) does the scapula articulate with?

The **arm** is defined as the region from the shoulder to the elbow. The arm has a single long bone, the humerus.

The **humerus** has a spherical head forming the articulation at the shoulder joint and a condyle forming the articulation at the **elbow** joint.

Task D.7

Identify and examine the humerus and then label it on **Fig. 1.11.**

Task D.8

Locate the widest, bony points of the humerus in the **coronal plane**. These bony projections are located medial and lateral to the **condyle** of the humerus. These bony projections are called **epicondyles**. See Fig.1.19 below.

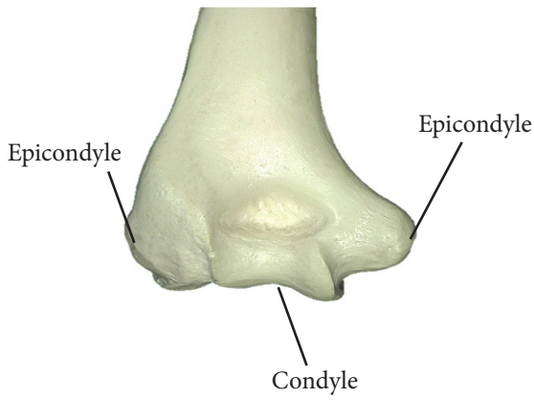

Fig. 1.19 *Distal region of humerus (Marieb & Mallatt, Human Anatomy , 2nd Edn., Benjamin Cummings, 1997).*

Question D.7

What do you think attaches (inserts) to the epicondyles of the humerus?

The **forearm** is defined as the region from elbow to wrist. The forearm has two long bones, the radius and the ulna. The radius has a round head at the proximal end, the ulna has a 'hook' shaped proximal end (the prominent olecranon process is the posterior part of the hook).

Task D.9

Identify and examine the radius and the ulna and then label these on **Fig. 1.11.**

Question D.8

In the standard anatomical position, where is the radius located in relation to the ulna? (Use the correct anatomical term).

Task D.10

On yourself or lab partner, flex your elbow and palpate the sharp point of the elbow. This is the olecranon process of the ulna.

Question D.9

At your wrist and on the skeleton, locate the bump on the medial posterior aspect of the wrist. Which bone are you palpating?

The **hand** consists of three sets of bones: the wrist bones (**carpals**), the bones of the palm (**metacarpals**), and the finger bones (**phalanges**).

The proximal part of the hand is the wrist and is formed by eight short carpal bones aligned in two rows.

The metacarpals form the palm of the hand and articulate with the phalanges (bones of the fingers and thumb, singular = phalanx).

The phalanges decrease in size towards the tips of the digits. Phalanges also have distal heads and proximal bases.

Question D.10

Proximally, the carpal bones articulate with only one bone. Which bone articulates with the carpals proximally?

Task D.11

Examine the metacarpals and the carpal bones and label them on Fig. 1.11. Locate the heads (distal) and the bases (proximal) of the five metacarpals.

Question D.11

With which region of the metacarpals do the carpals articulate with?

Task D.12

Examine the phalanges and then label them on **Fig. 1.11.**

Question D.12

How many phalanges are in each finger and how many are in each thumb?

The Lower Limb

The **pelvic girdle** (or pelvis) consists of two hip bones articulating posteriorly with the sacrum (you will remember this is the inferior region of the vertebral column, and therefore part of the axial skeleton as well as a part of the pelvic girdle). The lower limb is the entire appendage, from hip to toes, and consists of different regions.

Task D.13

Examine the hip bones on a skeleton and label them on **Fig. 1.11.**

Question D.13

Which bones do the hip bones articulate with anteriorly, laterally and posteriorly?
(Hint - look at the standing skeletons around the room!

Question D.14

Compare the pelvic girdle to the pectoral girdle. Do they differ in structure? Why might this be?

The **thigh** contains the femur, the largest bone in the body. It has a spherical head, which articulates with the pelvis at the hip joint.

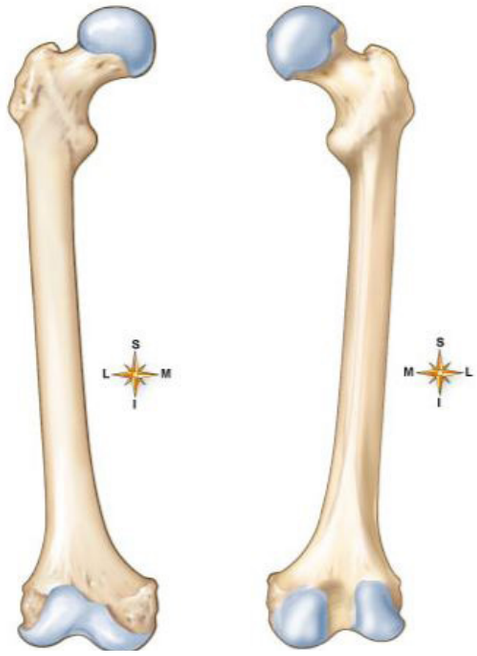

Fig. 1.20 *The femur. (Patton & Thibodeau, Anatomy & Physiology, 8th Edn, 2013).*

Question D.15

Note that the distal end of the femur is a smooth rounded surface with two large prominences. What are these prominences called?

Question D.16

Palpate the distal end of your femur, on the anterior aspect. What is the name of the bone that articulates with the femur in this region?

Task D.14

On a skeleton, examine the shape and position of the patella, and label it on **Fig. 1.11.**

The **leg** is defined as the region from the knee to the ankle. There are two bones in this region, the tibia and fibula.

Task D.15

On a skeleton, examine bones of the leg, and label them on **Fig. 1.11.**

Question D.17

A) Of the two bones in the leg, which is the largest?

B) Which of the bones of the leg lies laterally?

Question D.18

Palpate the large bump that lies anteriorly and just distal to the patella. Study the skeleton and disarticulated bones - which of the two leg bones are you palpating?

Question D.19

Which bones contribute to the 'bumps' on the lateral and medial aspects of the ankle?

The **foot** consists of three sets of bones, tarsals, metatarsals, and phalanges. They are structurally equivalent to the bones in the hand, but they are generally larger and more variable in size for the purposes of weight bearing.

There are seven tarsal bones in the foot. This group is equivalent to the carpal bones in the hand. There are five metatarsals that articulate with the tarsal bones. This group is equivalent to the metacarpals in the hand.

Question D.20

A) What differences can you see between the leg bones (*i.e.* the tibia and fibula) and the bones in the forearm (*i.e.* radius and ulna)?

B) What important function of the lower limb might explain these differences?

Task D.16

Examine the tarsal bones and find the two largest tarsal bones, the calcaneus (heel bone) and the talus (articulates with the tibia), and label them on **Fig. 1.11**.

Task D.17

Examine the metatarsal bones and then label this group of bones on **Fig. 1.11**.

Question D.21

A) How many metatarsals are there in each foot?

B) What is the name for the equivalent bones in the hand?

The most distal bones of the foot are those that form the toes, the **phalanges**.

Task D.18

Examine the phalanges and label them on Fig. 1.11.

Question D.22

How many phalanges are there in total in the human body (include the upper and lower limb)?

You have now finished the lab activities.

Please be sure to tidy up your area. Remember, if you have any questions don't hesitate to ask a demonstrator. If you are waiting for the wrap-up, there is additional material in the Lab 1 folder on your desktop.

NOTES PAGE:

Lab 2: Musculoskeletal Tissues and Movement 2

In this laboratory session you will be introduced to the structure and function of joints. You will also have the opportunity to see selected muscles of the upper and lower limb and, based on their location, deduce their influence at specific joints.

During this session it is particularly important that there is no cross contact between the human tissue and the other resources available in the lab.

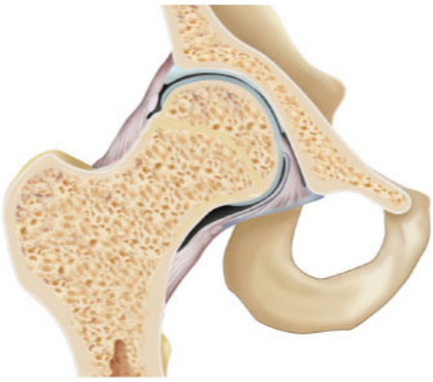

Fig. 2.1 *Hip Joint (Fig. 10-9, Patton & Thibodeau, Anatomy & Physiology, 8th Edn, Elsevier, 2013).*

Fig. 2.2 *Body's general musculature (Fig. 11-6, Patton & Thibodeau, Anatomy & Physiology, 8th Edn, Elsevier, 2013).*

Pre-lab Preparation

It is essential that you complete these activities prior to coming to the laboratories, as it will ensure that you make the most from your time within the lab.

- Read through this lab.
- Revise Anatomy lectures 8-14 and review associated readings and textbook pages.
- Complete Pre-lab Task 1 (page 32)

Objectives

By the end of this lab you should be able to:

A. Describe the gross structure of fibrous, cartilaginous and synovial joints and describe how their structure relates to their function.

B. Identify the types of soft tissues associated with synovial joints and how this relates to joint function.

C. Describe, explain and demonstrate the structure and movements possible at selected human limb joints, noting particular named muscles.

PRE-LAB TASK 1

Fill in the labels on the figure below and answer questions A, B and C

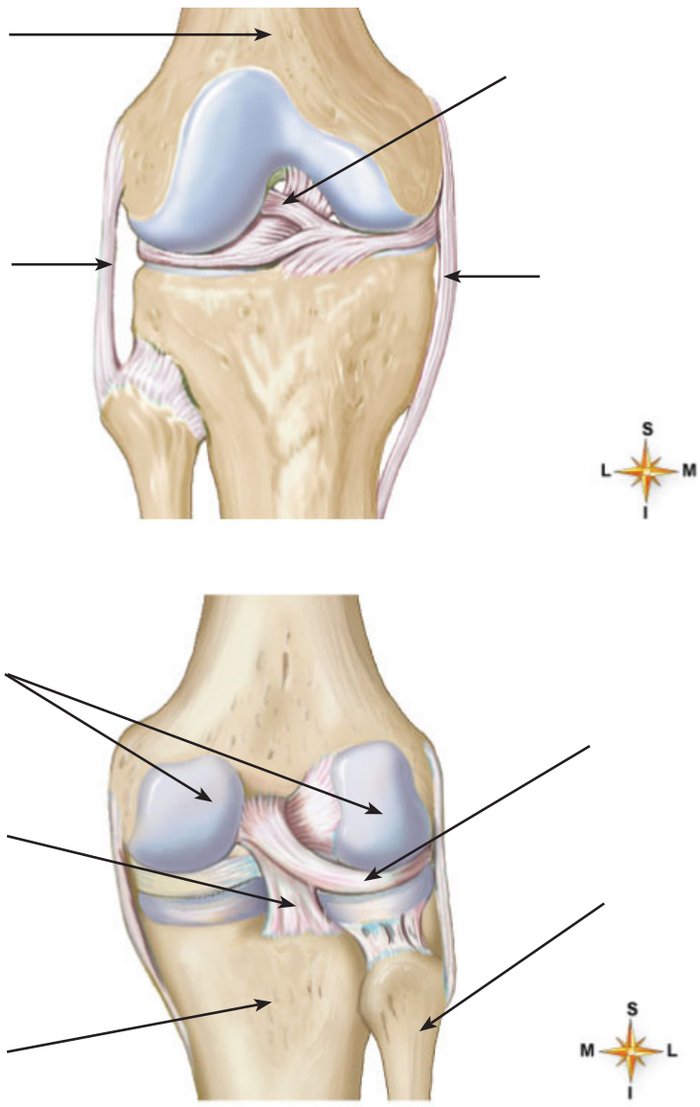

Fig. 2.3 *Knee joint (Fig. 10-10, Patton and Thibodeau 8th Edn., 2013)*

A) Name three tissues/structures located at a synovial joint that are essential for movement.

B) The collateral ligaments are thickened regions of what structure of the synovial joint?

C) Which two specific ligaments restrict movements in the sagittal plane?

Part A: Joints

Joints can be classified broadly by the connective tissues found between the bone ends. Movement is not a necessary attribute of a joint although, of course, most joints do move.

The three classes of joint that you should be able to identify are: **fibrous**, **cartilaginous** and **synovial**.

1) Fibrous Joints

The tissue that attaches the bone ends is dense fibrous connective tissue (DFCT). The two bones are held firmly together and allow minimal to no movement. The best examples are the sutures of the skull.

Task A.1

Look for the thin interlocking lines of the sutures on the skulls of the skeletons.

Task A.2

Draw a superior view of the skull.

Locate the sagittal and coronal sutures (joint lines) on the skull of a skeleton. Label these suture lines, and the anterior and posterior regions of the skull.

Question A.1

What function do you think is served by the sutures being fibrous joints?

2) Cartilaginous Joints

The tissue that attaches the bone ends is cartilage. The bone ends are firmly held together but a small amount of movement is available. An example is the joints between the bodies of the vertebrae.

Task A.3

Look at the skeletons and note the thickness of the cartilage between the vertebrae (the intervertebral dics). They serve as a cushion or "shock absorber".

Another example of a cartilaginous joint is the anterior joint between the hip bones, this is the **pubic symphysis**.

Question A.2

In women, the cartilage in the pubic symphysis can soften under the influence of certain hormones. When and why might this be useful?

3) Synovial Joints

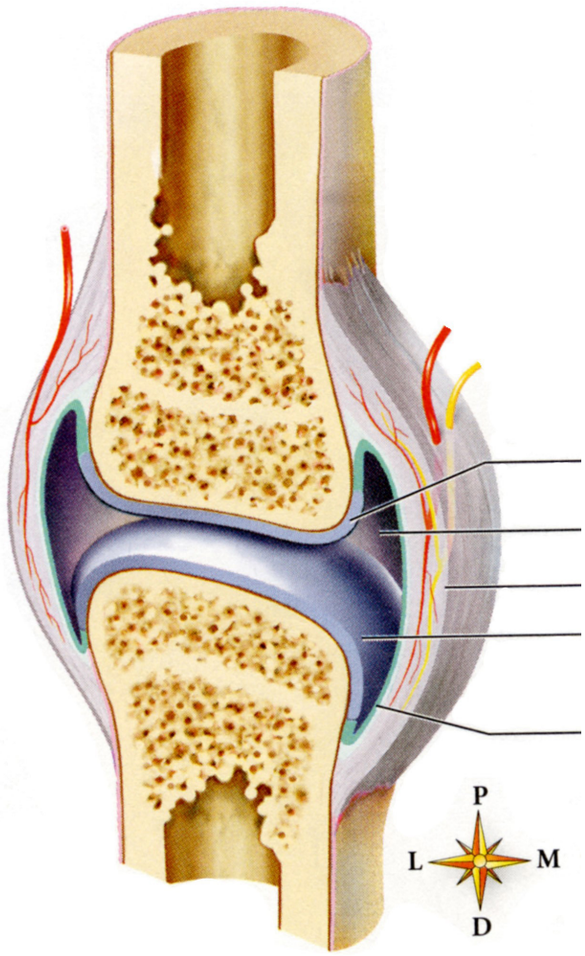

Fig. 2.4 *A synovial joint. (Fig. 10.3, adapted from Patton & Thibodeau, Anatomy and Physiology, 8th Edn., 2013).*

Task A.4

Label the following features of a synovial joint on Fig. 2.4. (Hint: you may need to use some labels more than once.)

the **synovial cavity**; **articular cartilage** (lining articular surfaces of bone); the **joint capsule** (incorporating capsular ligaments); the **synovial membrane**

Synovial joints allow movement through a very wide range - far more than fibrous or cartilaginous joints.

There is no direct bone to bone attachment by tissue at the bone ends, instead they are held together by a connective tissue "sleeve" (the **joint capsule**) attached at the margins of the joint. Note that the capsule surrounding the joint is strengthened/reinforced in some places forming capsular **ligaments**. (*e.g.* the collateral ligaments of the knee).

There is a potential space (or **synovial cavity**) between the bone ends, allowing the bones to move easily at the joint.

Cartilage covers the surfaces of bone which articulate with each other inside the joint. This is called **articular cartilage**.

The **synovial membrane** is very thin and covers structures within the synovial cavity other than those covered with articular cartilage. It can be thought of as the inner lining of the joint capsule.

Question A.3

A) Examine the standing skeleton; for the most part which type of joints have needed to be held together by wires and screws?

B) In living tissue what structure (other than muscle) would hold these joints together?

Movements of Synovial Joints

The types of synovial joints in the body are divided into three main groups: uniaxial, biaxial and multiaxial..

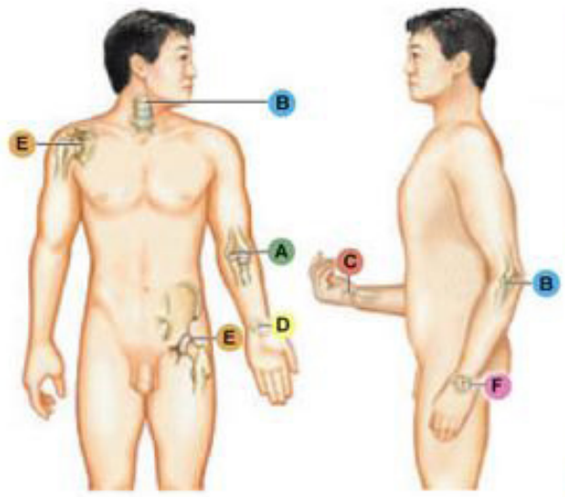

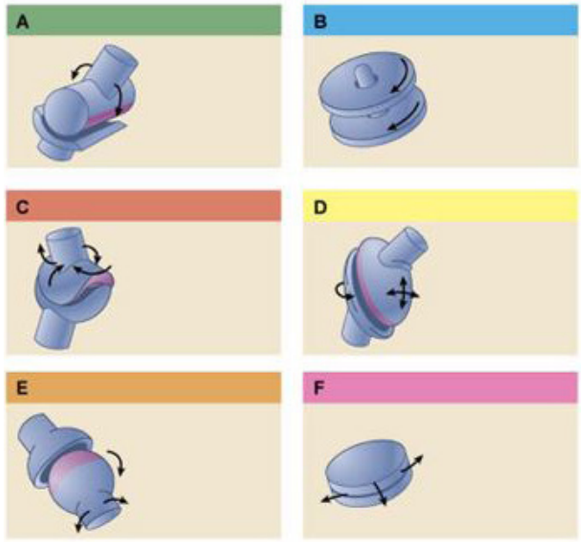

Fig. 2.5 *Types of synovial joints (Adapted from Fig. 10-4, Patton and Thibodeau, Anatomy & Physiology, 8th Edn., Elsevier, 2013).*

Table 2.1

Shape	Axis(es)	Structure	Movements	Example
Hinge	Uniaxial	A		
Pivot	Uniaxial	B		
Saddle	Biaxial	C		
Ellipsoid	Biaxial	D		
Condylar	Biaxial	* (See below)		
Ball & Socket	Multiaxial	E		
Plane	Multiaxial	F		

* NB - the knee joint (which you will see in part B) and the temporomandibular joint (TMJ) are examples of specialised joints called condylar joints.

Task A.5

Compare the range of movements in your wrist (an ellipsoid joint) and your kneee (a condylar joint).

Question A.4

A) What movement can you perform with the flexed knee that you cannot perform with the flexed wrist?

B) What are the structural reasons for the differences between these two joints?

Part B: Structure and Function of Synovial Joints

In this section you will explore the structures of synovial joints using general building/construction materials. These materials represent what you would see in a human.

Task B.1

On the computer, view the "Virtual Knee" and **follow through the directions outlined in "How to Make a Knee" (both these files located on the desktop in the Lab 2 folder).**



Fig. 2.6 *General materials used for constructing a knee (Anatomy Teaching Resources).*

Question B.1

Once you have finished Task B.1, answer the following question:

What do the objects in Fig. 2.6 represent?

A)

B)

C)

D)

Question B.2

The articular surfaces of objects A and B would normally be covered with what type of connective tissue?

Ligaments are extremely smooth due to the synovial membrane lining them. A ligament can be a thickened part of the joint capsule (e.g collateral ligaments).

Question B.3

Complete the following sentence:

Ligaments join _____ to_____, while

the tendons connect_____ to _____.

What objects did you use to replace ligaments?

Question B.4

What basic tissue are ligaments made from?

Why are the tendons and ligaments white?

Question B.5

Bone heals faster than ligaments when damaged. Why do you think it takes longer for DFCT structures to heal?

Question B.6

Why is the cartilage lining the ends of the bone able to survive without any blood vessels running through it?

A joint capsule forms a connective tissue "sleeve" surrounding the bone ends, and attached to the margins of the joint.

Question B.7

What general material was used to represent the joint capsule in Task B.1?

What lines some of the internal surfaces of the synovial joint and capsule, and lubricates the inside of the joint cavity?

Fig. 2.7 *Constructed wooden knee (Anatomy Teaching Resources).*

Normally, menisci are attached peripherally to the articular surface allowing some movement of the menisci as the joint is moved.

Question B.8

List the functions of the menisci that you would normally find in a knee joint.:

Part C: Structure, Form, and Movements at Specific Synovial Joints

The shapes of the articular surfaces of the bones determine the type of movement that can occur at a joint but in many cases the bones contribute surprisingly little to the stability of the joint.

Question C.1

What factors influence stability at a synovial joint?

Question C.2

What factors influence range of movement at a synovial joint?

Upper limb

Shoulder joint

The joint between the scapula and the head of the humerus is the shoulder joint and is a synovial joint of the **ball and socket** type.

Question C.3

Of the list below, which of the following movements are possible at the shoulder joint?

flexion, extension, adduction, abduction, rotation, circumduction, plantarflexion, opposition.

Task C.1

Move your own shoulder through its full range of movement. Note how the combined movements of flexion, abduction, extension, and adduction circumduct your arm in a full arc in either a forward or backward direction.

Next examine rotation at the shoulder. Remember to flex your elbow to ensure that it is the humerus in the arm which is being rotated, not the forearm.

Task C.2

Examine the standing skeleton and note the shape of the bones and how the bones fit together at the shoulder joint. Compare this fit with that of the large ball and socket joint in the lower limb.

Task C.3

Inspect the plastinated human shoulder joint and note how a series of capsular ligaments and muscles surrounding the joint help to hold the humerus in place, thereby helping to compensate for the poor fit of the bones.

Task C.4

Locate and examine the following muscles/muscle group on the embalmed human tissue:

- ☐ **Deltoid**
- ☐ **Biceps brachii**
- ☐ **Triceps brachii**

Question C.4

A) We have established that the shape of the bones allows the shoulder to be very mobile. What is a negative consequence of this arrangement of the joint?

B) Name one popular New Zealand sport that is likely to cause a dislocated shoulder joint and explain how this may occur.

Question C.5

Which bone forms the "ball" and which bone forms the "socket" at the shoulder (which in this case is called the glenoid cavity)?

Question C.6

A) Based on its location across the shoulder joint what is the main movement that concentric action of deltoid would produce?

B) Judging by the position and shape of the muscle, what other movements could deltoid assist with at the shoulder joint?

Task C.5

State the location of the muscle in relation to the shoulder joint and, using this information, deduce the concentric action that would be produced at the shoulder by contraction of the muscle:

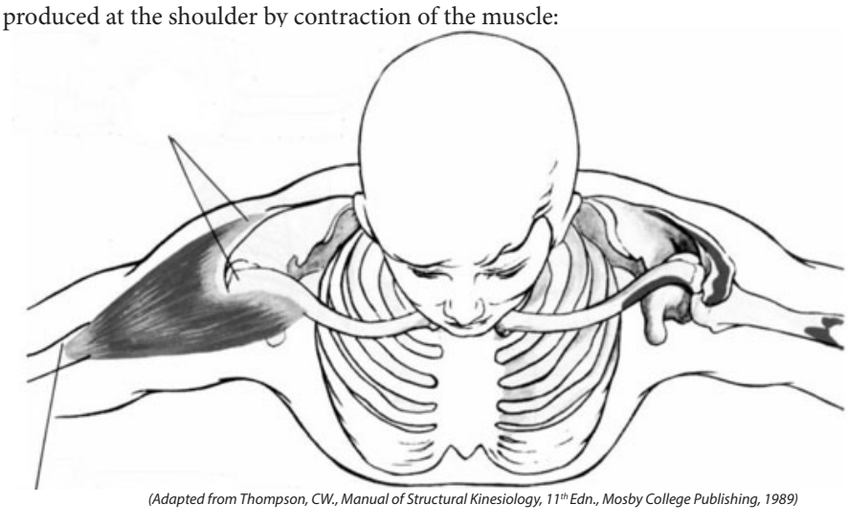

(Adapted from Thompson, CW., Manual of Structural Kinesiology, 11th Edn., Mosby College Publishing, 1989)

_____lies mainly _____to the shoulder joint and so concentric action would lead to _____at the shoulder._____also assists in _____and _____of the arm. Label the proximal and distal attachments of this muscle.

Elbow joint

The joint between the humerus and the bones of the forearm (ulna & radius) is a synovial joint of the **hinge** type. Only flexion and extension occur at this joint.

Task C.6

On the plastinated human elbow joint, locate the joint capsule and ligaments that stabilise the joint.

Question C.7

A) On a standing skeleton examine the elbow joint. How many and which bones are involved?

B) Compare the elbow (and in particular the articulation between the humerus and the ulna) to the equivalent joint in the lower limb (the knee). What difference do you notice in terms of the fit of the bones in these two joints?

Task C.7

On the embalmed human tissue locate the following muscles, noting their position in relation to the shoulder and elbow joints:

- ☐ **Triceps brachii**
- ☐ **Biceps brachii**

Question C.8

Examine the embalmed human tissue. Note the position of triceps brachii and its attachment across the elbow joint. What movement would concentric action of this muscle produce at the elbow?

Question C.9

As triceps brachii does not supinate or pronate the forearm, which bone of the forearm must it be attached to distally?

Radio-ulnar joint

The radius articulates with the ulna proximally and distally. These two radio-ulnar joints are synovial joints of the pivot type which permit special rotational movement of the forearm.

Question C.10

Palpate the head of the radius rotating under your finger as you move your forearm.

A) Which joints are involved in this movement?

B) What are the special names for the rotational movements of the forearm?

Task C.8

State the location of each muscle in relation to the shoulder and elbow joints and, using this information, deduce the concentric action that would be produced at the shoulder and elbow by contraction of the muscle:

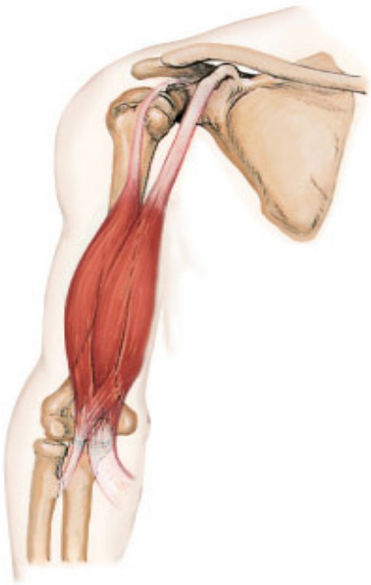

(Fig. 11-21, Patton & Thibodeau, Anatomy and Physiology, 8th Edn., pg.328)

_____lies _____ to the shoulder joint and so concentric action would lead to flexion at the shoulder.

_____lies anterior to the elbow joint and so concentric action would lead to _____ at the elbow.

_____ is attached to the _____ (a bone in the forearm) and can SUPINATE / PRONATE (circle one) the forearm.

(Fig. 11-21, Patton & Thibodeau, Anatomy and Physiology, 8th Ed., pg. 328)

_____lies posterior to the shoulder joint and so concentric action would lead to _____ at the shoulder.

_____lies posterior to the elbow joint and so concentric action would lead to _____ at the elbow.

Lower limb

Fig 2.8 *Lower Limb (Fig. 11-26, Patton & Thibodeau, Anatomy and Physiology, 8th Ed.)*

Hip joint

The joint between the head of the femur and the acetabulum of the hip bone is a synovial joint of the **ball and socket type**. The movements are flexion, extension, abduction, adduction, (therefore circumduction) and rotation. This joint is notable for having some of the strongest ligaments in the body.

Question C.11

Examine the bones involved in the hip joint. Note how well the bones fit together at the hip joint and the shape of the bones. Which bone forms the "ball" and which bone forms the "socket" (which in this case is called the **acetabulum**)?

Question C.12

Examine the thick sheet of ligaments enclosing the hip in the plastinated human joint and model L.31 (on central display tables) .

From your knowledge of the bones and ligaments of the hip joint do you think it is a stable or an unstable joint?

Task C.9

Locate the following muscles/muscle groups on the embalmed human prosections:

- ☐ **Iliopsoas**
- ☐ **Gluteus maximus**
- ☐ **Quadriceps femoris** group and in particular **rectus femoris**
- ☐ **Hamstrings** group

Task C.10

State the location of each of these muscles in relation to the hip joint. Using this information, deduce the concentric action that would be produced at the hip by contraction of the muscle:

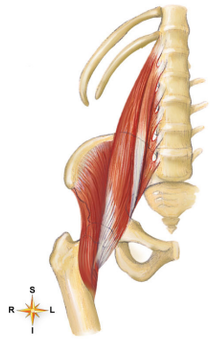

Iliopsoas muscle (Fig. 11-25, Patton & Thibodeau, Anatomy and Physiology, 8th Ed., pg. 333)

Iliopsoas lies _____

to the hip joint and so concentric action would lead to

hip _____.

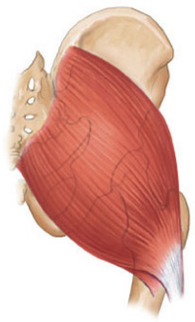

Gluteus maximus (Fig. 11-29, Patton & Thibodeau, Anatomy and Physiology, 8th Ed., pg. 337)

Gluteus maximus lies _____

to the hip joint and so concentric action would lead to

hip _____.

Rectus femoris (Fig. 11-27, Patton & Thibodeau, Anatomy and Physiology, 8th Ed., pg. 335)

Rectus femoris lies _____

to the hip joint and so concentric action would lead to

hip _____.

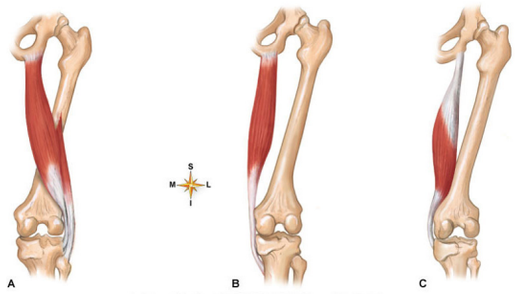

Hamstring group (Fig. 11-31, Patton & Thibodeau, Anatomy and Physiology, 8th Ed., pg. 339)

The **hamstring groups** lies _____

to the hip joint and so concentric action would lead to

hip _____.

Knee joint

The knee joint is the joint between the condyles of the femur and the proximal tibial surface. This is a synovial joint of the **condylar** type. The movements are flexion, extension and some rotation (but only if the knee is semi-flexed).

Task C.11

Examine the bones involved in the knee joint. Note the poor fit of the bones and especially the flatness of the condyles of both the femur and tibia.

Question C.13

Which bone of the leg is NOT involved in the knee joint?

Task C.12

Examine the plastinated human knee joint and model L.109 (on central display tables).

Locate the following:

- ☐ The semicircular menisci, known as "cartilages" because they are made of fibro-cartilage.
- ☐ The collateral ligaments running down each side of the joint.
- ☐ The two cruciate (crossed) ligaments inside the joint.

Question C.14

A) From the location of the collateral ligaments deduce what movements they would allow and which they would restrict?

B) Name one popular New Zealand sport that is likely to cause a ruptured collateral ligament and explain how this may occur.

Question C.15

A) Which ligaments might restrict the femur from sliding anteriorly and posteriorly (forwards and backwards) on the tibia?

B) We have established that ligaments are involved but what other structures stabilise the knee joint when the bones are such a poor fit?

Task C.13

Locate the following muscles/muscle groups on the embalmed human tissue:

- ☐ Triceps surae group and in particular gastrocnemius
- ☐ Quadriceps femoris group
- ☐ Hamstrings group

Task C.14

State the location of each muscle in relation to the knee joint and, using this information, deduce the concentric action that would be produced at the knee by contraction of the muscle:

Gastrocnemius muscle (Fig. 11-32, Patton & Thibodeau, Anatomy and Physiology, 8th Ed., pg. 341)

Gastrocnemius lies _____

to the knee joint and so concentric action would lead to

knee _____.

Quadriceps femoris (Fig. 11-27, Patton & Thibodeau, Anatomy and Physiology, 8th Ed., pg. 335)

Quadriceps femoris lies _____

to the knee joint and so concentric action would lead to

knee _____.

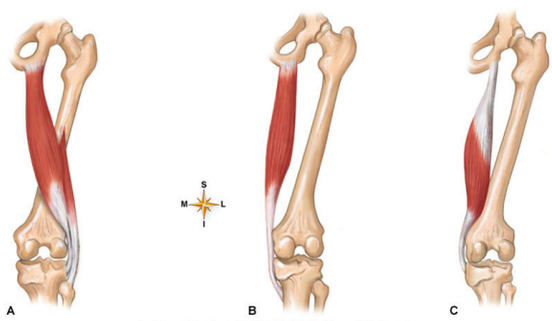

Hamstring group (Fig. 11-31, Patton & Thibodeau, Anatomy and Physiology, 8th Ed., pg. 339)

The **hamstrings group** lies _____

to the knee joint and so concentric action would lead to

knee _____.

Task C.15

Stand upright with your knees extended. Gently move your patella from side to side; it is probably quite mobile. Now unlock the knee by flexing it and do the same. This time the patella is probably less mobile.

Question C.16

Having performed the previous task: do you now think that quadriceps femoris is resting or active when standing in the anatomical position?

Question C.17

Which joint(s) does quadriceps femoris cross?

Ankle joint

The ankle joint is formed by the distal ends of the tibia and fibula, with the talus. It is a synovial joint of the **hinge** type. The movements are dorsiflexion and plantarflexion. (Note that the movements of twisting the sole of the foot (inversion and eversion) are movements between the joints of the other tarsals, not the ankle joint).

Task C.16

Examine the skeletons and plastinated human ankle joints. Notice the bony malleoli formed by the tibia and fibula on either side of the talus.

Question C.18

Which movements are restricted by these malleoli?

Task C.17

Locate the following:

- ☐ The medial collateral ligament (between the distal tibia and talus)
- ☐ The lateral collateral ligament (between the distal fibula and the talus)

Task C.18

Locate and examine the following muscles/muscle group on the embalmed human tissue:

- ☐ **Triceps surae** group
- ☐ **Tibialis anterior**

Task C.19

Stand on tip toes (plantarflex your ankle joint) and then return to the anatomical position. Next, lift your toes off the ground (dorsiflex your ankle joint). Compare the weight being lifted in each case and therefore the force required to make these movements.

Question C.19

A) The concentric action of which of these muscles would result in standing on tip toes?

B) How does the difference in appearance of triceps surae and tibialis anterior relate to the differences in function and force that you have just observed?

Task C.20

State the location of each muscle in relation to the ankle joint and, using this information, deduce the concentric action that would be produced at the ankle by contraction of the muscle:

(Note that the movements of twisting the sole of the foot (inversion and eversion) movements between the joints of the other tarsals, not the ankle joint).

Triceps surae (Fig. 11-29, Patton & Thibodeau, Anatomy and Physiology, 8th Ed., pg. 341)

The **triceps surae** group lies _____

to the ankle joint and so concentric action would lead

to _____at

the ankle joint.

Tibialis anterior (Fig. 11-32, Patton & Thibodeau, Anatomy and Physiology, 8th Ed., pg. 341)

Tibialis anterior lies _____

to the ankle joint and so concentric action would lead

to _____at

the ankle joint.

NOTES PAGE:

Lab 3: Anatomy & Physiology of the Nervous System

In this laboratory you will explore both the physiology and anatomy of the nervous system. There are two parts to this laboratory. In Part I you will examine the gross and microscopic organisation of the peripheral and central nervous system. In Part II you will investigate the neural pathways involved in reflex and voluntary responses.

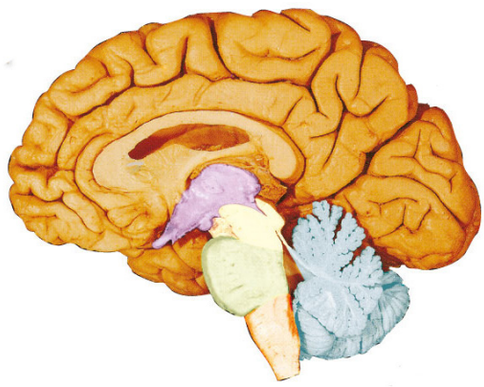

Fig. 3.1 *Divisions of the brain (Fig. 14-19, Patton & Thibodeau, Anatomy & Physiology, 8th Edn., Elsevier, 2013).*

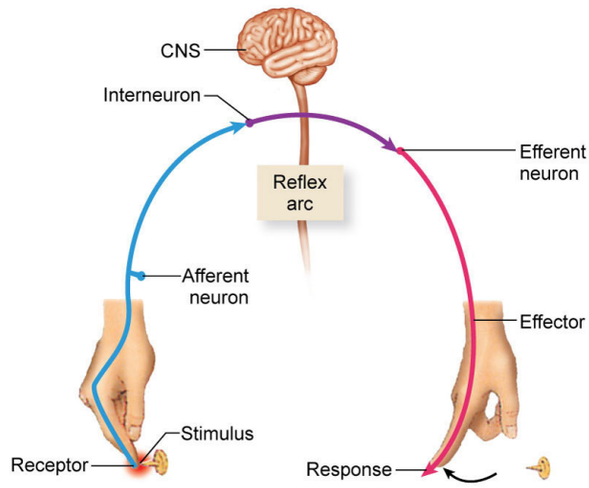

Fig. 3.2 *The reflex arc (Fig. 13-10, Patton & Thibodeau, Anatomy & Physiology, 8th Edn., Elsevier, 2013).*

Pre-lab Preparation

It is essential that you complete these activities prior to coming to the laboratories, as it will ensure that you make the most from your time within the lab.

- Read through this lab.
- Revise lectures 16-20, and 23, and the associated textbook readings and the following textbook pages: Patton and Thibodeau 8th Edn, pages 366, 390-392 and 426-451
- Complete Pre-Lab Task 1

PRE-LAB TASK 1

Define the term 'reflex' movement - (Hint - check your glossary).

Part I: Anatomical Components of the Nervous System

Objectives

By the end of this part of the practical you should be able to:

A. Describe the structure and function of a neuron and then describe the microscopic organisation of neurons within the peripheral nervous system and the central nervous system.

B. List the main divisions of the nervous system and then describe how the central and peripheral nervous systems connect to each other. Identify the superficial features and the major parts of the brain visible externally.

C. Describe and identify the features and the major parts of the brain visible internally. Describe the arrangement of the meninges and the distribution and flow of cerebrospinal fluid.

Objectives A-C relate to the sections with the corresponding letter.

A. Neuronal Structure and Microscopic Organisation of the Nervous System

Histology of Nerve Tissue - Peripheral Nerve

Peripheral nerves are made up of nerve axons (both **myelinated** and **unmyelinated**) arranged in bundles known as **fasciculi** (singular = **fascicle**) surrounded by connective tissue layers known as the **epineurium**, **perineurium,** and **endoneurium**.

We will be examining peripheral nerve tissue taken from an animal. This tissue is similar to that of a human.

Task A.1

Use the model NSC3.H3 or laminated sheet/PDF in the Lab 3 folder 'Neuron' to locate the:

- ☐ **Axon**
- ☐ **Dendrites**
- ☐ **Terminals of presynaptic neurons**
- ☐ **Myelin sheath and Schwann cell**

Task A.2

Locate the transverse section of a peripheral nerve (radial nerve). View the slide with the naked eye and then place it carefully on the microscope stage. Using the low power (x4) objective locate the tissue and then adjust the focus.

Task A.3

Change to the x10 objective and re-focus slowly using the fine focus knob. Identify each of the **connective tissue** layers listed.

- ☐ **Epineurium**
- ☐ **Perineurium**
- ☐ **Endoneurium**

Task A.4

Change to the x40 objective. Note the numerous, variably sized axons within each strongly pink stained ring of perineurium.

Task A.5

Draw an image of what you can see in the transverse section of the peripheral nerve, when you use the x10 objective. **Label the following structures:**

axon, endoneurium, fascicle, perineurium, and epineurium

Question A.1

You may have seen darkly-stained flattened nuclei in cells that seem to wrap around the axons, what cells do you think these nuclei might be from?

Histology of Nerve Tissue - Spinal Cord

Recall that nervous tissue in the CNS is made up of **grey matter**, containing mainly neuron cell bodies, and **white matter**, containing mainly myelinated axons.

You will examine the basic structure of nerve cell bodies using cells within the grey matter of the spinal cord. Again you will be examining animal tissue.

Task A.6

Locate the transverse section of a spinal cord. View the slide with the naked eye and identify the following structures. It may be helpful to use the laminated sheet/PDF in the Lab 3 folder "Reflex Arc".

- ☐ **grey matter**
- ☐ **white matter**
- ☐ **central canal**
- ☐ **anterior (ventral) horn**
- ☐ **posterior (dorsal) horn**

Identify these structures on model NSP.77 or laminated sheet/PDF in the Lab 3 folder 'Spinal Cord'.

Task A.7

Next place the slide carefully on the microscope stage. Start at the low power (x4 objective) and locate those structures that you saw with the naked eye. Draw an image of what you saw in the transverse section of the spinal cord, **and label the following structures**:

grey matter, white matter, anterior fissure, posterior sulcus, anterior horn, posterior horn, and indicate the regions where **sensory** (afferent) and **motor** (efferent) neurons are located.

Question A.2

What are the anterior and posterior horns made up of?

Question A.3

You may see that there are numerous processes coming off the cell bodies. Are these processes likely to be axons or dendrites?

Task A.8

Locate the anterior horn of the grey matter and increase the magnification to x10 to identify the **motor neurons** by their large cell body (**soma**).

Shrinkage during preparation of the material has caused spaces around the cells. The neurons have a roughly spherical **nucleus** and purple-stained **cytoplasm**.

B. Divisions of the Nervous System

Using your knowledge from lectures and the textbook, answer the following questions (you may need to revise your answers at the end of the laboratory).

Question B.1

What are the two structural divisions of the nervous system?

Question B.2

What two gross structures comprise the Central Nervous System (CNS)?

Question B.3

What gross structures comprise the Peripheral Nervous System (PNS)?

Task B.1

Examine model NSC3.82, a dissection of the brainstem, spinal cord, and spinal nerves, viewed from the anterior aspect. Note the continuation of the dura from the brainstem around the spinal cord.

Question B.4

Identify the cauda equina on the model. What is the cauda equina composed of?

Task B.2

Identify the dorsal and ventral roots of the spinal nerves on model NSC3.82, and the laminated sheet / PDF in the Lab 3 folder 'Spinal Cord.'

Question B.5

Identify the sympathetic trunk on model NSC3.82. What comprises this structure?

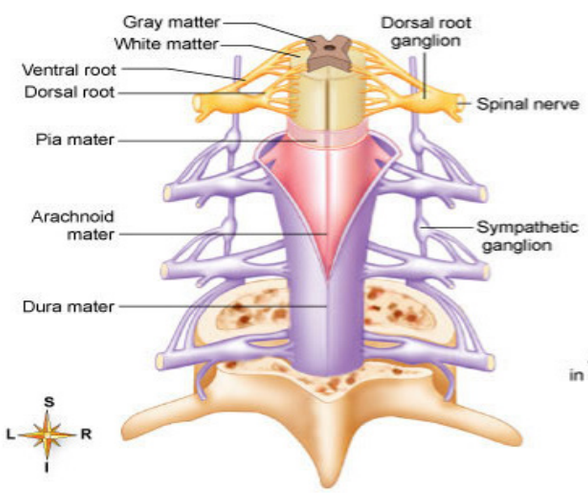

Fig. 3.3 *Coverings of the spinal cord. The dura mater is the outermost layer. Note how it extends to cover the spinal nerve roots and nerves. (From Patton and Thibodeau, Anatomy and Physiology, 8th Edn., Elsevier, 2013).*

C. Gross Anatomy of the Brain

Sectioned Brain

Task C.1

Identify the grey matter of the cerebral cortex on the horizontally sectioned model (NSC3.102) paying particular attention to planes 1 and 2.

Question C.1

What is **grey** matter composed of?

Question C.2

What is **white** matter composed of?

Question C.3

Identify the corpus callosum on planes 3 and 4 of model NSC3.102 or the plastinated brains. What is its general function?

Question C.4

What are the functions of the thalamus and basal ganglia?

Task C.2

Collections of cell bodies with a related function are called nuclei. Identify nuclei on planes 3-6 (model NSC3.102) and some of the plastinated brains:

- ☐ **Thalamus**
- ☐ **Basal ganglia (or basal nuclei)**

The Brain: External Features

Task C.3

Use model NSC3.103, laminated sheet/PDF 'Left Hemisphere' and the plastinated brains to identify the following features:

- ☐ **Sulci**
- ☐ **Gyri**
- ☐ **Central sulcus**
- ☐ **Lateral sulcus**
- ☐ **Frontal lobe**
- ☐ **Occipital lobe**
- ☐ **Temporal lobe**
- ☐ **Parietal lobe**
- ☐ **Cerebral Hemisphere**
- ☐ **Cerebellum**
- ☐ **Brainstem**

Now label each of the features above on the figure below.

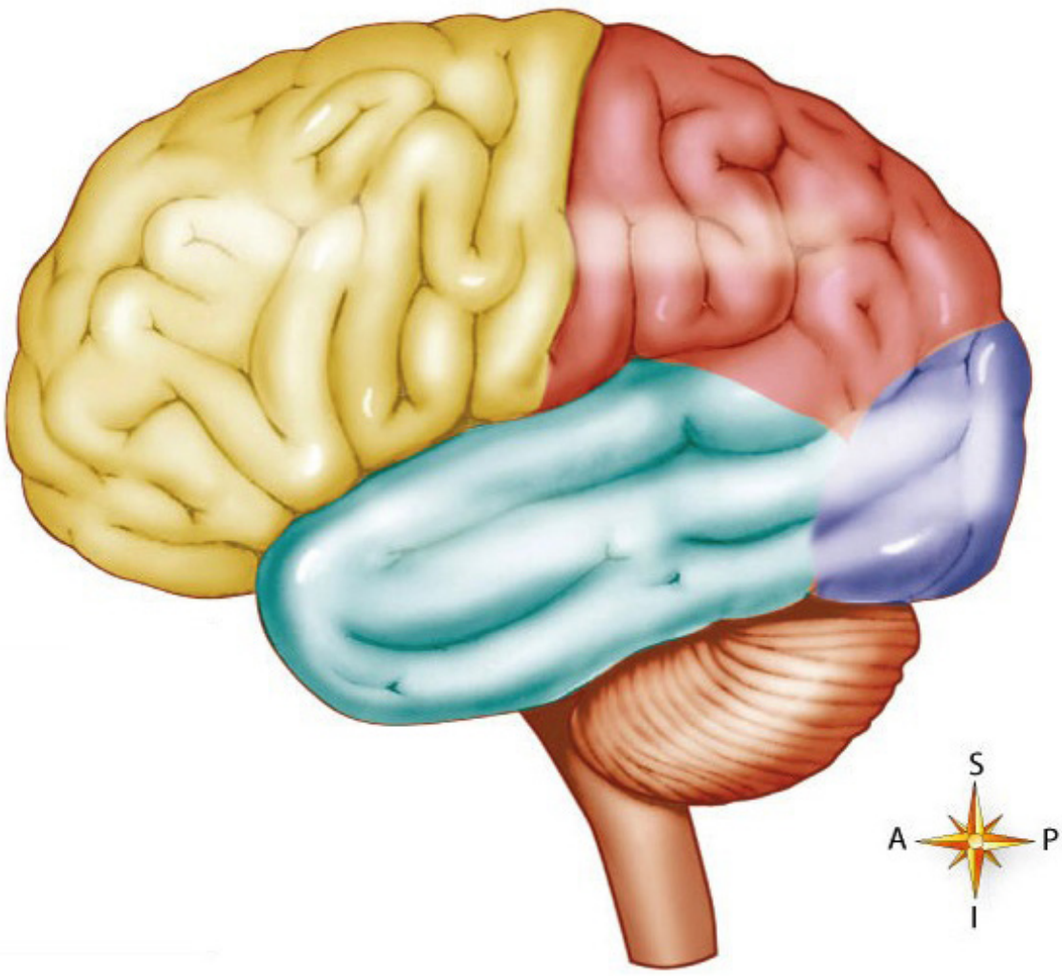

Fig. 3.4 *Left lateral view of the brain. (Fig. 14-16, Patton & Thibodeau, Anatomy & Physiology 8th Edn., Elsevier, 2013)*

The Brain: Internal Features

Brainstem

The brainstem is the lower extension of the brain, which connects the cerebrum to the spinal cord. The brain stem performs sensory, motor, and reflex functions and is divided into three parts: the **medulla**, the **pons,** and the **midbrain**.

Task C.4

Use models NSC3.103, NSC2.14, and the plastinated brains to identify:

- ☐ **Brainstem**
- ☐ **Medulla oblongata**
- ☐ **Pons**
- ☐ **Midbrain**

Task C.5

Label the following structures on the diagram below:

- ☐ cerebellum
- ☐ midbrain
- ☐ pons
- ☐ medulla oblongata
- ☐ cerebrum
- ☐ choroid plexus (in third ventricle)
- ☐ thalamus
- ☐ hypothalamus
- ☐ fourth ventricle

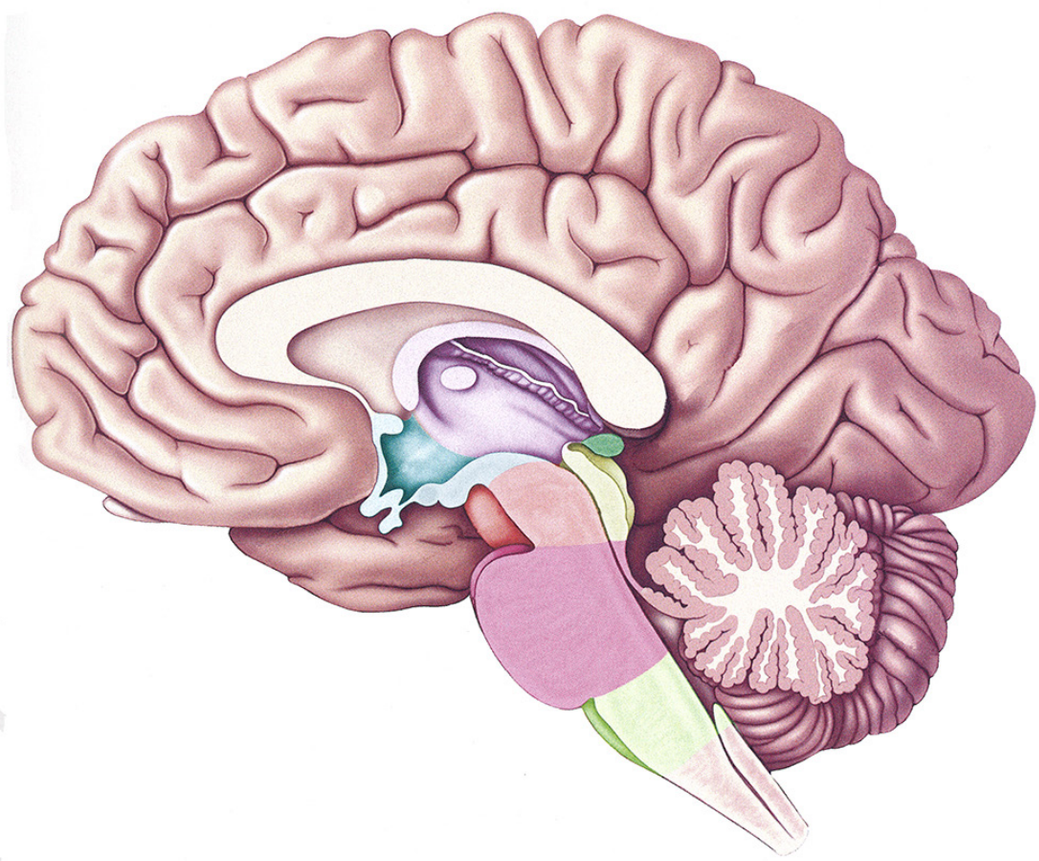

Fig. 3.5 *Medial view of the brain [median sagittal section]. (From Bear et al., Neuroscience, 3rd Edn., Lippincott, Williams & Wilkins, 2007).*

Meninges and Ventricles

The CNS is largely enclosed within bone. It is also protected by three membranes, the **meninges**, which lie deep to this bony covering. From outer to inner the meninges are the **dura mater, arachnoid mater,** and **pia mater**.

Dura Mater

The dura mater is the outermost meningeal layer. It is tough, white, and fibrous.

Task C.6

Identify the dura mater on model NSC3.74 and on some of the plastinated brains.

Arachnoid Mater

The arachnoid mater is the intermediate meningeal layer. It is a thin, semi-transparent connective tissue (resembling a spider's web) that is more intimately associated with the brain than is the dura mater. The arachnoid mater bridges over the **sulci** and **gyri** on the surface of the brain.

Task C.7

Identify the arachnoid mater on the plastinated brains.

Pia Mater

The pia mater is the innermost of the **meningeal membranes**. It is a fine membrane that closely follows the gyri and sulci of the brain.

Task C.8

Identify the pia mater on the plastinated brains.

Subarachnoid Space

Between the arachnoid and the more deeply situated pia mater is the **subarachnoid space**, which contains the **cerebrospinal fluid** (CSF).

Task C.9

Identify the subarachnoid space. Use the laminated sheet/PDF in the Lab 3 folder 'Ventricles' as a guide.

Cerebrospinal Fluid

Cerebrospinal fluid is produced (by the choroid plexus) in the ventricles and flows through the ventricles into the subarachnoid space to circulate around the brain and spinal cord.

It is then absorbed into venous blood through the arachnoid villi into the venous sinuses.

Task C.10

Use model NSC3.137 and the plastinated brains to identify:

- ☐ **Lateral ventricles**
- ☐ **Third ventricle**
- ☐ **Fourth ventricle**
- ☐ **Choroid plexus**

Part II: Physiological Processes of the Nervous System

Objectives

By the end of this part of the practical you should be able to:

A. Outline the basic physiological processes underlying reflex motor responses in general, and the muscle stretch reflex in particular.

B. Outline the basic physiological processes underlying voluntary motor responses.

C. Compare the latency of a muscle stretch reflex to the latency of a voluntary movement.

D. Link the physiological processes investigated in this part of the laboratory to the anatomical structures examined in Part 1 (Section A, B, and C).

Experiment 1: The Muscle Stretch Reflex

Background Theory

Muscles have stretch sensors called **muscle spindles.** These are receptors that are activated (depolarised) by an increase in muscle length (*i.e.* stretch).

Muscle spindles send information about stretch by initiating action potentials. These action potentials are conducted *via* **sensory neuron axons** in peripheral nerves through the **dorsal root** to the spinal cord. The sensory neuron axons are **myelinated** (see Section A).

The **axons** of these sensory neurons branch to send information to several other neurons, including:

- **interneurons**, which project up the spinal cord to higher centres, for conscious sensation and voluntary movement planning.
- **motor neurons** in the ventral spinal cord (see **Fig. 3.8** and **Fig. 3.9.**)

Information is passed to the interneurons and motor neurons *via* a **synapse** (see Section A).

The motor neuron axon projects to skeletal muscle *via* the ventral root and peripheral nerve. The motor neuron axons are myelinated (see Section A).

The specialised synapse between the motor neuron axon and the skeletal muscle is known as the **neuromuscular junction** (NMJ).

Stretching the skeletal muscle activates the sensory axon endings in the muscle spindles, generating action potentials in the sensory axon. This leads to activation of the motor neuron, which in turn activates the skeletal muscle.

Activation and subsequent contraction of the skeletal muscle shortens it. This restores the **pre-stretch** length. This is an example of a **negative feedback control loop.**

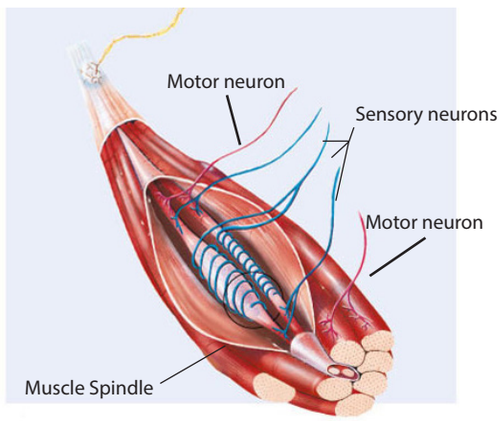

Fig. 3.6 *Muscle Spindle (Adapted from Fig. 17-5B, Patton & Thibodeau, Anatomy & Physiology, 8th Edn. 2013)*

One function of the stretch reflex is to automatically hold a muscle at a desired (set-point) length, in the face of external forces.

The stretch reflex is important clinically because it is affected in specific ways in various **neurological conditions.** For example, stretch reflexes are generally weaker in demyelinating diseases.

Experiment Aim

To measure the latency from stretch of the muscle to electrical activation of the muscle (Objective C).

Note - we will use the ankle-jerk reflex rather than the knee-jerk reflex, as the muscle (soleus) is easier to access.

Open the LabTutor experiment "**Reflexes versus Reaction Time**". Follow the instructions on the screen to record electrical activity of the soleus muscle as illustrated in **Fig. 3.7**.

Work in your group and collect data from ONE or TWO students for analysis.

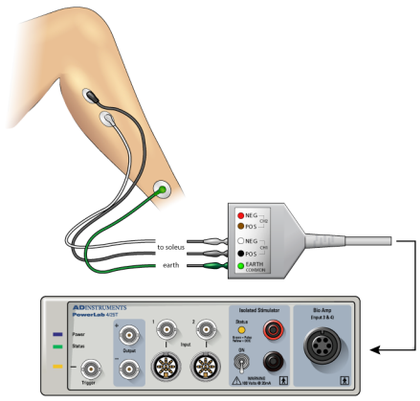

Fig. 3.7 *Recording set up for both Experiment 1 and Experiment 2. (AD Instruments, 2010).*

Question D.1

Describe the direct effect of the tap on the Achilles tendon on the soleus muscle.

Question D.2

Describe the direction of the foot movement that occurs as a result of the tendon tap. What must the soleus muscle have done to cause this movement?

Task D.1

Sketch a copy of your EMG data from the stretch reflex onto the blank data panel below. Add in a time scale on the x-axis.

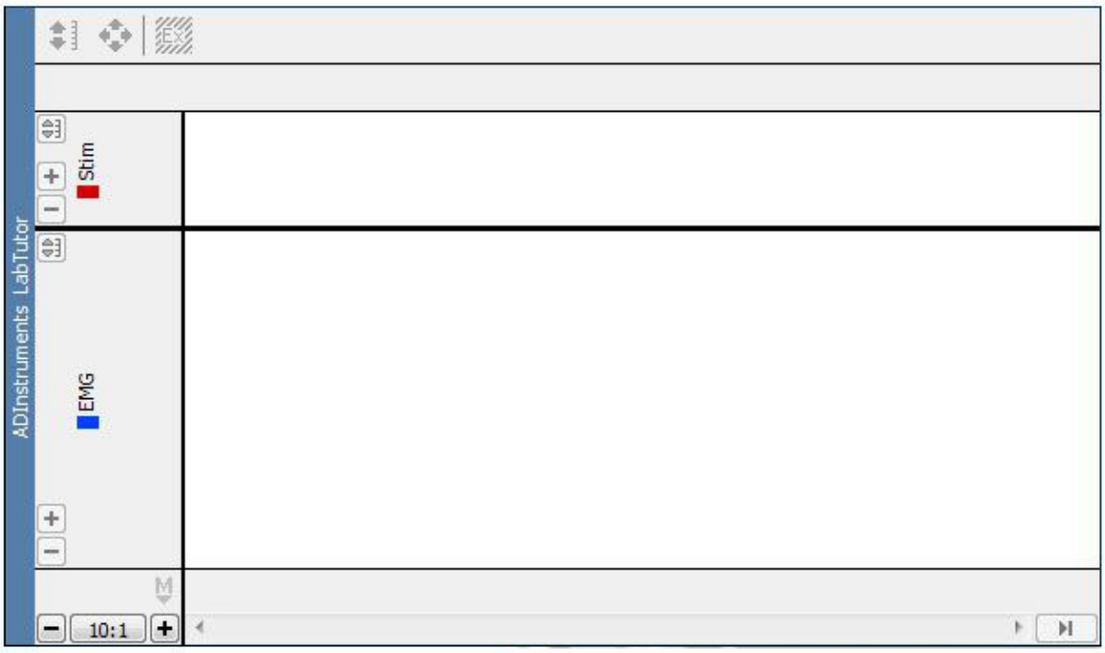

Task D.2

Match the locations numbered 1-7 in the figure below to the physiological processes in the following list:

- Synaptic transmission. **number(s).....**
- Action potential conduction. **number(s).....**
- Contraction. **number(s).....**
- Local/graded potentials leading to action potential initiation. **number(s).....**

Draw arrows to indicate the direction of the 'flow of information' around the reflex.

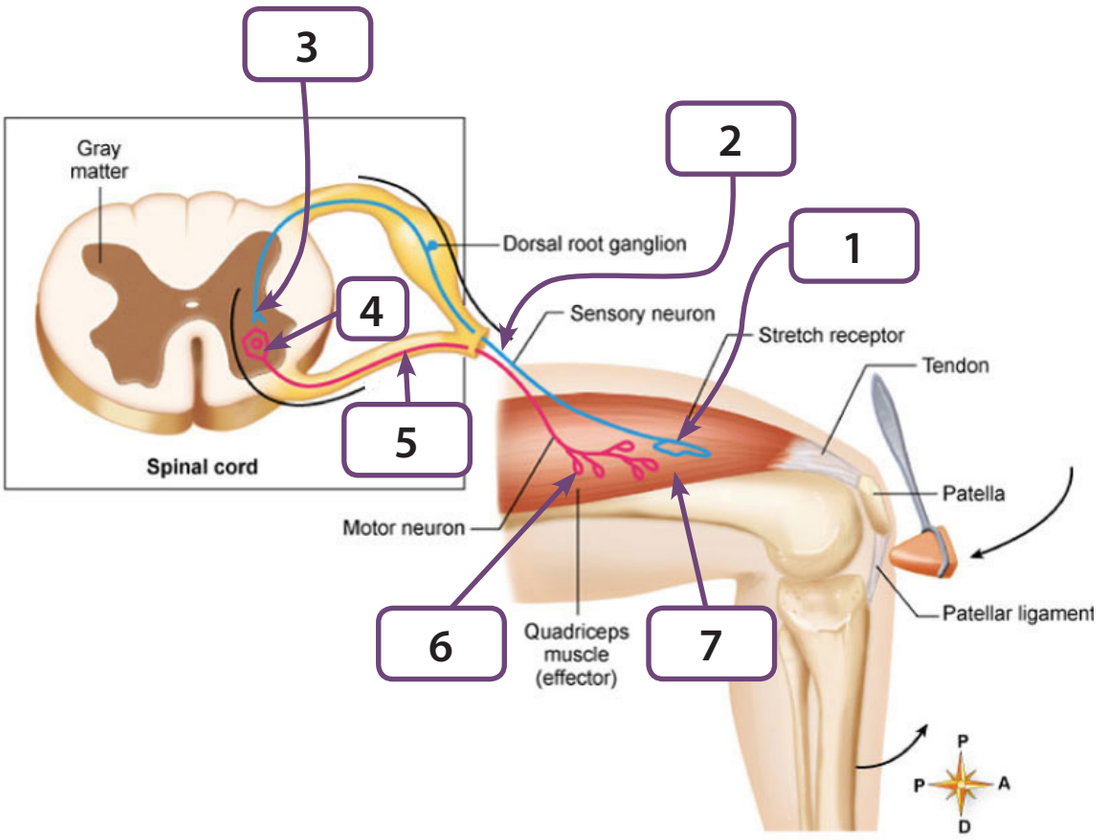

Fig. 3.8 *The muscle stretch reflex circuit (Adapted from Fig. 15.15, Patton & Thibodeau, Anatomy & Physiology, 8th Edn., Elsevier, 2013).*

Experiment 2: Voluntary Movement in Response to Sensory Stimulus

Background Theory

Voluntary movements involve activation of neurons in the motor cortex. The **motor cortex** is anterior to the **central sulcus** of the **cerebral hemisphere** (Section B in part 1).

Activation of the primary motor cortex is assisted by input from the **cerebellum** and the **basal ganglia**.

The cerebellum helps coordinate movements. It does this by using information about current body position to compute movements needed to achieve a new body position (feedforward control) and to check planned movements against actual movements to compute corrections (feedback control) (Section B in Part 1).

The basal ganglia help to select and activate cerebral cortex neurons to achieve **initiation** of movement (Section C in Part 1).

The axons of primary motor cortex neurons project to the spinal cord. One major pathway is the **corticospinal** (or **pyramidal**) tract. The corticospinal tract axons influence the activity of spinal cord motor neurons.

Mostly, this is indirectly, *via* synapses onto interneurons, which in turn synapse on the motor neurons. In some cases, this is direct *via* synapses directly on motor neurons.

Primary motor cortex activation may occur as a result of:

Internally generated movement plans; *e.g.* you may decide to wiggle your foot for no particular reason. Internally generated movements arise from activity in many brain regions including **pre-frontal** and **medial premotor** cerebral cortical areas.

Externally cued movements, made in response to specific external cues; *e.g.* you may be instructed, as part of an experiment, to wiggle your foot when you feel a touch. Externally cued movements are triggered by sensory information arriving from the **sensory pathways**, *via* processing in the **lateral premotor** cerebral cortical area.

Experiment Aim

To measure the latency from sensory stimulus to electrical activation of the muscle, in a voluntary reaction time task (Objective C).

Procedure

Continue with the **LabTutor "Reflexes versus Reaction Time"** experiment on the computer, and follow the instructions on the screen.

Individual Results

Latencies

Trial Number	Reflex Latency (ms)	Voluntary Movement Latency (ms)
1		
2		
3		
4		
5		

Pathway Length

	Reflex (mm)	Voluntary Movement (mm)
Pathway Length		

Task D.3

Class Data - Plot at least 10 points on the graph below for both reflex and voluntary movement

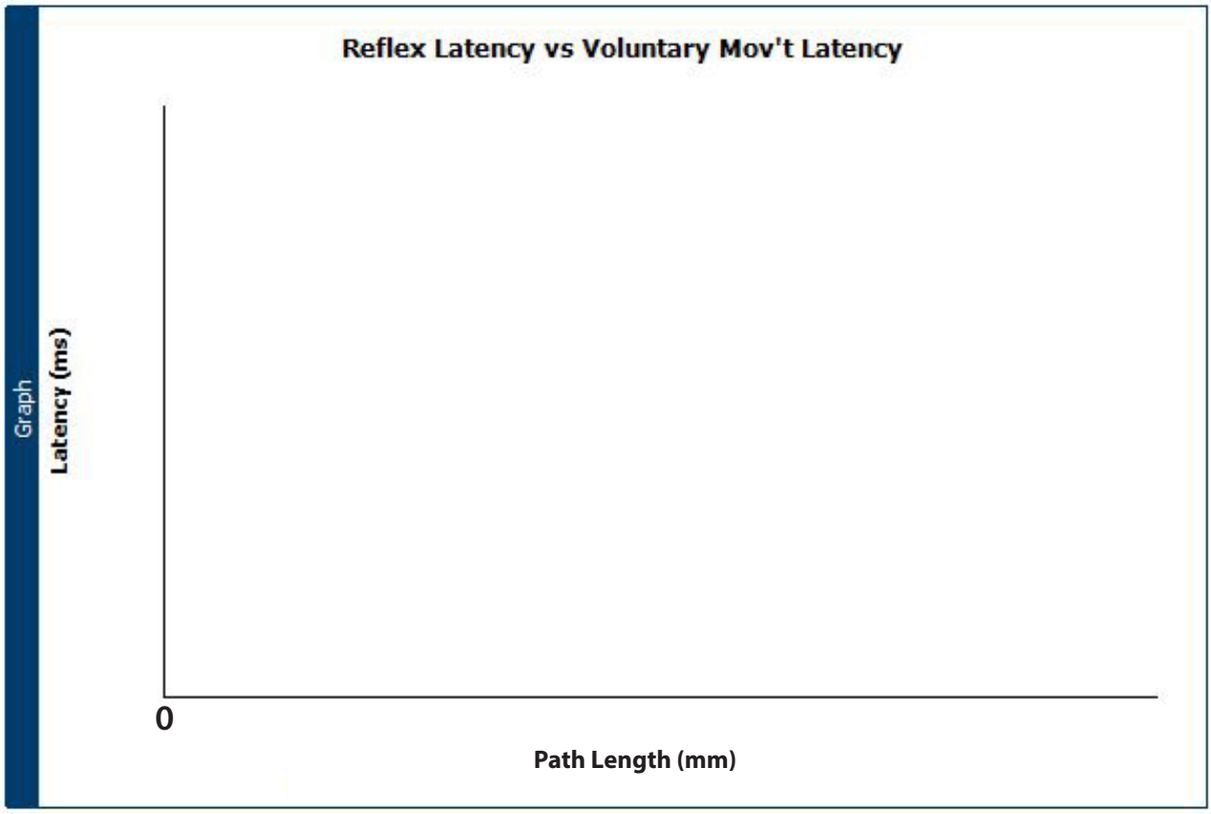

Question D.3

Compare **Fig. 3.8** and **Fig. 3.9** (Task D.2 and D.4)

A) Which figure shows the involuntary reflex pathway?

B) Which figure shows the voluntary response pathway?

C) List the differences and similarities between these two pathways (*i.e.* structures, number of synapses, length).

Question D.4

Outline two reasons for any difference in latency between reflex and voluntary responses. Include in your answer a list of the physiological processes that have to occur for each, and the pathways over which information has to travel (Part II Objectives A-D).

Task D.4

Match the locations numbered 1-8 in the figure below to the physiological processes in the following list:

- Assists the motor cortex to initiate response. **number(s).....**
- Activates muscle. **number(s).....**
- Conducts action potentials. **number(s).....**
- Assists the motor cortex to coordinate movements. **number(s).....**
- Transduces the sensory stimulus. **number(s).....**
- Generates motor commands. **number(s).....**
- The conscious identification and localisation of a sensory stimulus. **number(s).....**

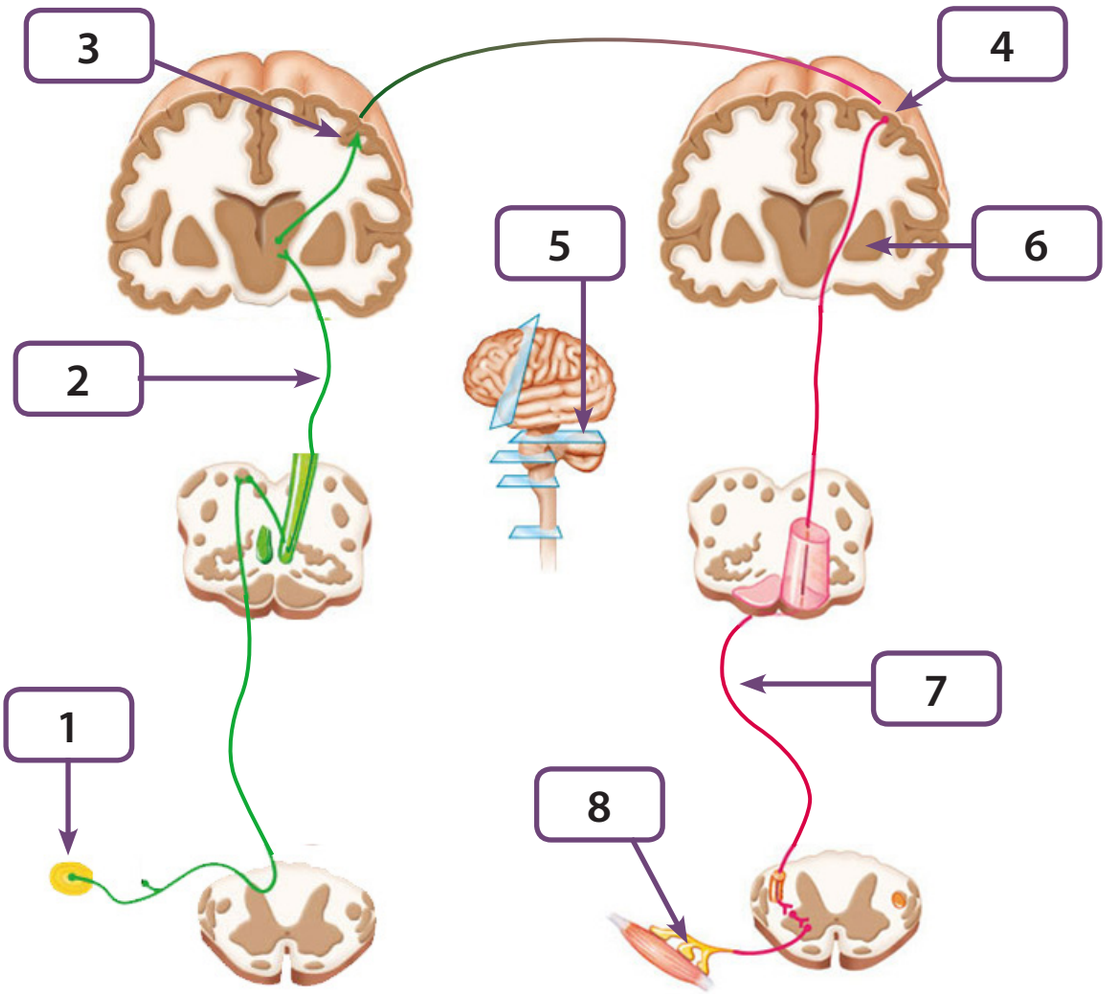

Fig. 3.9 *Pathways involved in voluntary responses to sensory stimulus (Adapted from Fig 14.23 and Fig. 14.24, Patton and Thibodeau, Anatomy and Physiology, 8th Edn., Elsevier, 2013).*

Question D.5

A) The range of reaction time (voluntary) values obtained gives an indication of the variability of your data. Using your own data, compare the range of latencies obtained for the reflex and voluntary responses. Which has the bigger range?

B) What is the most likely explanation for any differences in the variability of reflex compared to voluntary movements, within an individual? (Part II Objectives B & C)?

Question D.6

Looking at the group data (and your graph from Task 3), how big is the range for mean reflex latencies across individuals? What could give rise to this inter-individual variability? (Part II Objective B) .

Question D.7

Relating reaction time (voluntary) variation to real life:

A conundrum: In an Olympic 100 m final, runner A runs more quickly than the winner, but still comes in second. How could that be?

Question D.8

Use of a cell phone while driving is banned in New Zealand. Explain, in terms of possible changes in reaction time, why it is banned.

You have now finished the lab activities.

Please be sure to tidy up your area. Remember, if you have any questions don't hesitate to ask a demonstrator. If you are waiting for the wrap-up, there is additional material in the Lab 3 folder on your desktop.

NOTES PAGE:

Lab 4: Sensory and Motor Physiology

In this laboratory you will examine the physiology of the nervous system. In Part I you will investigate the coding of sensory information and the properties of sensory receptors for touch and temperature. In Part II you will investigate the properties of peripheral nerves and skeletal muscle.

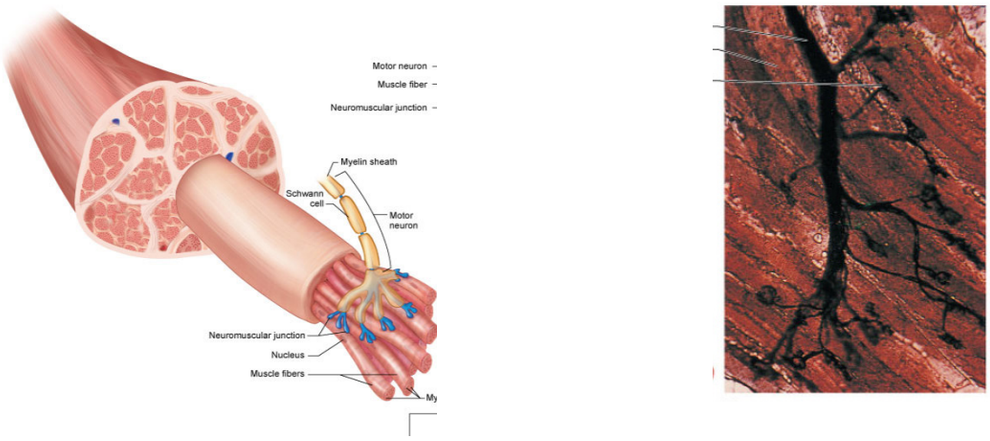

Fig. 4.1 *Diagrammatic and photomicrographic motor units (Adapted from Fig. 12-18, Patton and Thibodeau, Anatomy & Physiology, 8th Edn., Elsevier, 2013)*

Pre-lab Preparation

It is essential that you complete these activities prior to coming to the laboratories, as it will ensure that you make the most from your time within the lab.

- Read Patton and Thibodeau textbook, 8th Edn. pages 360-367, 387-399, & 506 – 508.
- Read Part A and Part B.
- Revise lectures 16 - 19, 22 – 25, and 28 - 30.
- Read heat loss mechanism notes from Lecture 3 on Blackboard.
- Complete Pre-Lab Tasks 1 & 2.

Aim

To investigate the physiology of peripheral nerves, skeletal muscle, and sensory receptors.

Objectives

By the end of this lab you should be able to:

A. Explain the coding of sensory information as it relates to the properties of cutaneous receptors for touch and temperature.

B. Describe coding of intensity of sensory stimuli by both recruitment of sensory axons and action potential frequency. Explain coding of stimulus location.

C. Describe the effect of motor unit recruitment and mechanical summation of twitches on the force of skeletal muscle contraction.

D. Estimate the conduction velocity of a peripheral nerve.

PRE-LAB TASK 1

Identify the structure at each site on the figure below by filling in the blanks with the following labels:

posterior horn, sensory neuron cell body, motor neuron cell body, motor neuron, sensory neuron, anterior horn, axon, peripheral nerve.

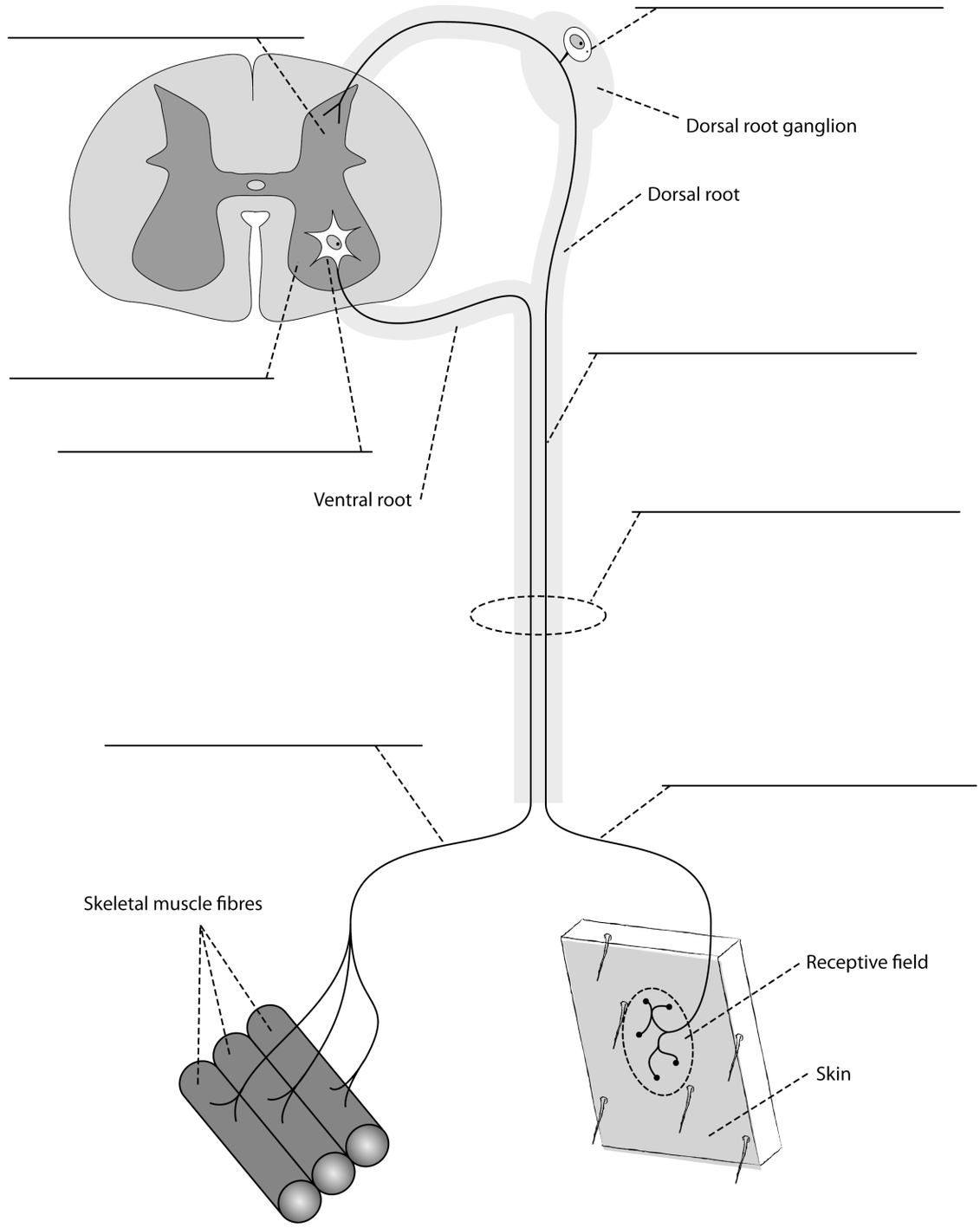

Fig. 4.2 *Schematic diagram of a sensory unit and a motor unit (Physiology Teaching Resources, University of Otago, 2010).*

PRE-LAB TASK 2

Identify the structure at each site on the figure below by filling in the blanks with the following labels:

- Whole nerve
- Myelin sheath
- Axon (2x)
- Fascicle.

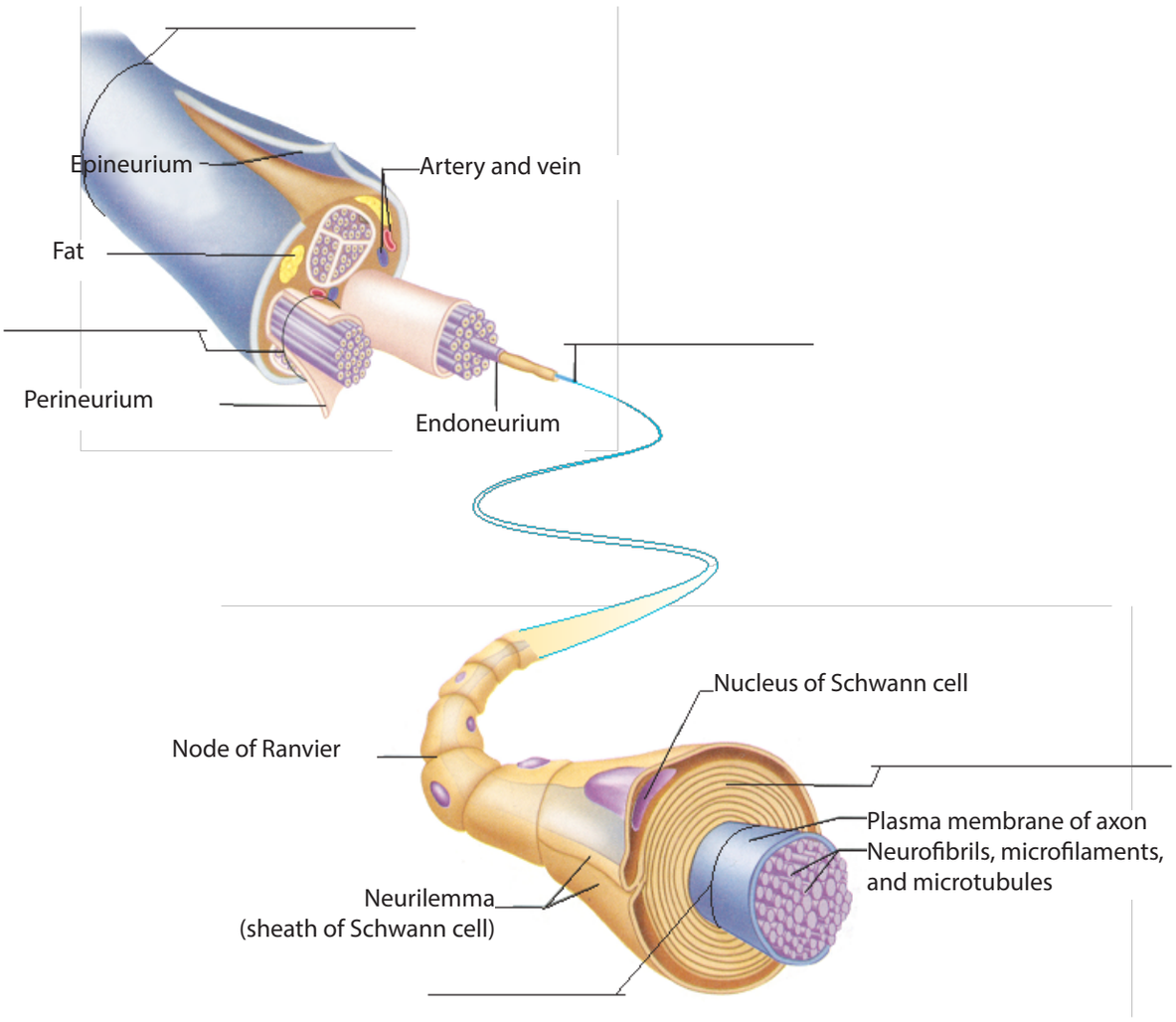

Fig. 4.3 *Schematic diagram of a peripheral nerve with a magnified myelinated axon. (Adapted from Fig. 13.6 and Fig. 13.12 Patton & Thibodeau, Anatomy and Physiology, 8th Edn., Elsevier, 2013).*

Physiology of the Nervous System

Physiology is the study of the function of the body, that is, how the body's cells, tissues, organs, and systems work. Today's lab will explore the physiology of the nervous system.

Two crucial aspects allow the nervous system to function properly; first, the cells of the nervous system (**neurons**) send extensive projections throughout the body, and second, these cells rapidly convey signals between different parts of the body. This is only possible because neurons are excitable.

Excitable tissues such as neurons and muscles have a resting voltage across their membranes, the **resting membrane potential**. These cells respond to stimuli with changes in membrane potential. Thus, excitable cells can be thought of like miniature batteries.

When these cells are excited, the membrane potential may reach threshold, at which point a transient, abrupt change in membrane potential is initiated. This is known as the **action potential**.

The action potential generated in a neuron propagates by regenerating itself along the axonal membrane (much like a trail of gunpowder ignited) until the action potential reaches a **synapse**. The neuron may then release a **neurotransmitter** that diffuses across the synapse to influence the membrane potential of the post-synaptic tissue, for example causing a muscle cell to 'fire'.

Information in the nervous system is coded in 3 ways:

1. Within a single axon or motor unit, by the frequency of action potentials.
2. By the number of axons or motor units active (recruitment).
3. By the selection of particular axons or motor units to be active along a specific pathway (modality).

(1) and (2) together code intensity, and (3) codes location and modality. We can explore these physiological principles through electrical stimulation.

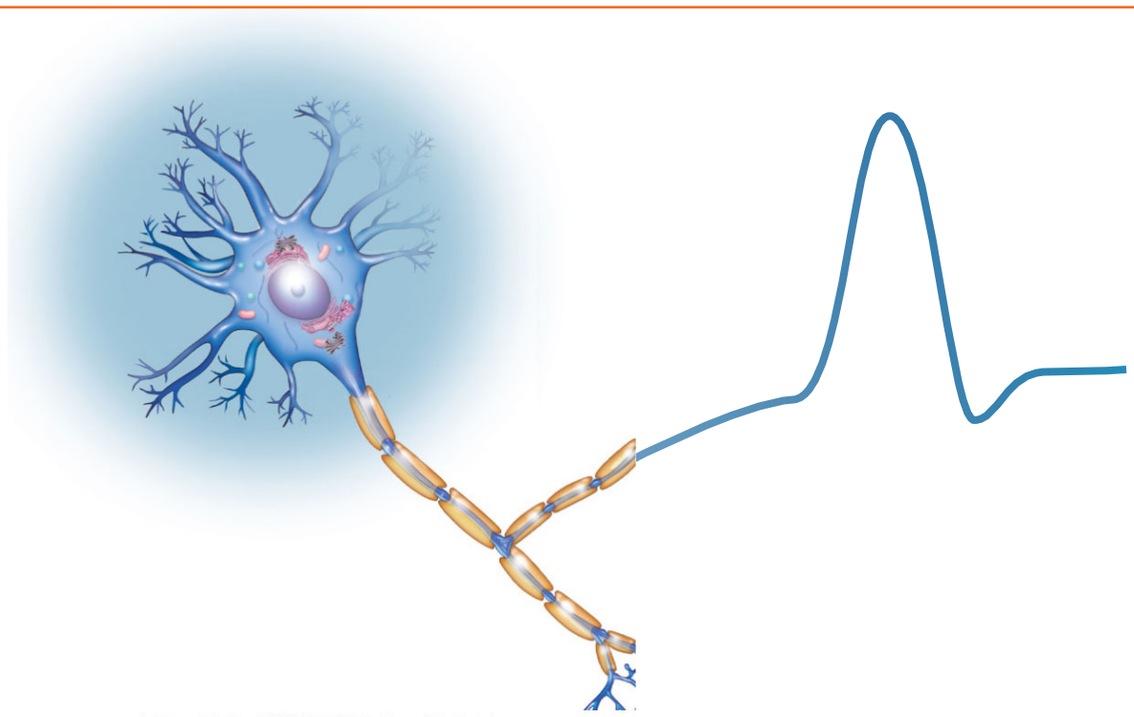

Fig. 4.4 *Schematic of a typical neuron along with a* ***stylised*** *action potential (Adapted from Fig. 12C-1, Patton & Thibodeau, Anatomy and Physiology, 8th Edn., Elsevier, 2013).*

Part A: Coding of Sensory Information & Properties of Sensory Receptors

Sensory neurons (or units) consist of a cell body (in the dorsal root ganglion) and an axon with two branches, peripheral and central (**Fig. 4.2**). The central branch terminates on synapses of neurons in the central nervous system. The peripheral branch terminates in the skin as **sensory receptors**. These can be unspecialised, or can be associated with specific structures. Action potentials are initiated at the sensory ending in response to a stimulus and propagate along the axon to the central synapses.

The receptor endings of one **sensory unit** are all the same, and are sensitive to one type (**modality**) of sensation. Thus, some neurons are **touch** sensitive, while others are **temperature** sensitive, *etc.*

There are a variety of endings for touch, *e.g.* Merkels discs and Pacinian corpuscles. Different types are sensitive to light touch or deep pressure. Temperature receptors are all bare (unspecialised) endings. Although the endings all look the same, sensory neurons for temperature fall into two groups, **warm** sensitive and **cold** sensitive. Skin sensory neurons sample from a discrete region of skin, known as the **receptive field** of that neuron.

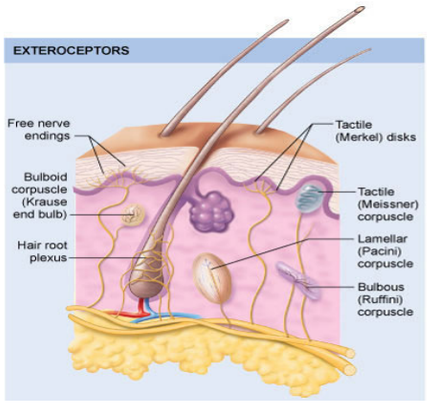

Fig. 4.5 *Somatic sensory receptors of the skin (Fig. 17.5 Patton & Thibodeau, Anatomy and Physiology, 8th Edn., Elsevier, 2013). Note you do not need to know all receptor types. Only those mentioned during the lab.*

Experiment 1: Determination of Stimulus Location

Experiment Aim

To determine relative light touch receptive field size and/or density for different areas of the body using **two-point discrimination** tests.

Background Theory

The **receptive field** of a sensory axon in a peripheral nerve is the area of the body that, if stimulated, results in the firing of that axon. Receptive fields can be characterised by size and also by density.

The **size** of receptive fields affects how accurately the **location** of a stimulus can be determined. A small receptive field allows for good localisation of a stimulus compared to larger receptive fields that provide less specific information about a stimulus location.

The **density** of receptive fields determines how accurately **two distinct stimuli can be discriminated**. Two stimuli can be more easily detected in areas of the body where receptive fields are more densely packed. This is because two stimuli close together on the skin will touch different receptive fields and therefore will be felt as two points. Any time two stimuli touch only one receptive field they will be felt as one, not two, points.

Size and density of receptive fields vary according to body location. This affects the ability to accurately locate and discriminate the position, shape, and texture of objects touching the skin. For example fine details and small objects can be detected most easily by the lips and fingertips as they have small and densely packed receptive fields. It is possible to determine how dense receptive fields are by doing two-point discrimination tests.

Procedure

Do this in your group and collect data from everyone.

1. Ask the subject to close their eyes.
2. Instruct the subject as follows: Tell them what you are going to do and ask them to report "one" or "two", depending on how many discrete points they feel.

3. First test the fingertip of an index finger, as follows:

A. Ensure that the two points touch simultaneously with equal pressure. Press lightly. Do not puncture the skin.

B. Briefly touch the tips of the dividers to the skin, with a side-on approach. Begin with the tips about 1 cm apart, then gradually decrease the distance until the subject reports "one" touch. Orient the divider on your fingertip such that the points form an imaginary **lengthwise** line (proximal to distal) instead of from side to side.

C. Occasionally touch with just one point, to ensure the subject is really detecting the difference. Measure the smallest tip separation at which two points were reliably detected and enter into the table that follows.

4. Repeat step 3 for the palm and the forearm beginning with the divider points 8-9 cm apart. Remember to keep the orientation of the points lengthwise (proximal to distal) similar to the path the long bones lie in.

Results

Minimum distance two points could be discriminated

	Subject 1	Subject 2	Subject 3	Group Mean
Finger tip				
Palm				
Forearm				

Question A.1

Discuss the functional implication of the differences in touch receptive field size and density that you observed in the tested regions *e.g.* how do you use each of the areas of skin that you have tested?

Experiment 2: Stimulus Intensity and Duration

Background Theory

Our sensors often do not accurately detect the **absolute** intensity of a stimulus, however, they do detect the **relative** intensity. For example: do your sensory receptors tell you the absolute temperature of the lab room today?

In a similar manner, the duration of a sensory stimulus is often not accurately reported by sensory receptors. Skin touch receptors show **adaptation**, *i.e.* they gradually reduce their response to a constant stimulus. Skin temperature sensors detect change in temperature, and then show adaptation.

The apparent temperature of an object also relates not just to its actual temperature, but to the **rate** at which heat is flowing between the object and the body. This is of practical importance; water at 15° C feels much colder than air at the same temperature, warning us that heat loss is faster in the water, and therefore the danger of hypothermia is much greater.

Experiment Aim

To demonstrate that the **intensity** and **duration** of a stimulus are not always matched by the intensity and duration of the sensation.

Procedure

Work in your group and collect data from everyone.

Touch Sensation

1. Ask the subject to close their eyes.

2. Instruct the subject to focus on sensations evoked by objects as they are placed on the skin, and whether the sensation is the same 15 seconds later.

3. Have the subject rest the forearm on the bench, palm upwards. It is important that they do not shake during the test, as this will re-activate the receptors.

4. Place the cork on the subject's forearm. Avoid hair if possible (use palm if necessary). Wait 15 seconds.

5. After 15 seconds prompt for comments about the

sensation now experienced. Warn that you will soon remove the cork. Wait for a few seconds (you can choose how long to delay); then quickly but carefully lift the cork off the skin with a single, clean vertical movement.

6. Repeat steps 2 - 5 using the container filled with lead weight.

Results

Question A.2

Which object feels heavier/exerts a more intense sensation of weight?

Question A.3

Identify two ways this increase in intensity is signalled by the sensory neurons e.g. how does your brain identify the heavier object using only action potentials?

Question A.4

A) Can you feel the weight is there the whole time?

Cork:

Lead weight:

B) What have the light touch receptors done after responding to the initial change?

C) Does the difference between the cork and lead weight suggest that there may be a third way that sensory neurons have signalled the increase in intensity?

Temperature Sensation

1. Go to the water baths labeled 20°, 30°, and 40° C. Turn off any stirrers in the baths.

2. Place one index finger in the 40° C water bath and the other index finger in the 20° C water bath. Note the apparent temperature of the very tip of the finger (warm, neutral, or cold).

3. Keep the fingers as still as possible and wait one minute.

4. Compare the sensations at the tip of the fingers after one minute, with what you felt when the fingers were first inserted (note, ignore sensations at the skin around the water surface).

5. Now transfer the finger in the 20° C water bath to the 30° C water bath and note the sensation.

6. Simultaneously transfer the finger in the 40° C water bath to the 30° C water bath and note the sensation.

7. Turn stirrers back on.

Question A.5

A) Does the intensity of the cold and warm sensations stay the same for the entire duration of the first minute?

B) Why might the sensation from each finger differ when transferred into the 30° C water bath?

Question A.6

List the possible advantages and disadvantages of rapid sensory adaptation in the context of daily living and survival.

Apparent temperature of metal and wood

1. Find the brass rod on your tray. Think about what the temperature of this object would be.

2. Take the brass rod and compare the apparent temperature of the metal part and the wooden handle by touching them to skin on the anterior surface of the wrist.

Question A.7

A) Which part of the rod feels colder?

B) Is it actually colder?

The significance of detecting this rapid rate of change in skin temperature is illustrated by the answers to the following questions:

Question A.8

If you stay in water at 15° C you can become hypothermic much more quickly than in air. Why is this?

Question A.9

Why does a windy day feel colder than a calm one, even if the air temperature is the same?

Part B: Physiology of Peripheral Nerves & Skeletal Muscle

Peripheral nerves rapidly conduct signals throughout most of the body and are made up of sensory and/or motor neurons.

Sensory (or **afferent**) **neurons** transmit information about stimuli acting on the periphery to the central nervous system. Remember that a **sensory unit** is made up of a sensory neuron and its associated sensory receptors.

Motor (or **efferent**) **neurons** transmit information from the central nervous system to control **skeletal muscle** contraction (and other effector outputs).

Skeletal muscle is made up of individual muscle cells, called **muscle fibres.** The axon of each motor neuron branches to control several muscle fibres. A **motor neuron**, its axon, and the muscle fibres it controls are called a **motor unit.**

The physiological data that you will collect in your experiments are often small **analogue** signals. It is necessary to use specialised recording equipment to observe such data. The data acquisition system you will use is **PowerLab** and the software program is **LabTutor**. .

Experiment 3: Electrical Activation of Sensory Axons

Experiment Aim

To demonstrate the principle of recruitment of sensory neurons by increasing stimulus intensity. To demonstrate the coding of location in the nervous system by activation of specific axons.

The Ethics Committee of the University of Otago has reviewed and approved these experiments– Neurophysiology in humans.

Background Theory

Sensory neurons in peripheral nerves carry information from **receptors** in the skin. A sensory neuron and its associated receptors pick up stimuli applied to specific regions of skin, their **receptive field**. The brain interprets any activity coming from a particular sensory neuron as coming from that region of skin.

Procedure

Read and sign the consent form if you have not already done so. Go to the **LabTutor: Lab 4 - Peripheral Nerve Activation** experiment and follow the instructions for exercise 1. **ALL** students in your group can be subjects **IF** you work efficiently and effectively.

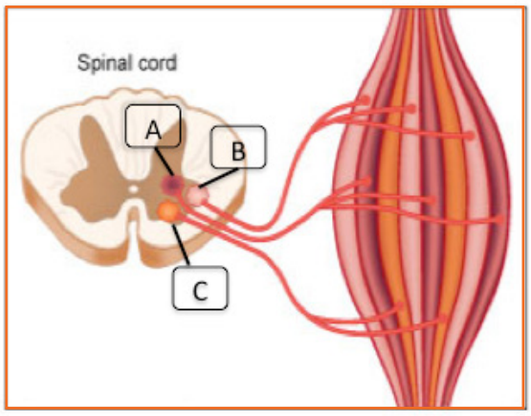

Fig. 4.6 *Motor units of muscle (Adapted from Fig. 12.18 Patton and Thibodeau, Anatomy and Physiology, 8th Edn., Elsevier, 2013).*

Question B.1

Describe the sensations evoked by the stimulus at low stimulus intensities. Where are the sensations felt?

Question B.2

What types of neurons were stimulated to produce the sensations felt at the elbow and in the hand?

Question B.3

Explain how the perceived location of the sensation can be different from the actual location of the stimulus.

Question B.4

Sometimes amputees can still have sensations that appear to originate from their amputated limb, if these are painful these are known as 'Phantom Pains'. How does this relate to the experiment just performed?

Experiment 4: Control of Muscle Force

Experiment Aim

To demonstrate the control of muscle force by two mechanisms: **recruitment** of motor units and increasing the **frequency** of activation.

Background Theory

In skeletal muscle, the action potential generated in a motor neuron propagates by regenerating itself along the axonal membrane until the action potential reaches a ***specialised synapse*** called the **neuromuscular junction (NMJ)** (**Fig. 4.8**). The motor neuron releases a neurotransmitter that diffuses across the synapse. The neurotransmitter interacts with the muscle fibre membrane to generate an

action potential. The action potential propagates along the muscle fibre membrane and causes the release of **calcium ions** from intracellular stores. This triggers the contraction of that muscle fibre. A single action potential in a single motor unit will evoke the brief development of tension, known as a muscle **twitch**. The force generated by a twitch of a single motor unit is very small.

Control of force generated by a whole muscle is achieved by regulating motor unit activity in two ways:

A. **Recruiting** more motor units into action, so more fibres are twitching.

B. Activating individual motor units at higher **frequency**, which causes twitches to add together (called treppe; at very high frequencies twitches merge together and force reaches a maximum called **tetanus**).

Procedure

Continue with the LabTutor Experiment: **Peripheral Nerve Activation**.

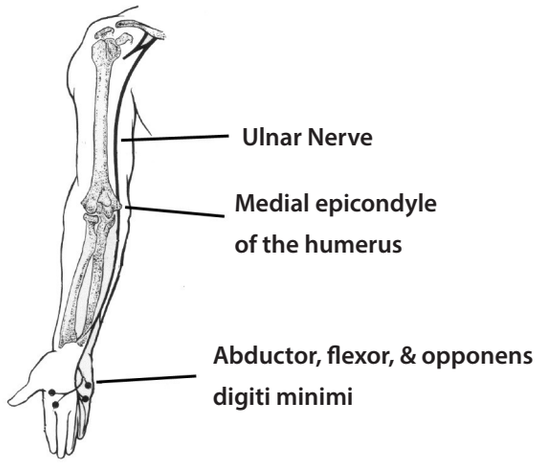

Fig. 4.7 *Ulnar nerve. At the elbow the nerve runs behind the medial epicondyle of the humerus in the groove formed by the bony prominences of the epicondyle and the olecranon process. (Adapted from Gardner, Gray & O'Rahilly, Anatomy, 3rd Edn., 1969).*

Question B.5

Your threshold stimulus amplitude =

Your maximum stimulus amplitude =

Question B.6

Describe the changes you observed in the muscle twitches evoked as you increased the strength of the stimulation.

Question B.7

What is a motor unit?

Question B.8

Increasing the current (strength of the stimulation) increases recruitment / frequency (circle correct answer).

Question B.9

How does increasing the current (strength of stimulus) cause an increase in the force of the twitches?

Question B.10

Describe the changes you observed in the muscle twitches evoked as you reduced the interval between stimuli.

Question B.11

What is mechanical summation?

Question B.12

What is tetanus?

Question B.13

Decreasing the interval between stimuli causes an increase in recruitment / frequency (circle correct answer).

Question B.14

How does increasing the frequency of stimulation increase muscle force?

Experiment 5: Generating an Electromyogram

In this experiment you will record an **electromyogram** (**EMG**), a recording of the **electrical** activity in a skeletal muscle. You will place surface recording electrodes on the subject's skin, superficial to the biceps brachii muscle. The surface electrodes are the sensors that detect electrical activity (voltage changes) on the surface of the skin. This electrical activity is produced by electrical signals (action potentials) sent from the brain to the muscle to cause the contraction of biceps brachii. PowerLab converts the detected electrical activity from an analog to a digital format. LabTutor records the data and reconstructs the original analog waveform from the digitised data.

It is important to note that an EMG is **not** a recording of the muscle contraction but a recording of the electrical activity in the muscle that leads to the contraction of the muscle.

Experiment Aim

To record the electromyogram (EMG), firstly as a means to learn how to use the LabTutor system for the collection of physiological data, and secondly to better understand the relationship between electrical and mechanical events involved in muscle contraction.

Procedure

Open the LabTutor experiment '**Lab 4 - Electromyogram**' Work in your group of three. Today, due to time constraints, we will record from one subject only.

Results

Question B.15

In an EMG of a voluntary movement, the electrical activity is initiated in the _____ and is sent to the skeletal muscle.

Fill in the blank axes on the left with the data that you have just produced. Remember to label both axes and give your graph a title. To help with this, a simplified graph based on example data from a subject performing the same experiments is provided.

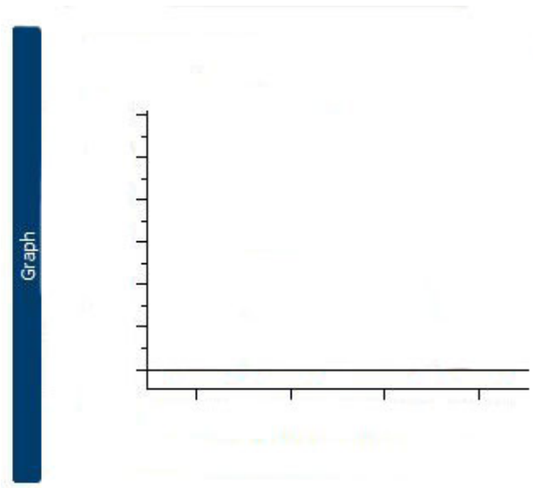

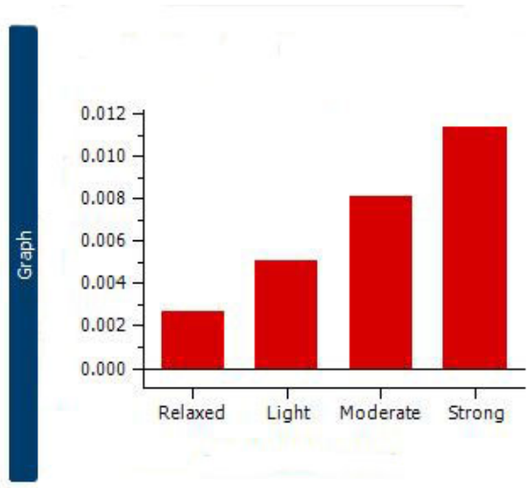

Question B.16

If your data does not look like the data provided in the example graph, why might this be?

Question B.18

Which of the following statements is correct?

1) Skeletal muscle contractions occur due to electrical activation.

OR

2) Electrical activity is generated by the contraction of skeletal muscle.

Question B.17

What is the relationship between the amplitude of the EMG recorded and the amount of electrical activity in the muscle?

Question B.19

If an injury caused a nerve to be damaged between the brain and the biceps muscle, would you still be able to detect and record EMG activity in the biceps muscle?

Experiment 6: Nerve Conduction Velocity

Experiment Aim

To measure the conduction velocity of the ulnar nerve between the elbow and the wrist. To determine the range and mean conduction velocity for a group of young adults.

Background Theory

The speed of conduction of the action potential along a neuronal axon (**conduction velocity**) depends on the extent of **myelination** of the axon. Peripheral nerves are made up of many axons, so the measurement of the conduction velocity of a nerve is an average conduction velocity of many axons.

Measurement of conduction velocity of peripheral nerve axons is clinically important. Certain diseases and injuries decrease nerve conduction velocity as they cause a loss of myelin (**demyelination**). The standard international (SI) units for velocity are metres per second (m/s).

Stimulating a single axon and measuring its activity in a living person is difficult. Even recording directly from a whole nerve is difficult. However it is easy to stimulate a whole nerve and to record the **electromyograms (EMGs)** evoked in the skeletal muscle innervated by the nerve.

Conduction velocity of the nerve can be calculated by measuring the time delay it takes for the muscle to respond (the **latency**) following nerve stimulation. The total latency of a muscle response to nerve stimulation is due to a combination of several phenomena:

- Initiation of the action potential in the nerve by the electrical stimulus. This is very brief and generally ignored in calculations.
- Propagation of the action potential along the nerve. This is the component of interest.
- Processes of synaptic transmission at the synapse between the axons and the muscle (the **neuromuscular junction, NMJ**).
- Propagation of the action potential along the muscle to the recording electrodes. This is relatively slow, compared to axons.

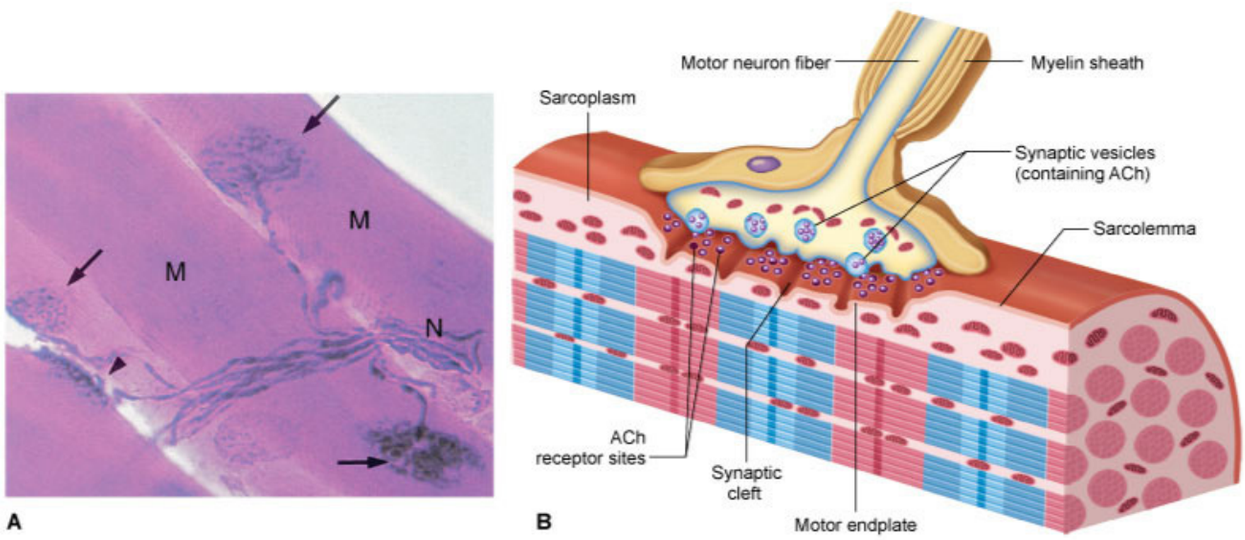

Fig. 4.8 *Neuromuscular junction (NMJ) shown as a micrograph (**A**) and in diagramatic form (**B**). (Fig. 12-7, Patton & Thibodeau, Anatomy and Physiology, 8th Edn., Elsevier, 2013).*

Procedure

Open the LabTutor experiment '**Lab 4 - Conduction Velocity**'.

Results

On the axes provided below, draw as best you can how your EMG appears on the screen on LabTutor. Remember to label your axes and provide a title for your graph. (**Hint**: All this information can be found on LabTutor).

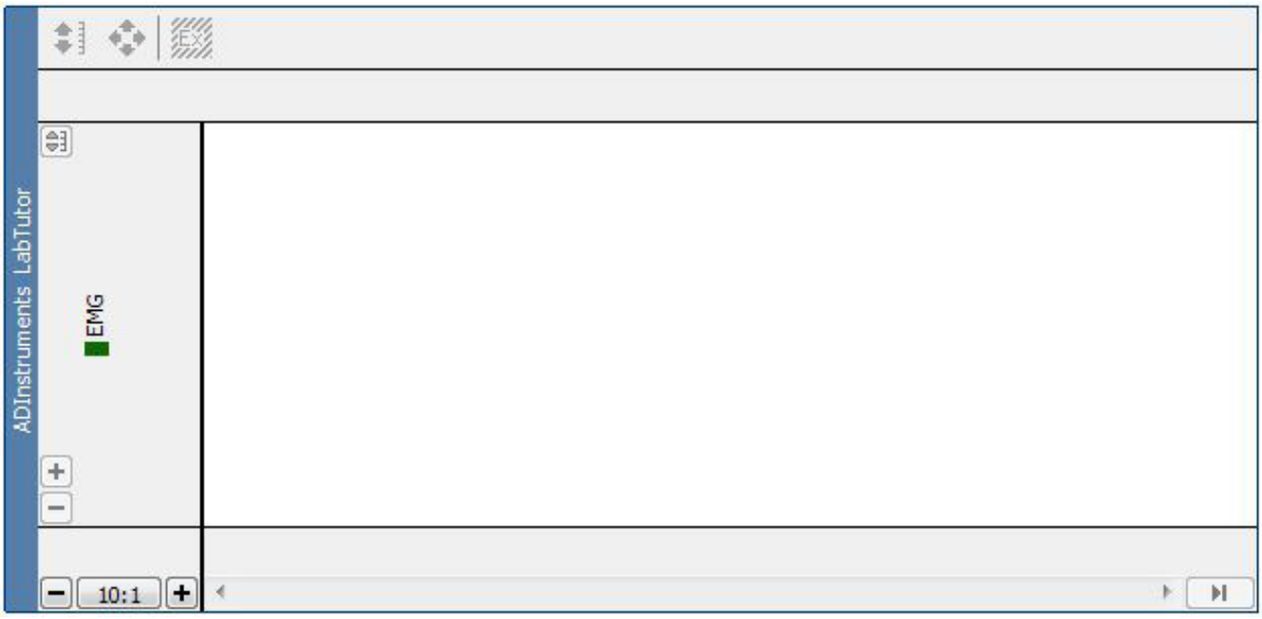

Nerve Conduction Velocity - Subject 1				
Wrist Latency (ms)	**Elbow latency (ms)**	**Conduction Time (ms)**	**Conduction Distance (mm)**	**Conduction Velocity ($m.s^{-1}$)**
3.0 ms				

Conduction Velocity Class Data	**Minimum ($m.s^{-1}$)**	**Maximum ($m.s^{-1}$)**	**Mean ($m.s^{-1}$)**

Question B.20

What is the formula used to calculate conduction velocity (V) from conduction time (t) and distance (d)?

Question B.21

What are the SI units for velocity?

Question B.22

What physiological processes contribute to the total latency of the muscle response following electrical stimulation at the elbow?

Question B.23

Why was the wrist latency provided in the table on the previous page?

Question B.24

Is the speed of the action potential conduction the same at all points along the path from stimulation site to muscle recording site? Why so?

Question B.25

How does your conduction velocity compare to the speed of a car (Hint: convert your ulnar nerve conduction velocity to km/h, *i.e.* x 3.6).

Question B.26

What is the advantage of having fast conduction velocities in the nerves controlling skeletal muscles?

You have now finished the lab activities.

Please be sure to tidy up your area. Remember, if you have any questions don't hesitate to ask a demonstrator. if you are waiting for the wrap-up, there is additional material available in the Lab 4 folder on your computers.

Lab 5: Principles of Homeostasis

In this laboratory you will examine physiological control systems. There are two parts to this laboratory. In Part A you will examine neural control of core body temperature using the LabTutor system. In Part B you will investigate hormonal control of plasma glucose in Experiment 2 and neural control of the diameter of the pupil of the eye (light reflex) in Experiment 3.

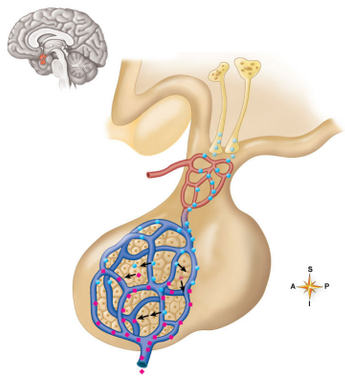

Fig. 5.1 *Hypophyseal portal system (Fig. 19-4, Patton & Thibodeau, Anatomy & Physiology, 8th Edn., 2013).*

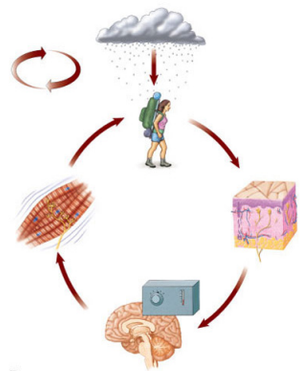

Fig. 5.2 *Core temperature homeostasis (Fig. 1-13B, Patton & Thibodeau, Anatomy & Physiology, 8th Edn., 2013).*

Pre-lab Preparation

It is essential that you complete these activities prior to coming to the laboratories, as it will ensure that you make the most from your time within the lab.

- Read General Background, Part A, Part B
- Revise lectures Homeostatic Principles 1-3
- Revise textbook Patton and Thibodeau 8th Edn., p. 18-25, 182-184, 191-192 & 943-945
- Complete Pre-Lab Task 1 in the general background section and Pre-Lab Tasks 2 and 3 in Part A

Aim

To explore the concepts involved in control systems as applied to human biology and in particular to homeostatic control of the extracellular fluid environment of cells in the body.

Objectives

By the end of this lab you should be able to:

A. Explain in words (and with diagrams) the terms: controlled variable, set point, sensor, integration centre, control signals, communication pathways, effector, feedback and feedforward, as used in physiological control systems.

B. Describe a physiological control system (feedback and feedforward control) that uses neural communication.

C. Describe a physiological control system that uses hormonal communication.

D. Discuss the origins of intra- and inter-individual differences in physiological measurement.

E. Describe the relative advantages of hormonal and neural signaling in physiological control.

PRE-LAB TASK 1

Use the summary diagram of a generic feedforward control system and a generic negative feedback control system below to complete table. 5.1 on the next page.

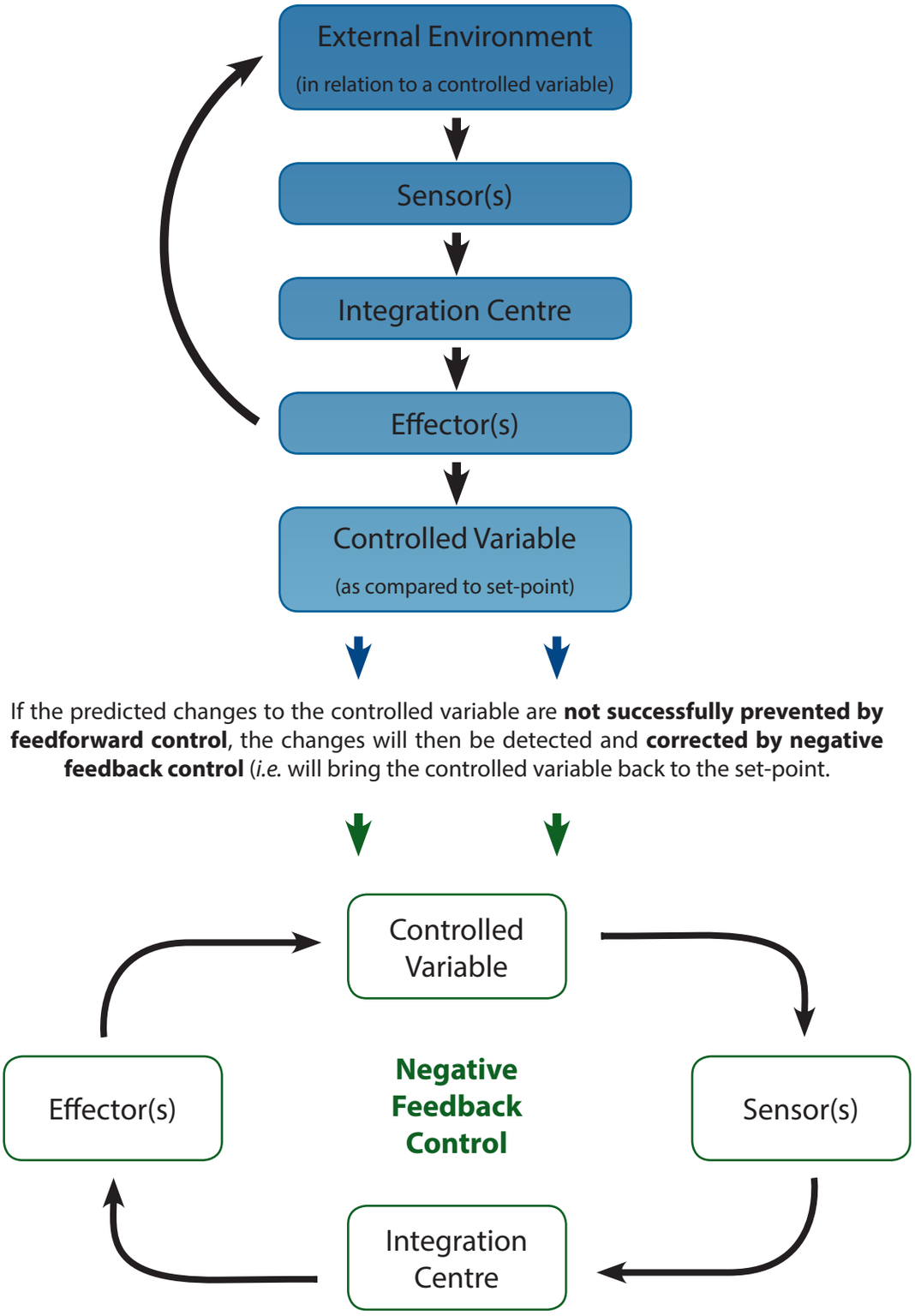

Fig. 5.3 *Feedforward & negative feedback control system diagrams. (Physiology Teaching Resources, University of Otago).*

PRE-LAB TASK 1 continued.

Insert the following labels into the spaces provided:

actual, communication pathways (2x), control, controlled, correct, environment, integration centre (2x), predicted, prevent, reduce, signals.

Table 5.1 *Comparison of feedforward & negative feedback control systems. (Physiology Teaching Resources, University of Otago).*

	Feedforward Control	**Negative Feedback Control**
Sensor(s)	The sensor detects changes in the situation or the_____. This information is then sent to the _____ _____.	The sensor detects changes in the _____ variable. This information is then sent to the _____ _____.
Integration Centre	The integration centre compares the _____ value, derived from information sent from the sensors, to the set-point value. It then sends _____ signals *via*_____ _____ to activate the effectors.	The integration centre compares the _____ value, sent from the sensors, to the set-point value. It then sends control _____ *via*_____ _____ to activate the effectors.
Effector(s)	The actions of the effectors _____ or _____the *predicted* changes in the **controlled variable.**	The actions of the effectors _____ the *actual* changes in the **controlled variable**.

PRE-LAB TASK 2

Complete the negative feedback control summary diagram for an **INCREASE** in core body temperature. **Insert the following labels into the spaces provided:**

action potentials, axons, central thermoreceptors, evaporation, glands, hypothalamus (2x), radiation, skin, sweat.

Controlled Variable:

Core Body Temperature ↑

Effector(s)

Blood vessels in the _____ vasodilate to cause heat loss *via* _____.

Sweat _____ secrete _____ to cause heat loss *via* _____.

Sensor(s)

The _____ _____ in the _____ detect the increase in temperature and send this information to the integration centre.

Integration Centre

The _____ compares the actual temperature to the set-point temperature and sends control signals called _____ _____ to the effectors *via* communication pathways called _____.

Fig. 5.4 *Negative feedback control to an increase in core body temperature (Physiology Teaching Resources, University of Otago).*

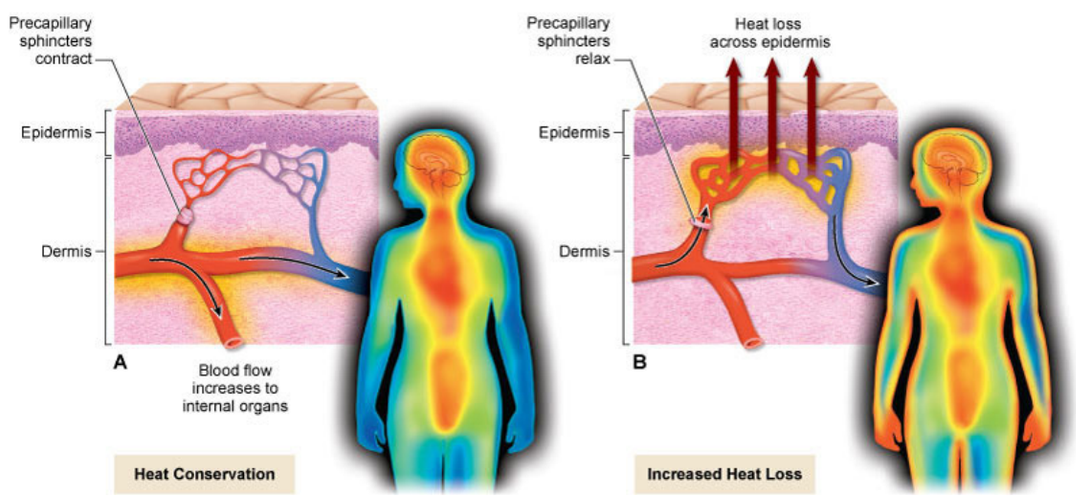

Fig. 5.5 *(A) An example of heat conversation due to vasoconstriction (B) An example of heat loss due to vasodilation and increased blood flow to the skin. (Fig. 7.15, Patton & Thibodeau, Anatomy and Physiology, 8th Edn., Elsevier, 2013).*

PRE-LAB TASK 3

Complete the negative feedback control summary diagram for a **DECREASE** in core body temperature. **Insert the following labels into the spaces provided:**

action potentials, axons, central thermoreceptors, goosebumps, hypothalamus (2x), muscles, shivering, vasoconstrict.

Controlled Variable:

Core Body Temperature ↓

Effector(s)

Skeletal _____ produces heat *via* _____. Blood vessels in the skin _____ and piloerector muscles contract to form _____ on the skin to minimise heat loss from the body.

Sensor(s)

The _____ _____ in the _____ detect the decrease in temperature and send this information to the integration centre.

Integration Centre

The _____ compares the actual temperature to the set-point temperature and sends control signals called _____ _____ to the effectors *via* communication pathways called_____.

Fig. 5.6 *Negative feedback control of a decrease in core body temperature. (Physiology Teaching Resources, University of Otago).*

Part A: Neural Control Systems

Experiment 1: Control of Core Body Temperature

Background Theory

Core body temperature is the temperature of the major organs of the head, chest, and abdomen. The temperature of our core is dependent on the heat produced by **metabolic processes** and the transfer of heat between the body and the environment. Both the rate of metabolic heat production and the transfer of heat to or from the environment can change quickly leading to perturbations in core body temperature. Monitoring and responding to changes occurs *via* rapid neural control.

In this part of the lab, we will measure core and peripheral body temperature, and examine how these are affected by moderate exercise. This is an example of negative feedback control.

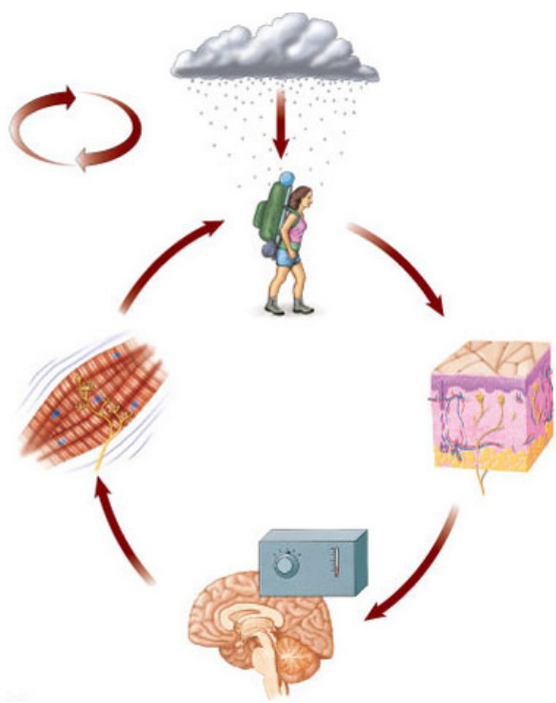

Fig. 5.7 *Basic negative feedback loop (Fig. 1-13, Patton and Thibodeau, Anatomy & Physiology, 8th Edn., 2013)*

The essential components of the core body temperature negative feedback loop are (Pre-lab tasks 2 and 3):

- **Controlled variable** = core body temperature
- **Sensor** = central thermoreceptors in the hypothalamus
- **Integration centre** = neurons in the hypothalamus
- **Communication pathways** = neuronal axons
- **Control signals** = action potentials
- **Effectors** = smooth muscle in the walls of skin blood vessels, skeletal muscle, sweat glands, piloerector muscle of skin hair

Note that a decrease in core body temperature will require a different response (and different effectors) than would be required for an increase in core body temperature.

During exercise, the negative feedback loop operates by exercise generating heat as a product of the increased **metabolism**. This heat begins to increase core body temperature, which is detected by the **central thermoreceptors** in the **hypothalamus**. The hypothalamic neurons send signals *via* the peripheral nervous system to increase sweat production from sweat glands and to increase **vasodilation** in superficial blood vessels. This increases the opportunity for heat loss from the body *via* evaporation, conduction, convection, and radiation. An increase in heat loss, if it balances the increase in heat production, will **stabilise** core body temperature.

Feedforward control of core body temperature occurs when a perturbation of core body temperature is **anticipated** and attempts are made to **minimise** the predicted change. Peripheral thermoreceptors monitoring skin temperature, and behaviours like listening to weather forecasts and dressing appropriately, help with **feedforward control** of core body temperature.

Question A.1

What do you notice about the location of the sensor and integration centre in the negative feedback control of core body temperature?

Experiment Aim

To record core and peripheral body temperatures before and after moderate exercise in order to examine the negative feedback control of core body temperature.

The Ethics Committee of the University of Otago has reviewed and approved these experiments– Practical classes involving Exercise (Dynamic or static).

Procedure

Work in your group when performing experiments using LabTutor. All members of your group should be able to record control data today but only one member will exercise. One person operates the computer, and one person volunteers to be the initial subject in the experiments.

Go to the LabTutor **Lab 5 - Control of Core Body Temperature** experiment. Read LabTutor pages and follow the instructions to estimate your core body temperature. Please record your results within LabTutor and on the whiteboard.

Question A.2

What process produces heat in our bodies?

Question A.3

Why might oral temperature be lower than ear temperature?

Question A.4

A) List four ways heat can be transferred from the body to the environment (body heat loss).

1.

2.

3.

4.

B) Which of the above mechanisms can be used to transfer heat from the environment to the body (body heat gain)?

1.

2.

3.

Question A.5

Name one other site from where core body temperature could be estimated.

Question A.6

Identify at least two external factors that determine peripheral skin temperature.

Continue with LabTutor and follow the instructions to estimate the environmental and peripheral body temperature. Please record your results within LabTutor and on the whiteboard.

The first subject will be connected to the PowerLab as shown in Fig. 5.8.

IMPORTANT: Anyone completing the following experiment **MUST** read and sign the consent form that accompanies this experiment.

Question A.7

Which external factor would most likely contribute to inter-subject difference in peripheral skin temperature measured today?

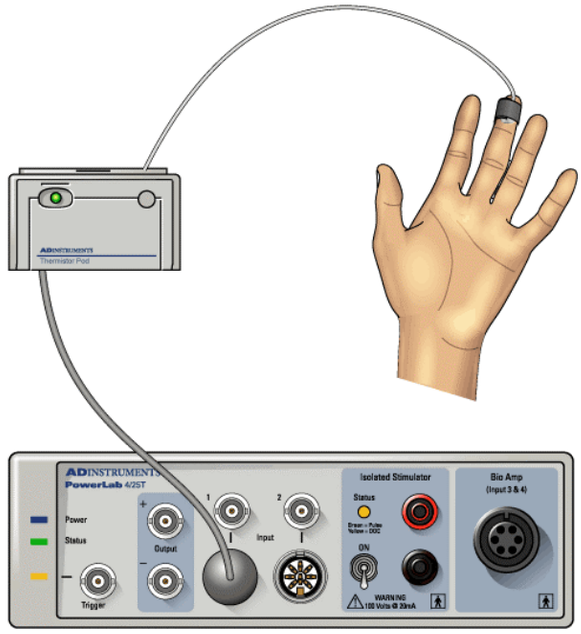

Fig. 5.8 *Set up for recording peripheral skin temperature. (AD Instruments 2010)*

Room Temperature (°C)	

Core Body Temperatures (°C)				
	Subject 1	Subject 2	Subject 3	Mean
Ear				
Oral				

Exercise and Body Temperature (°C)			
	Resting	Post-Exercise	Change
Fingertip			
Palm			
Forehead			
Ear			
Oral			

Question A.8

A) Does the subject feel hotter than before the exercise?

B) Do the subject's feelings reflect a change in core temperature? If not, why does the subject feel hot?

Question A.9

Which two physiological responses to an increase in heat production did you observe? How do these responses get rid of excess heat?

Question A.10

When a person is very cold sometimes their skin will look pale. This reflects the regulation of heat flow from the core to the limbs. How is this regulation achieved?

Question A.11

Name two additional responses that may occur as a result of cold exposure. Explain how these responses affect heat loss (Hint: refer to the effectors in Fig 5.6).

Question A.12

A) Before exercising, did your subject use a feedforward control mechanism to prevent an increase in body temperature?

B) How do peripheral thermoreceptors contribute to feedforward control of core body temperature?

Part B: Hormonal and Neural Control Systems

Experiment 2: Blood Glucose Measurement

IMPORTANT: Anyone completing the following experiment **MUST** read and sign the consent form that accompanies this experiment.

The Ethics Committee of the University of Otago has reviewed and approved these experiments– Practical classes involving finger-prick blood sampling.

Background Theory

Glucose concentration in the extracellular fluid has to be maintained at suitable levels to provide energy for cells; if too low, the brain cannot work, and if too high, damage to cells can occur. The regulation of blood glucose concentration within acceptable limits is thus an example of homeostasis. The adult reference range for blood glucose concentration is **3.5 – 6** mmol L^{-1} (in the **fasting state**).

The control system for glucose includes both feedback and feedforward components. Negative feedback control of blood glucose concentration is an example of a control system that uses hormonal communication and involves two opposing signals to achieve optimal control. The sensor and integration centre are combined in a single organ.

The essential components of the negative feedback control system for glucose are:

- **Controlled variable** = blood glucose concentration
- **Sensor, integration centre** = cells in the pancreas
- **Communication pathway** = the blood stream
- **Control signals** = hormones (balance of mainly but not only, insulin and glucagon concentrations)
- **Effectors =** liver, skeletal muscle, adipose tissue

The negative feedback control system operates as follows:

A rise in blood glucose concentration after a meal (**fed state**) triggers the release of insulin from the pancreas, which stimulates glucose uptake into liver, muscle and adipose tissue for use and storage. This lowers blood glucose concentration, and hence, the insulin level also falls again (negative feedback loop).

Between meals (**fasting state**), glucagon and other hormones are released that stimulate the liver to release glucose into the blood (opposing arm of the negative feedback loop).

Feedforward control operates as follows:

Physiological: Food entering the stomach can trigger insulin release before blood glucose starts to rise.

Behavioural: Eating food with a high energy content before exercise.

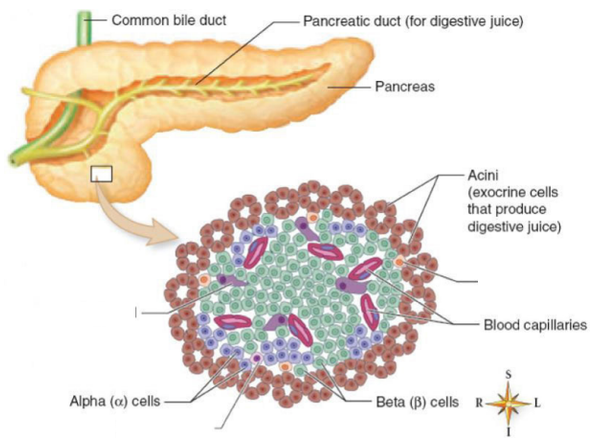

Fig. 5.9 *The pancreas and acini (Fig. 19-22, Patton and Thibodeau, Anatomy & Physiology, 8th Edn., 2013)*

Experiment Aim

We will examine blood glucose regulation to demonstrate the principles of hormonal physiological control systems. Note glucose regulation is discussed further in the endocrine lectures.

Procedure

Spilled blood must be cleaned up with an anti-viral agent. Please notify your demonstrator if this occurs.

1. Make sure you have all the equipment you need:
   - ***i.*** auto lancet and disposable tip
   - ***ii.*** glucometer and disposable test strip
   - ***iii.*** alcohol swab, tissue and a band-aid.
2. **Read and sign the consent form.**
3. Read all the following instructions right through before beginning so you know in advance the sequence of events.
4. Clean finger with alcohol swab. Wait 30 seconds for alcohol to evaporate.
5. Activate the lancet and attach a new disposable tip.
6. Turn the glucometer on and insert a test strip.
7. Puncture finger.
8. Wait a few seconds for a drop of blood to build up. If necessary 'milk' more blood out of the puncture by firmly pressing along the finger from the base towards the puncture site. You need a rounded drop of blood.
9. Touch the absorbing site of the test strip (marked by a small cut-out) to the drop, and allow the small square of absorbent gauze area to completely fill with blood.
10. Apply pressure to the puncture site with tissue then place a band-aid on it.
11. Record your blood glucose concentration; including the time the test was taken, in Table 5.1.
12. Wait 20 minutes. Complete Experiment 3 and Task 4 whilst you wait.
13. Repeat steps 4 - 11 for second sample.
14. Enter the time and type of your last food consumption in Table 5.1.
15. Enter your data on the whiteboard.
16. Collate group data and enter the group minimum and maximum values in Table 5.1.

Note, there is a video demonstration of the above procedures on your computers.

Results

Table 5.1 *Individual and group blood glucose concentrations.*

Description of last meal:			**Time of last meal:**	
Blood glucose (mmol.L^{-1})			**Time of test**	**Time since meal**
First Sample				
Second Sample				
Group Range	**Minimum**		**Maximum**	

Question B.1

What do you notice about the location of the sensor and integration centre in the negative feedback control of blood glucose concentration?

Question B.2

Give at least one example of a feedforward behaviour that we use to help minimise fluctuations in blood glucose concentration.

Task B.1

Complete the negative feedback control summary diagram for an **INCREASE** in blood glucose concentration

Insert the following labels into the spaces provided: bloodstream, insulin, insulin secreting cells (2x), liver, muscle, pancreas, tissue.

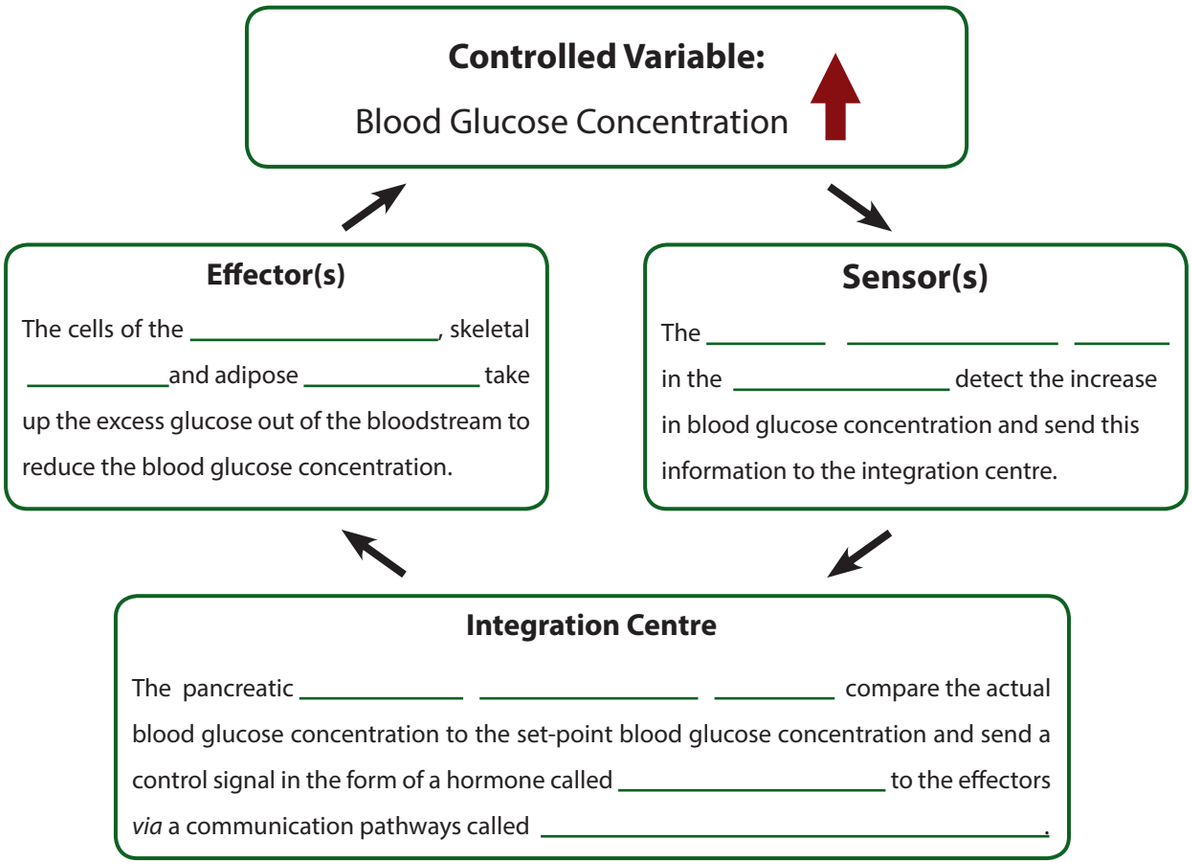

Fig. 5.10 *Negative feedback control of an increased blood glucose concentration. (Physiology Teaching Resources, University of Otago).*

Task B.2

Complete the negative feedback control summary diagram for a **DECREASE** in blood glucose concentration

Insert the following labels into the spaces provided: bloodstream, glucagon, glucagon secreting cells (2x), liver, pancreas.

Controlled Variable:

Blood Glucose Concentration

Effector(s)

The _____ releases stored glucose into the blood stream to increase the blood glucose concentration

Sensor(s)

The _____ _____ _____ in the _____ detect the decrease in blood glucose concentration and send this information to the integration centre.

Integration Centre

The pancreatic _____ _____ _____ compare the actual blood glucose concentration to the set-point blood glucose concentration and send a control signal in the form of a hormone called _____ to the effectors *via* a communication pathways called _____.

Fig. 5.11 *Negative feedback control of a decreased blood glucose concentration. (Physiology Teaching Resources, University of Otago).*

Question B.3

Give at least two possible causes of any variation seen in your own values (Objective D).

Question B.4

Give at least two possible reasons for the variation seen between individuals (Objective D).

Task B.3

Enter your own blood glucose concentration relative to the time of your last meal on Fig 5.12.

On the Y-axis only, insert the minimum and maximum concentrations for the class.

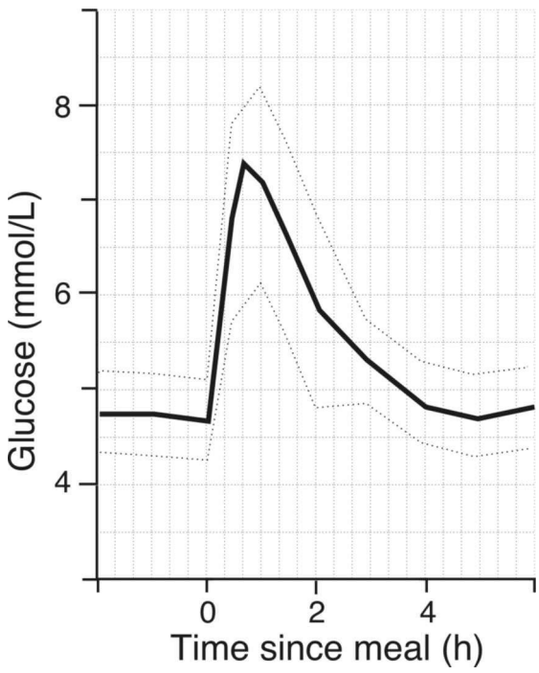

Fig. 5.12 *Mean blood glucose level (n = 17 subjects) following a standardised (50:37:13% carbohydrates:fat:protein) meal. Dotted lines show one standard deviation (Adapted from Mari et al., Am J Physiol Endocrinol Metab 283:E1159-1166, 2002).*

Question B.5

Circle the correct answer:

Hormonal control acts over:

(a) milliseconds to seconds or

(b) minutes to hours

Experiment 3: Light Reflex

Background Theory

The light reflex is an example of negative feedback controlled by the nervous system. Intensity of light shining on the **retina** is the controlled variable. When a light shines in the eye, the amount of light reaching the retina increases. The pupil circular muscle reflexively constricts, reducing the **pupil** diameter and therefore reducing the amount of light reaching the retina.

This reflex involves a sensor (rods & cones of the retina), communication pathway via afferent neurons to the central nervous system (brainstem = integration centre) and efferent neurons carrying control signals back to the effector organs (pupil circular muscle).

Experimental Aim

You will examine the light reflex to demonstrate the speed of negative feedback control by the nervous system.

Procedure

Using a torch, briefly shine the light beam into the participant's eye. Observe the change in the pupil diameter. Note that both pupils respond. Observe the speed of the response to your light beam.

Question B.6

Circle the correct answer:

Neural control acts over:

(a) milliseconds to seconds or

(b) minutes to hours

Task B.4

Complete the negative feedback control summary diagram for the control of intensity of light shining on the retina

Insert the following labels into the spaces provided: action potentials, axons, central nervous system, light receptors, iris.

Controlled Variable:

Intensity of light falling on the retina

Effector(s)

The _____ constricts, making the pupil smaller, to reduce intensity of light falling on the retina, or dilates, making the pupil larger, to increase intensity of light falling on the retina.

Sensor(s)

The _____ _____ (rods & cones of the retina) detect the increase or decrease in the intensity of light falling on the retina and send this information to the integration centre.

Integration Centre

The _____ _____ _____ compares the actual intensity of light to the set-point intensity of light and sends control signals called _____ _____ to the effectors *via* communication pathways called _____.

Fig. 5.13 *Negative feedback control of the light reflex. (Physiology Teaching Resources, University of Otago).*

Question B.7

What are the relative advantages and disadvantages of neural and hormonal signaling for communication in homeostatic control (Objective E)?

Question B.8

As we move through the environment we pass through areas of light and shade. If the light reflex were controlled by hormonal rather than neural signals, what would happen to the ability of the pupil to respond to these different light levels?

Question B.9

If someone was unconscious, will a light reflex still occur if that person's eyelids were held open and a light is shone into them?

Explain why or why not.

Question B.10

Identify a common feedforward behaviour that serves to prevent too much light from reaching the retina (Hint: what do you do on a sunny day?).

Task B.5



Clues Across

4. *The state of equilibrium of an organism's internal environment that is maintained using various physiological processes.*

6. *In response to a rise in core body temperature these effectors are stimulated to secrete fluid to aid in cooling the body through evaporation.*

7. *This type of physiological control system works slowly and has long-term sustained effects.*

8. *Detected changes in peripheral body temperature are used in the feedforward control of _____ _____ temperature.*

9. *When a person has not eaten for an extended period of time they are said to be in a state of _____.*

12. *The _____ range for blood glucose concentration is 4 - 6 mmol/L in the fasting state.*

14. *The primary role of effectors is to _____ a controlled variable to its set-point value.*

17. *In neural control systems the control signal is an _____ _____ that travels along the axon of a neuron.*

18. *The sensors and integration centre for the control of core body temperature are located here.*

20. *When core body temperature drops, blood vessels in the skin will _____ to reduce blood flow to the skin.*

22. *This hormone is released from the pancreas during the fasting state to facilitate the release of glucose into the blood when the blood glucose concentration is too low.*

24. *The communication pathway in a hormonal control system.*

26. *Heat transfer through air or fluid movement.*

28. *Actions of the _____ are intended to return the controlled variable to its set-point value.*

31. *The location of peripheral thermoreceptors, goose bumps and sweat glands.*

32. *This device is used to measure blood glucose concentration.*

33. *Feedforward control of blood glucose concentration may include taking this with you to work or school.*

35. *The _____ value is detected by sensors and compared to the set-point value in the integration centre.*

36. *In the _____ centre, actual (detected) values are compared to set-point values for a given controlled variable.*

40. *When core body temperature rises, blood vessels in the skin will _____ to increase blood flow to the skin.*

41. *Heat transfer through direct contact.*

42. *The iris of the eye constricts or dilates to control the _____ of light shining through the pupil onto the cells of the retina.*

48. *This is the cellular process employed by the body to produce heat.*

49. *The primary role of a sensor is to _____ changes in the controlled variable.*

51. *This organ is both the sensor and integration centre in the hormonal control system that regulates blood glucose concentration.*

53. *A _____ detects changes in a controlled variable.*

54. *This hormone is released from the pancreas after a meal to facilitate the uptake of glucose into organs to lower blood glucose concentration.*

55. *The iris surrounds this small black hole through which light enters the eye.*

Clues Down

1. *Wearing sunglasses on a sunny day is an example of behavioral feedforward action based on cues from the external _____.*

2. *The part of a neuron used as the communication pathway in neural control systems.*

3. *Control signals travel through the body along _____ pathways.*

5. *This effector organ stores glucose from the blood in the presence of insulin.*

10. *These effectors vasoconstrict or vasodilate to control blood flow to the skin.*

11. *Feedforward control of light intensity shining on the retina may involve the wearing of these.*

13. *Glucagon and insulin are examples of these.*

15. *Production of sweat helps to cool the body through this process.*

16. *In response to a decrease in core body temperature, skeletal muscles are stimulated to _____.*

19. *A method of heat transfer utilised by the sun or the body where energy is emitted from the body into the surrounding environment.*

21. *A control mechanism used to predict and prevent/ reduce changes in controlled variables within the body.*

23. *If the actual value of the controlled variable differs from the set-point value, _____ signals will be sent from the integration centre to effector organs.*

25. *In feedforward control, changes to a controlled variable are _____ and prevented or reduced.*

26. *Feedforward control of core body temperature may include the wearing or removal of _____.*

27. *A physiological control system that reverses (corrects) changes in controlled variables within the body is called a _____ feedback control system.*

29. *Another name for adipose tissue.*

30. *Control signals are sent to effectors to _____ them.*

34. *A variable the body tries to maintain within specified limits.*

37. *In response to a decrease in core body temperature, piloerector muscles in the skin are stimulated to contract, thus forming _____ _____ that trap a thin layer of warm air next to the skin.*

38. *Blood vessels vasoconstrict to reduce skin blood flow to _____ body heat.*

39. *These thermoreceptors are located in the skin.*

43. *The part of the eye where light sensors called rods and cones are located.*

44. *This type of tissue works as an effector in the control of blood glucose concentration, by removing glucose from the blood in the presence of insulin.*

45. *An example of a hormonal control system is the regulation of blood _____ concentration.*

46. *This type of control system works very quickly and has short-lived effects.*

47. *These thermoreceptors are located in the hypothalamus and detect core body temperature.*

50. *This effector organ releases glucose into the blood in the presence of glucagon, but stores glucose from the blood in the presence of insulin.*

52. *The coloured part of the eye that constricts or dilates to control light intensity shining on the retina.*

NOTES PAGE:

Lab 6: Immunology

In this lab you will investigate both the early response of the body to microbial attack and the activation of the adaptive immune response. We will observe how the host response to infection can lead to destruction of the invading microbe, and how this response can be measured in the laboratory. This laboratory session is designed to complement the 'Immunology' lectures. Therefore you should have reviewed as many lectures as possible before attending this lab.

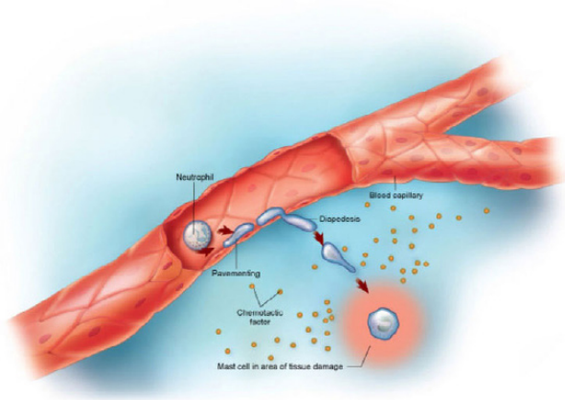

Fig. 6.1 Chemotaxis and diapedesis (Fig. 24-5, Patton) & Thibodeau, 8th Edn., pg. 751).

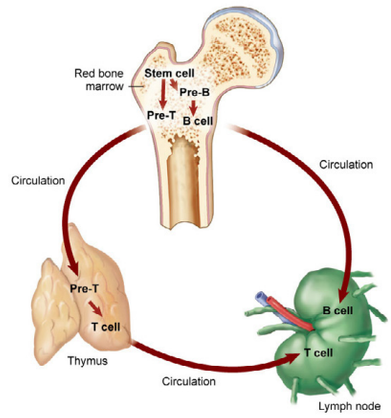

Fig. 6.2 Development of B and T cells (Fig. 24-12, Patton & Thibodeau, 8th Edn., pg. 756).

Objectives

By the end of this lab you should be able to:

A. Outline the general range of innate defence mechanisms and the events that occur when a microbe penetrates into the tissues of the body.

B. Define the terms given in bold in the text, *e.g.* phagocytosis, macrophage, dendritic cell, cytokine, antibody etc.

C. Describe the process of phagocytosis (your lecture notes will be useful for this).

D. Explain what is meant by 'neutrophilia' and 'pyrexia' in relation to inflammation, including an outline of how they are measured and what physiological factors influence the result.

E. Explain the role of opsonisation in phagocytosis.

F. Describe the main events from bacterial antigens entering the body to antibody production.

G. Describe the principles of the detection of serum antibody using the ELISA.

Pre-lab Preparation

It is essential that you complete these activities prior to coming to the laboratories. Failure to do so will severely hinder the learning opportunities for you and your lab group.

- Today's laboratory refers specifically to content covered in lectures 40-49.
- Read Patton and Thibodeau textbook, 8th Edn., pages 745-781.
- Complete Pre-lab Tasks 1 & 2.

PRE-LAB TASK 1

Briefly list how infections caused by skin-borne bacteria can be prevented by physical and chemical barriers and the innate immune system.

PRE-LAB TASK 2

Familiarise yourself with the ELISA test in this laboratory manual used to detect the presence of antibody to bacteria (e.g. *Staphylococcus*)

Using the anti-staphylococcal antigen ELISA as an example, label the numbered parts of the diagram below.

1. _____

2. _____

3. _____

4. _____

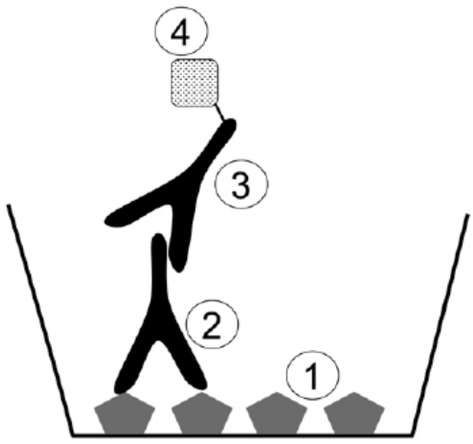

Fig. 6.3 Microbiology and Immunology Teaching Resources, University of Otago.

Part A: The Innate Response

There are many barriers that help to prevent organisms gaining access to the tissues. These include **physical barriers** (*e.g.* skin, or cilia in mucosal epithelium) and **chemical barriers** (*e.g.* fatty acids in sebum, lysozyme in tears, or acidity in stomach contents). When microbiological organisms penetrate these external barriers, several other internal defence mechanisms are activated.

Innate defence mechanisms are immediately mobilised by a microbial invasion. This is therefore a non-specific response, also referred to as innate resistance (*e.g.* **phagocytosis** - cell eating - of the invading **microbe**).

The **phagocyte** - most commonly a **neutrophil** or **macrophage** - first ingests the microbe. The microbe then becomes contained within the cell in a **phagosome**. A lysosome fuses with the phagosome, forming a **phagolysosome**.

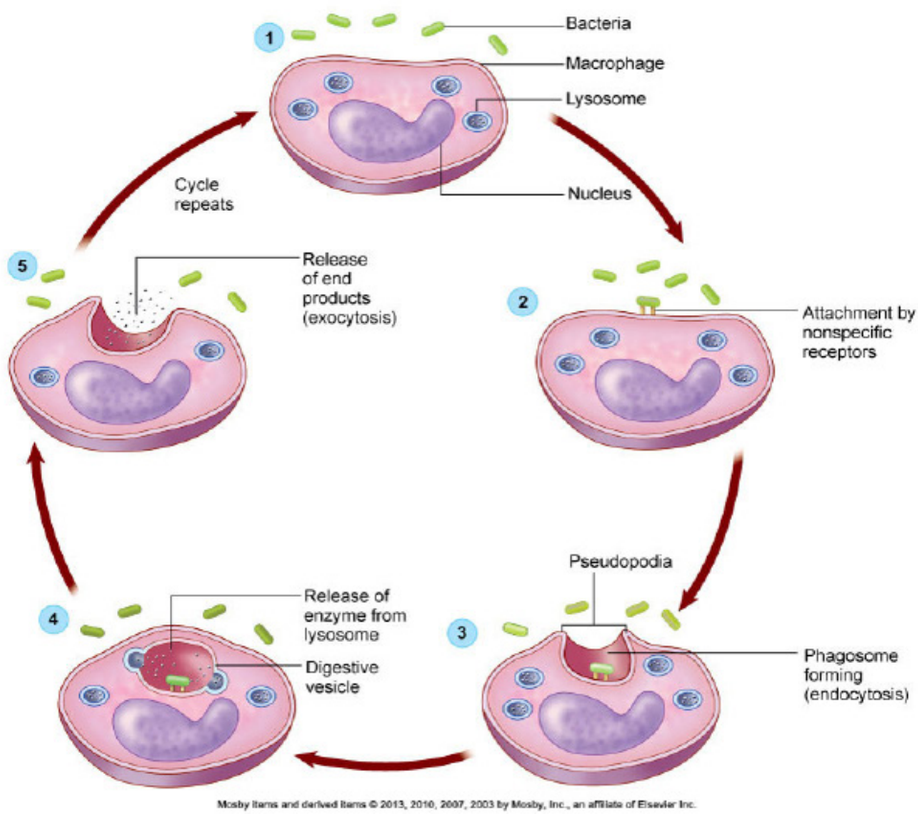

Fig. 6.4 Phagocytosis of bacteria (Fig. 24-7, Patton & Thibodeau, 8th Edn., pg. 752)

When the blood vessel walls become sticky to neutrophils, these cells adhere to the margins of the blood vessels. This process is called **margination**, a necessary step before the neutrophils can move into the surrounding infected tissue. The process of cells moving from the blood stream through the capillary wall into the tissues is called **diapedesis** (Fig. 6.1).

An increase in the number of neutrophils circulating in the blood is called **neutrophilia**.

Task A.1

Note the following points from the video:

- ☐ Molecules unique to prokaryotes are 'recognised' by host macrophages or dendritic cells.
- ☐ Monocytes in blood migrate into tissues to become macrophages.
- ☐ Macrophages are triggered to produce a variety of cytokines (messenger molecules) that trigger other cells. Cytokines also act at distant sites, *e.g.* hypothalamus.
- ☐ The liver produces haptoglobin (sequesters iron away from microbes) and fibrinogen (a clotting factor which 'walls off' microbes).

Looking at Leukocytes

When a blood specimen is taken from a patient many different tests can be carried out on it.

A test commonly applied is to count the number of leukocytes (white blood cells) and determine the relative proportions of the various leukocyte types. Normal values are given in Table 6.1.

Table 6.1: *Reference Values for Differential Counts in Healthy Adult Human Caucasian Subjects [Notice - for example - that you are very unlikely to see many basophils, probably none at all.]*

Cell type	***Range (%)***	***Range x*** 10^9/L
Neutrophils	40-75	2.0-7.5
Eosinophils	1-6	0.04-0.4
Basophils	<1	<0.01-0.1
Lymphocytes	20-45	1.5-4.0
Monocytes	2-10	0.2-0.8

In a person developing an infection, **neutrophils**, the leukocytes mainly responsible for phagocytosing bacteria, are recruited to the infection site. This means more are needed in the blood stream, so more neutrophils are released from the stores in the bone marrow. By looking at white cells in the blood stream we can gain an idea of what is happening in the patient. When the stored neutrophils flood into the blood stream, the increase in circulating neutrophil number is called **neutrophilia**.

In this exercise we are simply going to look at all the nucleated cells in the blood and determine how many of them are neutrophils.

HOW TO RECOGNISE NEUTROPHILS:

In some neutrophils the cytoplasmic granules are very small, in others somewhat larger, however, they are never as large or as dark as basophil granules, or as large and yellow/orange as eosinophil granules.

Refer to the *Blood Cell Picture* file on your computer.

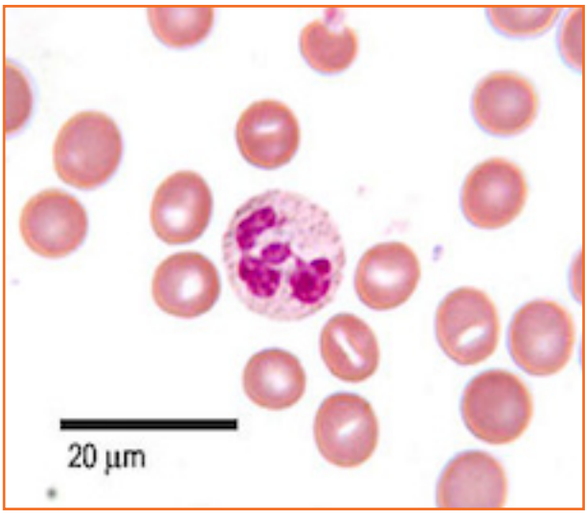

Fig. 6.5 Examples of neutrophils (Microbiology & Immunology Teaching Resource).

A) Neutrophil Numbers

Before you start counting, you should look at each film under the × 40 lens to get a general idea of the number of neutrophils present. This is a good time to consult with each other, and with your demonstrator, to make sure you can distinguish neutrophils from the other cells present.

You can use an insert for the eyepiece that will give you a square field of view of reduced size to make counting easier with the × 40 lens. Ask your demonstrator if you want one. If there is one in your microscope that you do not wish to use, ask your demonstrator to remove it.

1. Set up your microscope by focusing on the blood slide using the coarse focus and the × 10 objective.

2. Select an area of the blood film where you can see the white cells clearly (where they are not too numerous or distorted). Move to the × 20 then to the × 40 objective. Use fine focus (inner knob) for adjustment.

3. Count the total number of leukocytes (purple nuclei) in the field, and then count the number of neutrophils in the same field. Ideally you should have about 20-25 cells per field - many more than this will be difficult to count accurately.

4. Move the microscope stage slightly so that you are looking at a new field just next to the one you have counted. Repeat until you have counted between 60 and 100 cells in 5 fields. Enter these values in Table 6.2.

Table 6.2 *Results of Leukocyte differential count*

	Blood A		**Blood B**	
Field	**Total Leukocytes**	**Total Neutrophils**	**Total Leukocytes**	**Total Neutrophils**
1				
2				
3				
4				
5				
Total				
%				

In question 6.1 you are given the total white cell counts for each subject. Use these to calculate the number of neutrophils circulating in the blood from the percentage of neutrophils you have calculated in Table 6.2. For example, if the total number of leukocytes is 8.0×10^9/L, and 25% of them are neutrophils, then there are 2.0×10^9/L neutrophils.

Question A.1

Table 6.3 Number of Neutrophils

	Total Leukocytes *x 10^9/L*	**Neutrophils** *x 10^9/L*
Patient A	**5.0**	
Patient B	**14.0**	

B) Body Temperature Increase

An increased body temperature known as **pyrexia** has several effects that help in resisting microbial attack.

- The amount of available iron decreases with increased body temperature.
- Some leukocytes are more active between 38˚ and 40˚ C than at normal body temperature.
- The growth rate of some microbes is slowed.

Inspect the temperature charts provided, and answer the following questions. You may need to consult the glossary at the back of the manual.

Question A.2

Which patient has pyrexia (increased body temperature)?

Question A.3

Explain the mechanism by which the entry of bacteria into the system causes an increase in body temperature.

.

Part B: The Adaptive Immune Response

We have seen that when microbes gain entry into the tissues of the body the innate immune response attempts to destroy these organisms. Other sequences of events are also set in motion, including the activation of **T cells**, **B cells** and the formation of **antibody** as part of the **adaptive immune response**.

Whole microbes, or fragments of destroyed microbes (**antigens**), pass from the tissue into the lymph fluid draining into the nearby **lymph nodes**. Here, **T cells** and **B cells** are activated by the microbial antigens to produce an **adaptive immune response**.

Secondary lymphatic tissues *e.g.* **lymph nodes** provide an environment for the optimal interaction of antigen with B cells and T cells. Secondary lymphoid tissues include:

- **lymph nodes**, scattered throughout the lymphatic system.
- **the spleen**, located within the blood circulation that deals with any antigens that enter the blood stream.
- **mucosal lymphatic tissues** especially tonsils in the nasopharynx, and Peyer's patches in the intestine.

The lymphatic system has lymph nodes positioned strategically along it. It is in these lymph nodes that antigen, **antigen presenting cells (APC)** *e.g.* dendritic cells, together with B cells and T cells interact to begin producing antibody against antigens brought in via the lymph.

When antigenic material in the lymph enters the lymph node, APC phagocytose and break down the antigenic material, presenting it as peptides along with MHC-II on the surfaces of the macrophage. CD4 (helper) cells with receptors corresponding to these particular MHC-II/peptide combinations are then activated.

These activated CD4 T cells begin to release cytokines. These cytokines are one of the two triggers required to activate B cells to differentiate into **plasma cells** (antibody secreting B cells). The other signal is native antigen (unprocessed antigen) which triggers antigen-specific B cells. Only when both signals are present will the B cell become activated and undergo mitosis.

The secretion of antibody by plasma cells causes an increase in antibodies in the blood. These antibodies can then participate in **opsonisation**, **neutralisation** and activation of **complement**. In this laboratory, you will measure the amounts of antibody as an indication of activation of the adaptive immune response.

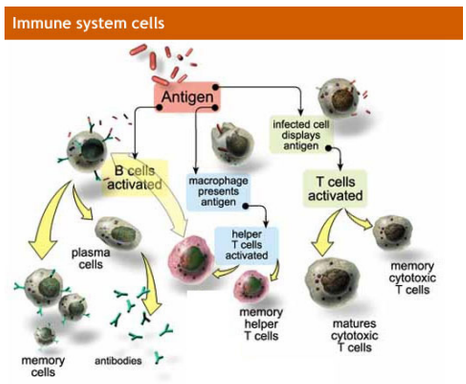

Fig. 6.6 Overview of the cells of the Immune System modified from the Human Immune Response System (www.uta.edu/chagas/images.ImmunSys.jpg).

Task B.1

Points from the video on antibody production to notice in particular are:

- ☐ Antigens from bacteria broken down in the APC are presented in association with MHC molecules on the cell surface.
- ☐ A CD4 T cell recognises the peptide/ MHC complex and begins to proliferate and secrete cytokines.
- ☐ The cytokines stimulate the B cell to divide. B cells must also become activated by binding native antigen.
- ☐ The B cells develop into antibody secreting plasma cells.
- ☐ The antibody enhances bacterial destruction by opsonising the bacteria, and by initiating bacterial lysis (with complement).

A) Antibody Detection

One of the patients presenting with the skin infection is now seriously ill, and further investigations are to be carried out. First you will test both patients for the presence of anti-staphylococcal antibody.

When an antibody is mixed with its corresponding antigen the reaction between the two molecules is often invisible to the naked eye. However, since antibodies are divalent (having two antigen binding 'arms') when the antigen is part of a large structure (red blood cells or bacteria, for example) the reaction may be made visible because the large structures clump together.

Several strategies have been developed to enable visualisation. You will see two such strategies widely used in diagnostic and research work: agglutination test, and the ELISA technique.

AGGLUTINATION TEST

In this technique small latex beads are coated with a staphylococcal antigen. When the corresponding antibody is added to a suspension of coated latex beads, each antibody molecule combines with more than one antigen molecule so that masses of latex beads become linked together in a readily visible agglutination reaction.

Procedure

1. Take a new (unused) glass slide. Using a marker pen divide the microscope slide into two halves.

2. Label the left half 'A' and the right half 'B'

3. Mix the latex suspension labelled 'coated latex' by inversion.

4. Place 25 µL of the mixed latex suspension near the centre of each of the two halves of the slide.

5. Close to the latex drop on the side marked 'A', but not touching it, place 25 µL of serum from patient A. Use the tube labelled patient A.

6. Similarly, put 25 µL of serum from patient B on the side marked 'B'. Use the tube labelled patient B.

7. Mix the two drops on each side using a clean pipettor tip for each, to give mixtures about the size of a 10 cent piece.

8. Rock the slide gently for two minutes and note agglutination against a dark background.

Table 6.4 Agglutination results

Results of Agglutination Test	
Patient A	
Patient B	

Put your results into the above table as positive (agglutination) or negative (no agglutination).

Dispose of your used slides in the YELLOW SHARPS bin on your bench.

ELISA

The agglutination test is a rapid method to demonstrate the presence of antibody. In order to quantify how much antibody is present, we will use the ELISA.

When an antibody is mixed with its corresponding antigen the reaction between the two molecules is often invisible to the naked eye. However, since antibodies are divalent (having 2 antigen binding 'arms') when the antigen is part of a large structure (*e.g.* red blood cells or bacteria) the reaction may be made visible because the large structures clump together or agglutinate.

In order to quantify how much antibody is present, we will use the ELISA.

'ELISA' is an acronym for 'Enzyme Linked Immuno Sorbent Assay'. You will look at its use in determining the amount of an antibody in patients' serum.

The intensity of colour produced is proportional to the amount of enzyme, and therefore to the amount of detector antibody present.

Procedure

Read the method carefully! ***It is suggested that you set up the ELISA test first***. You can then start the other procedures during the ELISA incubation steps.

You are provided with a set of three wells, for the ELISA. The wells have already been coated with antigen, then washed to remove excess antigen.

The three wells will be used as follows:

1	***2***	***3***
Saline Blank	***Patient A***	***Patient B***

You are provided with 3 tubes labeled **Saline Blank**, **Patient A**, and **Patient B**.

Label the three wells '**1**', '**2**' and '**3**'.

1. Use the 20-200 µL pipettor to pipette **50 µL** from each of these tubes into the appropriate well.

2. Cover the ELISA wells with the black plastic tray and leave for 30 minutes to allow time for any antibody to bind to the antigen in the wells.

3. Wash the wells 5 times with washing buffer, then blot. This will be demonstrated to you at the start of the practical.

4. Pipette **50 µL** of the detector antibody with enzyme attached to each of the 3 wells.

5. Leave for 20 minutes.

6. Wash the wells 5 times with washing buffer and then blot as above.

7. Add **100 µL** of the substrate solution (don't forget to reset your pipettor!) to each of the 3 wells. ***Wear a glove on the hand used to handle the substrate solution tube.***

8. Cover the wells again and leave for 20 minutes for the colour to develop.

9. Inspect the results after exactly 20 minutes.

Note down your assessment in the table below, using the following notation:

0	colour is no greater than saline blank
+	mild reaction
++	strong reaction
+++	very strong reaction

Table 6.5 ELISA results

Results of ELISA	
Patient A	
Patient B	

B) Effector Action: Phagocytic Activity and Opsonisation

Many cells in the body are able to bind to foreign particles and internalise them. As noted earlier this process is called **phagocytosis**. Phagocytosis is an innate property of these cells. Phagocytosis can be greatly enhanced if certain types of molecule attach to the microbes. This process is called **opsonisation**, and the various types of molecule that enhance phagocytosis in this way are collectively known as opsonins. One example of a specific opsonin is **antibody.** If antibody specific for some surface component of the microbe is present, these adhere to the microbe surface and increase the rate of phagocytosis.

Another example of an opsonin is the **complement** product **C3b**.

Complement can be activated by antibody bound to antigen (**classical pathway**) or by common microbial substances (**alternative pathway** or **lectin pathway**).

The classical pathway is the most effective way to produce complement products, including the opsonin C3b. This is due to the ability of antibody-antigen complexes (*via* **convertases**) to amplify early steps in complement activation.

Procedure

There are two 'phagocytosis' preparations for you to observe. These were prepared by adding 500 µL of a microbe suspension to 500 µL of a suspension of leukocytes. 100 µL of serum from patient 'A' was added to one tube, and 100 µL of serum from patient 'B' to the other. These mixtures were incubated at body temperature (37 °C) for one hour, then films for microscopic examination were prepared.

In one case, the serum contained antibodies that reacted with a surface component of the microbes, while the serum in the other case did not contain such an antibody.

Examine the two smears using the × 40 objective lens. Count 50 leukocytes, noting how many contain microbes.

Table 6.6 Number of Leukocytes containing microbes

	Patient A	***Patient B***
Number containing microbes	***/50***	***/50***
% Containing microbes		

Question B.1

Note the distinction between cells, such as neutrophils, and molecules such as antibody. Name two molecules of the innate immune response, along with their function and name the tissue or cells from which they originate

Question B.2

Which of the two patients investigated do you think most probably effectively opsonised the microbes?

Question B.3

Name two opsonins

Question B.4

Briefly outline the sequence of events in the innate immune response that occur immediately following skin infection. Include in your answer the role of local tissue reactions, the brain and the bone marrow.

C) Complement

Complement is a vital part of the body's immune system, provides a highly effective means for the destruction of invading microorganisms and for immune complex activation. Complement consists of a Series of 30 plasma (serum) proteins, activated in a cascade. There are 3 effects of this complement system activation:

1. Enhances inflammatory response, *e.g.* attracts phagocytes.
2. Increases phagocytosis through opsonization or immune adherence.
3. Creates Membrane Attack Complex (MAC) Cytolysis.

Question B.5

Describe the main ways that complement is activated.

Task B.2

Case Study

Open the folder entitled 'Lab 6 Case study' on your desktop and with the help of your demonstrator discuss the case paying particular attention to the following

1. What (if anything) is happening in the lymph nodes of the patient and what has caused this?

2. Are there any tests that could be used to detect the main products of these lymph node events and what are these tests?

3. Would complement have had a role to play in this case? – Give details.

4. Have B cells been activated in this case? If so what antigen activated these B cells?

5. Would a vaccine have been helpful in this case and, if so, how would it have worked? Include in your answer the characteristics of memory B cells that distinguish them from naive B cells and why the secondary antibody is faster than the primary antibody response.

Task B.3

Draw a diagram of an antibody molecule and describe how its structure relates to its function.

Glossary for HUBS 191

This glossary has been assembled as a guide appropriate to the first year Human Body Systems courses at Otago University. Terms are defined with respect to how they are used in this course. It is not intended to be an encyclopaedia or to replace a text book. Please refer to the laboratory manual, lecture notes or recommended reference texts if a fuller explanation is required.

abduction (ab-DUC-shun) The movement away from the median plane i.e. a lateral movement, opposite of adduction. This movement is in the coronal plane.

abscess (AB-sess) Latin: abscessus meaning "gone away' – presumably referring to the fate of the contents of an abscess. A cavity containing pus and surrounded by inflamed tissue, generally due to a local infection.

acetabulum (ASS-et-ab-u-lum) The large cup-shaped articular cavity, on each side of the pelvic girdle, into which the ball shaped head of the femur fits to form the hip joint. Latin: acetum = vinegar, used in the word 'acetabulum' meaning vinegar cup. The connection between acetum and acetic acid is easy to see.

acetylcholine (ASS-eh-tile-ko-leen) A chemical substance (neurotransmitter) released by some nerve endings, usually parasympathetic nerve endings.

Achilles tendon (or calcaneal tendon) The tendon attaching the triceps surae (calf muscles) to the calcaneus at the heel.

acquired resistance Resistance to microbial attack which develops as a response to exposure to the causative agent. If the same microbe enters the system at a later date, acquired immunity allows the body to mount a more rapid and generally more effective response. Contrast with 'innate'.

acronym A word made up of the initial letters of a set of other words, such as 'ELISA' for Enzyme Linked Immuno-Sorbent Assay.

action potential A self-propagating electrical impulse that occurs in excitable tissues that is characterised by a transient reversal in the membrane potential.

acute (a-KYOOT) Pertaining to a disease or illness with abrupt or sudden onset, intense symptoms, and short duration.

adaptation (ad-ap-TAY-shun) If a constant stimulus is applied to a sensor, the generation of sensory nerve impulses decreases. Sensors are effective at detecting changing rather than constant stimuli.

adduction (ad-DUC-shun) Movement towards the mid-line of the body. The reverse of abduction.

ADH abbreviation for antidiuretic hormone. A hormone formed in the hypothalamus, released by the pituitary gland in response to an increase in cerebrospinal fluid osmolarity. Promotes water retention by increasing the permeability of kidney distal tubule and collecting duct cells to water. Also known as vasopressin.

adipose A connective tissue consisting mainly of fat cells.

ADP Adenosine diphosphate.

adrenaline (ah-DREN-ah-lin) UK term, main hormone produced by the adrenal medulla. Also called epinephrine (USA).

adrenoceptor Receptors which interact with catecholamines. Can be classified as alpha or beta.

aerobic organism (air-OH-bic) Organisms which use oxygen as the terminal electron acceptor in the oxidation of energy-providing nutrients.

afferent lymphatic vessel (AFF-uh-rent) A vessel carrying lymph which is entering a lymph node. Contrast with 'efferent'.

affinity The strength of binding of one molecule to another at a single site, such as may occur between an antibody and the corresponding antigen.

agglutinate The visible aggregation (clumping) of antigen, or the action of forming such an aggregate.

agglutination (ah-GLUE-tih-na-shun) An antigen-antibody reaction in which an antigen forms a lattice with soluble antibody.

agonist A muscle when it is contracting concentrically to move a joint.

aldosterone (AL-DOSS-teh-rone) A steroid hormone secreted by the adrenal cortex that acts on the kidneys to promote sodium retention and potassium excretion.

allergen (AL-er-jen) An antigen which has the capacity to cause an allergy.

amino acids A group of molecules containing at least one carboxyl (acid) group and at least one amino group, which form the chief constituent of protein.

anaerobic (AN-err-OH-bic) Not utilising oxygen. Anaerobic metabolism uses an electron acceptor other than oxygen e.g. in mammalian muscle with an inadequate oxygen supply and in red blood cells, pyruvate accepts these electrons and is

converted to lactate.

analog signal a continuous electrical signal representing a specific condition, such as temperature, electrocardigram waveforms, telephones, or computer modems.

anaphylatoxin (AN-uh-fye-la-tox-sin) Any substance capable of triggering the release of substances from mast cells. For example, an anaphylotoxin may cause the release of histamine from mast cells in such quantity that the result is life-threatening. More usually, a small amount of substance is released, and contributes to a local inflammatory reaction.

anatomical position (an-a-TOM-i-kal) Standing upright, looking straight ahead with the palms of the hands facing forward and the feet together. The position of reference for all anatomical descriptions.

angiotensin II (AN-jee-oh-ten-sin) A vasocontrictor substance activated by renin; it triggers the release of aldosterone.

ankle (joint) A synovial hinge type joint, the articulation between the distal end of the tibia (medial) and fibula (lateral) with the talus.

antagonist (an-TAG-o-nist) A muscle that acts in opposition to an agonist.

anterior (ventral) (an-TER-e-or) Towards the front. Opposite of posterior.

anterior horn (anterior gray horn or anterior gray column) When referring to the spinal cord, the anterior horn is the anterior section of gray matter. Note that the anterior horn can also refer to a part of the lateral ventricle of the brain

antibiotic susceptibility (an-tee-by-OT-ic) A test used to determine how effective a particular antibiotic is at killing or preventing the growth of a bacterial strain.

antibody A glycoprotein produced in response to stimulation with antigen. Antibody combines specifically with the antigen which stimulated its production. Antibody is also known as immunoglobulin.

anticoagulant (AN-tee-co-AG-you-lent) A chemical substance that opposes blood clotting.

anti-diuretic hormone (ADH) A hormone formed in the hypothalamus, released by the pituitary gland in response to an increase in cerebrospinal fluid osmolarity. Promotes water retention by increasing the permeability of kidney distal tubule and collecting duct cells to water. Also known as vasopressin.

antigen (AN-tih-jen) A substance to which immune cells respond. When an antigen induces immune activation it is termed an immunogen.

antigen presenting cell (APC) A cell capable of presenting antigen with MHCII molecules to Th cells, an essential step in stimulating T cell proliferation.

anti-human globulin An antibody from another animal species which specifically binds to any human antibody taken from a human sample.

anti-immunoglobulin An antibody directed against immunoglobulin.

apoptosis (AP-oh-TOE-sis) Programmed cell death; the normal death of cells that have completed their function. Compare necrosis.

appendicular skeleton (AP-en-dic-you-lur) The skeleton of the appendages (limbs).

arachnoid (ah-RAK-noyd) weblike; particularly the middle layer of the meninges

arm The part of the upper limb between the shoulder and elbow joints.

artery (AR-ter-ee) A large blood vessel which carries blood away from the heart.

articular cartilage (ar-TIK-you-lar) A type of hyaline cartilage that covers the articulating surfaces of bones within synovial joints.

articular surfaces (ar-TIK-you-lar) The surfaces in contact with each other at a joint.

articulated Joined together, usually of the bones of the skeleton.

articulation (ar-TIK-you-lay-shun) Joint between bones.

aspirate To withdraw fluid or air. Usually uses some form of suction apparatus.

ATP Adenosine triphosphate, organic molecule that stores and releases chemical energy for use in body cells.

autonomic motor neuron (AW-toe-NOM-ic) A motor neuron which conducts impulses from the brain or spinal cord to organs, smooth muscles and glands. These nerve cells can be either sympathetic or parasympathetic.

axial skeleton (AC-see-ul) The bones of the main axis of the body : cranium, spinal column and thorax.

axilla (AK-sill-ah) Armpit, or related to the armpit eg. axillary lymph nodes.

axon Neural process that carries impulses away from the nerve cell body; efferent processes; the conducting portion of a nerve cell.

B lymphocytes (B cells) Lymphocytes derived from bone marrow which develop into antibody-producing plasma cells following activation by antigen.

bactericidal Destructive to bacteria.

bacteriostatic Tending to restrain the development or the reproduction of bacteria.

ball and socket (joint) A synovial joint in which the ball shaped head of a bone articulates in a cup-shaped cavity, the socket. The arrangement allows the distal bone to move around in a number of axes i.e. to allow flexion, extension, abduction, adduction and rotation.

base *Anat*. The end of some long bones, opposite to the head. Also, the other end from the apex (base of the heart). *Chem*. A chemical compound that can combine with an acid to form a salt.

basal ganglia (BAY-sal GANG-glee-ah) Regions of grey matter located in the cerebrum of the brain that are responsible for automatic movements and postures; now known more properly as **basal nuclei.**

basophil (BAY-so-fill) A white blood cell of the granulocyte group whose relatively large granules stain a purple-black colour with standard blood stains. The granules are stained with the basic (blue) component of these dyes so intensely that they appear almost black. Basophils contain several subtances released in response to injury and infection, being very similar to mast cells in make-up.

biceps (BYE-seps) Two-headed, usually applied to certain muscles.

biceps brachii (BRAY-kee-eye) The best known muscle of the upper limb - on the anterior aspect of the arm. It is a powerful flexor of the elbow, and an important supinator of the forearm.

biceps femoris (FEM-or-iss) One of the hamstring muscles. Biceps femoris has two heads, one arising from the ischium of the pelvic bone and the other from the middle part of the shaft of the femur. Both heads merge into a tendon which is attached to the lateral side of the fibula. Along with the semitendinosus and semimembranosus muscles, biceps femoris plays a part in: knee flexion, knee rotation (in semiflexion) and hip extension.

biological rhythms Cyclical changes in the biochemical and physiological processes of living things. More strictly, variations in the set point of controlled variables at differing times to best match them to the needs of the organism.

bone A type of connective tissue characterised by hardness due to calcium salts.

bone marrow Specialised soft tissue which fills the marrow cavity of bones. It is the site of the production and maturation of red cells, white cells, and platelets in adult humans. Stem cells are also produced in bone marrow, and it is the site of a number of other immunologically significant activities, including a significant amount of antibody production.

bradycardia (bray-dee-CAR-dee-uh) Slow heart rate; clinically, a heart rate below 60 bpm.

brainstem Part of brain containing the midbrain, pons, and medulla oblongata.

'bulk-flow' The movement of large volumes of blood around the circulation.

bursa (BUR-sa) A fibrous sac lined with synovial membrane and containing synovial fluid which acts as a cushion where soft tissues rub on bone. Examples are bursae between certain tendons and bones beneath the tendons, allowing the tendon to move over the bone as the muscle contracts and relaxes. [Plural = bursae]

calcaneus (cal-CAY-nee-us) The largest tarsal bone, it forms the heel of the foot. A short bone.

callus A cartilaginous mass formed in the gap between the ends of fractured bone during healing.

canaliculus (CAN-uh-LIC-you-lus) Microscopic channels such as those in bone that connect lacunae. [Plural = canaliculi] Latin: tiny canals.

cancellous bone (KAN-sel-us) Cancellous or cancelli is Latin for lattice-work, and it is easy to see why this word was used to describe the mesh-like structure of cancellous bone. Spongy or trabeculated bone found inside most bones.

capsule *Anat* A fibrous, membranous, fatty or cartilaginous structure surrounding another structure. *Micro* A virulence factor; carbohydrate layer on some extracellular bacteria which inhibits phagocytosis.

capsular ligament A ligament that is part of the capsule surrounding a joint

cardiac muscle Specialised muscle cells of the heart. Also called myocardium (myo = muscle; cardium = heart).

carpal bones The bones of the wrist. Short bones.

cartilage A non-vascular type of connective tissue, composed of chondrocytes and protein fibres embedded in a ground substance.

cartilaginous joints (kar-ti-LAJ-i-nus) The tissue between bones, e.g. intervertebral discs. This type of joint allows limited movement only.

cauda equina (KAW-dah eh-KWINE-ah) "horse's tail"; lower end of spinal cord with its attached spinal nerve roots

cellular fluid That portion of body fluid which is located inside body cells. Also called intracellular fluid.

central canals The channels in compact bone for blood vessels and nerves. Also called Haversian canals.

central nervous system (CNS) One of the two main divisions of the nervous system, consists of the brain and spinal cord. The other main division is the peripheral nervous system (PNS).

centrifugation A process for applying an acceleration, greater than gravity, to particles in a liquid suspension. Particles sediment at rates dependent on their size, density, shape and friction and can be separated by adjusting the conditions.

cephale (sef-AH-lee) Greek: head, hence 'biceps' means two heads.

cerebellum (sair-eh-BELL-um) second largest part of the human brain; plays an essential role in the production of normal movements

cerebrospinal fluid (CSF) (seh-ree-broh-SPY-nal) plasma-like fluid that fills the subarachnoid space in the CNS (brain, spinal cord and in the cerebral ventricles).

cerebrum (seh-REE-brum) largest region and major part of the human brain. Controls consciousness, memory, sensations, emotions, and voluntary movements in the body.

cervical (SUR-vih-cul) Of or pertaining to the region of the neck (or a constricted part of an organ e.g. cervix of the uterus).

chemotaxis (KEM-oh-TAC-sis) The movement of a cell along a chemical gradient, especially the attraction of neutrophils to chemicals released by pathogens or inflamed tissues.

chondrocyte (CON-dro-site) A cartilage cell; a former chrondroblast that has become enclosed in a lacuna in the cartilage matrix.

choroid plexus (KOH-royd PLEK-sus) specialised group of capillaries in ventricles of the brain that secrete cerebrospinal fluid (CSF).

chronic (KRON-ic) Pertaining to a disease or illness that progresses slowly and has a long duration.

circumduction (sur-kum-DUK-shun) The circular movement of a limb (or of the eye) produced by a combination of abduction, adduction, extension and flexion. Circumduction should be distinguished from rotation which is turning around central axis.

clavicle (KLAV-i-kul) Collar bone. A flat bone.

coagulation (co-AG-you-LAY-shun) A cascade of enzyme reactions terminating in clot formation. One trigger is tissue damage, another is contact with certain types of surface, such as glass. The end result is polymers of the protein fibrin, formed by enzyme activity of the precursor protein fibrinogen. Calcium ions are a cofactor for some of the enzymic steps.

coccyx (KOK-six) The tail bone, attached to the sacrum. A short bone.

collateral ligaments Ligaments on either side of a joint, notably those supporting the medial and lateral sides of the knee, elbow, wrist and ankle joints.

compact bone Bone with a dense structure compared to cancellous (spongy) bone. Also known as cortical bone. Forms the outside of most bones.

complement (KOM-ple-ment) A group of plasma proteins which interact in a cascade to amplify inflammatory cell responses.

concentric action When a muscle develops sufficient tension to overcome resistance, so that it shortens (contracts towards its centre) and moves a body part.

condylar Pertaining to a condyle. Sometimes used to describe articulations which involve condyles e.g. the knee joint is a condylar joint.

condyle (CON-dile) A rounded process at the end of a long bone. Greek: condylos, meaning 'knob', and is generally applied to certain projections on bone.

conduction When heat or current is transvered directly between materials due to their being a difference in heat or charge.

conjugate (KON-ju-git) One organic compound bound to another compound of a different class. A conjugate vaccine is made from capsular polysaccharides bound to proteins of known immunogenicity e.g. tetanus toxoid.

connective tissue Tissue that supports and binds other body tissue and parts. Bone, cartilage and fibrous tissue are examples. Characteristically connective tissue contains few cells with a large amount of material between the cells. This intercellular material is made up of fibres in a matrix or ground substance that may be solid (as in bone), gelatinous or liquid. Many consistencies of connective tissue are possible depending on the location requirements.

controlled variable generally considered as any one of the many factors or substances in the body whose level is kept within a certain range e.g. body temp, pH, BP, etc. However, this term may sometimes be reserved for variables that can be changed by the system but for which specific sensors do not exist. For example, heart rate is controlled but there are no known sensors in the body that monitor it. HR is controlled in order to regulate blood pressure which is monitored by baroreceptors.

convection When a material (gas, liquid, *etc.*) warms up, becomes less dense and rises, whilst cooler (thus denser) materials sink/replace the space left by the material that has risen. Wind is caused by this process of warm air rising and cooler air coming in due to a decreased pressure in that region. This process requires energy.

core temperature The temperature of blood perfusing brain and organs of chest and abdomen. Contrast with peripheral temperature, which is more variable.

corpus callosum (KOHR-pus kah-LOH-sum) Nerve tissue connecting the right and left cerebral hemispheres.

coronal (ko-RO-nal) The plane running vertically through the body separating it into anterior (front) and posterior (back) parts.

cortex (KOR-teks) An outer layer of a structure.

cortical Pertaining to the cortex. (Cortex comes from the Latin for 'bark' as in bark of trees, not of dogs!)

corticolspinal tract Refer to Pyramidal tract.

costal – relating to the ribs

cranium (CRAY-nee-um) The part of the skull encasing the brain.

cruciate ligaments (CROO-she-ate) Ligaments found deep within the knee joint, so named because they cross over each other. Also, called intracapsular ligaments.

CSF *Physiol/Anat.* abbreviation for Cerebro-spinal fluid. CSF is continually secreted to provide a fluid surrounding the brain and spinal cord. (*Immunol.* Colony stimulating factor - not dealt with in 191).

culture When incubated with nutrients over a given period of time, the resultant bacterial growth is called a culture.

-cyte Cell; from the Greek, cytos.

cytokines (SY-toe-kines) Hormone-like peptides produced by immune cells or phagocytes after interaction with antigens. Cytokines produced by lymphocytes are called lymphokines. Cytokines regulate the function of other cells in the local environment.

cytoplasm (SYE-toh-plaz-em) Gel-like substance of a cell exclusive of the nucleus and plasma membrane; includes organelles (except nucleus) and cytosol (intracellular fluid)

cytosol (SY-toe-sol) The fluid and semifluid matrix of the cytoplasm in which the organelles of the cell are suspended.

deep In gross anatomy, used to describe structures further from the surface. Opposite of superficial.

delayed type hypersensitivity (DTH) A cell mediated immune reaction characterised by cellular infiltrate and oedema developing 24 to 48 hours after antigenic exposure.

deltoid A powerful abductor muscle of the shoulder. It attaches from the pectoral girdle to the shaft of the humerus, forming the roundness of the lateral aspect of the shoulder.

dendrite Processes of a neuron that receive information from other cells or environmental stimuli, and conduct signals towards the nerve cell body.

dense fibrous connective tissue (DFCT) DFCT contains compact, strong, inelastic bundles of collagenous fibres arranged in parallel. DFCT has a glistening white appearance. It is found in tendons, ligaments, capsules and periosteum and is able to withstand tension. (See also 'connective tissue').

depolarisation To change membrane potential value towards zero so that the cell interior becomes less negative than the resting potential.

diapedesis (DY-uh-peh-DEE-sis) The movement of leucocytes through intact blood vessel walls, generally into tissue e.g. neutrophils move from capillaries to tissues by diapedesis to reach micro-organisms in the tissue.

diffuse lymphatic tissue Immune cells found in areas of tissue that are not specific lymphatic organs. It is commonly called extralymphatic tissue and can be found in any tissues of the body, most commonly in the gut or mucosal surfaces.

digital signal The characterisation or measurement of a signal in terms of a series of numbers rather than some continuously varying value.

diluent Substance used to dilute another substance. E.g. serum might be diluted in a test tube with saline to one tenth of its original strength. The saline is acting as a diluent.

disarticulated Not joined together – term used when the bones of the skeleton are taken apart.

dislocated Articular surfaces of a joint no longer in contact with each other. Usually due to trauma.

distal Further from the trunk, in relation to the anatomical position. Opposite of proximal.

dorsal See posterior.

dorsiflexion (DOR-sih-FLEC-shun) The movement of the ankle as the dorsum of the foot is elevated. Opposite of plantarflexion.

dorsum Back of hand or upper surface of foot.

double stance phase The phase in walking when both feet are on the ground.

DTH Delayed Type Hypersensitivity.

dura mater (DOO-rah MAH-ter) literally "strong" or "hard mother"; outermost layer of the meninges

eccentric action (EE-sen-tric) When resistance overcomes muscle tension so that the muscle lengthens (extends away from its centre). It therefore helps to control the movement of a body part, e.g. when lowering a heavy container of liquid onto a table, biceps brachii acts eccentrically to control the force of gravity acting on the limb during the extension of the elbow joint.

ECF Extracellular fluid.

effectors (e-FEK-torz) Biological devices that correct deviation of controlled variables to return them to the set point.

efferent lymphatic vessel (EFF-ur-unt) A vessel carrying lymph which is leaving a lymph node. Contrast with 'afferent'.

elbow (joint) Hinged articulation of the humerus with the ulna. This joint allows forearm flexion and extension.

electromyogram (EMG) The recording of a muscle's electrical activity obtained by placing recording electrodes over the muscle of interest.

electrophoresis Migration of a charged particle such as a protein in an electric field.

ELISA Enzyme Linked ImmunoSorbent Assay. An immunoreactant substance (antigen or antibody) labelled with enzyme is allowed to react with another immunoreactant substance bound to a solid support, such as the plastic wall of a test tray.

ellipsoid (e-LIP-soyd) Oval shape. Applies to a type of synovial joint, e.g. the wrist. Ellipsoid joints cannot rotate, but can move in all other directions.

encephalitis (en-seh-fal-EYE-tus) An inflammatory condition of the brain. The cause is generally a virus infection and the symptoms are headache, neck pain, fever, nausea and vomiting.

endo- Inside.

endogenous (en-DODJ-en-us) In connection with antigen presentation, the presentation of antigen from inside the cell, as in viruses and MHC class I.

endomitosis Division of the nucleus of a cell without dissolution of the nuclear membrane or division of the cytoplasm, leading to doubling of the number of chromosomes within the nucleus.

endomysium A layer of connective tissue that surrounds each muscle fibre, allowing blood capillaries and nerve fibres to reach each muscle fibre.

endoneurium (en-doh-NOO-ree-um) Thin wrapping of fibrous connective tissue that surrounds each axon in a nerve

endosteum Thin connective tissue which lines the inside of the marrow cavity.

eosinophil (EE-oh-SIN-oh-fill) A white blood cell of the granulocyte group whose relatively large granules stain a yellow/orange colour with standard blood stains. The granules are stained by the eosin component of these dyes, hence the name. The number circulating in the blood is increased in allergic conditions and parasitic worm infestations, and decreased in infection and during steroid administration.

epi- Outside, above.

epicondyle A projection outside a condyle e.g. the medial epicondyle of the femur.

epimysium A layer of connective tissue that covers the entire muscle as a whole. The epimysium plays an important role in attachment of muscle to bone.

epineurium (ep-i-NOO-ree-um) Tough fibrous sheath that covers the whole nerve.

epitope An epitope is the small part of the antigen molecule that is immunogenic; it is the part to which antibodies or activated lymphocytes can bind.

Eppendorf (microcentrifuge) tube A small tapered plastic tube holding approximately 1.5 mL of fluid, suitable for centrifugation at moderate speed.

erythrocytes (eh-RITH-ro-site) Red blood cells (RBCs) disc shaped cells about 7 μm (microns) in diameter in humans, which have no nucleus and contain the respiratory pigment haemoglobin.

evaporation The changing of a liquid into a gas often due to an increase in temperature. This process requires energy.

eversion (e-VER-shun) Movement at the joints of the foot so the sole faces laterally.

exogenous (ec-SODJ-eh-nus) In connection with antigen presentation, the presentation of antigen from outside the cell, as in bacteria and MHC class II.

extension (ek-STEN-shun) The reverse of flexion at a joint, usually straightening of a flexed joint. See flexion.

external environment The environment is all of the physical and psychological factors that affect the life and survival of the individual. The external environment is those factors which exist outside the body of the individual.

extra- Outside, beyond, in addition to.

extracellular fluid (ECF) That portion of body fluid located outside cells, this includes plasma and interstitial fluid.

extravasation Discharge or escape of a substance from a blood vessel.

extrinsic (ec-STRIN-sic) Something external or outside. Opposite of intrinsic e.g. the extrinsic muscles of the fingers are outside the hand, connected by long tendons.

Fab Antigen binding site of the antibody molecule. This consists of a heavy chain and light chain of the antibody molecule.

fasciculi (fass-IH-cul-us) Small bundles of muscle fibres visible to the naked eye.

Fc 'Fraction crystalline' so named because it is the crystallisable part of the immunoglobulin molecule after enzymic digestion, as used in the discovery of immunoglobulin structure. The Fc portion is at the C-terminal part of the heavy chains and is involved in binding to Fc receptors on certain cells.

feedback control Adjusting the controlled variable back to the set point by monitoring the situation relative to the controlled variable. Contrast with 'feedforward control'.

feedforward control Predicting situations which would tend to deviate a controlled variable from its set point and taking action to reduce or prevent that deviation e.g. observing frost outside and putting on a coat before stepping into the cold.

femoral condyles The condyles (one lateral, one medial) at the distal end of the femur which articulate with the tibia to form the knee joint.

femur The bone of the thigh (between the hip and the knee joints). Latin: thigh. A long bone.

fibrinogen (FY-brin-oh-gin) A protein found in blood plasma involved in blood coagulation, primarily produced in the liver. Fibrinogen is converted to fibrin by the enzyme thrombin. The fibrin molecules polymerise to form long strands. It is laid down around sites of inflammation, apparently helping to prevent the spread of infection. The rate of synthesis increases in infection.

fibrocartilage A type of cartilage, dense matrix of collagen fibres, found as the intervertebral discs and the menisci (in the knee).

fibrous joints (FY-brus) The tissue between the bone ends forming the joint is dense fibrous connective tissue. Such joints allow very little or no movement, e.g. skull sutures.

fibula The slender bone on the lateral side of the leg (beside the tibia). A long bone.

flat bones These are thin, flattened and usually curved e.g. the sternum (breast bone), scapula (shoulder blade).

flexion (flec-shun) Bending of a joint usually so that the fleshy surfaces of the limb come into contact. Flexion is the opposite of extension.

flight phase One of the phases of running - when both feet are off the ground.

follicle (FOLL-ih-cul) In lymph nodes, a collection of lymphocytes. See also primary and secondary follicles. The word "follicle" is derived from the Latin word for a small bag – folliculus.

fontanelle These are areas between the unfused cranial bones, filled with DFCT. Pulsation of an infant's pulse can be felt at the fontanelles.

foot The part of the lower limb, distal to the ankle joint. It consists of 26 bones: 7 tarsals, 5 metatarsals and 14 phalanges.

foramen (fo-RAY-men) An opening, usually in a bone, for blood vessels and/or nerves. [Plural - foramina]

forearm The part of the upper limb between elbow and wrist.

fracture (FRAK-cher) A break in a bone.

frequency modulation In neural signalling, the change in frequency of nerve impulse generation in a given axon as the stimulus strength changes.

gait The manner or pattern of walking.

gap junction A junction between two cells - a pore surrounded by a ring of proteins in the plasma membrane of each cell - allowing diffusion of substances from one cell to another.

gastrocnemius (gas-trok-NEE-me-us) The large superficial two headed muscle of the leg (calf) which forms the triceps surae along with the deeper soleus muscle. A powerful plantarflexor of the ankle joint, also involved in knee flexion.

gastrointestinal tract The continuous digestive system from stomach through to sigmoid colon.

gelatin A tasteless, colourless or yellowish water-soluble protein derived from collagen prepared by boiling animal hides and bones.

germinal centre A relatively pale-coloured region in lymph nodes consisting of dividing cells, following antigen stimulation of a primary follicle.

glenoid cavity (gle'noid) Cavity of the scapula that articulates with the humerus, forming the shoulder joint.

globulin (GLOB-you-lin) Globular proteins such as an antibody that migrate together in electrophoresis of serum.

glucose phosphate A compound formed in the first step of glycolysis involving the utilisation of an ATP molecule (yielding glucose-6-phosphate and ADP). (Glucose-1-phosphate is another glucose phosphate, not dealt with in HUBS 191).

gluteus maximus (GLOO-tee-us) The buttock muscle, important in the bipedal stance and in locomotion, and is a powerful extensor of the hip joint.

gyrus (JYE-rus) Convoluted ridge, usually refers to rounded elevations of the brain surface.

glycogen (GLY-co-jen) A polysaccharide that is the main storage form of glucose in animals.

goblet cell A mucus-secreting cell (in cross section the interior mucus secreting part resembles a wine goblet).

graded potential Local potentials that vary according to the strength of stimulus and distance on membrane from the source.

Gram stain of colony The Gram Stain is performed on the cell wall of a bacterial colony. It involves a process of dyes which differentiate the bacteria into two groups, namely Gram positive and Gram negative. The make up of the cell wall determines which colour the bacteria will stain. (If the cell wall stains pink the bacteria are classified as Gram negative and if the cell wall stains purple the bacteria are classified as Gram positive.)

granulocyte (GRAN-you-lo-site) Blood cells with large numbers of granules in their cytoplasm, namely eosinophils, basophils and neutrophils.

grey matter (gray MAT-ter) Type of nerve tissue characterised by a relative lack of myelin and often including many neuron cell bodies and synapses that process information; contrast with white matter

gross anatomy The study of structures visible to the unaided human eye.

haemoglobin (HE-mo-GLO-bin) An iron-containing protein on RBCs which transports the bulk of the oxygen carried in the blood.

haemostasis (HE-mo-STAY-sis) Physiological mechanisms for prevention of blood loss.

hamstrings A group of three muscles in the posterior region of the thigh. Powerful flexors of the knee, they also extend the hip joint. Consists of semitendinosus, semimembranosus and biceps femoris.

hand The part of the upper limb distal to the wrist joint. It consists of 27 bones: 8 carpals, 5 metacarpals and 14 phalanges.

haptoglobin A protein found in plasma, manufactured primarily in the liver. Haptoglobin combines with haemoglobin, making the iron in haem unavailable to bacteria. The rate of haptoglobin synthesis increases in infection.

Hassall bodies Whorls (swirls) of degenerate epithelial cells of unknown function found in thymic tissue.

Haversian canals Name sometimes given to the central canals of bone.

Hb A commonly used abbreviation for 'haemoglobin'.

head One end of a long bone is often termed the head. Identified by its relatively round shape compared with the other end. Also used for the proximal attachments of a muscle when there is more than one, e.g. biceps (two heads), triceps (three).

heel-strike A phase in walking at the end of the swing phase. It is the point when the heel initially strikes the ground.

hemisphere (HEM-iss-feer) one half of a generally spherical structure, as in the left and right hemispheres of the cerebellum or cerebrum

hertz The unit of measurement of frequency. It is equivalent to one cycle per second.

heterogenous (HET-er-oh-gen-us) **1**. having a non-uniform composition throughout. **2**. derived or developed from another source or from two different sources

Hg symbol for the element of **mercury**.

hilum (HY-lum) Common term for a depression or pit at the part of an organ at which the blood vessels and nerves enter and exits. Also called 'hilus'.

hinge A type of synovial joint allowing movement about one axis only, e.g. the ankle joint which allows only plantarflexion and dorsiflexion.

hip (joint) The articulation of the rounded head of the femur in the cup-shaped acetabulum of the pelvic bone. This 'ball and socket' joint, supported by powerful ligaments, allows a wide range of movements: flexion, extension, adduction, abduction (and therefore circumduction) plus rotation.

histamine (HISS-ta-meen) A substance found in high concentration in the granules of mast cells and basophils. It is released in inflammatory and allergic reactions, causing a variety of effects including dilation of blood capillaries and contraction of smooth muscle of the respiratory tract.

histology (his-TOL-o-gee) The study of the microscopic structure of tissues.

homeostasis (HO-me-oh-STAY-sis) The maintenance of the internal environment of the body within a set range, essential for the optimal functioning of the body cells and tissues e.g. the pH of plasma is maintained within the range 7.35 to 7.45.

hook grip A grip formed by flexion of the fingers but not thumb or hand - as when carrying a suitcase.

host The organism that is the target of the pathogen or microorganism.

humerus The bone of the arm that is between shoulder and elbow joint. A long bone.

humoral immunity Immunity mediated by soluble proteins (antibodies) found circulating in plasma, lymph or in mucous secretions.

humors Fluids of the body.

hyaline cartilage A type of cartilage, very smooth, found on the articular surfaces of bones at synovial joints (where it is called articular cartilage) and in the nose and trachea.

hyper- Above, above normal, excessive.

hyperextension Extension beyond the anatomical position.

hyperglycemia (HY-pur-gly-see-me-uh) An excess of glucose in the blood.

hyperosmotic (solution) A solution having an osmolarity greater than that of the cells suspended in the solution.

hyperthermia (HY-pur-THUR-me-uh) Excessively high core body temperature; as in heatstroke or fever.

hypo- Below, below normal, deficient.

hypo-osmotic A solution that has a lower solute concentration than another solution.

hypothalamus (HY-po-THAL-uh-mus) Part of the brain at the base of the cerebrum with many functions in homeostatic control, including temperature regulation and control of pituitary hormones.

hypothermia (HY-po-THUR-me-uh) A state of abnormally low core body temperature.

Ig Abbreviation for 'immunoglobulin' or antibody.

IgE The class of immunoglobulin involved in allergic reactions and expelling surface parasites. It is located on the surface membranes of mast cells, basophils and platelets. Activation of IgE by combination with allergen, results in release of vasoactive amines such as histamine into the system.

iliopsoas (ill-ee-oh-SO-us) A powerful hip flexor muscle located deep on the anterior aspect of the hip joint.

immediate type hypersensitivity (ITH) An immune reaction to antigen which occurs very rapidly after antigen has combined with antibody.

immune Protected against a particular disease by specific cellular or antibody mediated defences.

immune response The response following contact with antigen that causes antibody production or activation of lymphocytes.

immunoglobulin (IM-you-no-GLOB-you-lin) Immunoglobulins are globulins which have an immune function, namely antibodies. There are five structurally distinct classes, IgA, IgD, IgE, IgG and IgM. See also 'globulin'.

in vitro (in VEE-tro) Usually refers to experiments done on tissues or cells in culture vessels e.g. flasks or plates. Latin: "In Glass".

in vivo (in VEE-vo) Inside the body.

indurated 'durus' is Latin for hard – used in 'durable' meaning hard-wearing, for example.

induration (IND-your-ay-shun) Hardening of a tissue. Used particularly in relation to the skin when the hardening may be due to infiltration by cells.

infection (IN-fect-shun) The invasion of the body by pathogenic microorganisms that reproduce and multiply.

inferior Towards the feet. Opposite of superior.

inflammation (IN-fluh-MAY-shun) A localised cellular response to injury, tissue destruction or infection. Acute inflammation (rapid onset, short course, pronounced symptoms) is characterised by pain (dolor), heat (calor), redness (rubor) and swelling (tumor).

inguinal (in-GWY-nal) Of or pertaining to the groin area, e.g. the inguinal lymph nodes.

innate Inborn, hereditary. Contrast with 'acquired'.

inter- Among, between.

interferons (IN-tur-fear-ons) Proteins made by cells in response to virus infections, these proteins being capable of protecting non-infected cells from viral attack.

interleukin (IN-tur-LOO-kin) Cytokines produced by macrophages and lymphocytes which regulate the growth and differentiation of other leucocytes.

internal anatomy The study, classification and description of the interior of the body. Contrast with surface anatomy.

interneuron In a three neuron reflex arc, nerve cell that conducts impulses from a sensory neuron to a motor neuron.

interstitial fluid (IN-tur-STISH-ul) (ISF) That part of body fluid that is in the interstices of tissue, i.e. between the spaces in a tissue or structure.

intervertebral disc Made of fibrocartilage with a central pulp-like area, found between vertebrae in the spinal column.

intra- within, inside.

intrinsic (in-TRIN-sic) Situated within a part of the body. Opposite of extrinsic, e.g. intrinsic muscles of the hand are in the hand itself.

inversion (in-VUR-shun) Movement of the joints of the foot so the sole faces medially.

ion(s) An atom or group of atoms having a positive (cation) or negative (anion) electric charge. Cations are positive due to losing an electron, anions negative due to gaining an electron.

irregular bone A bone that fits none of the other categories (i.e. long, flat, short) e.g. the pelvic bone, the vertebrae.

ischial (ISH-ee-ul) To do with the ischium - the inferior part of the pelvic bone. As in ischial tuberosities on which we sit.

iso- Same, equal.

isometric action (eye-so-MET-ric) When a muscle develops tension that is insufficient to move a body part against resistance so that the muscle does not change its length (iso = same; metric = length). An example is when trying to lift an impossibly heavy object, biceps brachii is acting isometrically in trying to flex the elbow against the resistance.

iso-osmotic (isosmotic) Having the same osmotic pressure as the intracellular and extracellular fluids.

ITH Immediate Type Hypersensitivity.

knee (joint) The synovial condylar articulation of the distal end of the femur with the proximal end of the tibia, together with the articulation of the patella and the femur. This joint allows flexion and extension and, when semiflexed, rotation.

lacuna (la-CUE-nuh) Latin for pool or hollow. The English word 'lake' comes from the same source.

lacunae (la-CUE-nee) Microscopic spaces in bone and cartilage in which cells are found.

lamellae (la-MELL-ee) Thin rings of compact bone, between which are found the lacunae.

latency (lay-ten-see) The interval between a stimulus and a response, especially in the action of nerve and muscle cells.

lateral Away from the median plane. Opposite of medial.

latex In immunology, latex particles to which antigen has been attached enable visualisation of a reaction of that antigen with the appropriate antibody.

leg The part of the lower limb between the knee and ankle joints.

leuko (LOO-co) Greek: white, while albus is Latin for white. So we have the words albino and albumin, but also leucocyte, etc.

leucocydin (LOO-co-SI-din) A potent toxin produced by *Staphylococcus aureus* that destroys phagocytes (leucocytes) allowing infection to become established in wounds or within hair follicles e.g. pimples.

leucocyte (LOO-co-site) White blood cells which normally circulate through the bloodstream but may also be found in sites of inflammation and lymphatic organs. See table at end of chapter 6.

leukaemia (loo-KEE-me-uh) A disease in which there is uncontrolled production of blood cells, generally characterised by substantially increased numbers of one blood cell type in the circulation.

ligament A band of dense fibrous connective tissue (DFCT) binding bones together at joints. Ligaments join bone to bone. Contrast with tendon.

ligament of the patella This ligament is formed of DFCT continuous with that of the tendon of quadriceps femoris. Proximally it is attached to the apex and margins of the patella, distally to the tibial tuberosity. Also called ligamentum patella.

lobe A more or less well defined division, generally rounded in shape e.g. divisions of the lung are easily distinguished and are called lobes. The most inferior part of the outer ear is generally rounded and is called the ear lobe. Nuclei with clearly defined rounded divisions are referred to as 'lobed' or 'lobulated'. Regions of the cerebrum e.g. occipital, temporal, frontal, parietal.

long bones Are longer than they are wide. They consist of a tubular shaft and two expanded ends with articular surfaces forming joints at the extremities, e.g. humerus and tibia.

lumbar Of or pertaining to the region of the body between the thorax (chest) and pelvis.

lumen (LOO-men) The internal space of a hollow organ such as a blood vessel or the intestines.

lymph (limf) The liquid found in the lymphatic vessels. Plasma without any cells and some dissolved substances seeps through capillary walls, circulates around tissue cells, and is known as tissue fluid. When this is drained from the tissues into the lymphatic system it becomes lymph.

lymph node Lymph nodes are oval structures that filter lymph. Healthy lymph nodes vary in sizes from about the size of a pinhead to that of a broad bean. They are situated throughout the lymphatic system generally in clusters in locations draining specific regions of the body. Thus lymph from the arm goes through the axillary nodes in the armpit.

lymphatic system (lim-FAT-ic) The system of lymph channels that drains extracellular fluid from the periphery via the thoracic duct to the blood. It includes lymph nodes, Peyer's patches, and other organised lymphatic elements.

lymphocyte (lim-FOE-sites) A non-phagocytic mononuclear leucocyte with specific surface receptors which interact with antigens.

lymphoid tissues An older term for tissues associated with the lymphatic system. The term "lymphatic" is now preferred, though lymphoid is still in fairly wide use.

lymphokine (lim-FOE-kine) A cytokine produced by lymphocytes.

lysis Destruction of a cell through the action of a specific agent, rupturing the cell membrane.

lysosome (LY-so-some) An intracellular organelle which contains hydrolytic enzymes responsible for intracellular digestion of foreign substances and infectious microorganisms.

lysozyme (LY-so-zime) An enzyme found in tears, milk, saliva, mucus and other bodily secretions that destroys bacteria by digesting their cell walls. Also called muramidase.

macromolecule A very large molecule commonly polymeric in structure such as DNA, RNA, proteins and storage carbohydrates.

macrophage (MAC-ro-faje) Large mononuclear phagocytic cell (macro = large, phage = eater) found in blood, lymphatic tissue and within other specialised organs (skin, brain, lung and liver). Immature macrophages, called monocytes, first circulate through the bloodstream before maturing in tissues.

major histocompatibility complex (MHC) The genetic complex coding for the unique cell surface glycoproteins that confer identity on each individual. MHC is vital for presenting foreign antigens by antigen presenting cells (APCs). MHC activates T cells and is the target for graft rejection.

malleolus (pl. malleoli) – either of the two rounded projections on each side of the ankle joint; the medial malleolus being formed by a projection of the distal tibia and the lateral malleolus by a projection of the distal fibula.

mandible (Man'di-bl) The lower jawbone.

margination (mar-gin-AY-shun) The movement of cells to sides (margins) of a vessel e.g. neutrophils moving and sticking to the margins of a blood vessel prior to undergoing diapedesis.

marrow cavity Hollow core of a long bone where the marrow is found. Also called the medullary cavity.

mast cell A type of connective tissue cell containing several physiologically active substances in large granules. These active substances include histamine and the granule contents can be released in infection, allergic reaction or physical injury.

medial Closer to the median plane. Opposite of lateral.

median Midline. The median plane is the sagittal plane dividing the body into equal left and right parts.

medulla (meh-DULL-uh) The central or inner portion of an organ (adjective is medullary).

medulla oblongata (meh-DUL-ah ob-long-GAH-tah) Lowest part of the brainstem; an enlarged extension of the spinal cord; the vital centers are located within this area.

membrane potential The electrical potential measured inside a cell relative to the outside of the cell.

meninges (meh-NIN-jeez) Fluid-containing membranes surrounding the brain and spinal cord.

meniscus (men-ISS-cuss) The fibrocartilaginous structure found inside the knee joint.

mesenteric (MESS-en-tare-ic) The mesentery is a membrane connecting the small intestine to the posterior wall of the abdominal cavity. The mesenteric lymph nodes are lymph nodes situated within this membrane. Lymph fluid formed in the intestinal tissue drains into these nodes.

meta- After, beyond.

metabolism (meh-TAB-oh-lizm) The sum of all chemical reactions in the body.

metacarpals The five bones forming the palm of the hand between wrist and fingers. All metacarpals are long bones.

metatarsals The five bones of the part of the foot between the tarsal bones and the toes. All metatarsals are long bones.

MHC See major histocompatibilty complex.

microbe A life form too small to be seen without the aid of a microscope.

midbrain Region of the brainstem between the pons and the diencephalon.

mitotic activity An indicator of the rate of cell division by mitosis (my-TOE-sis), this generally refers to the proportion of cells that are in the process of dividing.

Mø A common abbreviation for macrophage.

modality The type of sensation detected or encoded by a sensory nerve, e.g. light touch, deep pressure, temperature, etc.

mole Generally, the molecular mass in grams. Strictly, the amount of a substance (molecules, atoms, ions or free radicles) that contains as many particles as 12 grams of pure carbon-12.

monocytes (MON-o-site) A type of leucocyte found in the blood, the monocyte has a kidney-shaped nucleus and is the precursor of the tissue macrophage.

mononuclear (mon-oh-noo-klee-uh) Although this literally means cells with one nucleus, it is applied to white blood cells whose nuclei are not lobed. This probably derives from the early days of studies on blood cells, when it was thought that the lobes were actually separate nuclei. 'Mononuclear leucocytes' therefore refers to lymphocytes and monocytes.

morphology The study of the physical shape and size of cells, tissues, organs or other structures.

motor neurons Nerve cells which conduct impulses from the brain or spinal cord to muscular or other tissues.

motor unit A motor unit consists of a single motor neuron and all of the muscle fibres that it innervates.

mucus (MEW-cuss) A viscous, slimy or sticky secretion produced by mucous cells. Protects the mucous membrane from infection and abrasion.

muscle contraction The development of active tension in a muscle.

muscle fibre Striated muscle cell.

muscle spindle The sensor in muscles which responds to any stretch in the muscles, sending the information back through a reflex arc to aid in restoring the muscle length to its set point.

myelin (MY-eh-lin) Lipoprotein substance in the myelin sheath around many nerve fibers that contributes to high-speed conductivity of impulses.

myelinated (MY-eh-li-nay-ted) Axon surrounded by a sheath of myelin formed by Schwann cells (PNS) or oligodendrocytes (CNS)

myocardium The muscle tissue of the heart.

myocyte Muscle cell. Also called muscle fibre.

naive (ni-eve) Innocent, undeveloped. Naive lymphocytes have never been exposed to antigen to which they may respond. All lymphocytes that leave the primary lymphatic organs are naive. Memory and effector lymphocytes are clearly not naive.

nasopharynx (nay-so-fah-rinx) The upper part of the throat extending down to the level of the soft palate.

native antigen Antigenic material that has not been broken down into peptides by phagocytic cells.

natural killer cell A type of lymphocyte able to recognise and attack virus infected cells or tumour cells without the requirement for specific antibody or MHC.

neck In bones, the narrow section of the shaft immediately adjacent to the head.

necrosis (neh-CRO-sis) Pathological tissue death due to such causes as infection, trauma or hypoxia. Compare apoptosis.

negative control A reagent that will give a negative result; used to test the reagents in a test and also to eliminate false positive results.

nerve A collection of multiple nerve axons and surrounding connective tissue that travel a common route within the peripheral nervous system.

neuron (NOOR-on) The basic nerve cell of the nervous system containing a nucleus within a cell body and extending one or more processes. Nerve cells conduct information along the lengths of these processes.

neuromuscular junction (NMJ) The point of contact between a motor nerve ending and a muscle fiber.

neurotransmitter (NEW-roh-TRANS-mitt-er) Chemical released by neurons that may, upon binding to receptors on other cells, stimulate or inhibit them.

neutraliser A muscle acts as a neutraliser when it counteracts, or neutralises, an undesired action of another muscle such as movement at one of the joints acted on by a two joint muscle. E.g. the extrinsic finger flexor muscles cross the wrist and therefore can act to flex the wrist as well as the finger joints. In order to permit the full strength of the muscles to act in finger flexion, such as during power grip, the wrist extensor muscles act as neutralisers to cancel out the wrist flexion capability of the extrinsic finger flexors.

neutrophil (NOO-tro-fill) Also called a polymorphonuclear leucocyte (PMNL) because of polymorphic multi-lobed (uneven-shaped) nucleus. Cytoplasm contains neutral straining hydrolytic granules. Neutrophils are common white cells found in human blood.

neutrophilia (NOO-tro-fill-ee-uh) An increase in neutrophils circulating in the blood above the levels normally found in health.

nodes of Ranvier The unmyelinated sections of a nerve axon between two adjacent schwaan cells which are excitable and allow propagation of action potentials.

noradrenaline (NOR-ad-ren-ah-lin) UK term, a catecholamine chemical transmitter (neurotransmitter) substance released by some nerve endings, usually sympathetic nerve endings. Also called norepinephrine (USA).

norepinephrine (nor-eppy-NEF-rin) See noradrenaline.

normal range The range of a controlled variable around a set point which is normally observed in health. (Strictly, the term 'reference range' is more appropriate). *Anat*. The limits of movement of a joint without dislocation.

nuclei (NOO-klee-eye) Distinct regions of grey matter in the central nervous system; clusters of neuron cell bodies.

nucleolus (noo-KLEE-oh-lus) Dense, well-defined but membraneless body within the nucleus; critical to protein formation because it "programs" the formation of ribosomes in the nucleus

nucleus (NOO-klee-us) Membranous organelle that contains most of the genetic material of the cell; also, group of neuron cell bodies in the brain or spinal cord

oedema (eh-DEE-ma) Abnormal accummulation of tissue fluid resulting in swelling of the tissue.

olecranon process (o-LEH-cran-on) The prominent part of the ulna posterior to the elbow joint.

oligodendrocytes A small astrocyte; helps to form myelin sheaths around axons within the central nervous system (CNS). Contrast Schwann cells.

opposition Touching the tip of the thumb to the tip of any finger on the same hand.

opsonin (op-SO-nin) A substance which enhances phagocytosis by promoting adhesion of the target to the phagocyte. E.g. antigens on the surface of a bacterium may become coated with antibody, opsonising the bacterium.

opsonisation (OP-son-eyes-eh-shun) The coating of a target with opsonin.

osmolarity (oz-mo-LAR-ih-tee) The osmotic pressure of a solution, measured in osmoles or milliosmoles per litre.

osmoreceptor (OZ-mo-re-SEP-tur) A neuron of the hypothalamus that responds to changes in the osmolarity of the extracellular fluid.

osmosis (oz-MO-siss) Movement of water through a semipermeable membrane, along its activity gradient.

osmotic pressure The pressure applied to a solution to prevent the movement of water.

osseous (OSS-ee-us) Pertaining to bone.

ossification (OSS-ih-fih-CAY-shun) Bone formation.

osteoblasts Cells involved in production of bone.

osteoclasts Cells involved in the destruction of bone.

osteocytes Mature osteoblasts.

osteon The basic unit of structure of compact bone consisting of a central canal and surrounding lamellae.

osteoporosis (OSS-tee-oh-pore-OH-sis) A condition in which there is a deficiency of bone. Visible in radiographs.

oxidation Any reaction in which electrons are lost from a chemical entity. Since electrons carry a negative charge, the oxidised substances become more positively charged e.g. Fe^{2+} oxidised to Fe^{3+}. Electrons released in oxidation generally reduce some other chemical entity.

palmar grip A grip involving the whole hand and the fingers, e.g. gripping a screwdriver.

palpate To feel with the hand.

pancreas Organ of the body that manufactures bicarbonate, many digestive enzymes, and is responsible for homeostasis of plasma glucose concentrations through the controlled release of the hormones glucagon or insulin.

parasympathetic nervous system (pa-rah-sim-pah-THET-ick) The 'resting and digesting' subdivision of the autonomic nervous system.

parenchyma (pa-REN-kih-muh) The functional part of an organ. Compare with 'stroma'.

partial pressure The pressure exerted by a gas in a mixture of gases.

patella The 'knee cap'. A roughly circular sesamoid bone anterior to the knee joint.

patellar ligament A strong ligament attaching the patella to the tibia. See ligament of the patella.

pathogen Any organism capable of causing pathogenic change or disease in the host.

pathogenicity The ability to cause disease.

pathology The study of the characteristics, causes and effects of disease.

pectoral girdle Scapula and clavicle, attaches the upper limb to the trunk.

pelvic girdle A basin-like bony structure formed by the pelvic bones, sacrum and coccyx; attaches the lower limb to the trunk.

pelvis See pelvic girdle

perfusion (per-FU-shun) The amount of blood supplied to a mass of tissue or organ in a given period of time.

peri- Around.

perimysium The connective tissue layer which surrounds a bundle of muscle fibres (fascicles).

perineurium (pair-i-NOO-ree-um) connective tissue that encircles a bundle of nerve fibers within a nerve.

periosteum (PERR-ee-OSS-tee-um) Protective fibrous connective tissue covering bone surfaces, except on articular surfaces of joints. Carries blood vessels and nerves to the bone.

peripheral nervous system (PNS) (peh-RIF-eh-rul) Branch of the nervous system that is located outside of the brain and spinal cord. It consists of sensory neurons that conduct action potentials towards the CNS, and neurons that conduct action potentials away from the CNS to the tissues (motor neurons and autonomic neurons).

peripheral temperature (peh-RIF-eh-rul) The temperature of exterior parts of the body such as skin. Peripheral temperature may be quite variable depending on local ('ambient') conditions. Contrast with 'core temperature'.

peritoneum (PERR-ih-toe-NEE-um) A cavity in the abdomen formed by a large, continuous membrane lining the intestine and body wall.

Peyer's patch A lymphatic nodule in the wall of the small intestine. Several of them are usually present in humans, situated in the distal small intestine.

phagocytose The action of phagocytosis.

phagocytosis (FAG-oh-sy-TOE-sis) Endocytic uptake of large particles within a membrane bound vacuole (phagosome) which results in breakdown of the ingested material. The phagosome fuses with lysosomes to produce a phagolysosome.

phagolysosome (FAG-oh-LY-so-some) The intracellular unit formed by the fusion of a lysosome and a phagosome.

phagosome An intracellular sac formed by involution of the cell membrane, which contains phagocytosed matter.

phalanx (FAY-lanks) Any single bone of a finger or toe. [Plural - phalanges]

pia mater (PEE-ah MAH-ter) Vascular innermost covering of the brain and spinal cord. (Singular=meninx)

pilo-erection (PY-LOW) Hairs standing up on end. Also called 'goose bumps'.

pivot joint A type of synovial joint which allows rotation only, e.g. the radio-ulnar joints.

planes Imaginary flat surfaces along which the body can be sectioned.

plantar Pertaining to the sole of the foot.

plantarflexion (PLAN-tur-flec-shun) Movement of the ankle such as occurs when standing on the toes. Opposite of dorsiflexion.

plasma (PLAZ-ma) The fluid part of circulating blood or of blood which has been prevented from clotting. Plasma is a division of ECF (extracellular fluid).

plasma cell The cell responsible for synthesis and secretion of antibodies in humoral immunity.

plasma membrane The membrane that encloses a cell and controls the traffic of molecules in and out of the cell.

plenary Of an assembly to be attended by all members.

PMNL Polymorphonuclear leucocyte. Strictly, this term may be applied to neutrophils, eosinophils and basophils, but often refers only to neutrophils.

pons (ponz) part of the brainstem between the medulla oblongata and the midbrain

porous Capable of allowing moisture to pass through. Literally 'having pores'!

positive control Used in clinical tests e.g. ELISA, latex agglutination - the reagent added gives a definite positive result. This ensures the reagents of the test are performing as they should and that the positive test is conclusive.

posterior (dorsal) Towards the back. Opposite of anterior.

posterior horn (posterior grey horn, posterior grey column or dorsal horn) The posterior section of the grey matter of the spinal cord.

potential cavities Cavities not apparent unless filled with fluid or air. An important means of allowing free movement in synovial joints and bursae.

power grip Grips involving the extrinsic muscles of the fingers.

precision grip Gripping small objects with the thumb and one or more fingers using the intrinsic muscles of the fingers. Precision grips usually involve opposition of the thumb.

presynaptic neuron (pree-si-NAP-tik) In neuron to neuron communication, the neuron that transmits a signal to an adjacent neuron via a release of neurotransmitters that cross the synapse and bind to the postsynaptic neuron.

primary follicle Roughly spherical collections of lymphocytes in the cortex of lymph nodes. When stimulated by an antigen to which one or more of the lymphocytes is reactive, they develop into larger, paler secondary follicles.

primary lymphatic tissue Tissues in which lymphocytes develop (e.g. thymus and bone marrow in mammals). Contrast with secondary lymphatic tissue.

process In anatomy, any bony prominence (e.g. vertebrae have a number of processes).

pronation (pro-NAY-shun) Turning the hand while in the anatomical position so the palm is facing backwards. The reverse of supination.

Protein A Protein produced by *Staphylococcus aureus* that inactivates antibody and prevents opsonisation thus enabling the bacteria to evade the innate immune response.

proximal (PROK-si-mal) Closer to the trunk, in relation to the anatomical position. Opposite of distal.

pubic symphysis (SIM-fih-sis) The articulation between the pelvic bones in the pubic (anterior) region. A cartilaginous joint.

pulmonary (PUL-mo-ner-ee) Pertaining to the lungs.

pus cell A dead neutrophil found in pus, generally due to migration of neutrophils into tissues under microbial attack. As a result of phagocytosing numbers of bacteria, or simply because they have a limited life span, dead neutrophils accumulate at the site.

pyrexia (PY-rect-see-uh) An abnormal elevation of core body temperature above 37°C. Also called 'fever'.

pyrimidal tract Fibers that come together in the medulla to form the pyramids, also called the corticospinal tract.

quadriceps femoris The four-headed muscle that makes up the bulk of the anterior aspect of the thigh. Powerful extensor of the knee.

radial artery An artery in the forearm starting roughly at the neck of the radius as the brachial artery divides to form the radial and ulnar arteries. It continues to the wrist and supplies the thumb and index finger. Because it is easily palpated at the wrist, the radial pulse is most often used to find the pulse rate.

radiation Direct **e**mmision of energy, *e.g.* the sun radiates energy (heat).

radiograph (or radiogram) (RAY-dee-oh-graf) Image formed by X-rays. Dense structures such as bone appear white.

radius The bone on the lateral side of the forearm.

receptive field The "receptive field" of a sensory axon in a peripheral nerve is the area of the body that, if stimulated, results in the firing of that axon.

receptor A cell, organ or protein specialised to detect a stimulus or molecule.

recruitment In neural signalling, the involvement of more nerve axons as the strength of stimulus increases.

rectus femoris The most superficial of the four muscles of the quadriceps femoris group, situated centrally on the anterior aspect of the thigh. Note: Only this one of the four muscles crosses the hip joint.

reflex An automatic involuntary reaction to a stimulus resulting from a nerve impulse passing over a reflex arc.

reflex arc The impulse conduction route to and from the central nervous system. The smallest portion of the nervous system that can receive a stimulus and generate a response.

regulated variable often used interchangeably with the term 'controlled variable' but specifically refers to variables for which a specific sensor is known to exist in the body.

repolarisation The return of the resting membrane potential after depolarisation of a nerve or muscle fibre.

resting membrane potential The state of nerve fibres at rest in which there is an electrical potential difference between the outside (+ve) and the inside (-ve) of the axon membrane.

rib cage Composed of 24 ribs articulating posteriorly with the vertebral column and mostly anteriorly, via cartilages, with the sternum. Ribs are flat bones.

rotation Turning the bone at a joint around its long axis.

s The standard abbreviation for second.

sacrum (SAY-krum) A triangular-shaped bone at the base of the vertebral column, formed usually by five fused vertebrae.

sagittal (SADJ-ih-tul) The plane running vertically through the body, separating it into left and right parts.

saline A solution of dissolved salts.

sarcolemma The plasma membrane around a muscle cell. See also T-tubules.

sarcomere (SAR-co-meer) In skeletal and cardiac muscle, the portion of a myofibril from one Z-line to the next, constituting one contractile unit.

sarcoplasmic reticulum The smooth endoplasmic reticulum of a muscle cell, serving as a calcium reservoir.

scapula (SKAP-you-lah) The shoulder blade. A flat bone.

Schwann cells (shwon or shvon) Large nucleated cells that form myelin around the axons of neurons, within the peripheral nervous system (PNS). Contrast oligodendrocytes.

sebum (SEE-bim) Secretion of the sebaceous (see-BAY-shus) [oil] glands.

secondary follicle A group or collection of lymphocytes in lymphatic tissue, actively dividing following stimulation by antigen.

secondary lymphatic tissue Lymphatic tissues such as lymph nodes and spleen which are the sites of the interaction of immune cells with antigen. (Compare with primary lymphatic tissue).

section A cut surface or slice of tissue. The action of cutting tissue.

semi- Half

semimembranosus One of the hamstring muscles of the posterior thigh, attached proximally to the ischial tuberosity and distally to the tibia. Its name is due to the membranous attachment to the tibia.

semitendinosus One of the hamstring muscles of the posterior thigh, attached proximally to the ischial tuberosity and distally to the tibia, i.e. very similar to semimembranosus. Its name is due to the unusual length of the tendon attaching it to the tibia.

sensors Biological devices capable of detecting changes in the condition of a controlled variable e.g. temperature sensitive nerve endings in the skin.

sensory neuron Nerve cells that originate at a sensory receptor and conduct action potentials encoding sensory information to the brain or spinal cord.

sensory receptor sense organs in the periheral nervous system that enable the body to respond to stimuli caused by changes in its internal or external environment [*sens*-feel, *-ory* relating to, *recept*-receive,*-or* agent]

sensory unit A single afferent neuron plus all the sensory receptors that it receives input from.

serum The fluid part of blood after clotting has taken place.

set point In homeostasis, the central mean value for the range within which a controlled variable is maintained in health.

shaft A long, generally straight, stem or stalk-like structure.

short bones These are roughly cube-like or round, e.g. the carpals (the small bones at the wrist).

shoulder (joint) The ball-and-socket articulation of the proximal humerus and the scapula.

sinus Latin: a hollow or curve.

skeletal (muscle) The voluntary contraction muscle(s) attached to the body skeleton. Skeletal muscle cells are multi-nucleated and cylindrical with obvious striations.

skull Consists of a number of bones of which all except the mandible (lower jaw) are fixed immovably together after infancy.

smooth (muscle) Non-striated involuntary contraction muscle found in many places in the body e.g. the walls of the blood vessels, body organs.

soleus (sole-eh-us) A muscle in the leg (calf) which, together with the gastrocnemius, forms the triceps surae muscle. It is a plantarflexor of the ankle.

solute The substance that is dissolved in a solvent to form a solution.

soma (SO-mah) cell body

somatic (so-MAT-ic) Pertaining to the body as a whole.

somatic motor neurons A motor neuron which conducts impulses from the brain or spinal cord to skeletal muscle.

sorbent as in 'immuno sorbent' : the property of a substance that allows it to interact with another compound, usually to make it bind.

spinal cord The nerve cord that passes through the vertebral column. The spinal cord plus brain constitute the central nervous system.

spleen A secondary lymphatic organ located in the left hand side of the abdominal cavity between the stomach and the diaphragm. In addition to its lymphatic organ activities, the spleen is involved in a number of activities involving red blood cells.

stabiliser (stay-bil-ise-er) A muscle acts as a stabiliser when it contracts isometrically to hold a joint still during carrying actions e.g. when carrying a tray like a waiter, biceps brachii is acting as a stabiliser at the elbow joint.

stance phase A phase in gait in which the foot is on the ground, in contrast to the swing phase.

stem cell A cell capable of mitosis whose progeny may give rise to other cell types.

sternum Breast bone. A flat bone.

stretch reflex The reflex generated when a muscle is stretched (e.g. by tapping an attached tendon) to restore the muscle length to the set point.

striated (stry-AY-ted) Striped appearance, usually refers to muscle cells.

stroma The tissue forming the framework of an organ. Compare with parenchyma. Greek: covering, was originally applied to the fibrous connective tissues covering of various tissues and organs.

sub- Under, beneath, below.

subarachnoid space (sub-ah-RAK-noyd) within the meninges, space under the arachnoid and outside the pia mater

subcapsular space A region just under the capsule of lymph nodes into which the afferent lymphocytes drain. Also called subcapsular sinus.

subperiosteal Beneath the periosteum i.e. between the bone and the periosteum.

subunit A subunit is some part of a whole. In relation to subunit vaccines, these are vaccines made using part of the infective agent, with the idea of producing antibody that will neutralise the infective agent without the vaccine itself causing disease.

superficial (soo-per-FISH-al) In gross anatomy, used to describe structures close to the surface. Opposite of deep.

superior Towards the head. Opposite of inferior.

supination (SOO-pih-NAY-shun) Turning the hand into the anatomical position so the palm is facing forwards. The opposite of pronation.

surface anatomy The study of the external surface of the body and its relationship to the underlying structures.

surface area In square metres, SA = wt(kg)0.425 x ht(cm)0.725 x 71.84/10,000. N.B It is not necessary to memorise this formula!

sulcus (SUL-kus) central or lateral furrow, or groove, often associated with the cerebral cortex.

suture *Anat* A border or a joint, e.g. between the bones of the cranium. *Medi* To stitch together cut or torn edges of tissue.

swing phase A phase in gait in which the foot is off the ground, in contrast to the stance phase.

sympathetic nervous system (sim-pah-THET-ick) The 'fright, fight and flight' subdivision of the autonomic nervous system.

syn- A prefix meaning union or association.

synapse The junction that forms between a nerve cell terminal and its following cell. Synapses are characterised by a minute gap between the two cells into which the neuron releases neurotransmitter to diffuse across the gap to interact with, and signal the following cell.

synovial fluid (sy-NO-vee-al) A transparent, viscous fluid secreted by the synovial membranes and acting as a lubricant for joints, bursae and tendons. It contains mucin, albumen, fat and mineral salts. In healthy tissues, there is only a thin film of synovial fluid present. Graeco-Roman: 'syn + ovia' - the white of an egg; synovial fluid resembles egg white.

synovial joints The class of joints characterised by a potential cavity. Such joints characteristically allow a wide range of movements.

synovial membrane A thin layer of very smooth connective tissue that lines the articular cavity of synovial joints. Secretes synovial fluid.

systemic (sis-TEM-ic) Widespread or pertaining to the whole body, as in the systemic circulation.

talus One of the tarsal bones which forms the ankle joint by articulating with the tibia and fibula. A short bone.

tarsal bones There are seven tarsal bones in the foot near the ankle, e.g. calcaneus and talus.

tarsus Is derived from the Greek for 'flat basket'. Originally applied to the flat part of the foot, it has been transferred to the bones in that part of the foot.

Tb Abbreviation for tuberculosis.

TBW abbreviation for total body water.

T-cytotoxic cell A type of lymphocyte derived from the thymus which can recognise MHCI molecules and foreign antigens on cell surfaces, and can destroy such cells. They are active against virally infected cells and cancer cells.

tendon A band of dense fibrous connective tissue connecting muscle to bone. Contrast with ligament.

tetanus When a muscle develops a sustained maximal contraction in response to high frequency stimulation.

thalamus (THAL-ah-muss) Mass of grey matter located in diencephalon just above the hypothalamus; helps produce sensations, associates sensations with emotions, and plays a part in the arousal mechanism.

T helper lymphocyte A type of lymphocyte derived from the thymus which assists other immune cells to perform their immune function e.g. usually by releasing cytokines.

thermoreceptor Specialised nerve endings capable of detecting changes in temperature.

thigh The region of the lower limb between the hip and the knee joint.

thoracic (thor-ASS-ic) Of or pertaining to the region of the chest (thorax).

thymus A glandlike structure in the upper part of the chest beneath the sternum where T lymphocytes differentiate and where only those lymphocytes which can recognise individual MHC molecules develop into immunocompetent T lymphocytes.

tibia The large bone on the medial side of the leg (between the knee and ankle joint). A long bone.

tibialis anterior A muscle located on the lateral anterior aspect of the leg (shin). This muscle dorsiflexes the ankle joint and is important during the swing phase of gait to clear the foot from the ground.

tissue component Any part of a tissue, e.g. a nucleus is one tissue component, collagen is another, muscle is another. The term is useful when discussing differential staining of tissue sections.

T lymphocytes (T cells) Lymphocytes produced within the thymus which serve to regulate immune function and produce immunity. See also T helper and T cytotoxic cells.

toe-off A phase in gait when the ankle on the stance side is being powerfully plantarflexed to lift the heel from the ground and push the body forward.

tonsils Secondary lymphatic tissue which filters lymph, particularly that arising from the mouth and nose regions.

total body water (TBW) Total body water consists of extracellular fluid + intracellular fluid.

toxoid Many toxins are powerful - in some cases one molecule is enough to kill a cell - so injecting toxins to make antibodies would not work. [Although there certainly would be an effect!] In some toxins, the molecule can be artificially altered so that it is no longer toxic, but can still stimulate the immune response to make antibody against the fully active toxin. These altered toxins are called toxoids.

trabecula (tra-BEC-you-la) Supporting structure, e.g. the struts of cancellous bone or connective tissue supports in lymph node, thymus etc. [Plural - trabeculae]

transduction (genetics) A method of genetic recombination by which DNA is transferred from one cell to another by a viral vector. Various bacteriophages transfer DNA from one species of bacteria to another.

transduction (physiology) Process of changing one form of energy, or other physical, event to another form, as when sound energy is changed to electrical energy in a microphone [*trans*-through, *duct* - to lead, *-ion* process]

transverse (trans-VERS) The plane running horizontally through the body or a limb separating it into superior (upper) and inferior (lower) parts.

trauma (TRAW-ma) Damage to tissues due to physical injury.

treppe The process of mechanical summation of successive muscle twitches.

triceps (TRY-seps) Three headed, usually applied to certain muscles.

triceps brachii The three-headed muscle on the posterior aspect of the arm. The powerful extensor of the elbow joint.

triceps surae (su-RAY) The three-headed muscle in the leg (calf) consisting of the soleus and the gastrocnemius muscles.

trunk General term for the thorax (chest), abdomen and pelvis.

T tubules Transverse invaginations of the sarcolemma that carry an electrical impluse from the surface of a muscle cell to it's interior when the cell is stimulated.

tuberculosis A disease caused by one of the members of the genus Mycobacteria; in humans, usually the bacterium *Mycobacterium tuberculosis.* While commonly a chronic lung infection in humans, it can affect many body sites.

tuberosity A protuberance or elevation. In anatomy, an elevation on a bone to which muscles or ligaments are attached.

turgor (TERR-gor) The normal resiliency of the skin caused by the outward pressure of the cells and interstitial fluid. In dehydration - decreased turgor, skin is lax (loose). In overhydration - increased turgor, skin is taut and cannot be grasped and raised.

ulna The bone on the medial side of the forearm. A long bone.

ulnar nerve The nerve supplying the muscle and skin on the ulnar side of the forearm and hand. It is easily palpated at the elbow in the groove between the olecranon process and the medial epicondyle of the humerus, where it is commonly referred to as the 'funny bone'.

vaccine A preparation of killed organisms; inactivated toxin or living, weakened (attenuated) microorganisms which induce protective immunity.

vasculature (VASS-ku-lah-cher) Of or pertaining to the 'blood vessels'.

vastus intermedius One of the four muscles of the quadriceps femoris group, situated deep to rectus femoris.

vastus lateralis One of the four muscles of the quadriceps femoris group, situated on the lateral aspect of the thigh.

vastus medialis One of the four muscles of the quadriceps femoris group, situated in the medial aspect of the thigh.

vein A vessel with a three layered coat, like arteries but whose wall is relatively thinner, and conveys blood from peripheral tissues (in the systemic circulation) back to the heart.

ventral See anterior.

vertebra (VUR-teh-bra) Any of the separate bones which together make the spine. [Plural - vertebrae] An irregular bone.

vertebral column (VUR-teh-brul) Spine - composed of 24 individual vertebrae together with the sacrum and coccyx.

virulence (VIR-you-lents) The degree of pathogenicity of an organism as measured by its ability to invade host tissue and cause tissue damage or fatality.

wheal and flare reaction A skin reaction that may follow injection of an antigen. The wheal is a fluid filled raised area rather like a blister, while the flare is an area of reddening spreading out from the site of antigen injection.

white matter Nerves covered with white myelin sheath.

wrist (joint) The joint between the distal end of the radius and the most proximal of the carpal bones. All movements except rotation are possible at the wrist (i.e. flexion, abduction, adduction, extension and circumduction).

x-ray Name commonly used for radiograph. Properly, the "rays" which produce radiographs.

The front cover

The front cover features a skull from the Anatomy Resource Collection

The images on the back cover from top to bottom are as follows:

1. Skull. From the Anatomy Resource Collection.
2. Spleen tissue labeled with monoclonal antibody to CD169 sialoadhesin (Green) with nuclei counterstain (DAPI; Blue). Source: Sarah Saunderson (PhD student; McLellan lab), Department of Microbiology & Immunology.
3. Mouse Cerebellum, a region of the brain critical for refinement of movement. This sagittal slice through the mouse cerebellum illustrates the highly folded nature of this important brain structure. The small, bright dots are the output neurons, called Purkinje neurons, the fibres you can see are bundles of axons of many individual Purkinje neurons heading towards the brain stem and other structures of the central nervous system involved in movement. From Ruth Empson, Department of Physiology, whose research focus is to understand the neurophysiology of cerebellar circuitry and how it goes wrong in a variety of neurological disorders.
4. Autofluorescence (green) in spleen tissue. Source: Alexander McLellan, Department of Microbiology & Immunology.
5. Lymph node tissue labeled with monoclonal antibody to CD169 sialoadhesin (Green) with nuclei counterstain (DAPI; Blue). Source: Sarah Saunderson (PhD student; McLellan lab), Department of Microbiology & Immunology.