Last update: december 2022

# Cervical and endometrial polyps

Author: Dr. med. Susanne Lanz

Oberärztin, Fachärztin für Gynäkologie und Geburtshilfe, Schwerpunkt operative Gynäkologie und Geburtshilfe, speziell Myomsprechstunde, Dysplasie, minimalinvasive Chirurgie, Universitätsklinik für Frauenheilkunde, Inselspital Bern

Co-Author(s): Prof. Dr. med. Michel Mueller

# Introduction

Polyps are hyperplastic protrusions of the mucosa. In the uterus, they are categorized based on their location as endometrial (uterine) polyps or cervical polyps.

Polyps are a common phenomenon, often oligo- or asymptomatic, often discovered incidentally during a routine gynecological examination or a transvaginal ultrasound.

The following questions are relevant and will be discussed with an evidence-based approach in this chapter: Do asymptomatic polyps require any treatment? How are polyps removed correctly? Does the procedure differ for pre- and postmenopausal patients? Or for asymptomatic patients versus those with abnormal uterine bleeding (AUB)? Can polyps show a malignant histology? If so, what are the parameters for assessing the risk of malignancy? What is the relevance of endometrial polyps for fertility/infertility?

# Definitions

Endometrial polyps are localized hyperplastic overgrowths of stroma and endometrial glands. They can have a wide base or be attached to the uterus with a pedicle, and range from a few millimeters to several centimeters. Large endometrial polyps or those with very elongated pedicles can even prolapse through the cervix and be visible in the vagina (= in statu nascendi).



Figure 1: Hysteroscopic images of endometrial polyps (with kind permission of the author S. Lanz).

Cervical polyps arise from a hyperplasia of endocervical mucosa. They are found inside the cervical canal or may prolapse into the vagina.

Endometrial polyps consist of:

- Endometrial glands
- Stroma
- Blood vessels

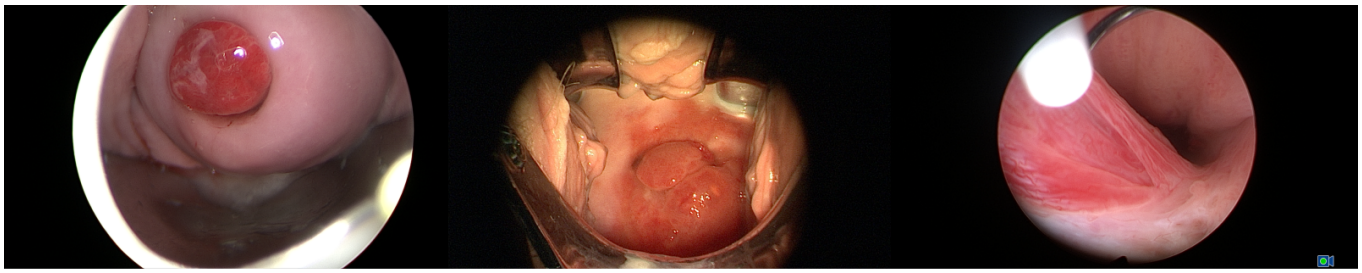

A B C

Figure 2 (with kind permission of the author S. Lanz).
A & B – Colposcopic view of cervical polyps
C – Hysteroscopic view of polyp pedicle (center of image B)

# Epidemiology

Endometrial polyps are common. The exact incidence remains unclear as they are often asymptomatic. High resolution transvaginal ultrasound is nowadays widely used, even for routine examinations with no clear indication, and device technology has improved So asymptomatic polyps are diagnosed more and more frequently. Studies suggest that the prevalence ranges from approx. 8 to 35 %, depending on the study population. Known risk factors are advanced age, obesity, hypertension, diabetes, and tamoxifen treatment.

There is little data on the natural course of endometrial polyps, but according to one study, polyps can spontaneously regress and disappear by up to 27 % within an observation period of one year.

The prevalence of polyps with premalignant (hyperplastic atypia) or malignant (endometrial cancer or sarcoma) histology is between 3,4 and 4,9 % in postmenopausal and 1,1 % in premenopausal patients. This risk is much higher in symptomatic patients, and the aforementioned risk factors also increase the risk of malignancy.

# Clinical presentation

Endometrial polyps

- Smaller polyps are usually asymptomatic. They may cause brownish spotting.
- Larger polyps can cause hypermenorrhea, menorrhagia or metrorrhagia. There is some discussion as to the role of endometrial polyps in the diagnosis of sterility (see below).
- If polyps enter the cervical canal, this can cause contraction-like pain.

40 % of postmenopausal bleeding is caused by endometrial polyps.

Cervical polyps

- Often asymptomatic
- Occasionally increased discharge and/or bleeding on contact or spotting

## Polyps and risk of malignancy

The vast majority of endometrial polyps are benign. However, as in normal endometrium, premalignant (atypical hyperplasia) or malignant (carcinoma, carcinosarcoma) histology can be found in endometrial polyps. If a polyp with atypical hyperplasia is removed by means of hysteroscopy, the risk of concomitant carcinoma in the surrounding endometrium is 30,8 %. A hysterectomy (usually with bilateral adnexectomy) is therefore recommended for postmenopausal patients in this case. For premenopausal women, a hysterectomy or - in specific cases, where the patient wishes to preserve fertility - progestogen therapy is an option.

In general, the risk of premalignant or malignant polyps is higher in postmenopausal (nearly 5 %) than in premenopausal women (1,1 %), and higher in symptomatic patients with AUB (5 %) than in asymptomatic patients (1,8 %).

The known risk factors for endometrial cancer, such as obesity, advanced age and diabetes, are also risk factors for premalignant or malignant histology in an endometrial polyp.

Attempts to define other parameters (e. g. size on ultrasound) for assessing the risk of malignancy have not been successful so far.

For this reason, as there are no clearly defined criteria suggesting that a malignancy is very likely, or can be ruled out with relative certainty, the hysteroscopic resection of polyps is widely recommended in practice. The surgery is relatively minor, the rate of complications is low and the accuracy of histological results after total resection is very reliable.

## Polyps and fertility/infertility

Endometrial polyps are found in approx. 8 to 12 % of women of childbearing age. There is no clear link between their presence and impaired fertility.

However, the prevalence of polyps increases to approx. 32 % in patients with infertility. Possible explanations for the negative impact of polyps on fertility, in addition to the mechanical effect, include the secretion of certain molecules that affect sperm transport or embryo implantation and can worsen endometrial receptivity. As evidence of the causal link between polyps and infertility, in a randomized trial of infertility patients with endometrial polyps, twice as many pregnancies were achieved in the group with hysteroscopic polypectomy before intrauterine insemination as in the group with polyps left in utero.

# Diagnosis

In the case of AUB, the usual general diagnostic procedure is carried out:

- Gynecological examination (speculum)
- Transvaginal ultrasound (where 3D ultrasound with Doppler is somewhat superior to 2D ultrasound) If it is difficult to distinguish between endometrial thickening and endometrial polyps, sonohysterography, whereby the uterine cavity is filled with saline via the cervical canal, can be helpful.
- Diagnostic hysteroscopy

## Endometrial polyps

Often discovered as an incidental finding during vaginal ultrasound.

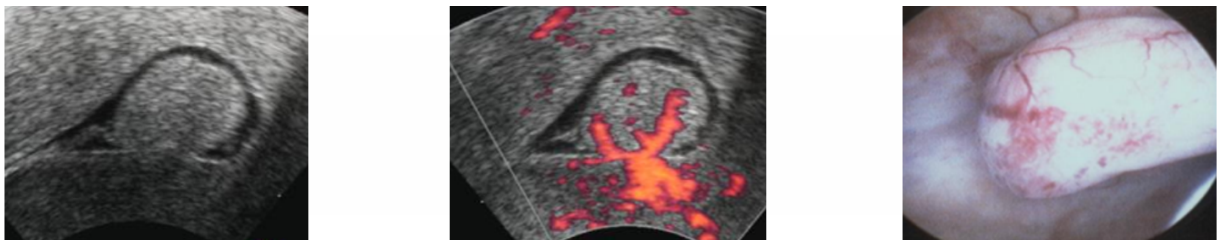

Figure 3: 2D ultrasound, power Doppler ultrasound and hysteroscopic image of an endometrial polyp (with kind permission of the author S. Lanz).

## Cervical polyps

Size ranges from a few millimeters to several centimeters. When directly visible, they present on the ectocervix as smooth-edged, round, usually reddish lesions.

Figure 4: Pedunculated serrated polyp protruding into the vagina (uterus opened longitudinally).

# Differential diagnosis

Cervical polyps have a typical presentation, and are hardly ever mistaken for other pathologies.

All endometrial polyps undergo histological testing to differentiate:

- Adenoma/Adenomyoma
- Submucosal fibroid
- Carcinoma (most significant cause of bleeding for differential diagnosis!)
- Sarcoma
- Retained products of conception/placental polyp

# Treatment

Endometrial polyps should always been removed under visual control.

Instrumental polyp removal (always with the pedicle) plus in most cases subsequent additional measures if indicated on differential diagnosis:

## Endometrial polyps

1. If a polyp is seen protruding into the vagina, in premenopausal patients with normal menstruation (no AUB), it can simply be twisted off at the base. (in absence of histopathological abnormalities, no further measures).
2. In all other cases (location in uterine cavity, post menopause, AUB), a hysteroscopy for targeted resection under visual control is indicated. There is still insufficient evidence as to which technical instruments should be preferred. Resection can be carried out with a loop electrode, or using hysteroscopic devices that separate the tissue with rotating or vibrating blades with direct aspiration of the removed tissue.
3. In order to avoid missing potential endometrial carcinoma or sarcomatoid changes, hysteroscopic resection is followed by uterine curettage in high-risk patients.
4. Note: "Blind" removal methods using uterine curettage alone (without a hysteroscope) are obsolete.

The combination of hysteroscopic polypectomy and curettage provides a high level of accuracy for the diagnosis or exclusion of endometrial carcinoma.

Hysterectomy should be considered, particularly in post- menopause:

- In case of numerous polyps - polyposis.
- In case of additional pathologies (e.g. adenomyosis, myoma, etc.)
- Before a hysterectomy is carried out, histological analysis of a mucosa sample is mandatory, either with a Pipelle de Cornier (alone, if results confirm malignancy) or hysteroscopy/resectoscopy and curettage.

A

B

Figure 5
A – Endometrial polyposis (surgical specimen)
B – Uterine polyposis (vaginal sonohysterography)

## Cervical polyps

1. Pedunculated polyps in premenopausal patients with no AUB can be removed by twisting off at the base. Histological testing is recommended.
2. In post menopause or when there is any doubt about the diagnosis (for example unclear information on AUB, limited conditions in ultrasound), a hysteroscopy and complete curettage should be carried out in addition to the removal of the cervical polyps to assess the uterus.

# Literature


| Nr. | Title | Author | Journal | Volume | Pages |
|---|---|---|---|---|---|
| [1] | AAGL practice report: practice guidelines for the diagnosis and management of endometrial polyps (doi: 10.1016/ j.jmig.2011.09.003. PMID: 22196255) | American Association of Gynecologic Laparoscopists | J Minim Invasive Gynecol | 19(1) | 3-10 |
| [2] | The oncogenic potential of endometrial polyps: a systematic review and meta-analysis | Lee SC, Kaunitz AM, Sanchez-Ramos L, Rhatigan RM | Obstet Gynecol | 116(5) | 1197-1205 |
| [3] | Treatment of endometrial polyps: a systematic review | Lieng M, Istre O, Qvigstad E | Acta Obstet Gynecol Scand | 89(8) | 992-1002 |
| [4] | Abnormal uterine and post-menopausal bleeding in the acute gynaecology unit | Bignardi T, Van den Bosch T, Condous G | Best Pract Res Clin Obstet Gynaecol | 23(5) | 595-607 |
| [5] | The risk of premalignant and malignant pathology in endometrial polyps: should every polyp be resected? | Papadia A, Gerbaldo D, Fulcheri E, Ragni N, Menoni S, Zanardi S, Brusacà B | Minerva Ginecol | 59(2) | 117-124 |

| Nr. | Title | Author | Journal | Volume | Pages |
|---|---|---|---|---|---|
| [6] | Atypical Endometrial Polyps and Concurrent Endometrial Cancer: A Systematic Review (doi: 10.1097/AOG.0000000000001566. PMID: 27500332) | de Rijk SR, Steenbergen ME, Nieboer TE, Coppus SF | Obstet Gynecol | 128(3) | 519-525 |
| [7] | Atypical endometrial polyps and the incidence of endometrial cancer: a retrospective cohort study (doi: 10.1111/1471-0528.16194. Epub 2020 Apr 9. PMID: 32133762) | Jacobs I, Tibosch R, Geomini P, Coppus S, Bongers MY, van Hanegem N | BJOG | 127(8) | 994-999 |
| [8] | The risk of malignancy in uterine polyps: A systematic review and meta-analysis (doi: 10.1016/j.ejogrb.2019.04.009. Epub 2019 Apr 15. PMID: 31009859) | Uglietti A, Buggio L, Farella M, Chiaffarino F, Dridi D, Vercellini P, Parazzini F | Eur J Obstet Gynecol Reprod Biol | 237 | 48-56 |
| [9] | Risk of malignancy on suspicion of polyps in menopausal women (doi: 10.1016/j.ejogrb.2017.07.013. Epub 2017 Jul 15. PMID: 28763739.) | Bel S, Billard C, Godet J, Viviani V, Akladios C, Host A, Faller E, Boisrame T, Hummel M, Baldauf JJ, Lecointre L, Garbin O | Eur J Obstet Gynecol Reprod Biol | 216 | 138-142 |

| Nr. | Title | Author | Journal | Volume | Pages |
|---|---|---|---|---|---|
| [10] | Uterine polyps, adenomyosis, leiomyomas, and endometrial receptivity (doi: 10.1016/j.fertnstert.2019.02.008. PMID: 30929720.) | Munro MG | Fertil Steril | 111(4) | 629-640 |
| [11] | Management of endometrial polyps in subfertile women: a systematic review | Afifi K, Anand S, Nallapeta S, Gelbaya TA | Eur J Obstet Gynecol Reprod Biol | 151(2) | 117-121 |