Last update: December 2023

Uterine artery embolization

Author: Prof. Dr. med. Christoph J. Zech

Leitung intervent. Radiologie, Angiografie, Qualität und Sicherheit, Mitglied Tumorzentrum, Universitätsspital Basel

Co-Author(s): Dr. med. Thomas Hess, Prof. Dr. med. Christoph Binkert

Introduction

Uterine artery embolization (UAE) is a symptom-oriented, organ-conserving procedure for treating benign uterine fibroids.

For this, a deliberate obliteration of the terminal arteries is carried out in the uterus via the uterine artery, thus interrupting the blood supply to the vessels around the fibroid. For this purpose, during UAE, gelatin or plastic particles the size of a grain of sand (500 to 900 µm) are introduced via catheter through the femoral arteries into the relevant uterine arteries. Reducing or interrupting the blood supply leads to all fibroids in the uterus being treated at the same time during the procedure and shrinking within a few months. The extent of fibroid shrinkage does not correlate with the extent of symptom improvement. Most fibroids shrink by some 50 to 70 % in volume.

History

The method of particle embolization for acute bleeding in the uterus (tumor hemorrhage, unstoppable postpartum or post Cesarean bleeding, or bleeding from arteriovenous malformation in the uterus) has been carried out since the 1970s. In 1989, transarterial embolization of symptomatic uterine fibroids (fibroid embolization) was first carried out by Merland, an interventional neuroradiologist.

Since it was first described in 1995 by Ravina, the angiographic treatment of symptomatic uterine fibroids using embolization under angiographic control has experienced rapid spread across the world. After first taking place mainly in France, Great Britain and the USA (referred to as uterine fibroid embolization, UFE), this minimally invasive angiographic procedure has been used in Germany since 2000 and is approved in Switzerland as an essential treatment subject to conditions since 2012.

Diagnosis

Before non-surgical, minimally invasive uterine fibroid embolization, pregnancy and inflammatory/(pre)malignant diseases of the uterus must be ruled out with an annual gynecological check-up including normal PAP smear and a transvaginal or additional abdominal ultrasound. For further diagnosis of the fibroid and its blood supply, an MRI with MR-angiography is useful for more precise assessment, particularly of circulation. A fibroid that is already infarcted should not be treated. In addition, other causes such as diffuse adenomyosis, endometriosis and ovarian tumors can be diagnosed. Before and after the intervention, it can make sense to determine/monitor ovarian function via blood E2 and FSH levels. Fibroid-induced foreign body sensations and symptoms such as pain, cramps, dyspareunia, dysuria, dys- and algomenorrhea, and bleeding disorders such as hypermenorrhea and menometrorrhagia generally improve or completely disappear thanks to the intervention. After the intervention, embolized fibroids shrink over a duration of several months. Submucosal fibroids can occasionally be expelled after varying intervals. This is accompanied by contraction-like pains and bleeding.

The procedure should be carried out under interdisciplinary collaboration between an interventional radiologist (embolization) and a gynecologist (patient preparation and clinical follow-up).

Indications include symptomatic fibroids extending to roughly the level of the navel and the patient’s desire and consent to carry out the intervention after an information session. Contraindications include asymptomatic fibroids, manifest infection of the urinary or genital organs, endometriosis lesions worthy of clarification, (pre)malignant uterine changes, iodine allergy (contrast) and hyperthyroid state. Relative contraindications are subserosal or submucosal pedunculated fibroids and large fibroids extending beyond the level of the navel, as efficacy can be limited or the procedure can be complicated in these cases.

UAE is not a treatment method for fertility in patients with fibroids. However, before a hysterectomy (not indicated if children are desired) is considered for a patient who has not yet completed her family, the possibility of UAE, ideally with a temporary embolizing agents (gelatin particles), should be verified. For patients who wish to have children, the role of UAE as a treatment option has not yet been clarified. UAE is not a contraceptive measure and subsequent pregnancies carry an elevated level of medical risk.

Summary of indications and contraindications

An indication for fibroid embolization should only be decided upon in close collaboration between a gynecologist and an interventional radiologist, in full knowledge of the range of treatment options available.

The literature currently gives the following indications:

Established indications

- Symptomatic fibroids in submucosal, intramural and subserosal locations with broad contact with the uterine wall and an individual fibroid diameter of up to approx. 12 cm with an overall uterine length of up to 22 cm, whereby the fundus should not extend beyond the level of the navel
- Recurrent fibroids after organ-conserving surgery (myomectomy)
- Contraindications for surgery

Relative contraindications

Technical

- Previous GnRH analog treatment in previous three months (increased risk of insufficient embolization of uterine artery), although this therapy should no longer be carried out for uterine fibroids.

According to current knowledge, the administration of ulipristal acetate has no significance for the indication and performance of UAE and does not influence the results of uterine artery embolisation.

Anatomical

- Isolates submucosal fibroids, type 0 and 1 as per ESGE, for which hysteroscopic ablation is available
- Isolated subserosal pedunculated fibroids
- (Additional) treatment of fibroid(s) via ovarian artery; the benefits and risks associated with cumulative reversible embolization of the relevant ovarian artery must be weighed up

Other

- Documented allergic reaction to contrast containing iodine

- Postmenopausal patients
- Allergy to local anesthetic
- Latent hyperthyroidism
- Kidney failure (creatinine value > 1.5)
- IUD in situ
- Wish to have more children
- Immunosuppression

Absolute contraindications

Clinical

- Suspected malignancy (the overall risk of an unrecognised uterine malignancy - including uterine sarcomas - is stated in the current literature to be between 0,09 and 0,18 % in patients who have undergone surgery for fibroids)
- Pregnancy
- Acute genital infections
- Manifest hyperthyroidism or florid thyroiditis with hyperthyroidism without thyrostatic treatment, either scheduled or started iodine radiotherapy, if contrast containing iodine is used

Results

In the medium term, UAE leads to a clear improvement in fibroid symptoms (intensified and/or prolonged periods, pressure pains and pain on urination) in approx. 80 to 85 % of embolized patients. Patient satisfaction with the treatment result is very high, as is readiness to recommend the procedure. Serious complications or those requiring treatment are rare.

Data from prospective randomized studies (EBM level I and II), case studies and data from registries have confirmed UAE as an established treatment procedure. The standardized procedure and technical descriptions with guidelines for safety and quality aspects have been published by Societies for Interventional Radiology. Approval for UAE as a medical service covered by health insurance has been granted in most European countries.

Technical procedure

Fibroid embolization should only be carried out by trained, experienced interventional radiologists. Catheter-based embolization of the uterine arteries is carried out in an x-ray room suitable for interventional procedures (angiography laboratory).

The femoral artery is punctured (usually unilateral access in the right groin) and a catheter is inserted into each of the two uterine arteries in turn, under x-ray control. In order to see the vessels angiographically, a contrast agent is injected via the catheter. The blood vessels supplying the fibroid are only embolized once the catheter is unmistakably located in the relevant vessel. The small gelatin or plastic particles used in most cases feed into the terminal artery of the fibroid and stay there permanently. Embolization is continued until the almost complete blockage of the blood flow to the fibroid. For good clinical success, both uterine arteries need to be embolized. The intervention generally lasts 60 to 90 minutes, depending on the vascular anatomy and any difficulties placing the catheter.

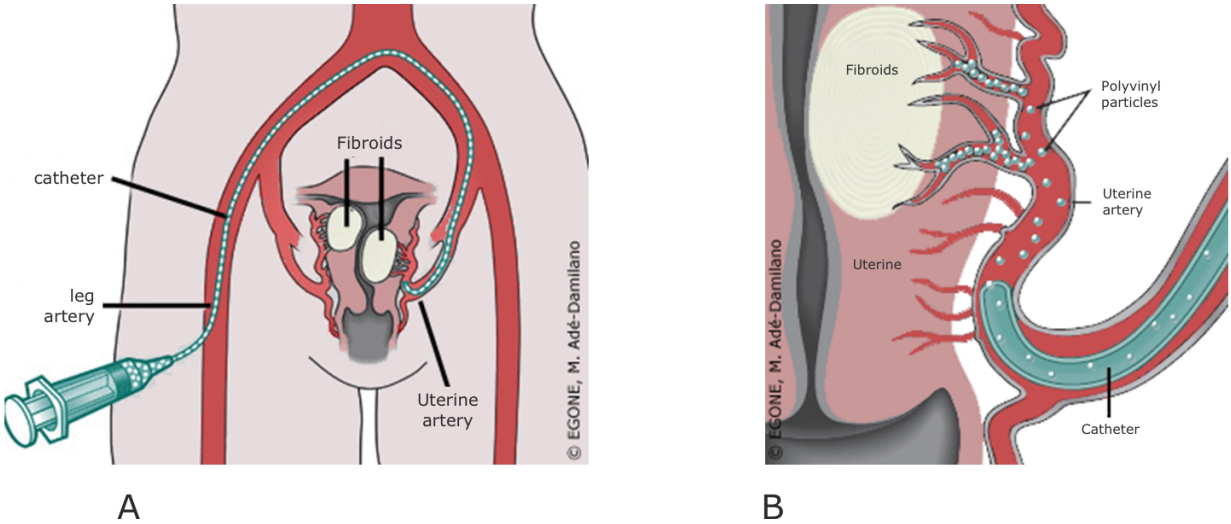

Figure 1: Technical procedure of fibroid embolization.
A – A catheter is inserted into the leg artery via the groin and moved through to the uterine artery.
B – Embolisation of the vascular system supplying the fibroid
Small particles are delivered into the uterine article and stop the blood supply to the fibroid.

How embolization works

The specific objective is to occlude the perifibroid vascular plexus and thus definitively stop the supply of blood to the fibroid. The transarterial embolization of uterine leiomyoma carried out in such a way leads to the hyaline degeneration and shrinkage of the fibroids, and the regression of symptoms. Pathophysiologically, this is attributable to the different vascular architecture of leiomyoma and normal myometrium/endometrium: fibroids are supplied via a large-caliber external vascular plexus with centripetal parenchymal vessels, while the myometrium has many intraparenchymal collaterals.

Normal uterine tissue around the fibroid therefore reacts differently to ischemia and the targeted occlusion of the plexus vessels with particles (embolizing agent) leads to a controlled/selective embolization of the fibroid while maintaining circulation to the surrounding uterine tissue.

Anesthesia

Adequate, efficient analgesia is required to treat intensive ischemic pain brought about peracutely by embolization. Suitable analgesia should be selected according to experience with the various procedures and the logistical requirements of the institution in question.

In principle, five procedures can be used:

1. Opiate analgesia with a PCA pump (patient-controlled analgesia).
2. Regional anesthesia with an epidural catheter.
3. Sedation and intravenous opiate anesthesia without PCA pump.
4. Spinal anesthesia.
5. Presacral block (under radiological control).

In most cases, methods 1 and 2 are used in collaboration with anesthesiologists. Without anesthesia, a presacral block is preferable.

Suitable analgesia and anti-inflammatory treatment are key to avoiding the development of ischemic pain and post-embolization syndrome and ensuring that the patient does not suffer after the intervention. Post-embolization syndrome is characterized by unresponsive pain associated with transient fever and malaise.

Summary and overview of treatment pathway

Fibroid embolization takes place according to the Winterthur Cantonal Hospital treatment pathway as follows:

Table 1: Treatment pathway for myoma embolisation according to Winterthur Cantonal Hospital

Step	What	Type	Who	Remarks
1	Clarification	Consultation (and written informed consent)	Gynecology and radiology	Prior information by referring physician
2	Pre-clarification	MRI (angio)	Radiology	
3	Intervention	Fibroid embolization	Radiology	No surgery
4	Follow-up 2 weeks	Consultation, gyn. check-up	Gynecology	Carried out by referring physician
5	Follow-up 2-3 months	Consultation	Radiology	
6	Follow-up 2 years	Consultation; potentially with MRI (angio)	Radiology	
7	Annual check-up, potential emergencies: Bleeding/pain	Gyn. check-up	Gynecology	Carried out by referring physician

Imaging

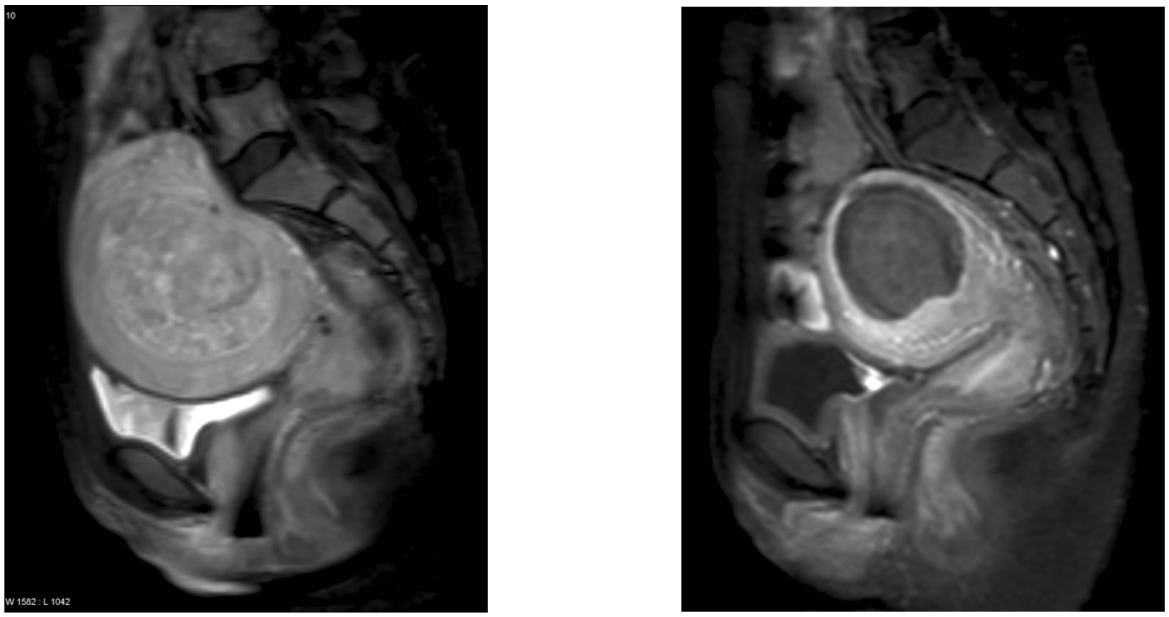

A B

Figure 2: MRI pre-interventional (A) and post-interventional (B) (with kind permission of Prof. Dr. med. Christoph Binkert, Chief Physician, Institute for Radiology, Winterthur Cantonal Hospital).

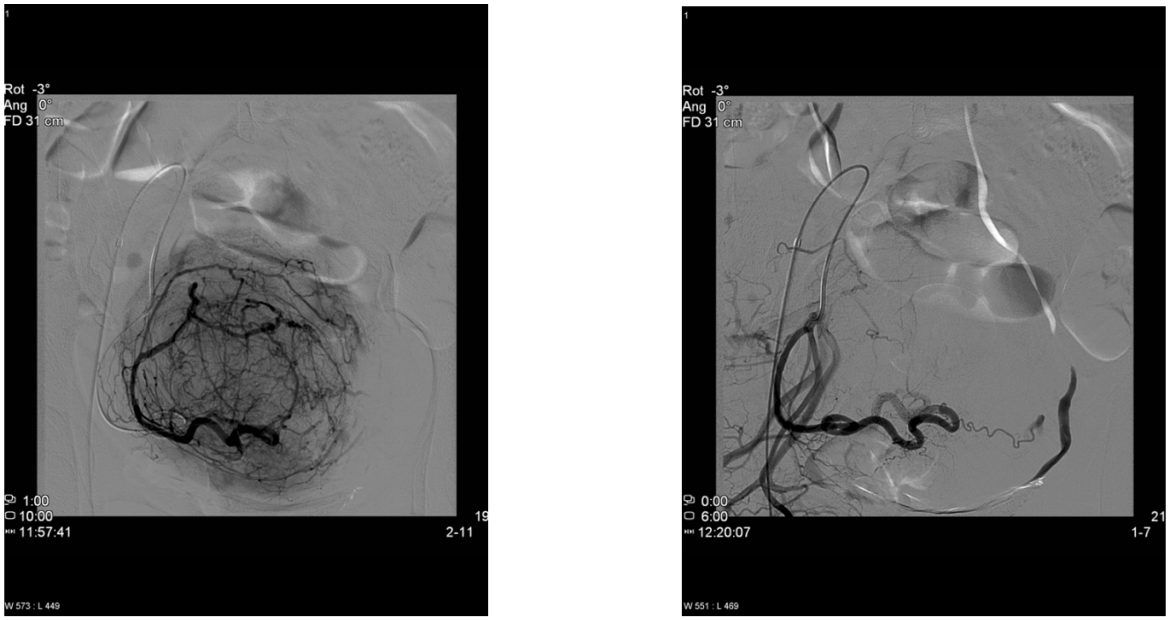

A B

Figure 3: Interventional angiographi (A) and postinterventional (B) (with kind permission of Prof. Dr. med. Christoph Binkert, Chief Physician, Institute for Radiology, Winterthur Cantonal Hospital).

Side effects

The following have been described as relevant and typical side effects of UAE:

- Amenorrhea (3,9–4,3 %)
- Pain (3,6 %)
- Vaginal discharge (3,4 %)
- Angiography-related complications (e.g. inguinal hematoma) (2,9 %)
- Vaginal leakage or discharge of fibroid tissue (1,5–4,7 %)
- Hot flushes and/or ovarian failure (1,4 %)
- Endometritis/myometritis (1,4 %)
- Post-embolization syndrome (0,2–2,9 %)
- Deep vein thrombosis/pulmonary embolism (0,2 %)
- Misembolization (< 0,1 %)

Uterine discharge can be normal in the first weeks after UAE. If discharge is abnormal, infection diagnostics and treatment should be carried out. Menorrhagia, cramp-like lower abdominal pain and leakage of tissue can occur, in particular with submucosal fibroids. Depending on the clinical symptoms and imaging, a hysteroscopic fibroid resection or vaginal fibroid ablation, as for a fibroid in statu nascendi, can be indicated. If there is an increased risk of thrombosis, prophylactic thrombosis prophylaxis makes sense. Antibiotic prophylaxis can also be indicated if there is an increased risk of infection.

Aftercare and check-ups

After embolization, the catheter is removed and the puncture site is closed with a compression bandage, which is left in place for four hours. Generally, patients stay in hospital for one night after this 60 to 90 minute intervention and require suitable, i.e. not restrained, analgesia for the first 30 to 36 hours. A gynecological check-up within the first 6 weeks is recommended, with check-ups by the interventional radiologist after 3 months and 2 years.

Economic assessment

The cost of fibroid embolization is comparable to that of fibroid enucleation. Abdominal hysterectomy is by far the most expensive intervention. The frequency of conservative (organ-conserving) operations with laparoscopic myomectomy/ enucleation or laparoscopic and hysteroscopic removal is only limited to 6 to 10 % of cases and embolization is generally preferred.
An advantage of UAE is that smaller fibroids can be treated as compared to the treatment of enucleation. The rate of recurrence with fibroid enucleation is therefore higher than with UAE. The economic comparison with abdominal hysterectomy should therefore be in the foreground. According to four clinical studies in the USA and Canada between 2001 and 2004, the direct costs of fibroid embolization are lower than both hysterectomy and myomectomy, particularly due to lower hospitalization costs. The cost assessment in Switzerland is comparable with the information from the literature. The cost is also dependent on the price and amount of embolization particles and diagnostics, in particular MR-angiography. For indirect costs, UAE quickly fares better due to the shorter hospitalization, shorter time off work and rapidly normal quality of life. In Europe, also a comparison of UAE and laparoscopic hysterectomy is relevant. Here, the costs of both methods are likely similar, although there is no direct comparable data.

Literature

Nr.	Title	Author	Journal	Volume	Pages
[B01]	Uterine artery embolization vs hysterectomy in the treatment of symptomatic uterine fibroids: 5-year outcome from the randomized EMMY trial	Van der Kooij SM, Hehenkamp WJ, Volkers NA, Birnie E, Ankum WM, Reekers JA	Am J Obstet Gynecol	203(2)	105.e1-13
[B02]	Uterine artery embolization vs hysterectomy in the treatment of symptomatic uterine fibroids: 5-year outcome from the randomized EMMY trial	Van der Kooij SM, Hehenkamp WJ, Volkers NA, Birnie E, Ankum WM, Reekers JA	Am J Obstet Gynecol	203(2)	105.e1-13
[B03]	Uterine Artery Embolization (UAE) for Fibroid Treatment - Results of the 7th Radiological Gynecological Expert Meeting	Kröncke T, David M	Rofo	191(7)	630-634

Nr.	Title	Author	Journal	Volume	Pages
[B04]	Quality improvement guidelines for uterine artery embolization for symptomatic leiomyomata	Hovsepian DM, Siskin GP, Bonn J, Cardella JF, Clark TW, Lampmann LE, Miller DL, Omary RA, Pelage JP, Rajan D, Schwartzberg MS, Towbin RB, Walker WJ, Sacks D	J Vasc Interv Radiol	20	193-199
[B05]	Outcomes from leiomyoma therapies: comparison with normal controls	Spies JB, Bradley LD, Guido R, Maxwell GL, Levine BA, Coyne K	Obstet Gynecol	116(3)	641-652
[B06]	Radiation exposure and uterine artery embolization: current risks and risk reduction. Uterine artery embolization for treatment of leiomyomata: long-term outcomes from the FIBROID Registry	Tse G, Spies JB	Tech Vasc Interv Radiol	13(3)	148-153

Nr.	Title	Author	Journal	Volume	Pages
[B07]	Fibroid Registry for Outcomes Data (FIBROID) Registry Steering Committee and Core Site Investigators	Goodwin SC, Spies JB, Worthington-Kirsch R, Peterson E, Pron G, Li S, Myers ER	Obstet Gynecol	111(1)	22-33
[B08]	What evidence should we demand before accepting a new embolic material for uterine artery embolization?	Spies JB	J Vasc Interv Radiol	20(5)	567-570
[B09]	Uterine fibroid embolization	Goodwin SC, Spies JB	N Engl J Med	13;361(7)	690-697
[B10]	Frequency and extent of uterine perfusion via ovarian arteries observed during uterine artery embolization for leiomyomas	Abbara S, Nikolic B, Pelage JP, Banovac F, Spies JB	Am J Roentgenol	188(6)	1558-1563

Nr.	Title	Author	Journal	Volume	Pages
[B11]	Myomas and reproductive function	Practice Committee of American Society for Reproductive Medicine in collaboration with Society of Reproductive Surgeons	Fertil Steril	90	125-130
[B12]	Fertility after bilateral uterine artery embolization in a sheep model	Laurent A, Pelage JP, Wassef M, Martal J	Fertil Steril	89	
[B13]	Embolization of uterine fibroids and infertility: is a clinical trial conceivable?.	Fauconnier A, Pelage JP, Lacombe P, Ville Y	Gynecol Obstet Fertil	32(9)	818-824
[B14]	Quality control and quality of life after uterine fibroid embolization: long-term results	Hirzel F, Hess T, Zollikofer C	Gynakol Geburtshilfliche Rundsch	48(2)	84-93
[B15]	terine artery embolization for symptomatic uterine fibroids	Gupta JK, Sinha A, Lumsden MA, Hickey M	Cochrane Database Syst Rev		

Nr.	Title	Author	Journal	Volume	Pages
[B16]	Uterine artery embolization and its effect on fertility	Mohan PP, Hamblin MH, Vogelzang RL	J Vasc Interv Radiol	24(7)	925-930
[B17]	Uterine-sparing minimally invasive interventions in women with uterine fibroids: a systematic review and indirect treatment comparison meta-analysis	Panagiotopoulou N, Nethra S, Karavolos S, Ahmad G, Karabis A, Burls A	Acta Obstet Gynecol Scand		