Last update: January 2026

Cervical dysplasia

Author: Prof. Dr. med. Mathias Fehr

Chefarzt Gynäkologie & Geburtshilfe, Ärztliche Leitung Brustzentrum Thurgau, Kantonsspital Frauenfeld, Spital Thurgau AG

Co-Author(s): Prof. Dr. med. Patrick Petignat

Authors of former script versions: Dr. med. Brigitte Frey Tirri

Introduction

Unlike ovarian cancer, cervical cancer and its precancerous, cervical dysplasia, are "accessible" to clinical examination due to their anatomical location and thus can be identified at an early stage.

For the uterine cervix, the latency period from preinvasive stages to invasion or metastasis is estimated to be 5 to 10 years. This means that there is a window of opportunity of almost a decade during which cancer prevention (screening with cervical smear or laboratory testing for the human papillomavirus (HPV)) can allow cervical dysplasia to be identified and treated before it becomes invasive.

Diagnosis of cervical cancer peaks between 35 and 45 years of age. Thanks to cervical cancer screening, the precancerous stages of cervical cancer can be identified and treated before they develop into invasive cancer. Cervical dysplasia is therefore typically diagnosed in patients between 25 and 35 years of age.

Human papillomavirus (HPV) and cervical dysplasia

Persistent infection with oncogenic human papillomavirus (HPV) is an essential condition for the development of high-grade cervical dysplasia and thus cervical cancer. HPV-negative adenocarcinomas of the cranial cervical canal are very rare.

There are over 130 different types of HPV, approx. 30 of which are found in the anogenital region. There are low-risk HPVs that mainly cause genital warts and are only rarely found in cancers. The 12 oncogenic HPV types cause precancerous lesions of the cervix, vagina, vulva, anus and oral mucosa (oncogenic HPV types: 16, 18, 31, 33, 35, 39, 45, 51, 52, 58, 59).

Epidemiology of oro-genital and anal HPV infection:

- HPV is transferred via sexual contact or close skin contact (e.g. petting, orogenital kissing), including oral sex without penetration. It is the most common sexually transmitted infection.
- Condoms only have a limited protective effect (approx. 50 %).
- HPV infection can also be transferred “non-sexually” from mother to child

vertically during pregnancy or horizontally via breastfeeding and kissing.
- HPV infection is very common. 70 to 80 % of all women and men will be infected at some time point. Between 15 and 45 % of all women are likely to come into contact with oncogenic virus types.
- In approx. 90 % of cases, HPV infection is transient and heals spontaneously within 3 years without symptoms.
  [P03]

In women, the prevalence of HPV infection is highest immediately after becoming sexually active (prevalence approx. 25 %) and slowly declines after 30 years of age to under 10 %. In men, the incidence of HPV infection remains high at around 60 % from 18 to 70 years. 56 % of HPV infections are caused by non-oncogenic HPV types and 44 % by oncogenic HPV types. The persistence of HPV infection and the development of high-grade precancerous stages depends on the type of HPV. The risk of high-grade cell changes with HPV 16 (20 %) is seven times higher than that of an oncogenic HPV type that is not 16 or 18 (3 %) [P10].

HPV viruses are protein-enveloped double-stranded DNA viruses that are omnipresent. There are different HPV viruses. Some are found only in humans, and others also in animals. They have a strong tissue tropism, and can only be found in the epithelial cells of the skin and mucosa. They have high environmental stability. [P10]

Table 1: Classification of anogenital HPV types as per 2024 IARC classifications

Risk level	HPV type
1a	16, responsible for approximately 60% of squamous cell carcinomas
1b	18 and 45, responsible for 15 % respectively 5 % of squamous cell carcinomas
1c	Related types, which together represent 15 % of squamous cell carcinomas: 31, 33, 35, 52, 58
1d	Low oncogenic types, together responsible for 5% of squamous cell carcinomas: 39, 51, 56, 59
Low risk	6, 11, 40, 42, 43, 44, 54, 61, 72, 81 etc.

The number of HPV types is constantly increasing as more can be isolated using PCR testing.

Digression nomenclature/classification systems

In Switzerland, cytological changes of the cervical are classified according to the Bethesda System 2014 (cytology) whereas histological specimens of the cervix are classified according to the 2014 WHO classification. The Munich Nomenclature III (Papanicolaou system) popular in Germany is mentioned additionally by most laboratories. The nomenclature distinguishes between squamous and glandular cell changes. The latter are rarer than squamous cell changes, but increasing.

Table 2: Squamous cell changes (Legend: ASCUS – atypical squamous cells of undetermined significance; ASC-H – atypical squamous cells (can not exclude HSIL); HSIL – high grade squamous intraepithelial lesion; LSIL – low grade squamous intraepithelial lesion; NILM – negative for intraepithelial lesion or malignancy (normal finding))

Cytological squamous cell findings: Bethesda nomenclature	Cytological squamous cell findings: Munich III	Histological squamous cell findings: WHO 2014	Histological squamous cell findings: WHO 2003
NILM	I,IIa		
ASCUS	II-p		
LSIL	IIID1	LSIL	CIN1 mild dysplasia
ASC-H	III-p		
HSIL	IIID2 IVa-p IVb-p	HSIL	CIN2 moderate dysplasia CIN3 severe dysplasia/ carcinoma in situ HSIL, invasion cannot be excluded.

Table 3: Glandular cell changes (Legend: AGC-fN – atypical glandular cells favor neoplastic; AGC – atypical glandular cells not otherwise specified, sometimes further divided into AGC endocervical (III-g) and AGC endometrial (III-e); AIS – adenocarcinoma in situ; NILM – negative for intraepithelial lesion or malignancy (normal finding))

Cytological squamous cell findings: Bethesda nomenclature	Cytological squamous cell findings: Munich III	Histological squamous cell findings: WHO 2014	Histological squamous cell findings: WHO 2003
NILM	I,IIa		
AGC Atypical glandular ceslls (-nos) AGC-endocervical AGC-endometrial	II-g III-g III-e		
AGC-(f)N	III-x		
AIS	Iva-g IVb-g AIS, Invasion cannot be excluded.	Adenocarcinoma in situ	Adenocarcinoma in situ

LSIL, CIN1 (mild cervical dysplasia)

CIN = Cervical intraepithelial neoplasia as histological diagnosis, LSIL as cytological diagnosis

- LSIL may be caused by HPV infection with a non-oncogenic type (lacking integration of HPV DNA into the host cell genome, low-risk HPV type) or HPV infection with an oncogenic HPV type (in a small percentage of cases with integration of the HPV DNA into the host cell genome, high-risk HPV type).
- In most cases, LSIL is simply the morphological expression of a transient HPV infection - in which case it is inconsequential and not precancerous.
- Only LSIL due to high-risk HPV types - in particular with integration of the viral DNA - are often persistent or can develop into high-grade dysplasia with oncological consequences.

LSIL due to non-oncogenic HPV types always return to normal - provided that the immune response is intact!

If the immune response is not intact, as with patients living with HIV or a transplant, lifelong LSIL is possible even with non-oncogenic HPV types.

HSIL, CIN2/3 (moderate and severe dysplasia)

- CIN2/3 are precancerous stages and are caused by persistence of high-risk HPV types. In clinical practice, separation of CIN2 from CIN3 is of particular importance in women of childbearing age. This is because with CIN2, a wait and see approach is preferred for up to two years with careful colposcopy and histological monitoring.
- Histopathologically, the difference between CIN3 and carcinoma in situ is not reproducible.

The annual incidence of high-grade cervical intraepithelial neoplasia (HSIL, CIN2 and CIN3) is 1,5 per 1000 women. [P01]

> Moderate and high-grade cervical dysplasias have oncological significance as progressive precancerous lesions. HSIL, CIN2/3, should be interpreted as stages of an initiated (but not (yet) irreversible) malignant transformation! Persistence and regression are still possible.

Table 4: Regression, persistence and progression of histological CIN

CIN	Spontaneous regression after 2 years	Persistence at same stage for 2 years	Progression: CIN 3	Progression: invasive CA
CIN1	60 %	30 %	5–10 %	< 1 %
CIN2	50 %	32 %	18 %	0,4 %
CIN3	30 %	40–45 %	---	25–30 %

Note: The aforementioned figures are in part estimations, as few prospective studies are available and those that are have been carried out over a limited time period. In addition, the regression rate depends on age, nicotine use and immunosuppression. [P07][P08]

The natural progression of HSIL depends not only on the HPV type but also on age. This means regression is rarer and progression more common in women older than 30 years. A meta-analysis showed 60 % regression of CIN2 within two years for women under 30 and only 44 % regression for those over 30. [P07]

The progression rate for individuals cannot be calculated!

The incidence of adenocarcinoma in situ (AIS), 1,25 per 100’000 women per year, is much lower than that of HSIL, CIN3 (41,4/100’000).

Progression to cervical cancer

Thanks to cytological screening, younger women are more likely to be diagnosed with precancerous cervical dysplasia. Diagnosis of cervical cancer is more likely from 40 years of age.

Risk factors for cervical cancer:

- Persistent HPV infection is the most important tumor promoter, together with individual predisposition (e.g., HLA system).
- HPV infection with oncogenic HPV types (see below) is very common in those who are sexually active: 50 % of all women within 5 years of becoming sexually active
- But even most “oncogenic” HPV infections heal without consequence (90 %)!
- In 5 to 10%, persistent infection will lead to HSIL CIN2/3 with potential malignant transformation within approx. two years.
- How long a HSIL CIN3 will take to transform into an invasive carcinoma varies greatly and can be up to ten years, as estimated on the basis of different peak ages.
- 99,7% of cervical cancers (and 100 % of HSIL CIN3 and most adenocarcinoma in situ) are high-risk HPV-positive.
- There are rare cervical adenocarcinomas that are not associated with HPV (mostly of the upper cervical canal).

An infection with oncogenic HPV types must be persistent in order to develop into high-grade cervical dysplasia (CIN2/3).

Contrary to earlier opinion, HPV persistence must not necessarily lead to LSIL or CIN1. Morphologically, high-grade dysplasia can occur directly without first going through the LSIL stage.

Other non-causal tumor promoters:

- Smoking
- Vitamin deficiency (carotenoids, vitamin C, folic acid)
- Immunodeficiency (e.g. HIV, history of kidney transplantation)
- Long-term oral combined use of ovulation inhibitors
- Risk factors for HPV infection (frequent changing of sexual partner, beginning

sexual activity at a young age)

Oncogenic transformation in squamous cell cervical cancer

In some women, high-risk HPV types resist the immune response, persisting in the epithelial cells of the cervix, vulva, vagina, perianal area and mouth. Viral DNA integrates into the host cell genome. With low-risk HPV types, the HPV genome remains epigenetic.

- Clinically, virus-induced CIN2 is initially found, followed by CIN3 on progression. These stages of dysplasia are the expression of genomic changes in the host cells and indicate the latent oncogenic transformation.
- Further trigger mechanisms then take CIN3 past the point of no return. The oncogenic transformation is irreversible. The new features are invasiveness and metastasis. It is not currently possible to predict which cases of CIN3 will develop into cancer. This step takes place in approx. 30 % of CIN3.
- The malignant degeneration of HPV-infected epithelial cells is associated with overexpression of the viral oncogenes E6 and E7. These inactivate tumor suppressor genes.

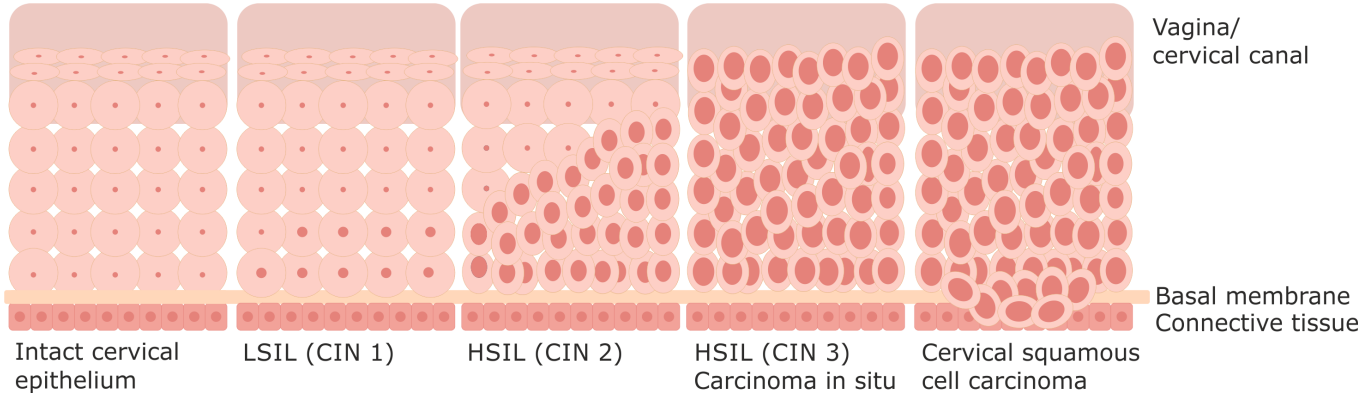

Figure 1: Infection with high-risk HPV types (following [P09]). [P09]

Cervical cancer must be understood as a possible consequence of persistent infection with high-risk types of HPV:

- The most oncologically dangerous high-risk HPVs are 16 and 18
- Rarer high-risk HPVs: 31, 33, 35, 39, 45, 51, 52, 55, 56, 58, 59, 68, 73, 82

Prevention

Primary prevention with HPV vaccination

See also expert letter Nr. 44 (about HPV vaccination) of Swiss Society for Gynecology and Obstetrics (SGGG) (available in German and French).

gynécologie Suisse SGGG – expert letter

One nine-valent HPV vaccine is available in Switzerland which protects against the two most common carcinogenic HPV types, 16 and 18, as well as the additional high-risk HPV types 31, 35, 45, 52 and 58. It also protects against the two most common low-risk causes of warts, 6 and 11.
Vaccination against the 7 high-risk HPV types prevents approx. 90 % of cervical cancers. As the vaccine is purely prophylactic, its benefit is greatest when vaccination is carried out before infection. This is why the Swiss Federal Office of Public Health recommends vaccination before the beginning of potential sexual activity, i.e. in adolescents aged 11 to 14. In this period, only two vaccinations are required (0 and 6 months). In Switzerland these vaccinations are provided by cantonal vaccination protocols.

- In addition, HPV vaccination is recommended as an additional vaccination for all young men and women up to 26 years old. This is also covered by health insurance under cantonal vaccination protocols in Switzerland. However, from the age of 15, three vaccinations at 0, 2 and 6 months are required.
- The nine-valent vaccine is also approved for the vaccination of boys and young men for the prevention of premalignant lesions and malignant cancers of the vulva, vagina, anus and oropharynx as well as genital warts.

Efficacy of HPV vaccination

The vaccine contains virus-like particles with L1 capsid protein antigens against the aforementioned virus types. The L1 proteins do not contain any virus particles. They are produced via biotechnology in yeast cells (nine-valent vaccine) using recombinant DNA technology and spontaneously assemble into empty capsids that do not contain virus genomes.

Immunogenicity is very high and causes much higher blood antibody levels than a natural infection induces. It has so far been proven that these antibody levels remain high for over 10 years. It is therefore assumed that immunization lasts for a lifetime. Immunization to all vaccine-specific HPV types is excellent, which is astonishing for a vaccine for an intraepithelial infection. The induced antibodies can obviously neutralize the virus before it enters the epithelial cells. All studies have shown the adverse effects of the vaccine to be negligible, as is to be expected with an inactivated/protein vaccine.

Protective effect of nine-valent HPV vaccine against lesions caused by the HPV types contained in the vaccine (CIN2/3, adenocarcinoma in situ, cervical carcinoma, VIN2/3, VAIN 2/3, vulvar and vaginal carcinoma) is very high at 97,4 %.

Secondary prevention with cervical cytology and colpyscopy

The goal of early cancer detection is to identify and eliminate precancerous lesions which might lead to cervical cancer. Most cervical dysplasias do not show clinical symptoms, which is why screening is so important. Between 5 and 7 % of women will develop an HSIL requiring treatment by their 40th birthday. The goal of cancer screening with cytology and, in case of pathological cytology, colposcopy and possible biopsy, is to identify and remove such precancerous lesions.
Repeated cervical cytology sampling (“smear”) is a highly effective measure for identifying cervical dysplasia and early cervical cancers. The sensitivity of a single smear is low at 66 %, but the specificity is high at 96 %, and the sensitivity increases with repeated sampling.

For cervical cytology, two samples are taken: one from the ectocervix (with a wooden spatula or a special sampling brush), and one from the cervical canal with a cytobrush.

Sampling using a cotton swab is obsolete as most cells remain in the cotton. The removed cells are either “smeared” on a slide, fixed in 90 % alcohol and sent for cytological staining (Papanicolaou), or the brush/spatula is deposited into a liquid. The liquid is filtered in a laboratory in order to place the cells on a slide in a single layer (thin layer cytology).
Both methods are equivalent if sampling is carried out correctly.

Expected dysplasia following abnormal cytology:

Table 6: Frequency of abnormal cervical cytology for 50’000 smears and correlation with CIN or invasive cancer (legend: ASC – atypical squamous cells; ASC-H – atypical glandular cells, can not exclude high grade lesion; AGC – atypical glandular cells; -NOS – not otherwise specipied; -US – uncertain significance)

Cytological diagnosis	Frequency of abnormal smears 7,0 %	Association with histological CIN2/3	Association with invasive Ca
ASC	ASC-US 4,1 %	5–17 %	0,1 %
ASC	ASC-H 0,3 %	24–94 %	0,2 %
LSIL	1,6 %	15–30 %	0,2 %
HSIL	0,45 %	70–75 %	1,0–2,0 %

Cytological diagnosis	Frequency of abnormal smears 7,0 %	Association with histological CIN2/3	Association with invasive Ca
AGC	AGC 0,3 % AGC-NOS AGC-favor neoplasia	9–54 % 9–41 % 27–96 %	1,9 % – –

In case of abnormal cytology, colposcopy (magnified visual inspection) of the vulva, vagina and ectocervix is recommended in Switzerland. For this, the cervix is swabbed with 3 to 5% acetic acid, which causes para or hyperkeratotic epithelium to swell and appear white due to increased light scattering. Pathological vessels can also be identified. Pathological colposcopy findings can be clarified with targeted biopsy.

Thanks to this screening, the incidence of cervical cancer in industrialized countries has declined sharply with a consistent or increasing incidence of cervical dysplasia.

In Switzerland, the incidence of cervical cancer has decreased by 28 % since the 1980s, from an average of 440 cases per year (1980 to 1983) to 220 cases per year (2018 to 2022), while the incidence of precancerous stages is estimated to have remained the same.

Due to the frequency of HPV infection, suspicious cancer smears are common, although two thirds of HPV infections do not cause cytological changes: approx. 6 to 7 % of all cervical cytology tests are assessed as suspicious.

Secondary prevention with a HPV test (primary HPV screening)

12 major screening studies with a total of over 77’000 women have shown that the sensitivity of the HPV test for precancerous stages and cancer is higher than that obtained with the conventional Pap smear or thin-layer cytology. At 63 to 100 %, the sensitivity of the HPV test for CIN2/3 was higher in each individual study than that of the conventional smear (40 to 86 %) or thin-layer cytology (38 to 94 %).
HPV screening is used to identify patients with a HPV infection, not precancerous lesions. The positive predictive value of the HPV test with regard to CIN2/3 is therefore between 4 and 23 % depending on the population investigated. However, the negative predictive value is very high at 98,2 to 100 %.
For women aged over 30, HPV screening is superior to cytological screening. However, it requires careful explanation, so that high-risk HPV positive patients do not confuse a high-risk HPV infection with cervical cancer and worry unnecessarily. A second important condition for good screening using the HPV test is using a validated HPV test.

Currently, primary HPV screening is not yet covered by Swiss health insurance (as of 2025).

It is important to differentiate primary HPV screening from:

- Secondary HPV screening: Carrying out a screening HPV test in addition to cytology is sensible in patients > 30 years, if the screening interval will be extended in case of negative HPV test. This is covered by most Swiss health insurance companies.
- Postoperative HPV screening (test of cure): Follow-up care after excision of an HSIL should include co-testing with a validated HPV test and cytology. Co-testing is far superior to cytology alone in predicting a recurrence of dysplasia. See also expert letter Nr. 50 (about recommendations for cervical cancer screening) of Swiss Society for Gynecology and Obstetrics (SGGG) (available in German and French).

gynécologie Suisse SGGG – expert letter

Diagnosis

The diagnosis must be based on histology (tissue biopsy) not just cytology! Clinical and cytological suspicion, together with one or more of the following tests, help guide the practitioner:

- Speculum: The examination always begins with an examination of the vulva, then the speculum is inserted into the vagina with careful inspection so the cervix is visible. Pronounced cervical dysplasia is visible to the naked eye, and appears as a noticeably distended irregular cervical surface.
- Colposcopy of the ectocervix and vagina: Precancerous growths can be identified with a microscope after application of acetic acid.
- If significant changes are seen, punch biopsies of the suspicious sites must be taken.
- Endocervical findings can only be identified with cervical curettage.
- A HPV DNA or RNA test is not indicated if CIN2/3 or carcinoma is already diagnosed. (HPV test will be positive anyway, "what type it was" is no longer relevant).

Treatment

See also expert letter Nr. 50 (about recommendations for cervical cancer screening) of Swiss Society for Gynecology and Obstetrics (SGGG) (available in German and French) as well as the algorithms based on expert letter Nr. 50.

gynécologie Suisse SGGG – expert letter

In case of CIN1, a follow up visit is scheduled after 6 months. Due to the high regression rate, regular 6-monthly colposcopic monitoring of mild dysplasia allows a watch and see period of at least 2 years. . Given the frequency and high regression rate of cytological LSIL and histological CIN1, unnecessary excisions (and their complications) must be avoided at all costs.

CIN2: Particularly for women of childbearing age who wish to have children in the future, regular colposcopies should be carried out, as the risk of preterm birth increases after conization and the spontaneous healing rate is 50 %.

CIN3 is a precancerous lesion requiring treatment. A wait and see strategy in CIN3 should only be recommended in women ≤ 24 years and only under colposcopic control..

The treatment involves excision for histological examination.

LSIL, CIN1 have a high rate of spontaneous remission: In a Brazilian study, 90 % of cytological LSIL regressed within 24 months. In a Dutch study lasting four years, all LSIL patients with non-oncogenic HPV types experienced regression, as did 70 % of LSIL patients with oncogenic HPV infection [P02]. In adolescents, the regression rate of LSIL within 36 months is 91 % regardless of HPV type [P03]. In case of colposcopy biopsy-confirmed CIN1, the risk of development into CIN2/3 within the subsequent two years is only 13 %. [P02][P03]

The preferred treatment of CIN2/3 is conization which means excision of the visible lesion using a loop wire under colposcopic guidance (LLETZ: large loop excision of the transformation zone, LEEP conization: loop electrosurgical excision procedure), as this can be carried out quickly, blood loss is minimal, and the transformation zone remains visible after healing of the wound bed.
The width of the loop electrode is adapted to the extent of the dysplasia.

Scalpel or laser conization leads to greater tissue loss and thus a higher risk of incompetent cervix leading to preterm birth and neonatal morbidity and mortality in a subsequent pregnancy, as well as more frequent cervical canal stenosis and thus more difficult follow-up care.

Recurrence rate after conization: LEEP conization has a recurrence rate of less than 5 %. If the resection margins are free from CIN, the recurrence rate is less than 2 %. However, even if the resection margins are CIN-positive, the recurrence rate is still only 13 %. This means that even with CIN-positive resection margins, a non-surgical approach with cytological, molecular biology (HPV test) and colposcopy check-ups every six months after conization can be taken. The probability of regression of residual CIN is over 85 %. [P05]

Treating adenocarcinoma in situ

- In case of a cytological or histological diagnosis of adenocarcinoma in situ (AIS) of the cervix, conization with endocervical curettage is indicated to rule out invasive adenocarcinoma.
- For women not intending a further pregnancy, hysterectomy is also recommended for excision with negative margins due to the high recurrence rate.

If the patient wishes for further pregnancies and the endocervical curettage reveals involvement of AIS, re-excision is recommended. However, in this situation a re-assessment without repeat surgery 6 months later with colposcopy, cytology, HPV test and endocervical sampling is also acceptable.

If conization margins are not free of AIS, repeat conization is recommended even if a hysterectomy is planned. This is because invasive lesions in the remaining AIS cannot be ruled out and are relatively common. If a hysterectomy is performed directly on AIS that has not been excised with negative margins and an invasive adenocarcinoma is found, the sentinel lymph node excision method becomes impossible and an unnecessary pelvic lymphadenectomy has to be performed. Therefore, it is best to discuss the case with an interdisciplinary tumor board.

Complications of conization

The most serious complication of conization is preterm birth in a subsequent pregnancy. This risk has been proven for all types of conization, but is significantly lower with LEEP conization. The rate of premature rupture of membranes with preterm birth in the control group was 4 %, in the laser evaporation group 5 %, with LEEP conization 9 % and with laser conization 19 %.

The rate of premature rupture of membranes with preterm birth depends on the height and volume of the excised tissue cone: With a cone height of 1 to 10 mm, it is 6 %, with a height of 11 to 16 mm 9 % and with a cone height of over 16 mm 18 %. [P04]

Follow-up

After treatment of CIN2/3, there is a long-term increased risk of developing an invasive cervical cancer in this patient group of 56 per 100’000 women over at least 20 years versus 5,6/100’000 in the normal population. Lifelong cancer screening according to national guidelines is therefore necessary for patients with treated dysplasia.

Procedure during pregnancy

Cervical cancer screening should not be modified due to pregnancy. Screening with HPV testing in the first trimester results in a higher incidence of high-risk HPV infection than in age-matched non-pregnant control patients (20,2 % vs. 11,7 %) [B03]. Cytological screening is therefore preferred over HPV-based screening. Ayers spatula or Cytobrush are permitted for smear collection with low rates of spontaneous abortion, premature rupture of membranes, or preterm birth within 2 weeks (2 studies) [B04, B05, B06, B07]. The absence of endocervical cells does not change the management. [B03][B04][B05][B06][B07]

There is a consensus that the indications for colposcopy with biopsy during pregnancy are the same as those outside of pregnancy. Due to physiological changes of the cervix during pregnancy [P11], colposcopic assessment can be more difficult and should therefore be performed by experts in a dysplasia clinic. Some authors find a trend toward overestimating colposcopic findings during pregnancy towards high-grade changes [P12]. In contrast, for experienced examiners, colposcopic findings correlate well with cytological and histological results [B08]. [B08][P11][P12]

A recent meta-analysis shows that the mode of delivery (cesarean section versus vaginal delivery) has no influence on the regression or progression of CIN postpartum [B09]. The presence of CIN2/3 should therefore not influence the decision regarding the mode of delivery. However, invasive cervical cancers diagnosed during pregnancy have a higher risk of recurrence after vaginal delivery compared to cesarean section (Odd Ratio 6.91; 95% CI, 1.45-32.8) [B10]. [B10]

Management of pregnant patients with HSIL and visible transformation zone

If colposcopy suggests a high-grade dysplasia, a colposcopically directed punch biopsy should be performed to rule out (micro-)invasive carcinoma as far as possible. Cervical punch biopsies are not associated with an increased risk of preterm birth or cesarean section rate. Excessive bleeding after punch biopsy is no more common during pregnancy than outside of pregnancy [B11, B12]. [B11][B12]

Punch biopsy with histological CIN2/3

In the absence of invasion, a repeat colposcopy in 12 to 24 weeks is recommended. A meta-analysis combined biopsied CIN2 and CIN3 and calculated a progression rate during pregnancy of 1 %, persistence of 59 %, and regression of 40 % [B13]. As outside of pregnancy, smoking, older age, and HPV 16 infection were associated with lower spontaneous healing. In the case of CIN2, a watchful waiting approach for up to 2 years is an option [B14]. [B14]

Cytological LSIL or punch biopsy with CIN1

If the assessment indicates a low-grade dysplasia (cytological, colposcopical, or histological), further colposcopic or cytological examinations during pregnancy are not indicated, as spontaneous regression is very likely in up to 86 % of cases and progression to carcinoma during pregnancy is very rare [B08, B15]. A re-evaluation should take place 6 to 8 weeks after delivery [B16]. The presence of low-grade dysplasia has no influence on decision-making regarding the mode of delivery. [B08][B15][B16]

Management of pregnant patients with HSIL and transformation zone not visible

A repeat colposcopy is performed in 6 to 12 weeks. Endocervical curettage is contraindicated during pregnancy [B16]. No conization should be performed during pregnancy without proof of invasive carcinoma or colposcopic suspicion of invasive carcinoma. Again, the presence of dysplasia has no influence on decision-making regarding the mode of delivery. Re-evaluation with colposcopy 6 weeks after birth [B17]. During postpartum re-evaluation, colposcopy, punch biopsies, and possibly endocervical curettage should be repeated, as there is a possibility of postpartum regression. Therapy is based on the current findings and not on the findings during pregnancy. [B16][B17]

Management of pregnant patients with atypical glandular cells

Cytology with atypical glandular cells always indicates a colposcopy. Multiple biopsies should be performed to increase sensitivity. If there is no colposcopic evidence of an invasive process, a colposcopic follow-up in 12 to 24 weeks is indicated. Postpartum, a colposcopic follow-up should be performed after 4 to 6 weeks. If adenocarcinoma in situ was diagnosed during pregnancy, conization should be performed postpartum, regardless of the current postpartum colposcopic result.

Literature

Nr.	Title	Author	Journal	Volume	Pages	Year
[B01]	ACOG Practice Bulletin no. 109: Cervical cytology screening	American College of Obstetricians and Gynecologists	Obstet Gynecol	114	1409-1420	2009
[B02]	2006 consensus guidelines for the management of women with cervical intraepithelial neoplasia or adenocarcinoma in situ	Wright TC Jr, Massad LS, Dunton CJ, Spitzer M, Wilkinson EJ, Solomon D	Am J Obstet Gynecol	197	340-345	2007
[B03]	Prevalence of human papilllomavirus and genoype distribution in pregnant and non-pregnant women in China	Luo D et al.	Risk Manag Health Policy	14	3147-3157	2021
[B04]	The efficacy and safety of the cytobrush during pregnancy	Orr JW et al.	Gynecol Oncol	44	260-262	1992
[B05]	Safety, efficacy and cost of three cervical cytology sampling devices in a prenatal clinic	Smith-Levitin M et al.	J Reprod Med	41	749-753	1996

Nr.	Title	Author	Journal	Volume	Pages	Year
[B06]	The effectiveness and safety of two cervical cytologic techniques during pregnancy	Stillson T et al.	J Fam Pract	45	159-163	1997
[B07]	Evaluation of the endocervical Cytobrush and Cervex-Brush in pregnant women	Paraiso MF et al.	Obstet Gynecol	84	539-543	1994
[B08]	Cervical dysplasia in pregnancy: a multi-institutional evaluation	Fader A.N, Alward E.K, Niederhauser A et al.	Am J Obstet Gynecol	203(2)	113 e1-6	2010
[B09]	The effect of the delivery mode on the evolution of cervical intraepithelial lesions during pregnancy. A meta-analysis	Douligeris A et al.	J Gynecol Obstet Hum Reprod	51	102462	2022

Nr.	Title	Author	Journal	Volume	Pages	Year
[B10]	Cervical cancer diagnosed shortly after pregnancy: prognostic variables and delivery routes	Sood AK et al.	Obstet Gynecol	95	832-838	2000
[B11]	Colposkcopically directed cervical biopsy during pregnangcy; minor surgical and obstetrical complications and high rates of persistence and regression	Kärrberg C et al.	Acta Obstet Gynecol Scand	92	692-699	2013
[B12]	Perinatal outcomes of pregnant women with cervical intraepithelial neoplasia	He Y et al.	Arch Gynecol Obstet	288	1237-1242	2013
[B13]	Natural history of histologically confirmed high-grade cervical intraepithelial neoplasia during pregnancy: meta-analysis	Chen C et al.	BMJ Open	11	e048055	2021
[B14]	J Low Genit Tract Dis	Perkins RB et al.		24	102-131	2020

Nr.	Title	Author	Journal	Volume	Pages	Year
[B15]	Prognosis and recurrence risk for patients with cervical squamous intraepithelial lesions diagnosed during pregnancy	Kaplan K.J, Dainty L.A, Dolinsky B et al.	Cancer	102(4)	228-232	2004
[B16]	J Low Genit Tract Dis	Massad L.S et al.		17	1-27	2013
[B17]	J Low Genit Tract Dis	Massad Sl et al.		9	146-148	2005

Nr.	Title	Author	Journal	Volume	Pages	Year
[P01]	Diagnoses and outcomes in cervical cancer screening: a population-based study	Insinga RP, Glass AG, Rush BB	Am J Obstet Gynecol	191	105-113	2004
[P02]	Cytological regression and clearance of high-risk human papillomavirus in women with an abnormal cervical smear	Nobbenhuis MA, Helmerhorst TJ, van den Brule AJ et al.	Lancet	358	1782-1783	2001

Nr.	Title	Author	Journal	Volume	Pages	Year
[P03]	Regression of low-grade squamous intra-epithelial lesions in young women	Moscicki AB, Shiboski S, Hills NK et al.	Lancet	364	1678-1683	2004
[P04]	Treatment for cervical intraepithelial neoplasia and risk of preterm delivery	Sadler L, Saftlas A, Wang W, Exeter M, Whittaker J, McCowan L	JAMA	291	2100-2106	2004
[P05]	Does histological incomplete excision of cervical intraepithelial neoplasia following large loop excision of transformation zone increase recurrence rates? A six year cytological follow up	Dobbs SP, Asmussen T, Nunns D, Hollingworth J, Brown LJ, Ireland D	BJOG	107	1298-1301	2000
[P06]	Incidence and clearance of genital human papillomavirus infection in men (HIM): a cohort study	Giuliano AR, Lee J-H, Fullp W et al.	Lancet	377	932-940	2011

Nr.	Title	Author	Journal	Volume	Pages	Year
[P07]	Clinical course of untreated cervical intraepithelial neoplasia grade 2 under active surveillance: systematic review and meta-analysis	Tainio K et al.	BMJ	360	499	2018
[P08]	Natural history of cervical neoplasia and risk of invasive cancer in women with cervical intraepithelial neoplasia 3: a retrospective cohort study	McCredie MRE et al.	Lancet Oncol	9	425-434	2008
[P09]	J of clinical Investigation	Lowy D.R. et al.		116	1167-1173	2006
[P10]	The elevated 10-year risk of cervical precancer and cancer in women with human papillomavirus (HPV) type 16 or 18 and the possible utility of type-specific HPV testing in clinical practice	Khan J	Nat.Cancer Inst			2005

Nr.	Title	Author	Journal	Volume	Pages	Year
[P11]	Pregnancy-related changes: a retrospective review of 278 cervical smears	Michael C.W, Esfahani F.M	Diagn Cytopathol	17(2)	99-107	1997
[P12]	Abnormal cervical cytology in pregnancy: a 17-year experience	Economos K.N, Perez Veridiano I, Delke et al.	Obstet Gynecol	81(6)	915-8.93	1993