Last update: 2015/2016

Ectopic pregnancy (EP)

Author: PD Dr. med. Edward Wight

ehem. Chefarzt Gynäkologie und gyn. Onkologie (pensioniert seit März 2017), Universitätsfrauenklinik Basel

Introduction

- Terminology: Fallopian tube, salpinx and tube are synonyms.
- Salpinx is only commonly used in word compositions (salping-, -salpinx).
- Implantation and nidation are often used synonymously.

Memory aid: Fertilization refers to the encounter and fusion between egg and sperm cell. This usually occurs outside the uterus, in the ampulla of the fallopian tube. The zygote is the fertilized egg. Through the immediate onset of cell division, the zygote becomes the embryo. A distinction is made between its two parts, namely the embryoblast and trophoblast (which later becomes the placenta).

- On Day 6 post-conception, the endometrium is decidualized.
- On Day 6 post-conception, the embryo is at blastocyst stage, in which it reaches implant maturity and implants itself where it currently is situated.

From a physiological standpoint, on Day 6 p.c., the blastocyst has reached the cavity of the uterus and implants itself orthotopically in the endometrium.

Extrauterine pregnancy results from a disturbance of the physiological transport or of the maturation processes during the first week after fertilization.

Definition

Synonyms: Extrauterine pregnancy = ectopic pregnancy (EP)

An extrauterine pregnancy occurs when the blastocyst is implanted outside the endometrium of the uterine cavity.

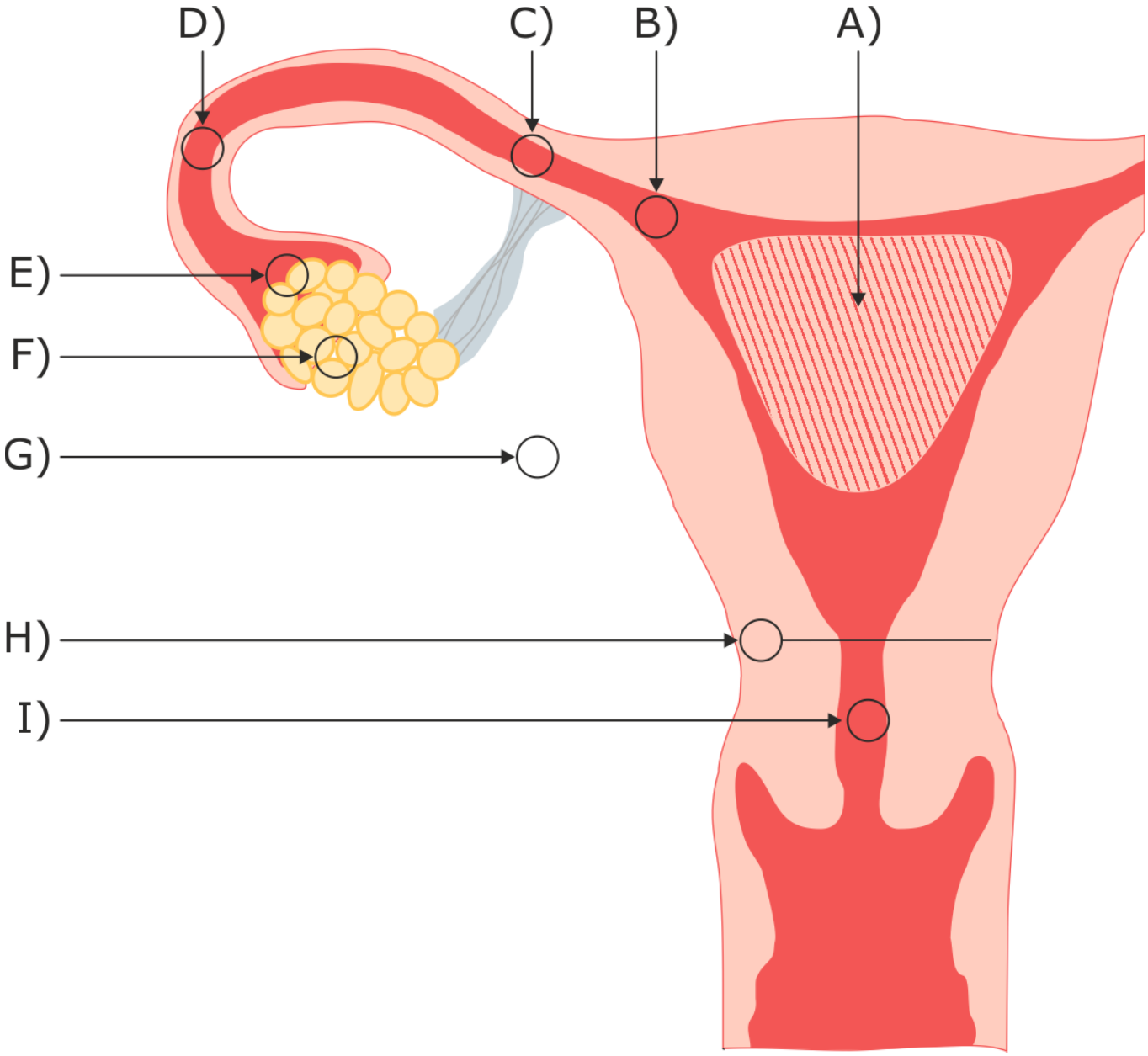

Figure 1

A) Area of normal implantation
B) Interstitial tubal pregnancy
C) Isthmic tubal pregnancy
D) Ampullary tubal pregnancy
E) Fimbrial infundibular pregnancy
F) Ovarian pregnancy
G) Abdominal pregnancy
H) EP in the dehiscent Cesarean scar
I) Cervical pregnancy

- An EP most commonly occurs in the fallopian tube (in over 95% of patients). An EP therefore almost always corresponds to a: Tubal pregnancy = fallopian tube pregnancy

Tubal pregnancy = fallopian tube pregnancy

Table 1

	Topography	Frequency (in % of all EPs)
Infundibular	Fimbria ends	approx. 11 %
Ampullary	Distal tube section (with wide diameter)	approx. 70 %
Isthmic	Tubal section (with narrow diameter)	12 %
Interstitial (*)	Uterine, i.e., tubal section traversing the myometrium	2 – 3 %

* An interstitial EP cannot be equated with a cornual pregnancy [see below]

Table 2: The two classical clinical pictures of tubal pregnancy in the infundibular/ampullar, or isthmic tubal section.

Tubal abortion	Tubal rupture
Typical for EP sites in the wide, ampullary part of the fallopian tube, as well as in the fimbrial funnel.	Typical for EP sites in narrow (isthmic) sections of the tube.

Tubal abortion	Tubal rupture
The conceptus is expelled via spontaneous wall contractions of the tube: • either into the free abdominal cavity • or the cavity of the uterus (rarely)	The elasticity of the tube wall is rapidly exhausted near the uterus. The stress-related rupture of the tube may lead to life-threatening hemorrhages into the free abdominal cavity.

A tubal pregnancy never produces a living child.

Ovarian pregnancy

- Rare.
- Possible mechanism: During ovulation, the oocyte was not released from the ruptured follicle and was therefore fertilized within the ovary.
- approx. 1 to 3 % of all extrauterine pregnancies

Abdominal pregnancy

- 1,4 % of all extrauterine pregnancies, dangerous as massive hemorrhage is possible in case of placental separation with maternal mortality up to 20 %).
- Caused via primary implantation or, more frequently, secondary implantation of the blastocyst (after tubal rupture, after tubal abortion).
- Placentation: generally in the pelvis, rarely in the upper abdomen, e.g. in the omentum (implantations at liver, spleen, diaphragm are possible and particularly dangerous).

In the uterus, the following forms of ectopic pregnancy are possible:

Cervical pregnancy

- Rare
- May occur due to impaired decidualization of endometrium (e.g., after repeated curettage/after cesarean section/after infertility treatment).
- approx. 1 % of extrauterine pregnancies
- Excessive bleeding during curettage might occur, rarely requiring emergency hysterectomy.

Cesarean scar ectopic pregnancy

- In recent times, there has been an increasing number of EPs in dehiscent cesarean scars (increased rate of cesarean sections.).
- This form of extrauterine pregnancy accounts for 6 % of EPs in women after previous cesarean section: 1:2000 pregnancies after cesarean section.

Intramural pregnancy

- Very rare (less than 50 cases reported in the literature) in intrauterine device (IUD) users (e.g., following partial perforation of the IUD).

Interstitial pregnancy

- Pregnancy in the proximal part of the tube which passes through the uterine musculature. 2–3 % of all extrauterine pregnancies. Not equivalent to “cornual pregnancy” = pregnancy in a horn of a uterus bicornis or unicornis. Mortality 2.5 %, i.e., approx. 7x higher than in cases of tubal pregnancy, due to acute intra-abdominal hemorrhage due to tubal/uterine rupture.
- The tubal/uterine rupture may also occur late (i.e., between 7 – 16 weeks gestation).

Simultaneous occurrence of intrauterine and extrauterine pregnancy = heterotopic pregnancy

- Rare in the event of spontaneous conception
- More common after pharmacological treatment of infertility or in vitro fertilization (1,5 of 1000 pregnancies obtained via assisted reproduction).
- Patients who are undergoing ART for infertility should receive weekly ultrasounds after a positive pregnancy test has been found
- In ultrasound-confirmed intrauterine early-stage pregnancy a concomitant additional ectopic pregnancy is very rare.
- 1:30'000 pregnancies

Epidemiology, risk factors

Incidence

- 2 of 100 pregnancies (frequency increasing due to higher rates of salpingitis and of use of artificial reproductive technologies).
- In individual cases, the pathogenesis for EP remains unknown. However, the factors are always maternal; fetal-related factors (e.g. chromosomal abnormalities) do not increase the risk of EP.

The most common cause of fallopian tube pregnancies is tubal damage either post-inflammation or due to scarring

History of salpingitis

- After chlamydia infection
- After gonorrhea
- After other salpingitis types

History of previous extrauterine pregnancy

- After tube-preserving surgery (salpingotomy): risk of EP recurrence = 15,4 %
- After (unilateral) tube removal (salpingectomy): risk of EP recurrence = 9,8 %
- After drug therapy (methotrexate = MTX): risk of EP recurrence = 8 %

Other risk factors for an EP

- Sterility, previous infertility treatment: Abnormal tube function, hormonal imbalance, previous treatment with clomiphene, gonadotropins, IVF
- Pregnancy with IUD: Generally, women with IUDs exhibit a lower risk of EP than those using no contraceptive. That said, if pregnancy occurs with an IUD, the EP rate proves greater both with levonorgestrel IUDs and copper IUDs.
- Smoking
- Age over 35 years (cumulation of risk factors)
- Tubal sterilization
- Endometriosis

Morphology

- Histologically, in up to 90 % of all tubal pregnancies, chronic salpingitis can be detected.
- In 10 % of cases, a salpingitis isthmica nodosa (= ingrowth of the tubal mucosa into the tubal muscles) is found.
- In half of cases, ampullary EPs exhibit an intraluminal location, while most isthmic EPs are typically extraluminal or partly intraluminal-partly extraluminal, which contributes to increased risk of tubal wall lesions in isthmic EPs.

Clinical picture

In most cases, an EP ends spontaneously between the 6 – 10 week gestation due to unfavorable implantation conditions.
The clinical signs depend on the site of implantation, i.e., the EP location.

The following symptom triad must raise suspicion of tubal pregnancy in a woman of reproductive age:

- Lower abdominal pain
- Amenorrhea and positive pregnancy test
- Vaginal bleeding or “spotting”
- Asymptomatic cases are possible.

An untreated EP often leads to a life-threatening condition for the woman:

- In case of isthmic and interstitial location, typically tubal rupture occurs
- In case of ampullar/infundibular site, on the other hand, typically tubal abortion ensues
- For all other EP locations: acute, life-threatening bleeding complications occur and resolves spontaneously only in rare cases (see: “expectative management”).

Lower abdominal pain as the leading symptom

Typically, EP-induced pain symptoms begin a few weeks after menstrual bleeding has ceased (between 6 and 8 week gestation) with:

- Dull pain of varying intensity in the lower pelvis
- Peritoneal signs (abdominal guarding, rebound tenderness caused by blood escaping into the free abdominal cavity)

For a patient of childbearing age, all types of abdominal pain, regardless of their duration and intensity, should arouse suspicion of EP.
Initially the pain is unilateral but often spreads to the opposite side or generalizes.
Sometimes, cramp-like pain develops.
Radiating pain in the back, upper abdomen, and shoulder [diaphragmatic irritation] is possible. In between, intervals with few or no symptoms may occur for hours to days.
Regression of pain may indicate that the EP is resolving spontaneously.
Sudden pain or hyperacute pain intensification (acute abdomen) is often associated with a complication (tubal rupture, intra-abdominal bleeding with circulatory instability: hypotension, tachycardia, cold sweat). The presence of blood in the rectouterine pouch may trigger fecal urgency.

Vaginal bleeding

- Typically spotting.
- Also possible: recurrent extensive bleeding or continuous bleeding.
- Despite the bleeding, amenorrhea can generally be suspected based on medical history.

The most frequent cause of spotting is that the endometrium which has decidualized under the influence of progesterone is unable to be maintained due to the empty uterine cavity and inappropriate rise in bHCG (or bHCG drop).

General symptoms

Usual symptoms are those typical of pregnancy (nausea, vomiting, and breast tenderness) that are generally less pronounced compared to an intact intrauterine pregnancy.

Typical progressions

Table 3

Tubal abortion	Tubal rupture

Tubal abortion	Tubal rupture
• Sometimes colic-like abdominal pain that increases over time (due to contractions of the ampullar tube end until the conceptus is “successfully expelled”). • Subsequent asymptomatic interval. • However, common recurrence of progressive pain thereafter, caused by irritation of the peritoneum (= peritonism) due to intra-abdominal bleeding.	• Acute abdomen: typically fulminant progression, often with hemorrhagic shock. • An asymptomatic progression is rare in case of tubal rupture. • Overall, blood loss is usually significantly higher compared to that seen with tubal abortion. The overall progression is more dramatic.

Table 4

Abdominal pregnancies
Abdominal pregnancies are very rare, but are often not detected until late gestations, even in some cases at term, due to the paucity of symptoms.
Repeated, diffuse abdominal pain during pregnancy or peritonism (after intraperitoneal rupture of fetal membranes or bleeding) should be interpreted as potential clinical warning signs.
Abdominal pregnancy is the only form of EP which, in exceptional cases, may lead to the birth a living child (which must be delivered from the abdomen via laparotomy). Depending on the location of the placenta (pelvic wall, intestine, omentum, liver), however, the mother can develop life-threatening hemorrhages upon spontaneous detachment of the placenta or during the attempt to remove the placenta operatively.

Diagnostics

Clinic, bHCG serum values and transvaginal ultrasound (TVUS) are crucial to diagnosing ectopic pregnancy (see also Appendix)

Dectection of ectopic pregnancy at early gestations has become common due to standardized (early) pregnancy monitoring.
That said, there are surprising EP diagnoses – for which doctors of nearly all fields must be prepared when treating women of childbearing age with corresponding clinical symptoms.

An EP is discovered

- either via primary diagnostics, generally during regular pregnancy monitoring
- or via acute diagnostics (emergency patients; complications).

Clinical Presentation

Medical history

- The risk factors are of interest (see above).
- Thus, in women following infertility treatment, even in case of a known early intrauterine pregnancy, it is always necessary to consider the possibility of an “extrauterine twin”, i.e., a heterotopic EP, when lower abdomen pain persists.

Abdominal palpation

- Unilateral pain, in the lower part of the pelvis (wide differential diagnosis, e.g., appendicitis, ovarian cyst rupture, or ovarian torsion)
- Please note: In the event of an EP, abdominal pain on palpation may very well be absent.
- Differential diagnosis: In normal early-stage intrauterine pregnancy, pain and guarding in the adnexal area may be caused by an enlarged corpus luteum.

Speculum

- Typically dark-brownish discharge from the cervical canal (corresponding to the spotting).
- In case of peritoneal irritation, the speculum examination is notably painful.

Bimanual examination

- Tenderness on palpation in adnexal area. Pain upon moving / elevating the cervix. Potentially doughy resistance.

- Caution, as rupture of the fallopian tube may be provoked.
- The gynecological examination is sometimes difficult to interpret.

bHCG testing and transvaginal ultrasound (TVUS)

If the tentative diagnosis of an EP was made based on medical history and clinical examination, the differential diagnosis must be made via the correlation of the bHCG values with the TVUS findings between:

- viable early-stage intrauterine pregnancy
- non-viable intrauterine pregnancy (miscarriage)
- EP

A single bHCG analysis does not allow a distinction to be made between these three differential diagnoses. Only serial bHCG analysis at intervals of 48–72 hours can provide indications as to presence of a viable intrauterinepregnancy (appropriate increase in bHCG = doubling of the previous value), a nonviable pregnancy, or an EP (drop or inappropriate increase in bHCG = no doubling of the previous value).

The TVUS is the best imaging diagnostic modality aimed to locate an EP. That said, for clear diagnosis of pregnancy, it is required to detect the amniotic cavity (not to be confused with a pseudogestational sac!), yolk sac, and embryo, while viability must be assessed by documenting cardiac activity. The TVUS can also reveal findings that are suggestive of, but do not prove the presence of an EP, such as an adnexal findings or free fluid in the rectouterine pouch.

Using devices available today, sonographic detection of an intrauterine pregnancy is possible at the earliest about 10 days after a positive pregnancy test by means of bHCG analysis of the serum [see appendix: “Diagnostic window”]. The bHCG value at which it should be possible to diagnose an intrauterine pregnancy via TVUS is 1500 to 2000 mIU/ml (= discriminatory zone). In one study, 98 % of all intrauterine pregnancies with bHCG values over 1500mIU/mL were detected via ultrasound. With these bHCG values, an EP is usually not able to be located with certainty using TVUS, but its location can only be suspected.
Algorithms for practical approach: see under “Therapy”)

Diagnostic laparoscopy

- If the serum bHCG value exceeds the discriminatory zone of 1500 to 2000 mIU/ml and no conceptus can be found via ultrasound in the uterine cavity, this suggests an EP, therefore a diagnostic/therapeutic laparoscopy (especially for

clinically symptomatic patients) or drug therapy is indicated to treat the EP, depending on the level of pain and hemodynamic state of the patient.

- At an early gestational age (4–6 weeks), in the event of absent clinical symptoms and non-diagnostic TVUS, the laparoscopy should be postponed – while the patient is closely monitored (clinical examinations, ultrasound, bHCG). At an early gestational age (4–6 weeks), a tubal EP may not be recognized at all during laparoscopy, and therefore the surgical intervention would prove useless and may have to be repeated later.
- In general, general, however, and especially if the patient is clinically symptomatic and potentially hemodynamic unstable, laparoscopic surgery must be performed.

Monitoring of general condition

- If upon tentative diagnosis of EP, the decision is made to proceed in an expectative manner, the signs of intra-abdominal bleeding and hypovolemic shock (tachycardia, hypotension, and cold sweat) must be expected to occur at any time. If the patient remains hospitalized, appropriate monitoring must be ensured. If outpatient management is opted for, the patient and her family must be informed of this possibility. Furthermore, it should be ensured that the patient can be immediately hospitalized at any time.
- Fever is not a typical symptom of EP. However, a “resorption fever” [as with intraperitoneal bleeding] or a febrile secondary infection is possible.
- Extrauterine pregnancies still remain the primary cause of pregnancy-induced maternal mortality within the first trimester, despite improved diagnostic and therapeutic methods.

4–10 % of all pregnancy-related deaths

Differential diagnosis

In the event of lower abdominal pain and vaginal bleeding, the differential diagnosis initially proves particularly broad (until the pregnancy test is available) in the emergency department:

- Benign and malignant tumors of the genitalia, bladder, intestines
- Infections (genital infections, urinary tract infections, or intestinal infections)
- Trauma (sexual intercourse, sexual violence, or foreign bodies)
- Nephrolithiasis, cystolithiasis
- Endometriosis
- Atrophy (atrophic colpitis)
- IUD

In the case of a positive pregnancy test, generally the relevant differential diagnoses are narrowed to:

- Viable intrauterine pregnancy with threatened abortion
- Impaired intrauterine pregnancy (inevitable or incomplete abortion)
- Extrauterine pregnancy
- Heterotopic pregnancy
- Trophoblastic tumor

Treatment

Active treatment includes the timely termination of the extrauterine pregnancy. The anticipated (potentially life-threatening) maternal complications do not justify any other option. Drug therapies are now an established alternative to surgical procedures. In this context, the respective indications and contra-indications must be observed.

Special case without active therapy:
If the bHCG values are low [typically <200mIU/mL] and continue dropping, and there is no pregnancy visable on ultrasound and absent or only mild clinical symptoms, expectative management can be opted for—with the knowledge that extrauterine pregnancies can resolve spontaneously—under close clinical, sonographic, and biochemical monitoring. bHCG values should be monitored until they fall below the detection limit. That said, there are no parameters to reliably predict the spontaneous course of an EP.

Systemic therapy with methotrexate (MTX)

As a folic acid antagonist, the cytostatic methotrexate (MTX) inhibits the DNA synthesis of rapidly growing tissues. The use of MTX in the treatment of EP (usually by i.m. route) is performed according to strict criteria and requires intense monitoring (i.e., close clinical, sonographic, and laboratory checks, as well as repeated serum bHCG analyses so as to assess response to the therapy).

Under optimal conditions, an excellent success rate (90 %) is achieved, thus rendering MTX therapy cheaper than a surgical procedure.

The success of MTX treatment is especially dependent on the βHCG value before treatment is initiated. The expected treatment success rate is 94 % for βHCG values between 500 and 1000 mIU/mL, 75 % for 2500 to 3000 mIU/mL, and 66 % for 4500 mIU/mL and above. The probability of treatment success after a single administration of MTX can be estimated via a βHCG analysis if a 15 % drop from day 4 to day 7 appears. If the βHCG value decreases by less than 15 % or even increases beyond the initial value, then re-administration of MTX or a surgical intervention may be required.

Indications (requirements) for MTX treatment of tubal EP

- Early cases of clinically symptom-free EP*, i.e., no or minimal pain, stable circulation
- Serum βHCG < 5000 mIU/mL*
- No or minor adnexal finding via ultrasound (< 4 cm in diameter)
- No fetal cardiac activity*
- Compliant patient (follow-up monitoring)
- Trophoblast persistence after salpingotomy

*for special EP locations (cervical pregnancy, interstitial tubal pregnancy), an MTX treatment (in higher dosage, see below) is also relevant in case of higher gestational age, positive cardiac activity, and βHCG significantly above 5000 mIU/mL.

Contraindications for MTX treatment of EP

- Hemodynamic instability
- Large amount of intra-abdominal fluid
- Significant pain
- Pathological laboratory parameters (hematology, liver and kidney parameters)
- Comorbidities which prohibit MTX treatment (e.g., immune deficiency, florid infections, or gastric ulcer)
- Allergy/intolerance to MTX
- Heterotopic pregnancy
- Lactation
- Serum βHCG > 5000 mIU/mL
- Positive cardiac activity of EP
- Large adnexal mass (> 4 cm)

Dosing of MTX

- 50 mg/m2 of body surface or 1 mg/Kg of body weight i.m. as single dose.
- In special cases (cervical pregnancy, interstitial tubal pregnancy), several days of MTX treatment should be opted for according to the therapeutic schedule for trophoblastic diseases (--> G12B): MTX Day 1, 3, 5, 7 – 1mg/Kg of body weight i.m. each as well as folic acid “rescue” Day 2, 4, 6, 8 0.1mg/kg of body weight p.o. each

Important considerations

- An increase in bHCG values up to 4 days after MTX administration is possible
- Between Day 4 and 7 after MTX administration, however, there should be a bHCG reduction of at least 15 %, otherwise another MTX administration is

indicated.
- Increase in abdominal pain is possible up to 4 days after MTX administration
- NSAIDs must not be used for treating pain (interaction with MTX)
- Temporary increase in adnexal findings detected via ultrasound proves possible
- Regular bHCG and sonographic follow-up checks are indicated until bHCG falls below the detection limit. This may last 1-3 months after therapy initiation, but occasionally even longer
- Bleeding complications (with the need for surgical intervention) are possible at any time during the course of treatment
- Avoid exposure to sun (MTX-induced dermatitis)
- Administration of folic acid should be avoided in the context of MTX treatment (this applies to single-dose treatment with MTX, but not to higher-dose treatment with MTX, e.g., in cervical pregnancy and for trophoblastic tumors, for which folic acid is administered as rescue treatment to minimize the adverse effects).
- Contraceptives should be used to prevent another pregnancy before the beta HCG levels have dropped to zero.

Surgical treatment

In general, and irrespective of the EP location, the following applies:

- Overall, in the event an EP diagnosis, surgery is performed in the majority of cases (approx. ⅔). The procedure is generally performed via laparoscopy. In the event of unstable circulatory conditions (hemodynamic [pre-]shock), an emergency laparotomy is sometimes indicated.

Indications for a surgical procedure in case of EP are:

- Hemodynamic instability
- Clinical signs of intra-abdominal bleeding, suspected rupture
- Pronounced clinical symptoms (pain)
- Heterotopic pregnancy
- Desire for tubal sterilization
- Hydrosalpinx and desire for future IVF
- Absolute/relative contraindications for MTX treatment (see corresponding section)
- Failed MTX treatment

If there is no emergency indication for surgical intervention, if possible, surgery should be performed only if EP is expected to be identified during the operation based on vaginal ultrasound findings (evidence of an adnexal finding) and the bHCG value.

Tubal surgery – in case of tubal pregnancy

Salpingectomy	Salpingotomy
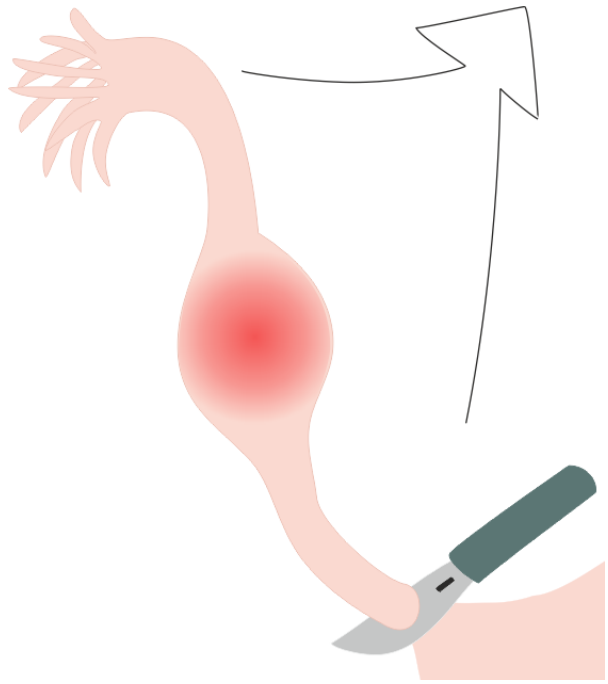 Figure 2: Removal of the tube.	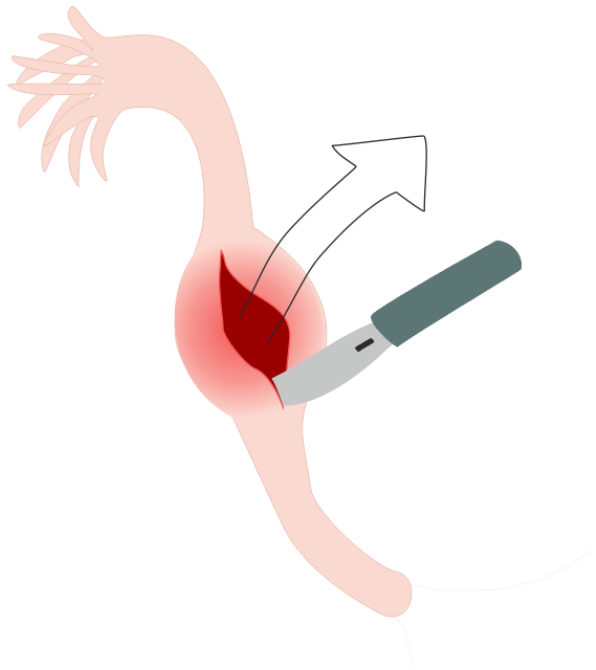 Figure 3: Tube-preserving operation.
usually laparoscopic	

Salpingectomy

Indications for salpingectomy include:

- Uncontrollable bleeding from the tube
- Tube irrevocably destroyed by the EP (large EP, tubal rupture)
- Simultaneous desire on the part of patient for tubal sterilization or salpingectomy (planned IVF, or prophylaxis of ovarian cancer)

Technique:

- usually complete, in rare cases partial removal of the tube

Salpingotomy

Indication:

- Conservation of tube function in case of minimal tube damage caused by EP, and in patients with only one fallopian tube due to prior contralateral salpingectomy.
- Typical intervention for ampullary EP

Technique:

- Longitudinal incision of the tube on the side opposite to the mesosalpinx, possibly after injecting vasopressin (Minirin®) and careful, atraumatic removal of the conceptus, if possible using a laparoscopic suction-irrigator device (hydrodissection); careful, atraumatic hemostasis via electrocoagulation; the incision on the tube is then left open (no suture).
- As an alternative to salpingotomy, another tube-conserving surgical procedure is possible – in rare cases – if the EP is located peripherally at the fimbrial end of the fallopian tube (infundibular EP): This is done by squeezing the conceptus out of the fimbrial end, a process referred to as milking out.

Trophoblast persistence occurs after salpingotomy (and after milking out) in 4 to 15% of cases. This is reflected in a renewed increase or a lack of decrease of the βHCG values below the detection limit (<5mIU/mL) postoperatively. The consequences of trophoblast persistence are the same as for the persistence of EP. For these reasons, the βHCG must be monitored in the short term after salpingotomy and milking out, until it has dropped below the detection limit.

The risk of secondary bleeding is increased with salpingotomy as compared to salpingectomy. Therefore, the benefits of fertility preservation versus the disadvantages of salpingotomy must be carefully weighed out in the indication for or against a tube-conserving surgical intervention.

Table 6: Clinical examples

Criteria					
Hemodynamics/ clinic	unstable	stable	stable	stable	stable
bHCG (mIU/mL)	positive	>1500	>1500	>1500	>1500
bHCG increase after 72 hours	not carried out	adequate	inadequate	inadequate	inadequate

Criteria					
TVUS: IUP, EP, Adnexal findings	no mean. no mean. free liquid	IUP, no mean.*	incr. IUP, no mean.*	diagnostic, yes	EP, yes
Tentative diagnosis	Acute intra-abd. bleeding	intact IUP	dist. IUP, abortion	Suspicion of EP	EP
Procedure	EM-LSC or laparotomy	expectative, symptomatic	spontaneous abortion, abortion cure	MTX or LSC	MTX or LSC

* = if no suspicion of a heterotopic pregnancy
Legend: TVUS = transvaginal ultrasound, IUP = intrauterine pregnancy, EP = ectopic pregnancy, no mean. = no meaning, EM = emergency, LSC = laparoscopy, MTX = methotrexate

Treatment of non-tubal EP

The surgical treatment of non-tubal EP (interstitial, cervical, or intramural) used to frequently consist of emergency hysterectomy. Given that today EP diagnosis is made earlier, drug treatments (MTX) and uterine-preserving surgical techniques are more common.

Cervical pregnancy

First-line treatment is MTX.
In the event of bleeding in the setting of drug therapy or at curettage, bilateral embolization or ligation of the uterine arteries (or their descending branches) should be considered. Postoperative insertion of a balloon catheter into the uterus for hemostasis. As a last resort when bleeding is unstoppable: hysterectomy

Pregnancy in the (dehiscent) cesarean section scar

- Increase of this EP location due to increased frequency of cesarean sections.
- The primary therapeutic focus is the removal of the ectopic pregnancy, which is often located between the uterus and the bladder, together with the freshening of the edges of the dehiscent scar and its closure either via laparoscopy or laparotomy.
- Cases treated with MTX and hysteroscopic procedures are described.

Interstitial EP

- Differential diagnosis: Cornual pregnancy = pregnancy in the horn of a uterus bicornis.
- The primary focus is on drug therapy with MTX or surgical procedures (cornuostomy, cornuectomy + salpingectomy) in case of failure of MTX treatment or bleeding complications, via laparoscopy or laparotomy.
- The ligation of the uterine vessels or their embolization must be considered in the event of bleeding and the desire to preserve the uterus.

Trophoblastic persistence

Trophoblastic persistence refers to the persistence of vital trophoblast tissues in situ after drug or surgical treatment, from which a sort of “local recurrence” consisting of trophoblast tissue can form via proliferation.

Trophoblast persistence poses a relevant risk (5–20 % of cases), both after MTX treatment and after tube-preserving surgery modes (salpingotomy/milking out of tube).

Symptoms:

- Recurrence of pain and intra-abdominal bleeding.
- The delayed decrease in bHCG serum value during follow-up monitoring is suggestive of trophoblastic persistence, while a plateau formation or renewed increase proves its manifestation.

It is therefore obligatory for short-term and repeated laboratory monitoring (bHCG) to be carried out after MTX treatment or after tube-preserving surgery in order to detect trophoblastic persistence as early as possible.

Treatment

- (If necessary) MTX or salpingectomy.
- After initial tube-preserving treatment, the tube may subsequently need to be removed in the event of trophoblast persistence.

Outcome

Within 24 months, ⅔ of women with a desire for a child can expect an intrauterine pregnancy after EP surgery via salpingectomy and ¾ after salpingotomy or an EP drug treatment (MTX) if they are under 35 years of age and have no medical history of infertility.
The incidence of an EP recurrence is about 15 %. The recurrence rates after salpingectomy (if one tube remains), salpingotomy, and MTX treatment are comparable. That said, after two preceding EPs, the risk of recurrence increases up to 30 %.

Appendix

Human chorionic gonadotropin (bHCG) as a laboratory parameter

The glycoprotein bHCG is produced by the syncytiotrophoblast (component of the trophoblast) at the time of implantation. Then, the bHCG secretion increases during the first 10 weeks of pregnancy in correlation with the growth of the conceptus.

> As a rule of thumb, the bHCG value should double in the serum every 48 to 72 hours in the event of normal intrauterine pregnancy.

An insufficient increase (less than 53 % bHCG increase within 2 days) or even a drop in bHCG values may suggest a nonviable intrauterine or possibly an ectopic pregnancy.

In immunological test systems used today, antibodies against the beta subunit of the HCG are used for pregnancy diagnostics. Several textbooks refer to HCG for reasons of simplicity (others consistently utilize bHCG).

Vaginal ultrasound

Normalfall

Intrauterine pregnancy is visible on ultrasound after cycle Day 32 at the earliest (= shortly after the absence of menstrual bleeding). In recent years, vaginal ultrasound has significantly refined the diagnosis of EP. If the uterine cavity is empty, findings should be interpreted in correlation to the simultaneously measured bHCG serum value.

The following is normal for intrauterine pregnancy:

1. It can be detected via ultrasound at the end of Week 5 or at beginning of the Week 6 of pregnancy (chorionic cavity, yolk sac, embryo, fetal membranes, cardiac activity)
2. It has a bHCG level of (600 -) 2000mIU/ml in Week 6

With very good ultrasound devices and under “favorable” ultrasound conditions, a normal, intrauterine pregnancy is already detectable at a bHCG serum value of 1000mIU/ml.

In the event of a bHCG serum value of (at least) 1500mIU/ml, an intrauterine pregnancy should be reliably diagnosable (in 98 % of cases) with the use of conventional ultrasound equipment via transvaginal ultrasonography.
If the uterine cavity – contrary to expectations – is found via ultrasound to be “empty”, an EP or an impaired intrauterine pregnancy, or, very rarely, a trophoblastic tumor (e.g., placental site trophoblastic tumor --> G12B) is to be assumed.

The “discriminatory zone” for the differential diagnosis between intrauterine and extrauterine pregnancy depends on:

- the experience of ultrasound operator
- the quality of the ultrasound equipment
- clinical conditions (e.g. presence of myomas)
- the quality of the bHCG test

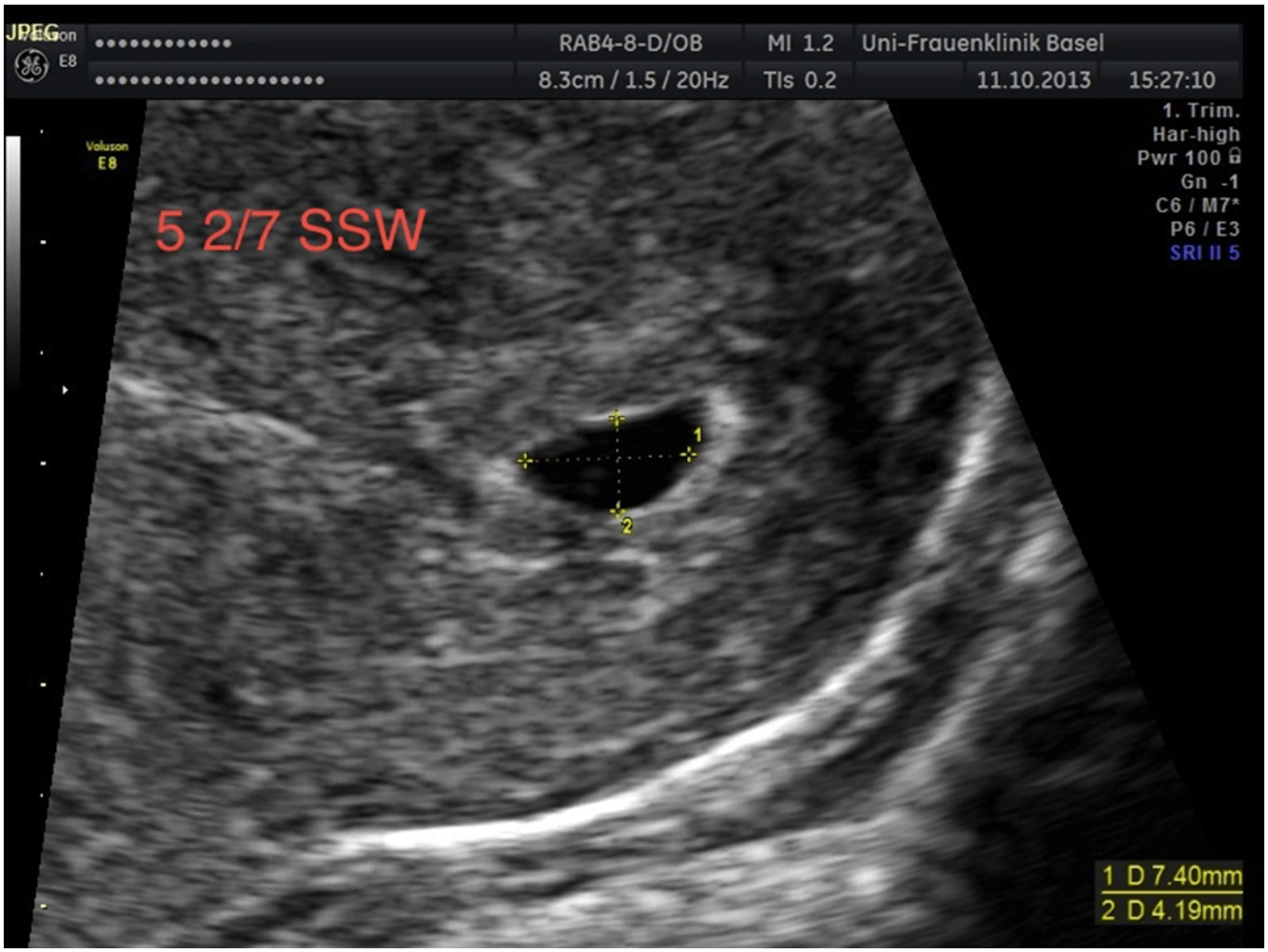

Figure 4: Vaginal ultrasound images (early pregnancy).

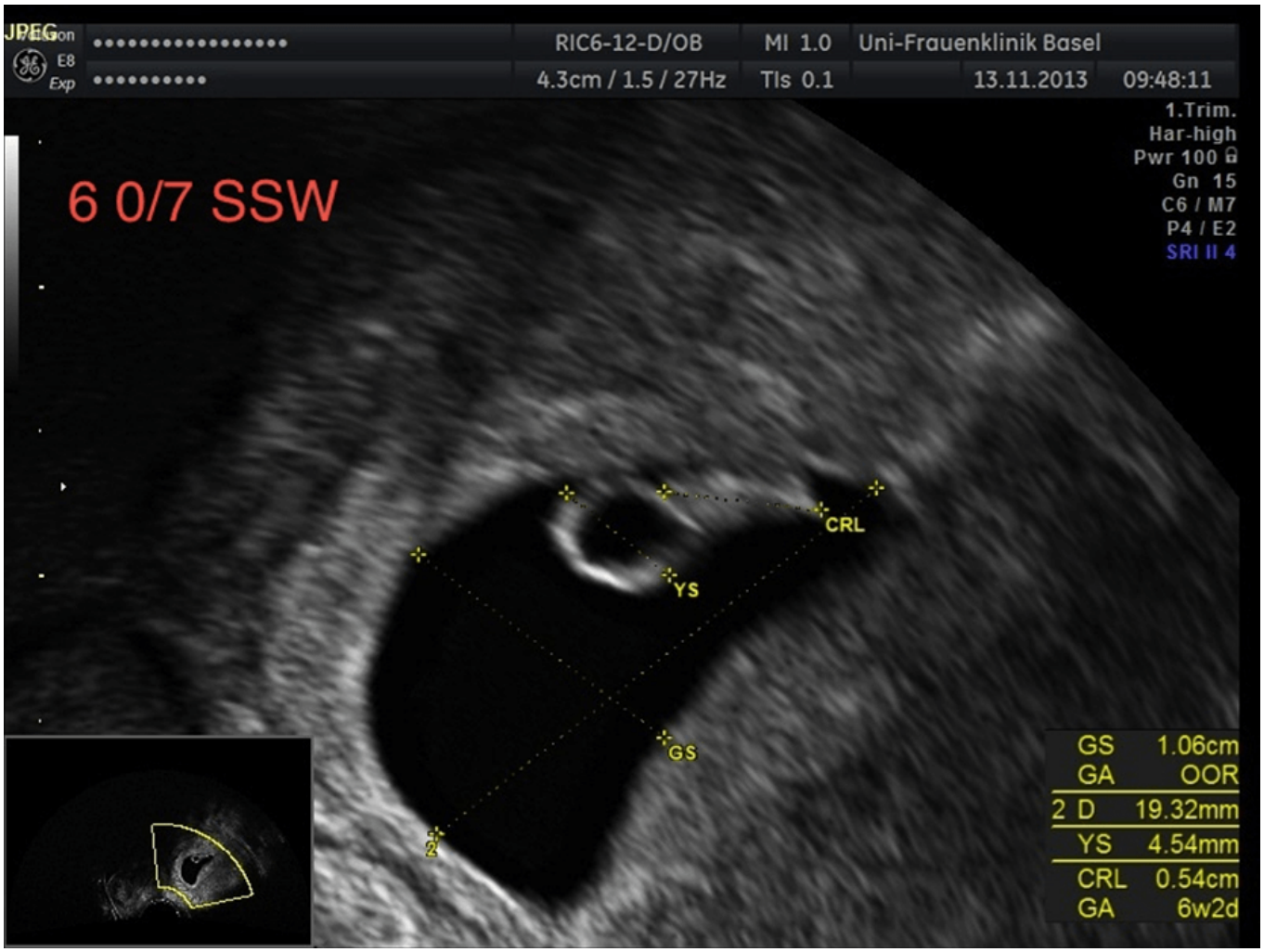
JPEG
E8
Exp
RIC6-12-D/OB
MI 1.0
Uni-Frauenklinik Basel
4.3cm / 1.5 / 27Hz
TIs 0.1
13.11.2013
09:48:11
1.Trim.
Har-high
Pwr 100
Gn 15
C6 / M7
P4 / E2
SRI II 4
6 0/7 SSW
CRL
YS
GS
2
GS 1.06cm
GA OOR
2 D 19.32mm
YS 4.54mm
CRL 0.54cm
GA 6w2d

Figure 5

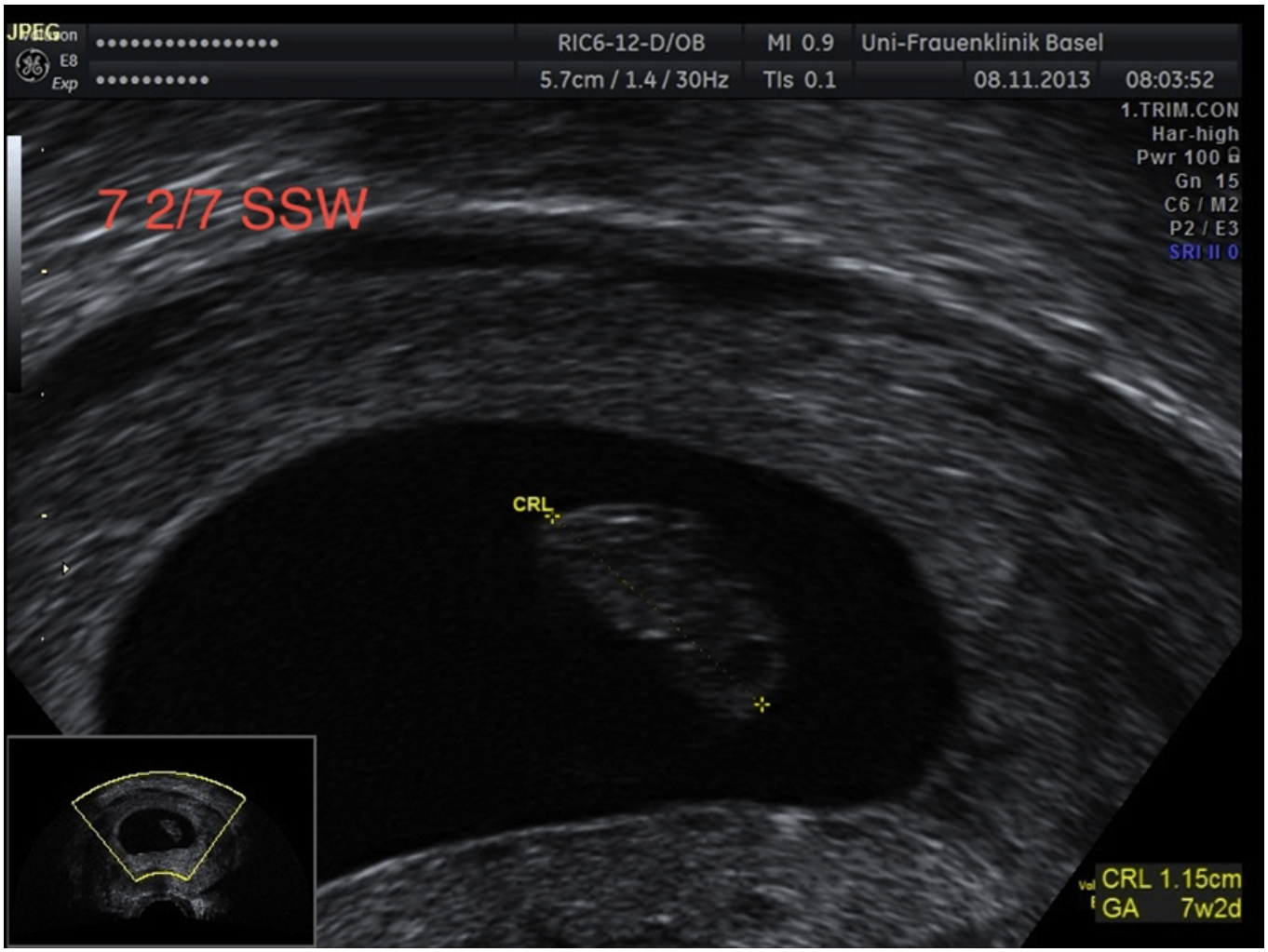

Figure 6

Summary of the “diagnostic window”

- Sensitive pregnancy test (bHCG in serum) – positive as of 10 days after conception.
- Localization via ultrasound is usually possible as of Day 20 post-conception.

“Cheat sheet” (conversion table of embryonic age indications)

Table 7

Chronology, expressed as...	p.c. post conceptionem	p.m. post menstruationem (“cycle day”)	week gestation*
Beta-HCG: positive	Day 10	Day 24	Middle of week 4

Chronology, expressed as...	p.c. post conceptionem	p.m. post menstruationem (“cycle day”)	week gestation*
Ultrasound: Proof of pregnancy and location can be postulated (chorionic cavity + yolk sac)	Day 20	Day 34	End of week 5
Ultrasound: Proof of pregnancy and location established (cardiac activity)		Day 40	End of week 6

* The gestational age (expressed in pregnancy weeks = PW) is always understood as “post menstruationem” according to clinical prescribed terminology. - Unless “post conceptionem” is explicitly noted.

The “post menstruationem” count begins on the 1st day of bleeding of the last menstruation. Thus, the difference to post conceptionem is 14 days.

Literature

Nr.	Title	Author	Journal	Volume	Pages	Year
[B01]	Ectopic Pregnancy	Walker JJ	Clinical Obstetrics and Gynecology	50	89-99	2007

Nr.	Title	Author	Journal	Volume	Pages	Year
[P01]	Interventions for tubal ectopic pregancy (Review) The Cochrane	Hajenius P et al	Library	Issue 3		2009
[P02]	Tubal ectopic pregnancy: diagnosis and management	Nama V, Manyonda J	Arch Gynecol Obstet	279	443-453	2009
[P03]	Ectopic Pregnancy: Role of Laparoscopic Treatment	Ehrenberg-Buchner S et al	Clinical Obstetrics and Gynecology	2009	372-379	52
[P04]	Current evidence on surgery, systemic methotrexate and expectant management in the treatment of tubal ectopic pregnancy: a systematic review and meta-analysis	Mol F et al	Human Reproduction Update	14	309-319	2008

Nr.	Title	Author	Journal	Volume	Pages	Year
[P05]	Ectopic pregnancy secondary to in vitro fertilization-embryo transfer: Pathogenic mechanisms and management strategies	Refaat B et al	Reproductive Biology and Endocrinology	13	30	2015
[P06]	Methotrexate success rates in progressing ectopic pregnancies: A reappraisal	Cohen A et al	Am J Obstet Gynecol	211	128.e1-5	2014
[P07]	Using a decline in serum hCG between day 0–4 to predict ectopic pregnancy treatment success after single-dose methotrexate: A retrospective cohort study	Skubisz M et al	BMC Pregnancy and Childbirth	13	30	2013
[P08]	ility after tubal ectopic pregnancy: Results of a population-based study	De Bennetot M et al	Fertil Steril			2012