Last update: May 2023

Endometrial cancer

Co-

Author: Dr. med. Martin Heubner

Chefarzt Gynäkologie und Direktor des Departements Frauen und Kinder, Kantonsspital Baden

Author(s): Prof. Dr. med. Rainer Kimmig, PD Dr. med. Pauline Wimberger, Prof. Dr. med. Daniel Fink

Introduction

- Endometrial cancer is the most common female genital cancer in industrialized countries.
- The most common female genital cancer worldwide is cervical cancer.
- The most common malignancy in women overall is breast cancer.
- Fourth most common tumor in women in the USA.
- Eighth most common cause of death among all cancers.
- 15 % of all women die from the disease.

Contrary to cervical cancer, endometrial cancer is:

- age-related
- hormone-dependent in most forms
- not triggered by a viral infection
- usually discovered at an opportune stage without screening, due to early symptoms alone

As with healthy endometrium, endometrial cancer is typically (but not always) hormone dependent.

As a reminder, healthy endometrial cells (--> endometrium = glands and stroma) depend on estrogen to complete their proliferation. This proliferation is limited by gestagens. As a countermeasure, gestagens carry out the secretory conversion of the endometrium.

Definitions

Terms: Endometrial cancer and uterine cancer are synonyms.

Epidemiology

Endometrial cancer is an age-associated cancer. The peak age is between 60 and 75 years (incidence increasing in recent years).

However, 5 % of patients affected are under 40 years old.

Endometrial cancer:

- Associated with colon, ovarian and breast cancer
- but not with cervical or vulvar cancer.
- Patients with hereditary nonpolyposis colorectal cancer (HNPCC) have a 40 % lifetime risk of developing endometrial cancer.

Estrogens stimulate the existence of the majority of endometrial cancers (namely all highly-differentiated endometrioid types):

Highly-differentiated endometrioid endometrial cancers are generally rich in hormone receptors. Estrogen receptors are directly relevant for carcinogenesis.

- This is because if a healthy endometrium is permanently exposed to a high estrogen stimulus, without a counteracting gestagen effect, this first leads to simple hyperplasia,
- which can then lead to atypical proliferation. With time, atypical hyperplasia of the endometrium can occur.
- Atypical hyperplasia most often involves high concentrations of estrogen (and progesterone) receptors; the further progression is therefore mapped out.

In 40 % of patients with atypical hyperplasia in material from curettage, endometrial cancer is diagnosed with histological processing of the uterus specimen after hysterectomy.
The incidence peak of atypical hyperplasia is a good decade before that of endometrial cancer.

Risk factors for (endometrioid) endometrial cancer

- Age
- Early menarche and/or late menopause (cumulative, higher than average endogenous estrogen stimulus).

- Obesity (subcutaneous fatty tissue produces estrogen [extraglandular aromatization unconjugated estriol in serum] and sex hormone-binding globulin [SHBG]). A BMI > 30 kg/m2 is associated with a 2-3x higher risk of endometrial cancer, and concomitant type II diabetes leads to a further increase in risk.
- Hormone Replacement Therapy (HRT): presently the main factor for exogenous estrogen overstimulation! However, the administration of progesterone (combination therapy) can neutralize the risk resulting from estrogen substitution, whereby progesterone is used to return the endometrium from the stimulating (proliferative) state to the “deactivated” (secretory) state in phases, in a pharmacologically controlled manner. This considerably lowers the mitosis rate and number of estrogen receptors again. If the uterus is present, HRT should therefore always be implemented as combination therapy (i.e. estrogen plus gestagen)!
- Certain SERMs (e.g. Tamoxifen®) – the partial estrogen agonist effect promotes the development of EMT hyperplasia and subsequently that of an EMT cancer.
- Corpus luteum insufficiency with polycystic ovaries (anovulation reduced gestagen formation relative estrogen overproduction)

Note: The traditional triad often found with type I endometrial cancer is a combination of overweight, diabetes and arterial hypertension. Diabetes mellitus and hypertension are not proven risk factors, but are associated with endometrial cancer (probably as these diseases are also associated with obesity).

Histopathology and classification

Malignant epithelial tumors of the endometrium are fundamentally always adenocarcinoma. A classification as type 1 and type 2 has been established:

Table 1: Type 1 carcinoma

80 %	Endometrioid endometrial cancer Often designated the typical type 1.
80 %	Tumor biology: mostly hormone dependent!
80 %	Mostly highly differentiated: Mostly rich in estrogen and progesterone receptors. Occurrence correlates with a variety of risk factors.
80 %	Development: Malignant transformation of a precancerous condition (namely endometrial hyperplasia with atypia) as a result of hyperestrogenism.
80 %	Overall, favorable prognosis. Any squamous cell involvement (adenosquamous carcinoma) does not worsen the prognosis.

Atypical hyperplasia: precancerous condition of type 1 endometrial cancer

Table 2: Type 2 carcinoma

20 %	Specific histological forms (see below) of adenocarcinoma are classified as type 2. This also includes serous papillary and clear-cell carcinoma.
20 %	Tumor biology: mostly NOT hormone dependent!
20 %	This type shows scant hormone receptors. Often occurs without risk factors, including in particular without obesity.
20 %	Development: Not a result of hyperplasia - but rather the malignant transformation of an endometrial intraepithelial neoplasm in otherwise atrophic endometrial tissue.
20 %	Prognosis less favorable than type 1 endometrial cancer.

Molecular classification of endometrial cancer

Particularly with endometrial cancer in early stages, the traditional histomorphological classifications such as TNM stages and grading have proven to be relatively unreliable with regard to assessing the risk of recurrence. A classification according to molecular tumor properties is therefore increasingly used for endometrial cancer, as is already the case for many other types of tumor. In addition to risk stratification, this analysis also allows for an estimation of whether the disease occurred spontaneously or as a result of a genetic predisposition: 5 to 10 % of all endometrial cancers occur in association with HNPCC (hereditary non-polyposis colorectal cancer) syndrome. This can be indicated by an absence of DNA mismatch repair proteins (MMR) shown on immunohistochemical analysis. This can be caused by promoter methylation (found in approx. 50 % of tests) and not by a germline mutation. However, if methylation is not found, genetic counseling should take place. If suspected HNPCC syndrome is confirmed with genetic testing, this has a direct impact on how the patient's treatment is managed and the advice given to relatives. In such cases, relatives should also be encouraged to undergo genetic counseling.

The molecular classification can provide valuable information for therapy planning and has therefore already been included in some international guidelines. While tumors with a p53 mutation are high-risk and should be treated aggressively, evidence of a POLE mutation is associated with a very good prognosis and most of these patients do not require any adjuvant therapy.

Previous data on clinical relevance were assessed retrospectively and clinical studies on the prospective benefits of molecular tumor classification are pending.

A distinction is drawn between the following molecular subtypes:

Table 3: Molecular subtypes

Subtype	Evidence	Relevance	Frequency
p53abn	Immunohistochemical demonstration of a suggestive p53 immunoreactive pattern	Associated with poor prognosis, benefits from adjuvant radio and chemotherapy	10–20 %

Subtype	Evidence	Relevance	Frequency
MMRd	Immunohistochemical loss of repair proteins (dMMR), microsatellite instability (MSI-high)	Good to intermediate prognosis, probably benefits from adjuvant radiotherapy Genetic counseling to rule out HNPCC (Lynch) syndrome is sensible (if no absence of proteins due to promoter methylation as is the case in approx. 50 %) In case of advanced disease, often good treatment response to immune checkpoint inhibitors	20–30 %
POLE	Molecular genetic evidence of POLE mutations	Excellent prognosis, in many cases does not require adjuvant therapy	5–10 %
NSMP (no specific molecular profile)	No evidence of the above mutations	Good to intermediate prognosis	40–60 %

Clinical picture

The most important symptom of endometrial cancer is postmenopausal bleeding from the corpus uteri (corresponding with the high age-prevalence of the disease).

The most common symptom is bleeding or a bleeding disorder!
This is a clear symptom that usually occurs at an early stage. This encourages early diagnosis and enables early detection.

The five-year survival rate is correspondingly high at 80 % (higher than most other cancers!).

Any postmenopausal bleeding could be a sign of endometrial cancer and should (therefore) be investigated.

Irregular bleeding (metrorrhagia), a dark reddish-brown discharge, and any lower abdominal pain can also indicate endometrial cancer.

However, endometrial cancer does not always become clinically apparent due to bleeding! Interestingly, in asymptomatic patients, early diagnosis (e.g. by ultrasound) does not have a favorable effect on prognosis - this is probably due to the overall fairly favorable prognosis, particularly for type 1 cancer. [B09]

Symptoms from metastases (or metastasizing progressions) generally present rather late with endometrial cancer.

For example: Back pain (with retroperitoneal lymph node involvement), symptoms due to lung metastases.

Diagnosis

Speculum examination

This can determine whether bleeding is coming from the uterus. The development of a metastasis of the endometrial cancer in the vagina can also be detected.

> Cytological smears are mostly negative - and therefore cannot be used for early detection, as a screening measure, for endometrial cancer.

Bimanual gynecological examination

- This examination is usually inconspicuous(!) in the early stage.
- In advanced stages, an enlarged uterus with a soft(!) consistency or the involvement of the parametrium can sometimes be palpated.

Patient obesity, which is often encountered, frequently means that the clinical test is inconclusive.

Rectal examination

This can indicate whether the tumor has already spread to the rectum. In addition, palpation of the parametrium and rectouterine pouch is possible.

Vaginal ultrasound - "measuring endometrial thickness"

Ultrasound imaging of the endometrium can provide important information. A thick endometrium with or without intrauterine fluid collection is suspicious. However, measuring the infiltration depth (suspicious findings) is difficult.

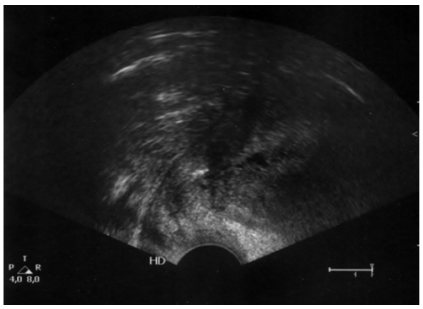

Figure 1: Ultrasound image of an endometrial cancer.
Ultrasound image of an endometrial cancer. An inhomogeneous thickened endometrium can be seen. This case shows no indication of an extended infiltration of the myometrium.

Histological confirmation with hysteroscopy and fractional curettage

Hysteroscopies can also be carried out as an out-patient procedure, in most cases they are done under general anesthetic.

A hysteroscope is inserted and the uterine cavity is filled with an isotonic solution so that it expands. This gives the investigating doctor a direct view of the cavity pathology to be investigated, which is valuable for differential diagnosis.

- In macroscopic terms, the location and extent of the findings are assessed, and a possible cervical involvement (=stage II) is investigated.
- Targeted tissue biopsies are taken from the suspect location.

After the hysteroscopy, during the same intervention, a wide area of tissue from the cavity and cervical canal is scraped off - “blindly” using a curette - for histological testing.

Fractioned tissue (sequential and separated according to sample site) is collected: (i) from the cervical canal (for targeted investigation of cervical involvement); (ii) from the whole uterine cavity

The fractional curettage is carried out under the same partial/general anesthetic as the hysteroscopy, after additional dilation of the cervical canal and inner cervix using dilatators (Hegar dilators).

Note: Curettage alone has a risk of missing especially smaller carcinomas. Hence, concomitant hysteroscopy is mandatory.

Caution: Curettage of a pronounced endometrial cancer invading the myometrium entails a risk of uterus perforation.

Possible alternatives: Vacuum aspiration (= outpatient endometrial biopsy in clinic)

There is a method for detecting (but not ruling out!) endometrial cancer, which can readily be used in clinics (except in cases of cervical canal stenosis, as is sometimes found in postmenopausal patients). A thin catheter (e.g. a Cornier Pipelle) is inserted into the cervical canal and pushed into the cavity. Endometrial tissue is then collected under vacuum aspiration.

- This can be used for cancer confirmation only!
- A “negative” finding in no way rules out cancer.

If the vacuum aspiration shows no cancerous tissue, a hysteroscopy with fractional curettage must be carried out.

Presurgical Staging Testing

If endometrial cancer is confirmed with histological testing, the results of the following “preliminary staging tests” are required for planning primary treatment.

- Transvaginal ultrasound is suitable for diagnosing local metastasis, in particular evaluating the possible involvement of the myometrium and the cervix. If the findings are unclear or interpretation is limited, an MRI should be provided.
- Chest x-ray - to rule out lung metastases (rare overall, but up to 4 % with high-risk cancers)
- Imaging with MRI or CT in case of justified suspicion of or high clinical risk of distant metastases

Side note: Definitive staging of endometrial cancer is only carried out post surgery, according to the additional peritoneal cytology findings (see below) and the resection histology!

Differential diagnosis

Endometrial cancer is the most common malignant cause of vaginal bleeding.

However, only 1/10 postmenopausal bleeds are caused by endometrial cancer.

Other causes of bleeding are:

- DD (malignant): cervical cancer, uterine cancer, vaginal/vulvar/ovarian/fallopian tube cancer
- DD (benign): polyps (mainly uterine polyps), submucosal myoma, bleeding from atrophic endometrium, etc.

Growth and metastatic pathway

Endometrial cancer generally originates in the uterine fundus. Its growth is either exophytic (into the uterine lumen) or penetrating the uterine muscles.

Direct spread

- In 10 % of cases, there is cervical involvement (DD!). Over time, spread into the parametrium is possible. Occasionally, the vagina may be involved (mainly the anterior vaginal wall; upper third). Suburethral involvement is a very common localization in the vagina.
- Finally, intracanalicular tumor cell spread is possible via the fallopian tubes - in the abdomen: peritoneal metastases.

Lymphogenic spread

- Possible pelvic lymph node involvement
- Metastases in the para-aortic lymph nodes must be considered, through direct metastasis via the lymphatic vessels in the suspensory ligament of the ovary (infundibulopelvic ligament).
- Ovarian metastases occur in < 10 % of cases.

Presence of secondary malignancies: the coincidence of endometrial and ovarian cancer is not rare.

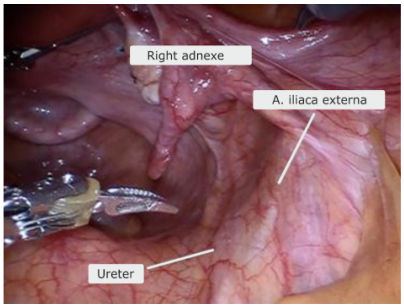

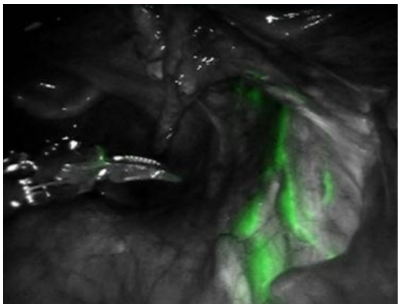

Figure 2: Indocyanine dye.
Indocyanine dye also shows the pelvic lymph flow of the corpus uteri.

Hematogenic spread

- particularly in lungs and liver (rare, late)

Tumor grading for endometrial cancer (only applies to type 1)

- G1: well-differentiated, well-formed glandular CA (adenocarcinoma); < 5 % solid component
- G2: moderately differentiated adenocarcinoma; 6 to 50 % solid component

- G3: poorly differentiated, immature adenocarcinoma; > 50 % solid component

Stage classification (as per FIGO/TNM)

Definitive staging takes place post surgery, on the basis of histological testing of the uterus, adnexa and lymph nodes.

Table 3: FIGO/TNM classification of endometrial cancer (2020)

TNM category	FIGO stages	Definition
TX		Primary tumor cannot be assessed
T1	I	Tumor confined to corpus uteri
T1a	IA	Tumor confined to endometrium or < 50 % infiltration of the myometrium
T1b	IB	Tumor has infiltrated > 49 % of the myometrium
T2	II	Tumor has infiltrated the cervical stroma
T3	III	Local/regional involvement
T3a	IIIA	Tumor involves serosa and adnexa
T3B	IIIB	Tumor involves vagina/parametrium
N1	IIIC1	Metastases in pelvic lymph nodes
N2	IIIC2	Metastases in para-aortic lymph nodes
T4	IVA	Rectal/bladder mucosal involvement
M1	IVB	Distant metastases, including intra-abdominal metastases (excluding metastases in the vagina, pelvic serosa or adnexa, including metastases in the inguinal or other intra-abdominal lymph nodes as para-aortic and/or pelvic lymph nodes)

Prognosis (factors)

The generally early diagnosis is reflected in the overall favorable 5-year survival rate of 80 %. 3 out of 4 endometrial cancers are detected in stage I, where prognosis is favorable.

Table 4: Relative frequency of tumor stages and prognosis

Stage	Relative frequency of this tumor stage for new detection	5-year survival rate for this tumor stage
Stage I	75 % of patients	85 %
Stage II	10 % of patients	75 %
Stage III	10 % of patients	55 %
Stage IV	< 5 % of patients	20 %

Morphological risk factors

The histological subtype (type I/type II) and molecular properties of the tumor are important factors for the prognosis.

The presence of lymph nodes metastases, tumor stage, grading and histopathological tumor type are established morphological parameters for prognosis.

If there is evidence of lymphovascular invasion (LVSI), the risk of lymph node metastases is significantly higher. However, without the presence of lymph node metastasis, LVSI is a negative prognosis factor that impacts adjuvant therapy planning.

Age and comorbidities are also prognostic factors that cannot be influenced and that should be taken into account when planning therapy.

There is no consensus concerning the prognostic value of positive peritoneal cytology (wash cytology).

Type 2 endometrial cancers have a poorer prognosis - they are biologically more aggressive, and often undifferentiated.

Treatment

Surgical treatment is the treatment of choice for endometrial cancer.

However, the risks of anesthetic must be evaluated and discussed in good time: Older patient population → concomitant factors such as obesity, high blood pressure, diabetes mellitus (“risk triad”) must be taken into account.

Treating atypical endometrial hyperplasia

Conservative therapy for endometrial hyperplasia with atypia: e.g. 100 mg medroxyprogesterone acetate per day or megestrol acetate per day for approx. 3 months.

For women who do not wish to have children, postmenopausal women and young women who do not show remission on follow-up curettage, a hysterectomy should be carried out even in case of atypical hyperplasia (postmenopausal: an invasive cancer is found in 40 % of cases on examination of the uterus).

Treating endometrial cancer

Surgery

- First, peritoneal cytology/wash cytology is carried out. Positive cytology is documented but the stage is not changed. There is no consensus on the prognostic value of the test.
- The uterus and bilateral uterine appendages (fallopian tubes and ovaries) are removed = bilateral adnexectomy = bilateral salpingo-oophorectomy (also possible laparoscopically at early stages and with a small uterus).
- Depending on stage: pelvic and para-aortic lymphadenectomy versus sentinel node biopsy
- Depending on stage: vaginal cuff removal.
- Depending on stage: adjuvant therapy (radiotherapy and chemotherapy)

In case of high risk of metastasis: Pelvic and para-aortic lymphadenectomy (always for grade G3 and from FIGO stage Ib).

The guidelines for the treatment of endometrial cancer anticipate pelvic and para-aortic lymphadenectomy. However, sentinel node lymphadenectomy is gaining traction in clinical practice, and is included as an acceptable staging method in some international guidelines.

This recommendation is based on the observation that an incidence of lymph node metastasis of 3 to 15 % for para-aortic lymph nodes and 8 to 19 % for pelvic lymph nodes is reported even at stage I. In stage II, 16 to 30 % of patients have para-aortic lymph node involvement and 29 to 40 % pelvic lymph node involvement. Systematic lymphadenectomy is therefore currently only dispensed with in cases of endometrioid histotype (grade 1 and 2), myometrial invasion < 50 % and - where ascertainable - a primary tumor diameter of < 2 cm, or with an endometrioid histotype without myometrial invasion (then regardless of primary tumor diameter and grading).

The recommendation to dispense with lymphadenectomy in cases of early-stage low-risk endometrial cancer is based in part on the work of Eltabbakh and Mariani. In Eltabbakh et al's study of 303 patients with grading 1-2 and endometrial invasion < 50 %, a relapse-free 5-year survival rate of 98,9 % and a relapse-free 20-year survival rate of 96,7 % could be achieved with surgical treatment without lymphadenectomy but with subsequent vaginal brachytherapy [B04, P05].

The recommendation for para-aortic lymphadenectomy in cases of high-risk endometrial cancer is based in part on a study by Mariani et al, where treatment with para-aortic lymphadenectomy was compared with that without para-aortic lymphadenectomy in 131 patients. Here, an increase in relapse-free survival from 62 % to 77 % with para-aortic lymph node removal was shown for the whole cohort. However, these results were not statistically significant (p = 0,12). This situation was different for the subgroup of patients with lymph node involvement. Here, in 51 patients, there was a highly significant increase in relapse-free 5 year survival from 36 % to 76 % if the para-aortic lymph nodes were also removed (p = 0,02) [B04, B05].

Various studies have investigated the possibility of sentinel node biopsy for endometrial cancer. Sentinel node biopsy has been introduced as an alternative to complete lymph node dissection for lymph node staging. When carried out correctly, it appears suitable for confirming pN0. Several studies, including prospective cohort studies, have shown the high sensitivity of the sentinel approach for lymph node staging in patients with early stages of endometrial cancer (clinical stage FIGO I). Extensive pathologic processing and assessment of sentinel lymph nodes (lymph node ultrastaging) contributes to the discovery of small metastases that could be missed with traditional approaches. Sentinel lymph node biopsy without dissection of other pelvic lymph nodes is associated with a lower risk of postoperative morbidity, in particular postoperative lymphedema. Several prospective cohort

studies have shown high sensitivity for detecting lymph node metastases and a high negative predictive value with the use of the sentinel lymph node algorithm for high-risk/high-grade endometrial cancer when used by experienced surgeons. The use of indocyanine green shows higher detection rates than methyl blue. Retrospective studies show similar prognoses for patients following complete lymphadenectomy and sentinel lymph node biopsy. The sentinel technique is therefore now included in current European guidelines [B02]. [B02][B04][B05][P05]

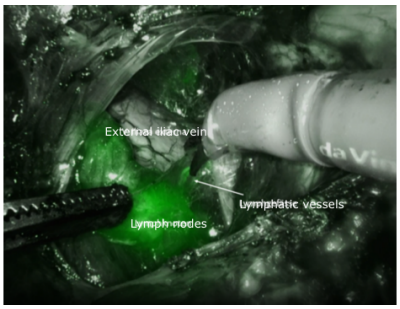

Figure 3: Sentinel node technique: lymph nodes in right pelvic vasculature. Lymph nodes and lymphatic vessels can be identified with indocyanine dye (here injection into the cervical stroma) (with the kind authorization of Prof. Martin Heubner).

According to current AWMF guidelines, radical hysterectomy is also not indicated in stage 2, as there is no positive evidence of a therapeutic effect. In case of clinical invasion of the paracervical structures, the level of radicalness must be expanded to achieve a R0 resection.

To date, it has not been fully clarified whether a modification of the hysterectomy from an ontogenetic perspective (peritoneal mesometrial resection, PMMR) leads to an improved outcome. Preliminary data suggest increased local tumor control [B08]. [B08]

Minimally invasive surgery in the treatment of endometrial cancer

While malignancy was previously largely a contraindication for the use of minimally invasive surgery, this approach now has a well-established role in the treatment of endometrial cancer. The low rate of complications and rapid post-operative mobilization of - often comorbid - patients support this procedure [B07]. Robot-assisted surgical techniques mean that it is now possible to use minimally invasive approaches even for difficult techniques. Long-term results on the oncological equivalent effectiveness of minimally invasive surgery are not yet available. However, applicability data and historical data to date are extremely promising [P10, P12, P13].

For type I => Surgical primary treatment takes place according to FIGO stage and grading: [B07][P10][P12][P13]

Table 5: Procedure depending on FIGO stage

Stage/ grading	Procedure
Ia:G1 (Ib:G1)	Peritoneal cytology Abdominal or laparoscopic hysterectomy with bilateral adnexectomy (salpingo-oophorectomy)
Ia:G3 Ib:G1 - G3	Aforementioned plus: Lymph node staging (pelvic and para-aortic lymphadenectomy versus sentinel node biopsy)
II: G1 - G3	Peritoneal cytology Hysterectomy with bilateral adnexectomy (salpingo-oophorectomy) Lymph node staging (pelvic and para-aortic lymphadenectomy versus sentinel node biopsy)
III, IV	Tumor debulking (poss. exenteration) Local intervention(s) at sites of metastasis

For type II => In principle, surgical lymph node staging, in case of serous histology, carcinosarcoma or undifferentiated carcinoma, peritoneal staging with omentectomy and peritoneal biopsies.

Adjuvant therapy

Adjuvant radiotherapy

No radiotherapy:

- Stage IA G1/G2 with no other risk factors (e.g. p53mut, pronounced LVSI).
- Stages I/II with proven POLE mutation.

Indications for brachytherapy alone:

- Tumors in early stages with elevated risk of local recurrence: FIGO IA G3 /FIGO IB without other risk factors, stage II without risk factors.
- Indications for pelvic teletherapy: Stages IB/II with risk factors, stages III/IV, lymph node involvement, serous histopathology, p53mut.

Type II carcinoma

- Tumors with serous histopathology/p53mut should be treated with brachytherapy in stage I and percutaneous radiotherapy of the pelvis from stage II.
- If percutaneous radiotherapy and adjuvant chemotherapy is indicated, combined radiochemotherapy (along the lines of the PORTEC-3 study) can be considered.

Adjuvant (i.e. postsurgical) irradiation can reduce the local recurrence rate (vaginal, pelvic). Survival is not impacted.

The conclusion of the ASTEC/EN.5 Study Group Study is that external radiotherapy should no longer be used as routine treatment for moderate and high risk endometrial cancer with the goal of increasing survival. However, in FIGO stages III and IVa, it can be used in addition to chemotherapy to improve local follow-up [P08]. [P08]

- No adjuvant radiotherapy takes place in stages Ia (G1, G2) and Ib (G1).
- With high risk of vaginal recurrence: Vaginal brachytherapy for irradiation of the vaginal cuff.

Risk factors in this regard are FIGO I and G3 or pT1b or clear-cell or serous or > FIGO I.

- No more “routine” external irradiation!

Pelvic radiotherapy is also indicated for poorly differentiated carcinoma (G3), with which no staging lymphadenectomy took place.

In the PORTEC 3 study, combined radiochemotherapy with cisplatin, combined with adjuvant chemotherapy over four cycles (carboplatin/paclitaxel) showed no significant advantage in terms of overall survival versus radiotherapy alone. However, the combination did show better progression-free survival in patients in FIGO stage III. The optimal sequence and combination of radiotherapy and chemotherapy for endometrial cancer has not yet been established [B10]. [B10]

Adjuvant cytostatic therapy

Indications for adjuvant chemotherapy:

- Stage III/IV, lymph node involvement, serous histopathology, p53mut.

The adjuvant use of cytostatic agents in situations at high risk of distant metastasis * (e.g. several para-aortic lymph nodes involved or peritoneal metastasis) also provides an advantage versus adjuvant radiotherapy alone in terms of survival.

However, this increased survival means accepting significant side effects (in a mostly older patient cohort).

* overall in the same situation that initiates adjuvant radiotherapy

A Cochrane analysis in both 2011 and 2014 showed an advantage for adjuvant platinum-based chemotherapy for both relapse-free and overall survival, regardless of radiotherapy. In the advanced tumor stages III and IV, the increase in survival was quantified as approx. 25 % [P11, P14]. [P11][P14]

- Effective substance classes: Platinum salts, anthracyclines, taxanes.
- The combination of carboplatin and paclitaxel has been implemented as adjuvant therapy in clinical practice.
- In addition, in cases of high-risk stage I carcinoma, adjuvant chemotherapy should be considered (type 2 carcinoma, type 1: FIGO Ib G3).
- In advanced stages, chemotherapy appears to be more effective than radiotherapy [P09].
  [P09]

Palliative therapy

In case of recurrence, various factors must be taken into consideration for therapy planning:

- Localization and spread
- Tumor properties (above all hormone receptor expression, MMR/MSI status)
- Previous therapies
- Age, general condition and patient's personal preferences

Localized recurrence, for example at the vaginal cuff, can often be treated with surgery and/or radiotherapy (this can often even be curative). Multifocal recurrences and/or distant metastases generally require drug treatment.

Systemic therapy with gestagens, "gestagen therapy"

Well-differentiated endometrial cancer contains progesterone receptors and estrogen receptors and often (in receptor-rich tumors in 70 % of cases) responds to gestagen therapy.

Frequently used substances are medroxyprogesterone acetate (MPA) (Depo-Provera®), and megestrol acetate (DE: Megestat®). Some data are now available on treatment with aromatase inhibitors, suggesting even better efficacy in combination with the CDK4/6 inhibitor palbociclib. The tumor must be hormone-receptor positive.

Indications: Metastatic endometrial cancer, inoperable tumors, tumor residue after palliative surgery or palliative radiation.

Palliative chemotherapy

The same substances that are effective as adjuvant chemotherapy are effective here.

Immunotherapy in palliative care

Immune checkpoint inhibitors are gaining importance in the treatment of advanced endometrial cancer. Other than platinum-based chemotherapy, until recently there were few effective substances, let alone a therapy standard. Tumors with mismatch repair deficiency (dMMR) or high microsatellite instability (MSI-high) often respond well, sometimes for long periods, to immunotherapy. Treatment with the immune checkpoint inhibitor pembrolizumab has thus now become the first-line treatment for MSI-H/dMMR tumors. The substance dostarlimab has also shown a response rate (dMMR, MSI-high) of almost 65 % in advanced stages, with at least stabilization in a further 21 %. In 83 % of patients, there was a long-term response persisting after a follow-up period of over two years.
As not all tumors present these properties (dMMR/MSI-high), studies have investigated whether combination therapy can improve response with other tumor properties. The Keynote-775 study is currently investigating a combination of these two immunotherapeutics in this situation. Combination therapy with lenvatinib and pembrolizumab has shown an improvement in overall survival of almost seven months versus monochemotherapy. These results are encouraging and confirm the growing importance of immunotherapy for gynecological tumors.

Digression - uterine sarcoma

In the case of a large uterus or rapid growth of suspected uterine fibroids, the rare uterine sarcoma must be considered as a DD.

Epidemiology:

- 3 % of malignant uterine tumors are sarcomas

Location:

- mostly in the corpus uteri.

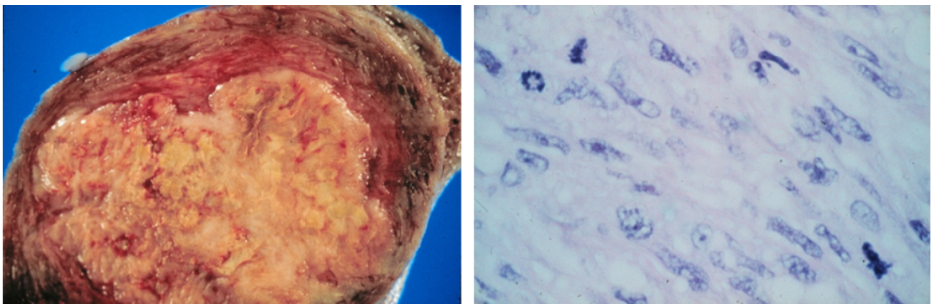

Figure 4: Uterine sarcoma.

Three histopathological types

- Carcinosarcoma (mixed mesodermal müllerian tumor; most commonly uterine sarcoma; average age 60 years)
- Leiomyosarcoma of the uterine wall
- Endometrial stromal sarcoma.

Clinical:

- Symptoms uncharacteristic in general. With rapid growth, pain can be a key symptom due to tumor necrosis.
- Carcinosarcomas penetrate the uterine wall, and are aggressive and often necrotic. Early metrorrhagia and pelvic/hematogenic metastasis are common.
- Leiomyosarcomas most often show a structure similar to fibroids; it can be difficult to distinguish them from fibroids during surgery and even histologically (for leiomyosarcomas: core atypia and mitoses at high numbers). Leiomyosarcomas present hematogenic metastasis. Clinically, bleeding occurs in approx. 1/3 cases - however, leiomyosarcoma is more often an incidental finding in the course of histopathological processing after uterine surgery.
- Endometrial stromal sarcomas show early bleeding. Hematogenic and lymphogenic metastasis.

Diagnosis:

- Sarcomas are of mesenchymal origin (myometrium, stroma) and are therefore not always detected on curettage. Definitive proof is therefore sometimes only obtained from hysterectomy material. Accordingly, if there is clinical suspicion of sarcoma, hysterectomy should be carried out under an oncological perspective (above all avoiding tumor spreading due to morcellation).

Treatment:

- Treatment for uterine sarcoma takes the form of as complete as possible surgical resection (hysterectomy, often combined with bilateral adnexectomy).
- Occasionally, radiotherapy is also used to reduce the risk of local recurrence.

In cases of carcinosarcoma, pelvic and para-aortic lymphadenectomy should also be carried out [P01]. [P01]

In cases of uterine carcinosarcoma, the following surgical staging should take place:

- HE, bilateral adnexectomy, wash cytology and pelvic and para-aortic lymphadenectomy (LNE)

For carcinosarcoma, the following applies:

- 30 % extrauterine manifestations.
- Radiation reduces the risk of local recurrence, but has no influence on overall survival in case of metastasis.
- Cisplatin-ifosfamide-mesna vs. abdominal radiation (stage I-IV) shows a trend for chemotherapy [P01, P02, P03, P04].
  [P01][P02][P03][P04]

Carcinosarcoma response to monotherapy:

- Etoposide (Etopophos®, Etoposid®) → 7 %
- Doxorubicin (Adriblastin®, generic) → 10 %
- Cisplatin (Platinol®, generic) → 18 %
- Ifosfamide (Holoxan®) → 34 %
- Topotecan (Hycamtin®, generic) → 10 %

Prognosis:

- Overall, the prognosis is considerably worse than for endometrial cancer. Five-year survival is 30 % (50 % in early stages, 20 % in advanced stages).

Digression - Incidental diagnosis of sarcoma with suspected

uterine fibroids

- It is known that sarcoma morcellation during surgery worsens a patient's prognosis.
- The use of morcellators is therefore controversial. Morcellation into a specimen pouch to avoid potential tumor cell dissemination is possible, although there is no evidence for their use.
- In any case, the fact that the presence of an incidental sarcoma worsens prognosis should be explained to patients. The probability of this is quantified at approx. 0,25 %.

The risk of a malignant tumor increases with age, with a sharp increase in risk from approximately 50 years. This should be taken into account for investigations and therapy planning.

Literature

Nr.	Title	Author	Journal	Volume	Pages
[B01]	Molecular Classification of the PORTEC-3 Trial for High-Risk Endometrial Cancer: Impact onPrognosis and Benefit From Adjuvant Therapy	Leon-Castillo A et al.	Journal of Clinical Oncology	38(29)	3388-3398
[B02]	ESGO/ESTRO/ESP guidelines for the management of patients with endometrial carcinoma	Concin N, Matias-Guiu X, Vergote I et al.	International Journal of Gynecologic Cancer		
[B03]	Clinicopathological significance of deficient DNA mismatch repair and MLH1 promoter methylation in endometrioid endometrial carcinoma	Pasanen A et al.	Modern Pathology	33 (7)	1443-1452
[B04]	Low-risk corpus cancer: is lymphadenectomy or radiotherapy necessary?	Mariani A et al.	Am J Obstet Gynecol	182(6)	1506-1519

Nr.	Title	Author	Journal	Volume	Pages
[B05]	Prospective assessment of lymphatic dissemination in endometrial cancer: A paradigm shift in surgical staging	Mariani A et al.	Gyncol Oncol	109(1)	11-18
[B06]	Revised FIGO staging for carcinoma of the vulva, cervix, and endometrium	Pecorelli S et al.	Int J Gynecol Obstet	105	103-104
[B07]	Laparoscopy compared with laparotomy for comprehensive surgical staging of uterine cancer: Gynecologic Oncology Group Study LAP2	Walker JL, Piedmonte MR, Spirtos NM, Eisenkop SM, Schlaerth JB, Mannel RS, Barakat R, Pearl ML, Sharma SK	J Clin Oncol	27	5331–5336
[B08]	Embryologically based radical hysterectomy as peritoneal mesometrial resection (PMMR) with pelvic and para-aortic lymphadenectomy for loco-regional tumor control in endometrial cancer: first evidence for efficacy	Kimmig R, Iannaccone A, Aktas B, Buderath P, Heubner M	Arch Gynecol Obstet		

Nr.	Title	Author	Journal	Volume	Pages
[B09]	Is there a survival advantage in diagnosing endometrial cancer in asymptomatic postmenopausal patients? An Israeli Gynecology Oncology Group study	Gemer O et al.	Am J Obstet Gynecol	219(2)	181.e1-181.e
[B10]	Adjuvant chemoradiotherapy versus radiotherapy alone for women with high-risk endometrial cancer (PORTEC-3)	de Boer SM et al.	Lancet Oncology		

Nr.	Title	Author	Journal	Volume	Pages	Y
[P01]	The management of patients with uterine sarcoma: a debated clinical challenge	Gadducci A et al.	Crit Rev Oncol Hematol	65(2)	129-142	2
[P02]	Malignant mixed Müllerian tumors of the uterus: analysis of patterns of failure, prognostic factors, and treatment outcome	Callister M et al.	Int J Radiat Oncol Biol Phys	58(3)	786-795	2

Nr.	Title	Author	Journal	Volume	Pages	Y
[P03]	Phase III randomised study to evaluate the role of adjuvant pelvic radiotherapy in the treatment of uterine sarcomas stages I and II: an European organization for research and treatment of cancer gynaecological cancer group study (protocol 55874)	Reed NS et al.	Eur J Cancer	44(6)	808-818	2
[P04]	A gynecologic oncology group randomized phase III trail of whole abdominal irradiation (WAI) vs. cisplatin-ifosfamide and mesna (CIM) as post-surgical therapy in stage I-IV carcinosarcoma (CS) of the uterus	Wolfson AH et al.	Gynecol Oncol	107(2)	177-185	2

Nr.	Title	Author	Journal	Volume	Pages	Y
[P05]	Excellent long-term survival and absence of vaginal recurrences in 332 patietns with low-risk stage I endometrial adenocarcinoma treated with hysterectomy and vaginal brachytehrapy withour formal staging lymph node sampling: report of a prospective trial	Eltabbakh GH et al.	Int J radat Oncol Biol Phys	38(2)	373-380	1
[P06]	Potential therapeutic role of para-aortic lymphadenectomy in node-positive endometrial cancer	Mariani A et al.	Gynecol Oncol	76(3)	348-356	2
[P07]	Systematic pelvic lymphadenectomy vs. no lymphadenectomy in early-stage endometrial carcinoma: randomized clinical trial	Panici BP et al.	J Natl Cancer Inst	100(23)	1707-1716	2

Nr.	Title	Author	Journal	Volume	Pages	Y
[P08]	Adjuvant external beam radiotherapy in the treatment of endomtetrial cancer (MRC ASTEC and NCIC CTG EN.5 randomissed trials) pooled trial results, systematic review, and meta-analysis	ASTEC/ EN.5 Study Group	Lancet	373	137-146	2
[P09]	Randomized phase III trial of whole-abdominal irradiation versus doxorubicin and cisplatin chemotherapy in advanced endometrial carcinoma: a Gynecologic Oncology Group Study	Randall ME et al.	J Clin Oncol	24(1)	36-44	2
[P10]	J Robotics and gynecologic oncology: review of the literature	Cho JE, Nezhat FR	Minim Invasive Gynecol	16(6)	669-681	2
[P11]	Adjuvant chemotherapy for endometrial cancer after hysterectomy	Johnson N, Bryant A, Miles T, Hogberg T, Cornes P	Cochrane Database Syst Rev			2

Nr.	Title	Author	Journal	Volume	Pages	Y
[P12]	Definition of compartment-based radical surgery in uterine cancer: modified radical hysterectomy in intermediate/high-risk endometrial cancer using peritoneal mesometrial resection (PMMR) by M Hockel translated to robotic surgery	Kimmig R, Aktas B, Buderath P, Wimberger P, Iannaccone A, Heubner M	World J Surg Oncol	11(1)	198	2
[P13]	Definition of compartment based radical surgery in uterine cancer-part I: therapeutic pelvic and periaortic lymphadenectomy by Michael höckel translated to robotic surgery	Kimmig R, Iannaccone A, Buderath P, Aktas B, Wimberger P, Heubner M	ISRN Obstet Gynecol			2
[P14]	Adjuvant chemotherapy for advanced endometrial cancer	Galaal K, Al Moundhri M, Bryant A, Lopes AD, Lawrie TA	Cochrane Database Syst Rev			2

Nr.	Title	Author	Journal	Volume	Pages	Y
[P15]	Pembrolizumab in Patients With Microsatellite Instability-High Advanced Endometrial Cancer: Results From the KEYNOTE-158 Study	O'Malley DM et al.	J Clin Oncol	40(7)	752-761	2
[P16]	LBA28 A randomised double-blind placebo-controlled phase II trial of palbociclib combined with letrozole (L) in patients (pts) with oestrogen receptor-positive (ER+) advanced/ recurrent endometrial cancer (EC): NSGO-PALEO / ENGOT-EN3 trial	Mirza MR et al.	Gynaecological Cancers	31(Supp 4)	1160	2

Nr.	Title	Author	Journal	Volume	Pages	Y
[P17]	Lenvatinib plus Pembrolizumab for Advanced Endometrial Cancer	Makker V et al.	NEJM			2
[P18]	Dostarlimab in EC : The Garnet Study (ASCO 2022 abstract 5509)	Oaknin A et al.	JCO			2