Last update: April 2024

# Gestational trophoblastic diseases (GTD)

Author: PD Dr. med. Edward Wight

ehem. Chefarzt Gynäkologie und gyn. Onkologie (pensioniert seit März 2017), Universitätsfrauenklinik Basel

Co-Author(s): Dr méd. Manuela Undurraga, Prof. Dr. med. Patrick Petignat

# Introduction and definition

Gestational trophoblastic diseases (GTD) comprises a heterogeneous group of diseases originating from the trophoblastic epithelium of the placenta after "normal" or "abnormal" fertilization. Therefore, this maternal disease does not develop from maternal but from fetal tissue. The WHO distinguishes between benign (complete or partial) hydatidiform moles which are limited to the uterine cavity and 5 malignant forms of GTD: Malignant invasive mole, choriocarcinoma, atypical placental site nodule (APSN), placental site trophoblastic tumor (PSTT), and epithelioid trophoblastic tumors (ETT). The malignant forms of GTD are termed gestational trophoblastic neoplasia (GTN). GTN's may develop after different types of antecedent pregnancies (normal pregnancy, miscarriage, ectopic pregnancy, abortion), but particularly often after a hydatidiform mole. The clinical course (tumor progression, myometrial invasion, and metastases) can vary significantly; quickly proliferating and metastasizing tumor types are highly sensitive to chemotherapy. Consequently, even tumors in advanced and metastatic stages can often be cured with chemotherapy.

## Classification of GTD

Benign GTD

- Complete hydatidiform mole
- Partial hydatidiform mole
- Other benign trophoblastic lesions are rare: exaggerated placental site (EPS), placental site nodule (PSN) (hCG-testing for follow-up not needed)

Malignant GTD (GTN)

- Malignant invasive mole (chorioadenoma destruens)
- Choriocarcinoma
- Atypical placental site nodule (APSN)
- Placental site trophoblastic tumor (PSTT)
- Epithelioid trophoblastic tumor (ETT)

# Hydatidiform moles

(= Molar Pregnancy)

Complete hydatidiform moles (CHM) differ significantly from partial hydatidiform moles (PHM) in terms of their cytogenetic, histological, clinical, and prognostic characteristics.

## Epidemiology and risk factors

There are major geographic differences in the incidence of hydatidiform moles:

- Europe, North America: 0,5–1/1000 pregnancies
- Japan, China, South Korea: 2/1000 pregnancies
- Latin America, Africa: 0,5–4,5/1000 pregnancies (limited data!)
- South-East Asia (Indonesia, India): up to 12/1000 pregnancies (though recent studies indicate lower incidence, correlating with an increase of the Gross National Product = GNP)

The causes of this geographical frequency distribution are unknown. Dietary factors, maternal age, ethnicity (Non-white Hispanic women, American Indians, Alaskan Natives and Asian women have a higher incidence of hydatidiform moles compared to Caucasian and Black women), poor social-economic conditions and infections are being evaluated as possible reasons for this disparity.

Risk factors for developing hydatidiform moles are:

- Maternal age: < 16 years on the one hand, > 40 years on the other (relative risk: 5–10x); women above 40 are more likely to develop a malignant trophoblastic tumor after evaquation of a hydatidiform mole
- Previous GTD (risk of relapse: 1 to 2 %)
- Ethnicity
- Infertility?
- Malnutrition?
- Nicotine abuse?

From a pathogenetic perspective, oncogenes (activation of oncogenes and inactivation of tumor suppressor factors: c-myc, c-erbB2, bcl-2, Rb, EGFR, NLRP7, KHDC3L, PD-L1, and metalloproteinases) seem to play a role in the development of hydatidiform moles and/or malignant gestational trophoblastic disease.

In Europe, partial hydatidiform moles (PHM) are twice as frequent as complete hydatidiform moles (CHM).

Table 1

| | **Complete hydatidiform moles (CHM)** | **Partial hydatidiform moles (PHM)** |
|---|---|---|
| Genetics (illustration 1) | Almost always diploid (usually 46xy, rarely 46xx) | Almost always triploid (69xxx, 69xxy, 69xyy) |
| Chromosomes | Usually: Paternally inherited only: Fertilization of an anucleate ovum by 1 haploid, X-chromosome-carrying sperm and duplication of the paternal set of chromosomes, or fertilization by 2 sperms<br>Very rare: Diploid, biparental complete hydatidiform mole (autosomal recessive: increased risk of recurrence, familial biparental hydatidiform mole (FBHM)) | Paternally and maternally inherited: Fertilization of a normal haploid ovum by 1 sperm and duplication of the paternal set of chromosomes, or fertilization by 2 sperms |
| Fetus | None (no chorionic cavity) | Stigmata of triploidy in fetuses: Malformations, growth retardation |
| Fetal erythrocytes | None | Usually present |
| Hydropic villi | Diffuse, pronounced (illustration 2) | Focal, minimal |
| Trophoblastic hyperplasia | Common | Focal, minimal |
| Atypia | Moderate to significant | Focal, minimal |

| | Complete hydatidiform moles (CHM) | Partial hydatidiform moles (PHM) |
|---|---|---|
| Diagnostics | Negative immunohistochemistry for P57KIP2 | In situ hybridization or flow cytometry |
| Clinic (see below) | Molar pregnancy | Missed abortion |
| Size of the uterus | Larger than expected from the duration of amenorrhea (50 % of cases) | Smaller than expected from the duration of amenorrhea |
| Complications | 10–25 % | Rare |
| Progression to GTN | 15–20 % | 0,5–5 % |

Figure 1: Genetic origin of molar pregnancies (modified based on [15]).
Part 1: Monoparental, monospermic, complete hydatidiform mole (CHM), chromosomes entirely of paternal origin, but mitochondrial DNA remains of maternal origin. [15]

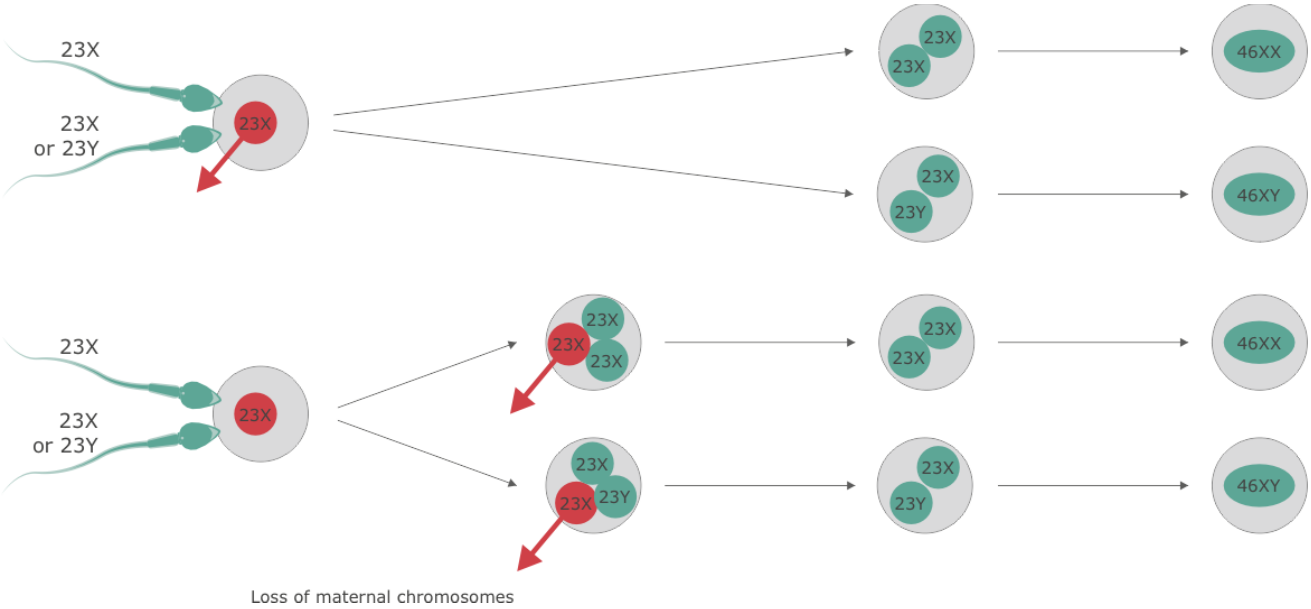


Figure 1: Genetic origin of molar pregnancies (modified based on [15]).
Part 2: Monoparental, di-spermic, complete hydatidiform mole (CHM), chromosomes entirely paternal origin. [15]

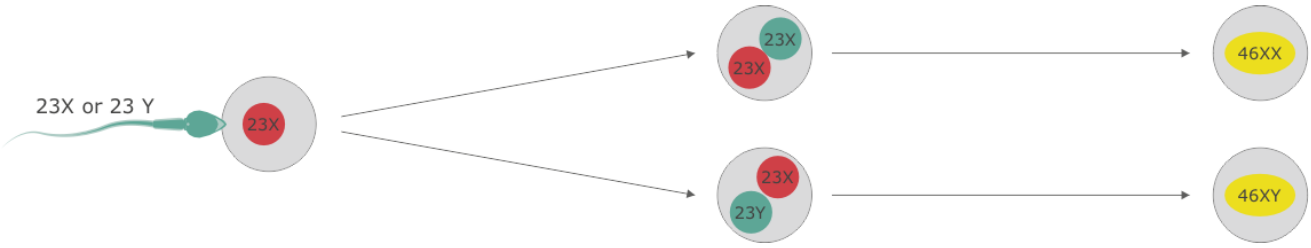


Figure 1: Genetic origin of molar pregnancies (modified based on [15]).
Part 3: Biparental, monospermic, complete hydatidiform mole (CHM). Chromosomes of maternal and paternal origin; occurrence in females who are homozygous, or compound heterozygote, for mutations in NLRP7 or KHDC3L, resulting in familial recurrent hydatidiform moles. [15]

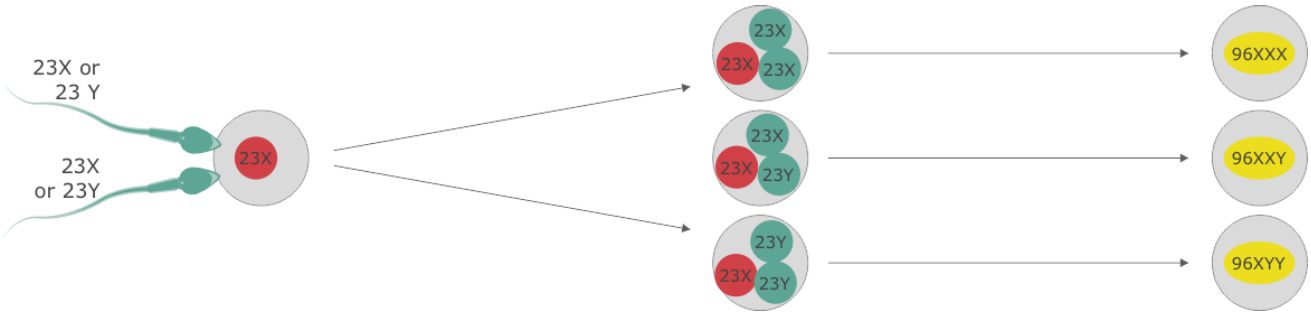


Figure 1: Genetic origin of molar pregnancies (modified based on [15]).
Part 4: Biparental, di-spermic, partial hydatidiform mole (PHM). Chromosomes of maternal and paternal origin. [15]

Figure 2: Hydropic villi.

## Clinical picture

Complete hydatidiform mole is usually diagnosed in the first trimester. This is earlier than described in historical cohorts thanks to the increased use of ultrasound and improved quality of beta-hCG tests.

Most of the classic symptoms used to describe complete hydatiform moles are more frequent starting the 2nd trimester, which means that symptoms at the time of diagnosis are less pronounced today:

- Vaginal bleeding
- Elevated beta-hCG values (> 100'000 U/L)
- Anemia
- Uterus much larger than expected from gestational age
- Adnexal cysts with a diameter of more than 5 cm (theca-lutein cysts, hCG-related)
- Hyperemesis gravidarum
- Preeclampsia
- Hyperthyroidism

Vaginal bleeding is the most common symptom of complete hydatidiform moles. Today, anemia occurs in only 5 % of cases (previously: > 50 %). Preeclampsia occurs in < 2 % of patients (previously: approx. 15 %). Serum beta-hCG values above 100,000 U/L are measured in almost half of women with complete hydatidiform mole and are an essential requirement for the development of theca-lutein cysts of the ovaries. Though rare, these cysts may cause acute abdominal pain through torsion or cyst rupture.

A partial hydatidiform mole is usually an incidental finding today during histological examination of curettage material after supposed incomplete or missed abortion, or if fetal trisomy is suspected during routine first trimester ultrasound.
A size of uterus, larger than expected for the gestational age is rarely observed, and beta-hCG values above 100’000 U/L occur only in 7 % of cases.

## Diagnostics

- Quantitative determination of beta-hCG in serum
- Ultrasound, Doppler
- Histopathology, immunohistochemistry, flow cytometry

The classical ultrasound findings considered characteristic of a complete hydatidiform mole is a complex, hyperechogenic intracavitary mass with numerous small cysts (corresponding with the hydropic villi). This is seen less and less because of early diagnosis of complete mole.

Sonographic findings of partial hydatidiform moles are less characteristic. Therefore, the diagnosis of partial hydatidiform mole is suspected less frequently by ultrasound and established only after histological examination of tissue from miscarriage or curettage.
A sonogram with cystic lesions in the placenta and an empty amniotic sac or signs of missed abortion may be suggestive for a partial hydatidiform mole. The ratio of the transversal compared to the anterior-posterior diameter of the gestational sac is typically greater than 1.5 if a partial hydatidiform mole is present (illustration 3).

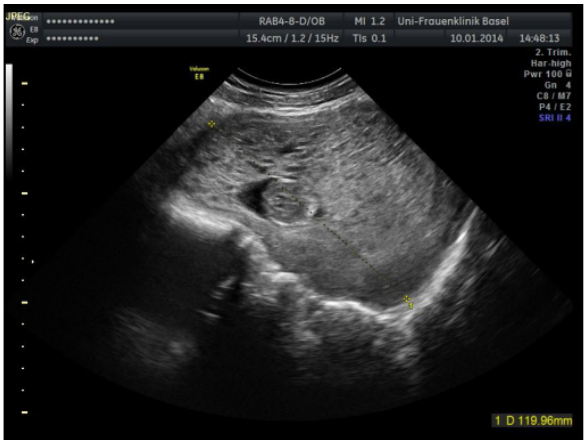


Figure 3: Partial hydatidiform mole, 13th week of gestation, beta-hCG > 1 x 106 IU/L.

Despite all sonographic criteria, the diagnosis of a hydatidiform mole is suspected preoperatively in less than 50 % of all cases that are later confirmed by the subsequent histological examination of the aborted material.

The insufficient diagnostic specificity of ultrasound examinations is also important in view of the potential of subsequent progression to GTN of hydatidiform moles. This is especially the case if no routine histological examination of the trophoblastic/ placental material is performed after termination of pregnancy or normal birth, respectively.

## Therapy

Hydatidiform moles are treated by suction, preferably monitored under ultrasound guidance. Curettage is avoided as much as possible to avoid scarring of the uterus (Asherman Syndrome):

- Though rare during suction, embolization of trophoblastic material into the circulation and the lungs via uterine veins can lead to respiratory insufficiency. This can happen particularly when oxytocin or other uterotonic medications (prostaglandins) are used prior to the dilatation of the cervix (No medical induction of labour!). Therefore, oxytocin should only be used after intraoperative dilatation of the cervix.
- During evacuation of the uterine cavity by means of suction, the myometrium should be stimulated with intravenous oxytocin to promote uterine contraction to reduce blood loss and to decrease the risk of uterine perforation (especially in cases of advanced complete hydatidiform mole and marked dilatation of the uterus).
- Oxytocin should be continued postoperatively to reduce the likelihood of hemorrhage.

- Rhesus negative women require rhesus prophylaxis! (Anti-D immunoglobulin, e.g. Rhophylac® 300)

Women must be monitored closely after a complete or partial hydatidiform mole because of the risk of progression to GTN. Ideally, women should be registered in centralized centers to aide in their follow-up, for this has shown a decrease in mortality and morbidity in GTD patients.

The following postoperative follow-up schedule has proven to be effective.

For partial hydatidiform moles:

- Serial, quantitative, biweekly beta-hCG tests should be obtained until the beta-hCG value is negative. The value of negative will depend on the laboratory and is variable.
- Once beta-hCG tests become negative, two further beta-hCG tests at 2 weeks interval should be performed. If the results stay negative, no further follow-up is needed.

For complete hydatidiform moles:

- Serial, quantitative, biweekly beta-hCG tests should be obtained until the beta-hCG value is negative.
- If beta-hCG values become negative within 8 weeks after curettage, further beta-hCG tests in monthly intervals should be performed for 6 months.
- If beta-hCG values become negative later than 8 weeks after curettage, further monthly beta-hCG tests should be done for 6 months after negativity had been attained.
- If beta-hCG levels plateau or rise (examples: four or more beta-hCG values with a plateau over at least three weeks (days 1, 7, 14, and 21), persistent beta-hCG values more than six months after removing a molar pregnancy, or a renewed increase of beta-hCG values by at least 10 % for three or more tests over at least two weeks (days 1, 7, 14)), the patient has to be considered to have malignant disease (GTN), metastatic lesions need to be excluded. Additional therapy is indicated and can be systemic chemotherapy or further surgery, depending on individual findings.
- During follow-up a further pregnancy must be avoided with effective contraception (preferred oestro-progestative) to ensure reliable assessment of beta-hCG testing.

The European Organization for the Treatment of Trophoblastic Diseases (EOTTD) discourages prophylactic chemotherapy.

## Pregnancy after hydatidiform mole

Patients after molar pregnancies can expect similar reproductive outcomes as compared to the general population. In a Swedish study a history of a hydatidiform mole was associated with an increased risk of preterm delivery in women exposed to a molar pregnancy prior to the index birth. The risk of repeat mole was 0,4 %.

## Coexisting normal pregnancy with mole

Molar pregnancy rarely coexists with normal pregnancy. Although there is a high risk of spontaneous abortion, about 40 to 60 % result in live births. Most of these births will be extreme pre-term, as one of the most frequent complications is pre-eclampsia. The risk of progression to GTN in coexisting molar and normal pregnancy is increased compared to singleton molar pregnancy (27 to 46 % compared to 15 to 20 %, respectively).

## Risk of recurrence

Women who had experienced an initial molar pregnancy have an increased risk of recurrence of about 1 %, compared to the normal population (10 times elevated). This risk is associated with complete molar pregnancy rather than partial molar pregnancy. The risk of a third hydatidiform mole is associated almost exclusively with previous complete molar pregnancies and particularly with the rare condition of “familial recurrent hydatidiform moles (FRHM).

# Malignant forms of GTD (GTN)

Invasive mole (Chorioadenoma destruens)

- Histologically characterized by the myometrial invasion of hydropic, proliferative chorionic villi.
- Locally destructive proliferation. Typical consequences: uterine perforation, bleeding, infections.

Choriocarcinoma

- Histologically purely epithelial tumor consisting of neoplastic cytotrophoblastic and syncytiotrophoblastic components without chorionic villi.
- Highly malignant! Initial clinical manifestations are typically caused by hematogenic metastatic disease (predominantly to the lungs in 80 % of cases; to the vagina in 30 %, to the liver and the brain in 10 % of cases), which can become extensive during the course of the disease. Intraabdominal and intracerebral bleeding, originating from metastases to the liver and to the brain, can be life threatening.

Atypical placental site nodule (APSN), placental site trophoblastic tumor (PSTT), epithelioid trophoblastic tumor (ETT)

- Precursor lesion of PSTT or ETT (see below), hCG levels not elevated at presentation or during follow-up; presence of APSN should indicate a thorough clinical and radiologic investigation and follow-up
- Very rare (approx. 0,2 % of all GTNs)! Histologically characterized by a proliferation of intermediate trophoblastic cells and a lack of chorionic villi, and to a large extent also a lack of syncytiotrophoblastic cells, resulting in low serum-hCG values in these tumors.
- Typically, the tumor-inducing pregnancy dates back several years before clinical symptoms appear at the former site of placental implantation (PSTT) or in the area of the chorion leave (ETT). Unlike to the other GTNs, PSTTs and ETTs do not respond well to chemotherapy, so their prognosis in advanced tumor stages is comparatively less favorable.

GTNs occur:

- After hydatidiform mole
- After normal pregnancy
- After miscarriage, abortion, or ectopic pregnancy

## Clinical Picture

Each of the following clinical situations may indicate a GTN:

- Plateau formation or renewed increase of beta-hCG values (Beta-hCG > 5 IU/L) (see above)
- Persistent elevation of beta-hCG for 6 months after removing a hydatidiform mole (Beta-hCG > 5 IU/L) (see above)
- Vaginal bleeding combined with high beta-hCG values after miscarriage, abortion, ectopic pregnancy, or delivery at term!
- Metastases of an "unknown" primary tumor in premenopausal women!

## Diagnostics

If a GTN is suspected, diagnosis and therapy must be initiated immediately because symptoms often develop rapidly (at times dramatically fast). To decrease mortality rates, treatment should be coordinated with GTD reference centers at the University Hospital of Geneva (HUG) or at the University Hospital of Zurich (USZ), Women's Clinic, Department of Gynecology.

- Medical history
- Clinical examination
- Laboratory testing: hematology, coagulation, blood chemistry, beta-hCG
- Imaging: transvaginal ultrasound (color Doppler), thorax radiograph, and, in case of suspected lung metastasis: Computed tomography (Chest-CT scan, abdomino-pelvic CT scan), MR imaging of the brain (always indicated if lung metastases are found). PET-CT may be indicated in special situations (evaluating disease recurrence that may not be detected at conventional imaging).
- Histological verification of GTN is not necessary, i.e. therapy should be started even without or prior to histologic diagnosis.

## Staging and Scoring

GTN is both staged anatomically and scored (risk-based). This helps to localize the tumor, as well as to define the risk of treatment resistance and metastasis.

Table 2: WHO Staging

| | |
|---|---|
| Stage 1 | Tumor confined to uterus |

| | |
|---|---|
| Stage 2 | Tumor exceeds the anatomical boundaries of the uterus. Extension to the vagina and pelvic structures (ovaries, fallopian tubes, broad ligament of the uterus) by metastasis or direct extension. |
| Stage 3 | Lung metastases with or without tumor involvement of the uterus, vagina or pelvis |
| Stage 4 | Metastases to organs other than the lungs (brain, liver, kidneys, gastrointestinal tract, etc.) |

## FIGO risk score 2000 for malignant trophoblastic neoplasia (GTN)

Table 3: FIGO risk score 2000 for malignant trophoblastic neoplasia. The score does not apply to PSTT and ETT (placental site trophoblastic tumor/epithelioid trophoblastic tumor). (Legend: Interpretation/risk category: 0–6 low risk; 7–12 high risk; > 12 ultra-high risk)

| Points | 0 | 1 | 2 | 4 |
|---|---|---|---|---|
| Age at diagnosis | < 40 | ≥ 40 | - | - |
| Antecedent pregnancy | Hydatidiform mole | Miscarriage | Full-term pregnancy | - |
| Interval between previous pregnancy and start of chemotherapy (months) | < 4 | 4-6 | 7-12 | > 12 |
| Pretreatment serum Beta-hCG value (U/L) | < 10^3 | 10^3-10^4 | 10^4-10^5 | ≥ 10^5 |
| Largest tumor diameter (cm) | < 3 | 3–5 | > 5 cm | - |
| Site of metastases | Lung, vagina | Spleen, kidney | Gastrointestinal tract | Brain, liver |

| Points | 0 | 1 | 2 | 4 |
|---|---|---|---|---|
| Number of metastases | 0 | 1-4 | 5-8 | > 8 |
| Previous failed chemotherapy | - | - | Monochemotherapy | Polychemotherapy |

# Therapy

- Invasive mole and choriocarcinoma respond very well to chemotherapy, even in metastatic stages.
- The cure rate for "low risk GTNs" is almost 100 %.
- Surgery may be considered in some cases of low risk GTN in selected cases of residual disease.
- "High risk" and "ultra-high risk GTNs" can often be cured with polychemotherapy, occasionally in combination with radiotherapy and surgical intervention (e.g. for emergency situations caused by bleeding of intra-cerebral or intra-abdominal metastases)
- In case of chemoresistance immunotherapy with checkpoint inhibitors offers a new form of salvage therapy
- A curative therapeutic approach must always be intended even in the case of metastases at multiple sites.
- The choice of chemotherapy regimen is based on tumor staging, GTN risk profile (according to FIGO risk score 2000), and in consideration of any previous therapies.

## Therapeutic approach in accordance with FIGO risk score 2000

Table 4: Therapeutic approach in accordance with FIGO risk score 2000

| Low risk GTN (FIGO ≤ 6) | High risk GTN (FIGO 7–12) & ultra-high risk GTN (FIGO > 12) | PSTT, ETT |
|---|---|---|

| Low risk GTN (FIGO ≤ 6) | High risk GTN (FIGO 7–12) & ultra-high risk GTN (FIGO > 12) | PSTT, ETT |
|---|---|---|
| Monochemotherapy: Methotrexate with or without folic acid rescue (Leucovorin®) (depending on the schema used) or dactinomycin = actinomycin D (Cosmegen®) | Polychemotherapy: e.g., EMA/CO (etoposide (Vepesid®), methotrexate, actinomycin D (Cosmegen®), cyclophosphamide (Endoxan®), vincristine (Oncovin®)), EMA-EP in ultra-high risk GTN (FIGO > 12), Salvage immunotherapy with checkpoint inhibitors (Pembrolizumab) | Both tumor types only respond to chemo-therapy to a limited extent (20 %). Therefore, the primary therapy should be hysterectomy, especially if family planning is completed and/or the tumor persists after chemotherapy.<br>In unfavorable prognostic situations after hysterectomy an adjuvant therapy with checkpoint inhibitors may be considered. |

- Radiological follow-up of previously known metastatic sites should be performed after normalization of beta-hCG values as baseline for future imaging
- After successful treatment of GTN, the risk of relapse is about 3 % and most occur in the first year of follow-up. After completion of chemotherapy (therapeutic and consolidation courses) beta-hCG levels should be monitored weekly for 6 weeks and then in bi-weekly intervals for up to 6 months (at the beginning with blood samples, after 6 months urine samples are sufficient). Afterwards the patients require long-term follow-up by means of monthly beta-hCG testing (after monochemotherapy: lasting for 12 months after beta-hCG-levels returned to normal (< 5 IU/L); after polychemotherapy: lasting for 18-24 months after beta-hCG levels returned to normal), so that relapse can be promptly diagnosed.
- During the follow-up period a reliable form of hormonal contraception is mandatory and excessive UV light exposure should be avoided for 1 year to prevent UV-induced skin toxicity after chemotherapy.

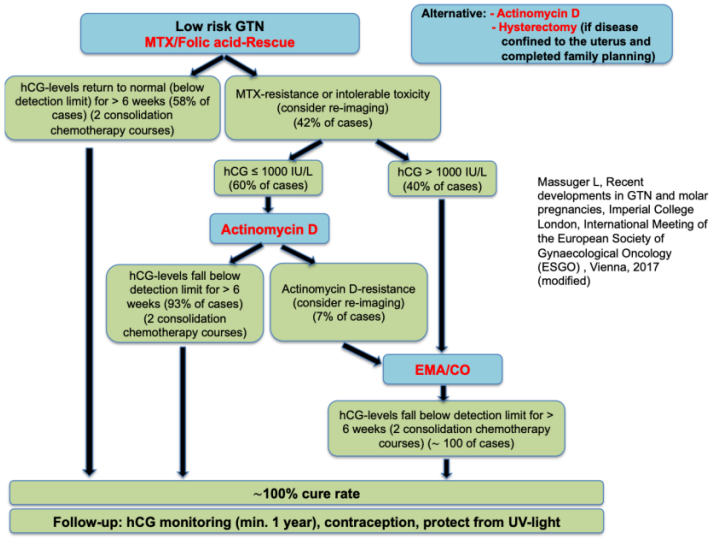


Figure 4: Low risk GTN (modified by [20]). [20]

In general, primary monochemotherapy is used for low risk GTN (FIGO ≤ 6): Methotrexate (MTX) with/without folic acid rescue (Leucovorin®) (depending on the schema), or dactinomycin = actinomycin D (Cosmegen®). In case of tumor persistence or relapse, salvage chemotherapies, usually polychemotherapies are recommended.

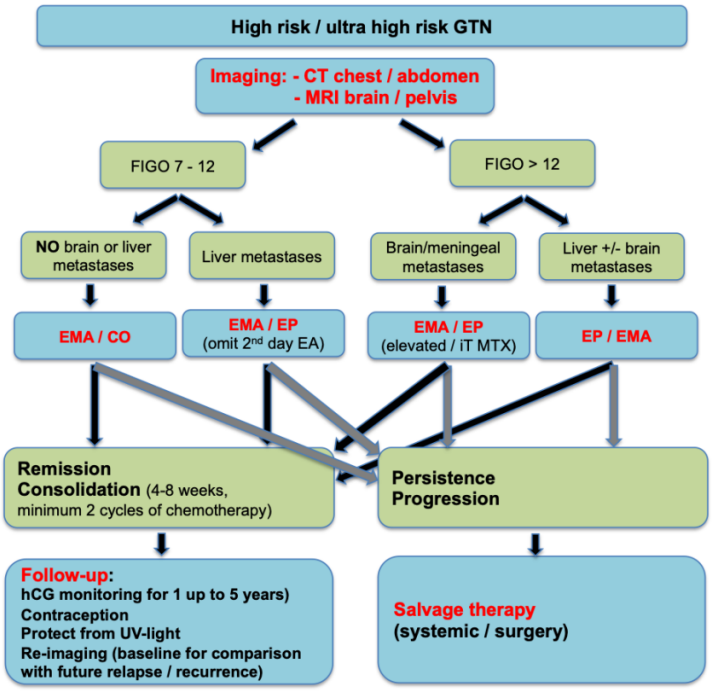


Figure 5: High risk GTN and ultra-high risk GTN (modified by [8]). [08]

High risk GTN (FIGO 7-12) and ultra-high risk GTN (FIGO > 12) are primarily treated with polychemotherapy (e.g., EMA-CO, EMA-EP, see below). Additional polychemotherapies including carboplatin, taxanes, and/or ifosfamide and recently an immunotherapy with checkpoint inhibitors are indicated as salvage therapies. PSTT (placental site trophoblastic tumor) and ETT (epithelioid trophoblastic tumor) show only a limited response to chemotherapy. Therefore, the tumor should be surgically resected (with hysterectomy or – in early stages and if family planning is not completed – with uterus-preserving surgery), often combined with an adjuvant systemic therapy (chemotherapy, Immunotherapy).

## Chemotherapy regimens for treatment of GTN

### 5-day methotrexate (MTX) regimen

MTX 0,4 mg/kg body weight (max. 25 mg/day) IV or IM on day 1 to 5; repeat every 2 weeks.

### 8-day regimen with methotrexate (MTX) combined with folic acid (Leucovorin®) = Leucovorin rescue

Table 5: 8-day regimen with methotrexate (MTX) combined with folic acid

| Day | | 1 | 2 | 3 | 4 | 5 | 6 | 7 | 8 |
|---|---|---|---|---|---|---|---|---|---|
| MTX | 1 mg/kg body weight IM | X | | X | | X | | X | |
| Folic acid | 0,1 mg/kg body weight PO or IM | | X | | X | | X | | X |

Repeat every 2 weeks. After beta-hCG is normalized (<5 IU/L), a minimum of 2 consolidation chemotherapy cycles should be given.

Toxicity

- Nausea
- Mucositis
- Blepharitis
- Conjunctivitis
- Myelosuppression
- No alopecia

### 5-days Dactinomycin = actinomycin D (Cosmegen®)

Dactinomycin 12 µg/kg body weight (or 0,5 mg total dose) IV, daily for 5 consecutive days. Repeat every 2 weeks.

Toxicity

- Highly emetogenic chemotherapy regimen: Antiemetics are indicated: tropisetron (Navoban®), ondansetron (Zofran®), aprepitant (Emend®)
- Alopecia
- High local tissue toxicity (CAUTION: extravasation)

### EMA-CO [etoposide (Vepesid®), methotrexate, dactinomycin = actinomycin D (Cosmegen®), cyclophosphamide (Endoxan®), vincristine (Oncovin®)]

Table 6: EMA

| | | |
|---|---|---|
| Day 1 | Etoposide<br>MTX<br>Dactinomycin | 100 mg/m2 as an infusion over 2 hrs<br>100 mg/m2 as an IV bolus, followed by 200 mg/m2 as an infusion over 12 hrs<br>0,5 mg as an IV bolus |
| Day 2 | Etoposide<br>Dactinomycin<br>Folic acid | 100 mg/m2 as an infusion over 2 hrs<br>0.5 mg as an IV bolus<br>15 mg PO or IM, q12h, 4x, starting 24 hrs after MTX |

Table 7: CO

| | | |
|---|---|---|
| Day 8 | Cyclophosphamide<br>Vincristine | 600 mg/m2 as an infusion over 1/2 hr<br>1 mg/m2 IV (maximum dose: 2 mg) |

Repeat every 2 weeks.

Toxicity

- Alopecia
- Myelosuppression (sometimes granulocyte colony stimulating factors = G-CSF necessary)
- CAUTION: Decreased fertility (EMA-CO therapy advances the onset of menopause by 3 years), secondary malignancies

### EMA-EP (etoposide (Vepesid®), methotrexate, dactinomycin = actinomycin D (Cosmegen®), cisplatin (Platinol®))

Table 8: EMA

| | | |
|---|---|---|
| Day 1 | Etoposide<br>MTX*<br>Dactinomycin | 100 mg/m2 IV as an infusion over 2 hrs<br>100 mg/m2 as an IV bolus, followed by 200 mg/m2 IV as an infusion over 12 hrs<br>0,5 mg as an IV bolus |

| | | |
|---|---|---|
| Day 2 | Etoposide<br>Dactinomycin<br>Folic acid | 100 mg/m2 IV as an infusion over 2 hrs<br>0,5 mg as an IV bolus<br>15 mg PO or IM, q12h, 4x, starting 24 hrs after start of MTX |

Table 9: EP

| | | |
|---|---|---|
| Day 8 | Etoposide<br>Cisplatin | 100 mg/m2 IV as an infusion over 2 hrs<br>75 mg/m2 IV as an infusion (3 liters) over 12 hrs |
| Day 9–13 | Filgrastim | 300 mcg SC per day |

Repeat every 2 weeks.

*In case of brain metastases consider an increase of the MTX dose: 1000 mg/m2 IV as an infusion over 24 hours followed by leucovorin rescue: 15 mg every 6 hours for 12 doses, starting 32 hours after the start of the MTX-infusion

### EP-EMA (etoposide (Vepesid®), cisplatin (Platinol®), (etoposide (Vepesid®), methotrexate, dactinomycin = actinomycin D (Cosmegen®))

Table 10: EP

| | | |
|---|---|---|
| Day 1 | Etoposide<br>Cisplatin | 150 mg/m2 IV as an infusion over 2 hrs<br>75 mg/m2 IV as an infusion (3 liters) over 12 hrs |
| Day 3–6 | Filgrastim | 300 mcg SC per day |

Table 11: EMA

| | | |
|---|---|---|
| Day 8 | Etoposide<br>MTX<br>Dactinomycin | 100 mg/m2 IV as an infusion over 2 hrs<br>300 mg/m2 IV as an infusion over 12 hrs<br>0,5 mg as an IV bolus |
| Day 9–10 | Folic Acid | 15 mg PO or IM, q12h, 4x, starting 24 hrs after start of MTX |
| Day 10–13 | Filgrastim | 300 mcg SC per day |

Repeat every 2 weeks.

### Other chemotherapy regimens

- BEP: Bleomycin, Etoposid (Vepesid®), Cisplatin (Platinol®)
- ICE: Ifosfamide (Holoxan®), Carboplatin (Paraplatin®), Etoposide (Vepesid®)
- MAC: MTX, Dactinomycin = Actinomycin D (Cosmegen®), Cyclophosphamide (Endoxan®), folic acid rescue (Leucovorin®)
- PC: Paclitaxel (Taxol®) (175 mg/m2), Carboplatin (6 AUC) every 3 weeks
- PVB: Cisplatin (Platinol®), Vinblastine (Velbe®), Bleomycin (e.g., Bleomycin Baxter®)
- TIP: Paclitaxel (Taxol®), Ifosfamide (Holoxan®), Cisplatin (Platinol®)
- TP/TE: Paclitaxel (Taxol®), Etoposide (Vepesid®), Cisplatin (Platinol®)
- VIP: Etoposide (Vepesid®), Ifosfamide (Holoxan®), Cisplatin (= Platinol®)

In case of very advanced GTN, the EMA-CO regimen can lead to severe bleeding and organ failure. Therefore, careful induction therapy with low-dose etoposide (Vepesid®) (100 mg/m2) combined with cisplatin (Platinol®) (20 mg/m2) may be indicated on days 1 and 2, repeated weekly, 3 times. To reduce duration and severity of chemotherapy-induced neutropenia of various chemotherapy regimens the administration of filgrastim or pegfilgrastim (Neulasta®) may be indicated.

Malignant gestational trophoblastic disease is rare in Europe. Therefore, the chemotherapies described, especially the salvage therapies, should only be performed in specialized institutions or after consulting with experienced interdisciplinary teams.

### Recent Developments in the Systemic Therapy of GTN

- Immunotherapy: The activity of the immune system is regulated by checkpoints. An important role of immune checkpoints is the prevention of immunological autoaggression, resulting in autoimmune diseases. The PD-1 receptor is such a checkpoint, which, binding to his ligand (PD-L1), leads to a blockage/inactivation of cytotoxic cells. Tumors expressing PD-L1 (like all histological subtypes of gestational trophoblastic neoplasia) can weaken or deactivate immunological tumor defense through this mechanism. Checkpoint inhibitors are monoclonal antibodies directed to either the PD-1-receptor or to PD-L1 and consequently prevent binding and interaction of PD-1-receptor with its ligand. As a consequence, immunological tumor defense mechanisms are enhanced, which permits to anticipate therapeutic success using checkpoints inhibitors in gestational trophoblastic disease, as these tumors represent a semi- or fully allogeneic transplant. Case reports and small studies have documented long lasting remissions using checkpoint inhibitors (e.g. anti-PD-1-

receptor antibody pembrolizumab = Keytruda®) as a salvage therapy in chemotherapy resistant, recurrent and high risk GTN. Side effects of checkpoint inhibitors include (as expected) various autoimmune diseases.
- Targeted therapy: Unlike PSTT, choriocarcinoma is characterized by a high concentration of metalloproteinases. Studies are being conducted to test whether metalloproteinase inhibitors could be a therapeutic option for chemotherapy-resistant choriocarcinoma. In contrast, PSTT, which typically responds poorly to chemotherapy, strongly expresses VEGF (vascular endothelial growth factor) and angiopoietin 1 and 2. Therefore, therapeutic use of VEGF inhibitors like bevacizumab (Avastin®) with or without anti-endoglin antibodies are being investigated. Another promising therapeutic option for chemotherapy-resistant GTN may be the monoclonal antibody pembrolizumab (Keytruda®), which acts on programmed cell death ligand 1 (PD-L1), which is strongly expressed in GTN. The mechanism of action probably utilizes the activation of immunocompetent cells (T cells, NK cells).

## Surgical Therapy of GTN

Indications for hysterectomy

- In early stages of GTN and for women who completed their family planning, prior to starting chemotherapy in order to prevent the development of chemotherapy-resistant (intrauterine) tumors
- Primary therapy for PSTT and ETT in stages 1 and 2
- Secondary therapy (after chemotherapy) for chemotherapy-resistant uterine tumors
- In case of uncontrollable vaginal bleeding or intra-abdominal bleeding from the uterus
- Patients above the age of 40 are more likely to develop GTN after removal of a complete hydatidiform mole (40+ years: 53 %, 50+ years: 60 %). For this reason, hysterectomy may be indicated in case of completed family planning.

During hysterectomy, the uterus should be manipulated as little as possible to prevent embolization of trophoblastic material into the circulation and the lungs via uterine veins that can lead to respiratory insufficiency.

Uterus-preserving surgery

- This can be evaluated in early stage, low risk PSTT and ETT (restricted to the uterus) in young women with strong desire to preserve fertility.

Surgery in case of complications (usually bleeding) caused by metastases

- Craniotomy for intra-cerebral metastases
- Laparotomy for liver metastases
- Thoracotomy, segmental lung resection for lung metastases
- Extirpation of vaginal metastases

## Radiotherapy of GTN

In case of brain metastases (combined with MTX). Whole brain radiation is controversial because of associated long-term toxicity and unclear evidence whether it improves survival. Possible alternatives are stereotactic radiotherapy or the use of the Gamma Knife.

## Follow-up after GTN

Follow-up after completed chemotherapy with beta-hCG tests has to be implemented depending on the risk situation. Note that GTN lesions may secrete fragmented hCG molecules. Therefore, hCG test systems have to be used which can recognize hCG fragments and metabolites (for example: Siemens IMMULITE ®).

After successful treatment of GTN, the risk of relapse is about 3 % and most occur in the first year of follow-up. After completion of chemotherapy (therapeutic and consolidation courses) beta-hCG levels should be monitored weekly for 6 weeks and then in bi-weekly intervals for up to 6 months. Afterwards the patients require long-term follow-up by means of monthly beta-hCG testing (after monochemotherapy: lasting for 12 months after beta-hCG-levels returned to normal (< 5 IU/L); after polychemotherapy: lasting for 18-24 months after beta-hCG levels returned to normal), so that relapse can be promptly diagnosed. In pronounced ultra-high risk situations follow-up should take place in specialized centers, can be indicated for several years and may continue for life.
During the follow-up period a reliable form of hormonal contraception is mandatory and excessive UV light exposure should be avoided for 1 year to prevent UV-induced skin toxicity after chemotherapy.
Radiological follow-up of previously known metastatic sites should be performed after normalization of beta-hCG values as baseline for future imaging
Despite the generally favorable diagnosis of GTN, patients occasionally suffer from mental distress after therapy, which require psycho-oncological counseling and care.

## Differential diagnosis of persistent, slightly elevated hCG-values during follow-up

- Dormant GTN: If no metastases are observed and beta-hCG is present in a non-hyperglycosylated form, an expectative approach may be used with continued beta-hCG testing. Additional courses of chemotherapy are only indicated if beta-hCG values increase.
- Phantom hCG: Caused by circulating heterophilic anti-hCG antibodies. The diagnosis can be made if hCG can be found in serum samples but not in the urine.
- Cross-reactivity: Cross reactivity of the beta-hCG test with LH. This typically occurs when chemotherapy affects ovarian function. Treatment with oral contraceptives suppresses LH and avoids the false positive test results for beta-hCG caused by LH.
- Pituitary hCG: In peri- and postmenopausal women, small amounts of pituitary hCG may be released as part of a negative feedback mechanism due to reduced ovarian estrogen production. Estrogen substitution or oral contraceptives allow in these cases the differential diagnosis towards a GTN-related hCG-increase.

# Literature


| Nr. | Title | Author | Journal | Volume | Pages | Y |
|---|---|---|---|---|---|---|
| [01] | Current Advances in the Management of Gestational Trophoblastic Disease | Berkowitz R S, Goldstein D P | Gynecologic Oncology | 128 | 3-5 | 2 |
| [02] | Risk of recurrent molar pregnancies following complete and partial hydatidiform moles | Eagles N et al. | Hum Reprod | 30 | 2055-2063 | 2 |
| [03] | Gestational Trophoblastic Disease | Garner EIO et al. | Clinical Obstetrics and Gynecology | 50 | 112-122 | 2 |
| [04] | Pembrolizumab is effective for drug-resistant gestational trophoblastic neoplasia | Ghorani E et al. | Lancet | 390 | 2343-2345 | 2 |
| [05] | The Role of Surgery and Radiation Therapy in the Management of Gestational Trophoblastic Disease | Hanna R K, Soper J T | The Oncologist | 15 | 593-600 | 2 |

| Nr. | Title | Author | Journal | Volume | Pages | Y |
|---|---|---|---|---|---|---|
| [06] | Placental site trophoblastic tumor and epitheloid trophoblastic tumors: Biology, natural history and treatment modalities | Horowitz NS et al. | Gynecol Oncol | 144 | 208-214 | 2 |
| [07] | Hydatidiform mole and subsequent pregnancy outcome: A population-based cohort study | Joneborg U et al. | Am J Obstet Gynecol | 211 | 681.e1-681.e7 | 2 |
| [08] | Practical clinical guidelines of the EOTTD for treatment and referral of gestational trophoblastic disease | Lok C et al. | European Journal of Cancer | 130 | 228-240 | 2 |
| [09] | Gestational Trophoblastic Disease II: Classification and Management of Gestational Throphoblastic Neoplasia | Lurain J R | Am J Obstet Gynecol | | | 2 |

| Nr. | Title | Author | Journal | Volume | Pages | Y |
|---|---|---|---|---|---|---|
| [10] | Trophoblastic Disease Review for Diagnosis and Management. A Joint Report From the International Society for the Study of Trophoblastic Disease, European Organisation for the Treatment of Trophoblastic Disease, and the Gynecologic Cancer InterGroup | Mangili G et al. | Int J Gynecol Cancer | 24 | 109-116 | 2 |
| [11] | Current Chemotherapeutic Management of Patients with Gestational Trophoblastic Neoplasia | May T, Goldstein D P, Berkowitz R S | Chemotherapy Research and Practice | | | 2 |

| Nr. | Title | Author | Journal | Volume | Pages | Y |
|---|---|---|---|---|---|---|
| [12] | FIGO Cancer Report 2018, Update on the diagnosis and management of gestational trophoblastic disease | Ngan HYS et al. | Int J Gynecol Obstet | 143 (Suppl.2) | 79-85 | 2 |
| [13] | Pathology of gestational trophoblastic diseases, Best Practice and Research | Nga-Yin Cheung A | Clinical Obstetrics and Gynaecology | 17 | 849-868 | 2 |
| [14] | NCCN Guideline | n.a. | Gestational Trophoblastic Disease | Version 1.2019 (August 09, 2019) | | 2 |
| [15] | Gestational trophoblastic disease: ESMO Clinical Practice Guidelines for diagnosis, treatment and follow-up | Seckl MJ et al. | Annals of Oncology, Ann Oncol | Suppl 6 | vi 39-50 | 2 |
| [16] | Gestational trophoblastic disease: Clinical and imaging features | Shaaban AM et al. | RadioGraphics | 37 | 681-700 | 2 |

| Nr. | Title | Author | Journal | Volume | Pages | Y |
|---|---|---|---|---|---|---|
| [17] | PD-L1 expression in premalignant and malignant trophoblasts from gestational trophoblastic diseases is ubiquitous and independent of clinical outcomes | Bolze P-A et al. | Int J Gynecol Cancer | 27 | 554-561 | 2 |
| [18] | Novel approaches to managing gestational trophoblastic tumors in the age of immunotherapy | Hennah L et al. | Int J Gynecol Cancer | 33 | 414-419 | 2 |
| [19] | Current evidence on immunotherapy for gestational trophoblastic neoplasia (GTN) | Mangili G et al. | Cancers | 14 | 2782 | 2 |
| [20] | Recent developments in GTD and molar pregnancies | Massuger L | ESGO, Wien | | | 2 |