Last update: February 2020

Endometriosis

Author: Prof. Dr. med. Michel Mueller

Co-Klinikdirektor, Chefarzt Klinik für Gynäkologie Universitätsklinik für Frauenkrankheiten, Inselspital Bern

Co-Author(s): Dr. med. Sara Imboden

Introduction

The two most common benign proliferative diseases in women of child-bearing age are endometriosis and fibroids.

Definition

Physiologically, the endometrium, which comprises glands and the stroma, occurs only in the uterine cavity.

> Endometriosis is the presence of endometrial tissue (stroma and epithelial cells) outside the uterus.

This is technically ectopic tissue (heterotopia).

- Endometriosis is most commonly found in the pelvis minor (= pelvic endometriosis).
- However, endometriotic lesions can occur in almost any location in the body:

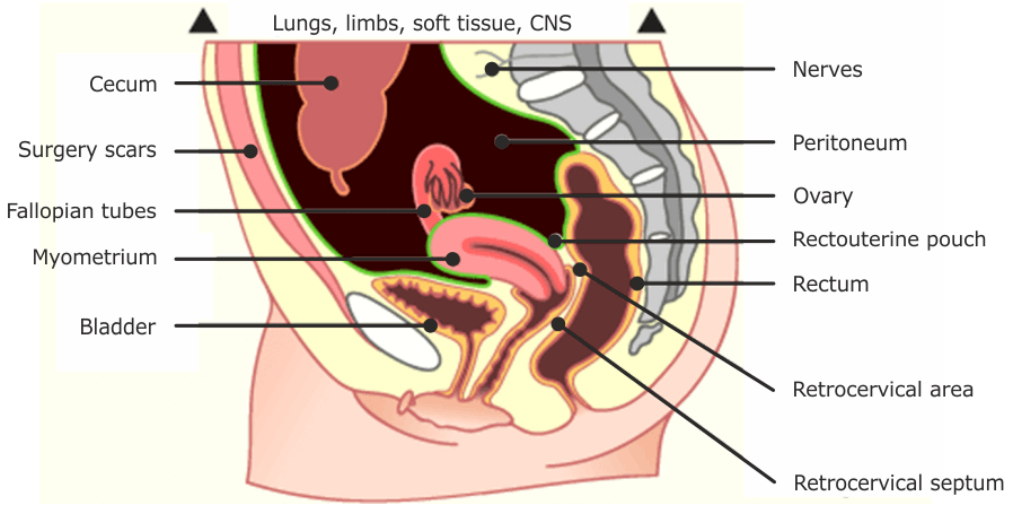

Illustration 1

From pathogenetic and clinical/therapeutic perspectives, a distinction is made between three entities:

- peritoneal endometriosis
- ovarian endometriosis (endometrioma)
- deep endometriosis

The presence of endometrial glands and stroma in the myometrium combined with hypertrophy of the surrounding myometrium is defined as adenomyosis (previously called endometriosis interna). A distinction is made between three distinct forms of adenomyosis:

- Diffuse adenomyosis: lesions are distributed across the myometrium
- Focal adenomyosis: lesions form a cluster (= adenomyoma)

- Cystic adenomyosis: the lesion is encapsulated. Juvenile cystic adenomyosis, which can also occur in young women (< 20 years) is a specific form of this.

Table 1: Index of possible locations of endometriosis in the body

Located in the	Terminology, comment	Frequency
Sacroiliac ligament		common approx. 65 %
Ovary superficial	A form of peritoneal endometriosis	common approx. 55 %
Ovary deep	= Endometrioma, = “chocolate cysts”	common approx. 20 %
Fallopian tube	Fallopian tube endometriosis	approx. 5 %
Rectouterine/retrocervical	• Rectouterine pouch endometriosis; a form of peritoneal endometriosis • Retrocervical endometriosis	common approx. 20 %
Rectovaginal septum: Intestine (small intestine, appendix, large intestine), bladder	Deep endometriosis	approx. 5 %
Myometrium	Here, endometriosis is called adenomyosis or adenomyoma (see above)	approx. 5 %
Scars	Scar endometriosis (often at the navel or a Cesarean section scar)	approx. 0,3 %
“anywhere” in the...	... vagina, vulva, perineum, mesenterium, navel, lungs, diaphragm, limbs, CNS, etc.	approx. 0,1 %

Note: The percentage frequency is based on the total number of patients with endometriosis. For example, 65 % of all patients with endometriosis have sacroiliac ligament endometriosis. Multiple locations are common, which is why the total is more than 100 %.

Epidemiology

- The peak age of diagnosis is before 30 years.
- Strong familial incidence (7x greater risk with first-degree relative).

Endometriosis concerns a specific age group:

- at least 10 % of women of child-bearing age are affected!

As a diagnosis can only be confirmed using invasive means (diagnostic laparoscopy and/or biopsy), prevalence data are generally imprecise. There is a high prevalence of endometriosis in female patients with infertility (20 to 50 %) and female patients with chronic lower abdominal pain (40 to 60 %).

Pathogenesis

The pathogenesis of endometriosis remains an unsolved mystery. Multiple factors probably contribute to its occurrence. Various theories exist to explain its different manifestations.

- Peritoneal endometriosis is usually justified by the implantation hypothesis put forward in 1927 by Sampson. This suggested that endometrial tissue reached the abdominal cavity due to retrograde menstruation. Studies have shown that these endometrial cells adhere to to peritoneum after just 18 hours, and migrate into the submesothelial tissue. Under the influence of paracrine and endocrine factors, these ectopic cells grow.
- The fact that endometriotic lesions only occur in some women, although retrograde menstruation occurs physiologically in up to 90 % of young women, is attributed to a complex combination of insufficient immune response, release of interleukins and growth factors, environmental influences and genetic predisposition [B01].
- Various interleukins, cytokines and growth factors have been found at high concentrations in the peritoneal fluid of patients with endometriosis [B02]. And several studies have demonstrated a connection between dioxin exposure and endometriosis [B03].
- Endometriosis involving the ovaries with endometrioma (endometriosis cysts) is explained by the formation of pseudocysts or coelomic metaplasia of invaginated epithelial inclusions.
- Metaplasia of paramesonephric duct residue or an infiltration originating in the rectouterine pouch are discussed as the possible pathogenetic cause of deep endometriosis involving the rectovaginal septum.
- Hematogenic and lymphogenic metastases and pluripotent cells are thought to be responsible for extragenital manifestations.
  [B01][B02][B03]

Clinical morphology

While endometriosis is a benign condition, it often grows like an invasive tumor, infiltrating and destroying tissue and organs.

Endometriotic lesions respond to the cyclical influence of estrogen and progesterone like eutopic endometrium, with proliferative and secretory phases. As a result of localized stimulation, interaction with macrophages, leukocytes and other cells in the peritoneal fluid leads to the release of inflammatory substances. The ability of endometrial tissue to implant and invade provides for its spread with organ-distorting growth.

Hormonal stimuli have a direct influence on endometriotic tissue.

1. Cyclical proliferation and edema of endometriotic lesions -> volume increase and inflammatory reaction -> pain
2. Desquamation within a closed compartment (endometrioma) -> blood accumulation -> various symptoms (which may be chronic due to mass effect/ capsule tension or acute due to rupture).
3. Desquamation in a hollow organ (rare) -> blood loss visible externally (cyclical intestinal bleeding/bladder bleeding/hemoptysis).

Clinical/macroscopic examples

The appearance of endometriotic lesions varies greatly and depends on the organ involved.

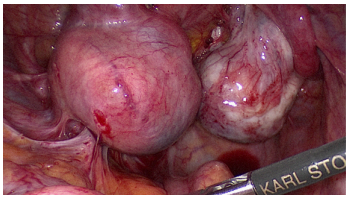

Illustration 2: Ovarian endometrioma

Illustration 3: Peritoneal endometriotic lesion

Illustration 4: Navel endometriosis

Laparoscopic view of two endometriomas: • increased ovarian volume • Both ovaries touch behind the cervix	Laparoscopic view of a peritoneal endometriotic lesion: • bluish lesion in center of image • star-shaped newly formed vessels (= neoangiogenesis) surrounding the endometriotic lesion	View of navel: • Bluish livid lesion in center of navel • Patient reported painful cyclical swelling of the lesion

Clinical picture

The presentation of endometriosis varies greatly and is often cyclical on a monthly basis. Most symptomatic patients experience the cardinal symptoms of dysmenorrhea (95 %) and dyspareunia (64 %), although many also experience chronic pain (85 %) and fatigue (87 %). Dyschezia (64 %) and dysuria (31 %) can also occur depending on the location of the endometriotic lesion.

A third of women with endometriosis are asymptomatic. Here, a diagnosis is often made during a laparoscopy to investigate infertility. Endometriosis should immediately be considered as a diagnosis for women who report symptoms such as dysmenorrhea, dyspareunia and chronic recurrent lower abdominal pain.

Symptoms suggesting endometriosis

- Dysmenorrhea
- Chronic recurrent lower abdominal pain
- Menstruation disorders (hypermenorrhea, menorrhagia)
- Defecation disorders (dyschezia)
- Dyspareunia (painful intercourse)
- Infertility
- Back pain
- Dysuria (hematuria)

Any symptoms that return with menstruation or are exacerbated by menstruation - regardless of their location or manifestation - may suggest endometriosis.

- The topographical situation generally characterizes the type of manifestation.
- Pain symptoms vary considerably. They are susceptible to impact quality of life (including work and sexuality) on an individual basis [B05].
- In the interval between two menstrual periods, endometriosis is clinically less active or even asymptomatic.
- Any form of amenorrhea, including pregnancy, often provides patients with endometriosis with an asymptomatic period of time - although symptoms often return as before after the patient gives birth.
- After menopause, the lesions transform into inactive scars due to the decrease in ovarian estrogens: “spontaneous recovery tendency/burnout”.
- Autoimmune processes seem to modulate progression of the condition

(persistence and activity varies on an individual basis).
[B05]

Consider endometriosis! Even when symptoms appear internal or neurological. Most common presentations of endometriosis: Lower abdominal pain and menstrual abnormalities. Endometriosis can also be a factor in infertility.

Table 2

Pain - a key symptom!	• Abdomen - lower abdomen - anywhere? • Type of pain and progression over time? • “Suitable” patient age?
Dysmenorrhea - a key symptom!	• Secondary (acquired) dysmenorrhea? • Primary dysmenorrhea can also be caused by endometriosis!
Dyspareunia/ algopareunia	
Many variations uterine bleeding disorders	• Metrorhaggia • Menorrhagia • Hypermenorrhea
Infertility - a possible symptom!	Even without symptoms, fallopian tube endometriosis can result in adhesions and loss of egg cell function, and thus infertility.
Serious or acute complications	An initial manifestation due to a complication is possible!
Urination/defecation abnormalities - rare!	Presence of blood (hematuria, anal bleeding) or painful symptoms.
Shoulder pain, particularly on right	Diaphragm endometriosis

Endometrioma with spontaneous rupture or twisted pedicle: -> acute abdomen (sometimes with significantly increased inflammatory parameters)

Involvement of the rectovaginal septum: -> pronounced dyspareunia (or algopareunia).

Diagnosis

A diagnosis of endometriosis must be made as early as possible and can only be confirmed with a laparoscopy and/or biopsy. However, the treatment of endometriosis has been revolutionized in recent years. Until a few years ago, patients with pain and clinically suspected endometriosis were encouraged to undergo a laparoscopy to confirm the diagnosis. In line with most guidelines and the current international consensus, today these patients are first given empirical drug treatment. A diagnostic/therapeutic laparoscopy is then indicated in cases of lack of response or insufficient success. [B05][B06]

Steps towards diagnosis

Obligatory basic clinical examination

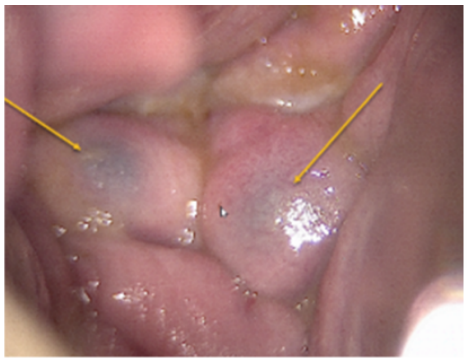

Illustration 5: Endometriosis in the posterior fornix.

- The history provides the reason to suspect endometriosis: family history, infertility, cyclical lower abdominal pain (rarely arbitrary, unspecific lower abdominal pain), dysmenorrhea, dyspareunia, bleeding disorders.
- Careful inspection of the vulva, vagina, ectocervix and any surgery scars.
- Typical palpation findings on bimanual rectovaginal examination.

Palpation findings: may include displaced/fixed uterus / hardness in the rectouterine pouch / adnexal mass / enlarged and in some cases hard uterus (typical of advanced adenomyosis) / dilated rectovaginal septum with rectal findings.

Typical additional investigations

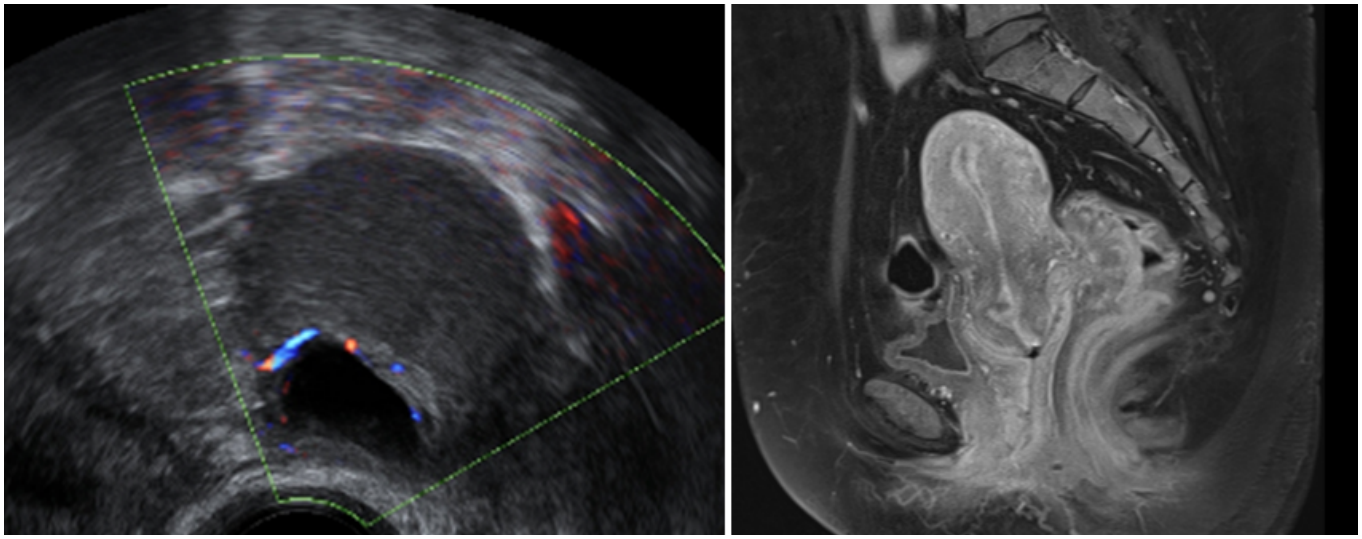

Illustration 6

- In addition, an ultrasound is carried out (generally transvaginal). There are typical ultrasound findings for endometrioma, although very small or peritoneal endometriotic lesion cannot be identified. With transvaginal ultrasound, is it important to check for the presence of kissing ovaries, as this is a sign of severe endometriosis [B08].
- With severe endometriosis, a targeted MRI is also indicated in order to quantify the extent of the condition and establish invasion of other organs (e.g. intestine, bladder) [B09]
- Laboratory tests are usually worthless for initial diagnosis! Testing of CA-125 levels (primarily used as an epithelial tumor marker for ovarian cancer) is also not helpful for diagnosing the progression of endometriosis, due to its low level of specificity.
  [B08][B09]

Gold standard for diagnosis

A diagnosis can only be confirmed by invasive means - the macroscopic identification of any lesion(s) with biopsy (usually via laparoscopy).

In addition to the biopsy evidence, the invasive procedure also provides further key information such as the distribution and extent of lesions and allows for the better evaluation of surrounding tissue reaction and any (in some cases treatment-induced) secondary organ damage.

Biopsy

- Biopsy-based confirmation of the diagnosis via laparoscopy is recommended, although it is not required in all guidelines.

- Technically, the biopsy material histopathology must show both glands and stroma.

Classifications

As endometriosis is a multifaceted condition, there is currently no satisfactory classification that takes into account all aspects of the disease. Nevertheless, individual classifications have prevailed in everyday practice.

rASRM The American Society for Reproductive Medicine's revised endometriosis classification. The presence of endometriosis is quantified using a points system.

ENZIAN classification. Used for deep endometriosis. Like the TNM system, the letters used provide information on the location of the endometriosis. Deep lesions are those which present invasion of 5 mm or more.

EFI. The Endometriosis Fertility Index, developed by Adamson and colleagues in 2010, is the only validated score that can be used to predict the probability of a patient with endometriosis becoming pregnant. [B10]

Differential diagnosis

- Tumor, diverticulitis, adhesions, appendicitis, psychosomatic.
- Adnexitis, PID, ectopic pregnancy.
- Organ torsion (large ovarian cyst, result of malignancy, etc.)

Complications

- Common: Infertility; Recurrence after treatment
- Rare: Malignant degeneration (2 %)
- Further complications include (all rare): Hydroureter or hydronephrosis; Pneumothorax or hemothorax; Anemia; Ileus; Neurological failures.

Treatment

Endometriosis is a chronic disease that requires lifelong care. An individual treatment plan must be established according to the patient's individual situation, age, desire to have children and pain symptoms. Treatment objectives must be decided with the patient during pre-treatment reflection and consultations.

Underlying factors

- Psychological strain on the patient
- Patient age
- Location, level of activity (type of growth)
- Desire to have children, family planning

Specific circumstances

- Asymptomatic patient, emergency patient or "typical" patient?
- Infertility patient with symptoms?
- Asymptomatic infertility patient?
- Symptoms but (currently?) no desire to have children?

Quantifiable treatment objectives

- Combating symptoms
- Elimination of endometriosis/its complications
- Treatment of infertility
- Acute management in emergency cases

Unfortunately, all forms of treatment have a recurrence rate of 20 to 50 %. Pre-treatment reflection and consultations are therefore of the greatest importance!

'Wait and see' approach

Indication: Incidental finding during laparoscopy for other reasons; Low level of symptoms; Scarce findings; No fertility issues.

Symptomatic drug treatment

- Analgesics: (NSAIDs such as mefenamic acid [Ponstan® etc.]): NSAIDs inhibit cyclooxygenase and thus reduce prostaglandin-mediated dysmenorrhea and inflammation-related pain in general [B11].
- Ovulation inhibitors: Ovulation inhibitors reduce cyclical hormone fluctuations and the formation of the endometrium, thus reducing pain associated with

menstruation. In addition, continuous administration of an ovulation inhibitor can lead to amenorrhea. Many patients have no symptoms under this treatment. Unfortunately, ovulation inhibitors do not slow the progression of endometriosis for all patients [B12].
[B11][B12]

Hormonal drug treatment

The progression of many forms of endometriosis is slowed and mitigated for the duration of treatment. Good pain relief is usually achieved.
However, symptoms often return after treatment is stopped.

Hormonal treatment works on the principle of estrogen deprivation (no estrogen in the bloodstream means endometriosis cannot grow)! But:

- costs are often high
- little effect on endometrioma and deep endometriosis

The range of drugs (and pharmaceutical groups) available means it is possible to establish customized treatment depending on side effects and subjective tolerability, and taking into account the estrogen suppression effects actually achieved in each specific case.

Table 3

GnRH analogues	Antigonadotropins	Progestogens
Either desensitization of pituitary FSH and LH secretion (*)	Or direct inhibition of pituitary gonadotropin secretion	Or negative feedback on the hypothalamic-pituitary-ovarian axis

Leading to drug-induced down-regulation of the ovaries (i.e. “switching off” of egg production).

(*) GnRH analogues (11.25 mg leuprorelin [e.g. Eligar®, Leuprorelinr®] or 11.3 mg goserelin [e.g. Zoladex®]) are “superagonists” of the anterior lobe of the pituitary gland: Due to their un-physiologically long stimulation, they eventually cause the pituitary to reduce the secretion of FSH and LH - after a temporary “flare”.

Interfering in the hormone/releasing factor balance in this way is not without its side effects (hypoestrogenic, androgenic and mineralocorticoid).

When using GnRH analogues, induced “menopausal syndrome” (hot flashes, sweating, vaginal atrophy, etc.) in particular can be very disruptive or even intolerable. The situation can be counteracted by an “add-back regimen” (adapted hormone replacement therapy). Today, this often takes the form of tibolone (Livial®], or low-dose transdermal estrogens (25 µg).

Tibolone [Livial®]: a synthetic steroid, the metabolites of which display mainly estrogenic, but also progestogenic and androgenic effects.

GnRH antagonists can also be used in the treatment of endometriosis, although with similar side effects.

Progestogens such as medroxyprogesterone acetate, dydrogesterone and dienogest (the only progestogen specifically approved for the treatment of endometriosis) are currently the first-line treatment. In prospective randomized studies, continuous oral progestogen (2 mg dienogest per day) was equivalently effective as a GnRH analogue at treating endometriosis-related pain, with dienogest being associated with far fewer side effects. Long-term data show a permanent clinical effect extending beyond administration. [B13]

New approaches to targeted treatments may be available in the future as our understanding of the pathophysiology of endometriosis improves. Aromatase inhibitors are also used to treat endometriosis, similarly to their use in breast cancer. Other currently experimental approaches include estrogen receptor beta agonists, angiogenesis inhibitors, antidiabetic drugs and immunomodulators.

Surgery

The surgical removal of lesions and affected parts of organs is required:

- in cases of highly organized forms of endometriosis
- at highly advanced stages of the disease
- for complications
- if definitive removal with high reliability is the objective
- where conservative treatment has been unsuccessful.

Typical indications for surgery: Large ovarian endometrioma; peritoneal endometriosis with infertility.

Complex forms of endometriosis require a highly experienced surgeon and must often be carried out in collaboration with other fields in specialized centers. For example, intestinal or bladder resection with or without ureter reimplantation may be required. Most procedures can today be carried out laparoscopically. [B14][B15]

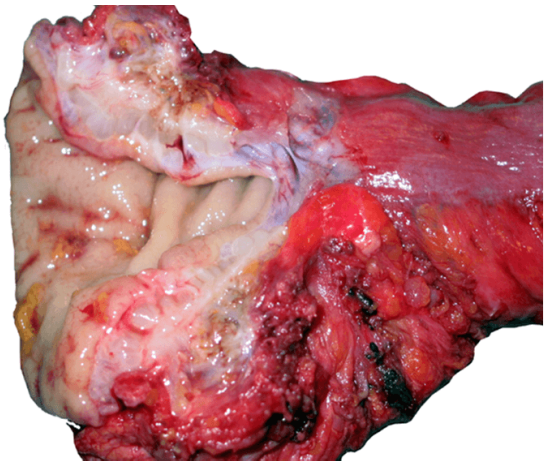

Illustration 7: Organ-conserving surgery = to maintain fertility

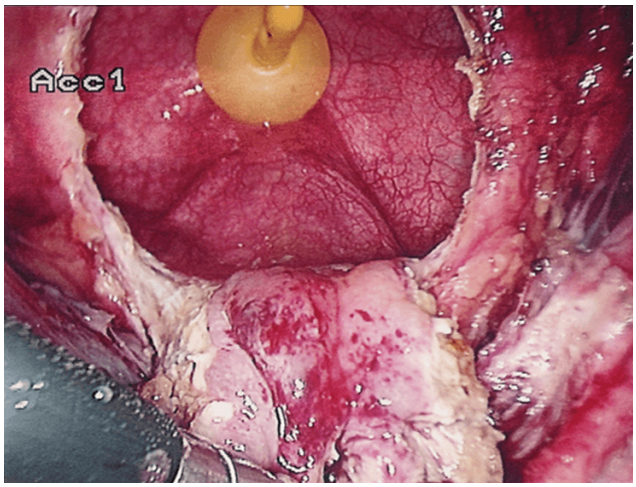

Illustration 8: Radical/ablative surgery (oophorectomy, hysterectomy, etc.)

Surgical procedures also allow biopsies to be taken, and treatment for any secondary issues to be dealt with at the same time (e.g. adhesions).

Combination of surgical and hormonal treatment

- Preoperative hormonal treatment can reduce the vascularization and size of endometriotic lesions (⇒ reduced intraoperative blood loss). However, this drug-based preparation for surgery requires an additional “time investment” (at least 3 months) and is expensive and not always effective.
- Long-term postoperative treatment and fertility measures are often indicated. The likelihood of becoming pregnant is highest in the first year after surgery.

Multimodal pain therapy

Patients with endometriosis can experience reduced quality of life due to restrictions affecting their work, social life and sexuality. It is therefore often necessary to treat the pain itself in addition to actually treating the endometriosis (with drugs or surgery). This is done by means of multimodal pain therapy comprising physiotherapy, psychosomatics and pain therapy.

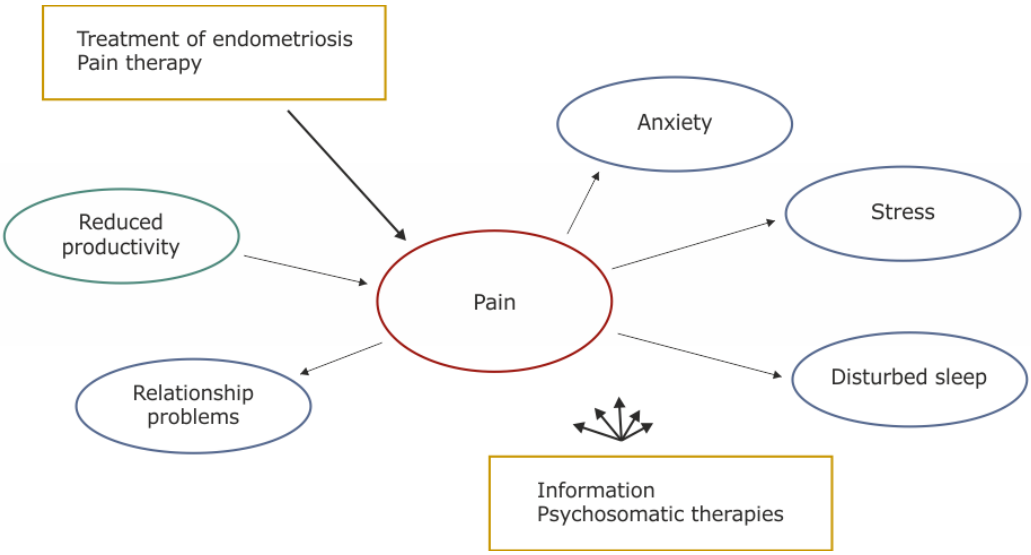

Illustration 9: Multimodal pain therapy by Imboden S, Gyn Endo 2018

Literature

Nr.	Title	Author	Journal	Volume	Pages
[B01]	Endometriose: Ein Chamäleon unter den gynäkologischen Erkrankungen	Imboden S., Mueller MD	Schweiz Med Forum	17(32)	654-659
[B02]	The association between progestins, nuclear receptors expression and inflammation in endometrial stromal cells from women with endometriosis	Giovanni G. et al.	Gynecol Endocrinol	33(9)	712-715
[B03]	2,3,7,8-Tetrachlorodibenzo-p-dioxin increases glycodelin gene and protein expression in human endometrium	Mueller M.D. et al.	J Clin Endocrinol Metab	90(8)	4809-4815
[B04]	Progesterone Resistance in Endometriosis: an Acquired Property?	McKinnon B, Mueller M, Montgomery G	Trends Endocrinol Metab	29(8)	535-548
[B05]	The burden of endometriosis: costs and quality of life of women with endometriosis and treated in referral centres	Simoens S, Dunselman G, et al.	Hum Reprod	27(5)	1292–1299

Nr.	Title	Author	Journal	Volume	Pages
[B06]	SHRE guideline: management of women with endometriosis	Dunselman GA, Vermeulen N, et al.	Hum Reprod	29(3)	400-412
[B07]	Interdisziplinäre S2k-Leitlinie für die Diagnostik und Therapie der Endometriose	AWMF online - das Portal der wissenschaftlichen Medizin			
[B08]	"Kissing ovaries": a sonographic sign of moderate to severe endometriosis	Ghezzi F. et al.	Fertil Steril	83(1)	143-147
[B09]	Cloverleaf Sign in Pelvic Magnetic Resonance Imaging for Deep Infiltrating Endometriosis: Association With Longer Operation Times, Greater Blood Loss, and Higher Rates of Bowel Resection	Härmä K. et al.	Invest Radiol	55(1)	53-59
[B10]	Endometriosis fertility index: the new, validated endometriosis staging system	Adamson GD, Pasta DJ	Fertil Steril	94(5)	1609-1615

Nr.	Title	Author	Journal	Volume	Pages
[B11]	Inflammation and nerve fiber interaction in endometriotic pain	McKinnon BD, et al.	Trends Endocrinol Metab	26(1)	1-10
[B12]	Oral contraceptives and endometriosis: the past use of oral contraceptives for treating severe primary dysmenorrhea is associated with endometriosis, especially deep infiltrating endometriosis	Chapron C, Souza C, et al.	Hum Reprod	26(8)	2028–2035
[B13]	Medical treatment of endometriosis-related pain	Vercellini P, et al.	Best Pract Res Clin Obstet Gynaecol	51	68-91
[B14]	Laparoscopic management of bowel endometriosis: resection margins as a predictor of recurrence	Nirgianakis K, McKinnon B, et al.	Acta Obstet Gynecol Scand	93(12)	1262-1267

Nr.	Title	Author	Journal	Volume	Pages
[B15]	nary tract endometriosis in patients with deep infiltrating endometriosis: prevalence, symptoms, management, and proposal for a new clinical classification	Knabben L, Imboden S, et al.	Fertil Steril		