Last update: April 2024

Epithelial ovarian cancer

Co-Author(s): Prof. Dr. med. Viola Heinzelmann-Schwarz

Author: PD Dr. Marcus Vetter

Leitender Arzt Medizinische Onkologie, Schwerpunkt Gynäkologische Tumoren

Authors of former script versions: Dr. med. Konstantin Dedes, Prof. Dr. med. Daniel Fink

Definition

In Switzerland, approximately 700 women per year are diagnosed with a malignant ovarian neoplasm. Due to the complexity of the disease, treatment should take place in specialized, accredited tumor centers and/or networks. According to the new IVHSM (Inter-cantonal agreement on highly specialized medicine), in the future ovarian cancer surgery will be carried out by highly-specialized doctors. Generally, malignant ovarian tumors are classified according to the tissue in which they originate.

Epithelial neoplasms (90 %)

- Serous (55 %)
- Endometrioid (20 %)
- Mucinous (10 %)
- Clear cell (5 %)
- Carcinosarcoma (or malignant mixed Müllerian tumor) (< 5 %)

Germ cell neoplasms (5 %)

- Dysgerminoma
- Malignant teratoma
- Other rare (choriocarcinoma, gonadoblastoma)

Stromal neoplasms (5 %)

- Granulosa cell tumor
- Sertoli-Leydig cell tumor

Additionally, malignant ovarian metastases can be found in rare cases. These are usually from stomach cancer (Krukenberg tumor), breast cancer or endometrial cancer. 5 % of malignant ovarian findings are metastases from other organs. Classification and attribution are easier today thanks to modern pathology and molecular pathology techniques.

Borderline ovarian tumors are a fluid intermediate form that cannot be histologically categorized as benign or malignant. They demonstrate increased atypical epithelial proliferation but without destructive stromal invasion.
Despite the lack of invasion, these tumors can lead to peritoneal implantations, which can show invasive growth in rare cases. By definition, where there is invasive implantation, there is a low-grade ovarian carcinoma. Hematogenous or lymphatic metastasis is rare. A distinction is drawn between mucinous and serous histology. In general, comprehensive surgical staging should take place in order to avoid missing invasive components. If necessary, a fertility-sparing approach may be discussed. However, an analysis from the German ROBOT study showed that de-escalation can lead to an increased risk of relapse. [B07]

Pathogenesis of epithelial ovarian cancer

As per Kurmann et al., today there is a dualistic model of ovarian cancer, distinguishing between type I and type II carcinoma. Type I carcinoma generally develops from a precursor lesion and can be associated with endometriosis. The molecular mutations in endometrioid ovarian cancers are comparable with those found in endometriosis. This subtype also includes clear-cell carcinoma (rare in Europe/USA) and seromucinous carcinoma, both also associated with endometriosis. Type I also includes low-grade carcinoma in the fallopian tube and mucinous carcinoma (germ cell-related), as well as Brenner tumors (transitional cell-related).

Type II carcinoma is found in the fallopian tube and generally then develops into a serous high-grade tumor with clinical manifestation in the fallopian tube, ovary or peritoneum. It is now known that these cancers generally develop from a precursor lesion (Serous Tubal Intraepithelial Carcinoma; STIC). Type II carcinoma also includes ovarian carcinosarcoma and undifferentiated carcinoma [B08, B09]. Table 1 gives an overview of the subtypes of epithelial ovarian cancer. [B08][B09]

Peritoneal cancer and fallopian tube cancer are difficult to clinically distinguish from epithelial ovarian cancer. Their histological properties are also very similar. The diagnosis, staging and treatment of these neoplasms are based on the management of epithelial ovarian cancer.

The molecular characterization of ovarian cancer types has led to a new classification. This categorizes them as serous low-grade or high-grade, which are different in terms of genetics, pathogenesis and prognosis [B05].

The majority of low-grade serous carcinomas probably develop from benign precursor lesions such as cystadenomas, endometriosis and borderline tumors and histologically show good differentiation (G1).

Poorly-differentiated serous carcinomas (G3) mainly form the group of high-grade carcinomas. With regard to aggressive high-grade tumors, the role of the distal portion of the fallopian tube as a organ of origin is discussed, as patients at high risk of ovarian cancer (carriers of BRCA1/2 mutations) are often diagnosed with cancer precursors (carcinoma in situ) here (the aforementioned STIC lesions). [B05]

Table 1: Subtypes of ovarian cancer and molecular alterations (legend ER – estrogen receptor; OC – ovarian cancer; PARPi – poly ADP ribose polymerase inhibitor; 5FU – 5-fluorouracil; OS – overall survival; (*) much higher in some geographical regions such as Asia, for example (**) more frequently diagnosed at an early stage than serous high-grade carcinoma, thus overall better prognosis, adapted from: Vetter M., Leary A. Times Oncol 2021)

	Serous high-grade cancer	Serous low-grade OC	Endometrioid OC	Mucinous OC	Clea
Frequency	70 %	5–10 %	10 %		1 %(
Molecular changes	TP53 mutations BRCA mutations and BRCAness CCNE amplifications	KRAS mutations BRAF mutations ERBB2	ARID1A CTNNB1 PTEN PIK3CA mutations	KRAS mutations	ARI PIK mut

	Serous high-grade cancer	Serous low-grade OC	Endometrioid OC	Mucinous OC	Clea
Treatment	Surgery, chemotherapy (platinum-based) +/- Bevacizumab PARPi	Surgery, chemotherapy (platinum-based) +/- Bevacizumab Endocrine therapy if ER+	Surgery, chemotherapy (platinum-based) +/- Bevacizumab PARPi	Surgery, chemotherapy (platinum-based) +/- Bevacizumab 5FU-based therapy	Surg che (pla bas +/- Bev
5-year overall survival (over all stages)	30–40 %	40 %	65 %	80 %	60 %
Clinical characteristics	Fast-growing Highly proliferative	Slow-growing, intermediate prognosis	Similar to corresponding serous types Low-grade: Slow-growing, intermediate prognosis	Slow-growing, intermediate prognosis	Very prog adv stag Freq che (pla resi

Frequency, age distribution

Ovarian cancer is the third most common gynecological cancer (after breast and endometrial cancer) in industrialized countries. With an incidence of approx. 15/100’000 women per year, the lifetime risk is approx. 1,5 %. In Switzerland, 700 women are diagnosed with ovarian cancer each year, and in Germany 8000 women per year. This makes it the leading cause of death among gynecological cancers. The peak age is 60 years (between 50 and 70 years). The incidence of borderline tumors is approx. 2-5/100’000 women per year, with a peak age between 30 and 40 years, unlike malignant ovarian cancer. Thanks to improvements in treatment in the form of surgery, systemic treatment and targeted therapies, the prognosis of ovarian cancer has improved in recent years. When optimally treated, approximately 40 % of stage III serous high-grade cancers can be cured.

Risk factors

One of the most important factors for the development of ovarian cancer are pathogenic mutations of the BRCA 1 and 2 genes. This can give a lifetime risk of up to 60 % for developing the disease. Approx. 20 % of women with high-grade serous ovarian cancer have pathogenic mutations of both of these genes. Thanks to recent advances in prophylaxis, genetics and drug treatments, awareness of the mutation status of all women diagnosed with serous ovarian cancer is now obligatory.

One possible explanation for the pathogenesis of ovarian cancer is inclusion cyst theory, which suggests that on each ovulation, epithelial tissue from the ovarian capsule is included in the ovarian stroma, and that various factors can cause this to transform into an epithelial carcinoma. More recent studies show that the most common subtype of high-grade ovarian cancer originates in the fallopian tubes and/or fimbriae (see above). It has also been shown that opportunistic salpingectomy in healthy patients can reduce the risk of ovarian cancer [B10]. [B10]

Table 2: Key risk factors for ovarian cancer (incl. protective factors)

Risk factors	Protective factors
Increasing age Nulliparity, infertility Early menarche, late menopause Breast cancer mutation carriers (BRCA1 and BRCA2) History of breast cancer Estrogen and gestagen substitution Infertility treatments Lynch syndrome Endometriosis Increased ovulation/menstruation rate	Long-term administration of ovulation inhibitors Multiparity Breastfeeding Tubal ligation

Hereditary ovarian cancer in BRCA1 and BRCA2 mutation carriers, associated with a lifetime risk of approx. 40 %, is only responsible for approx. 10 % of all ovarian cancers.

No established screening program

Given the overall low incidence rate, it has previously been impossible to establish a screening program for the early detection of ovarian cancer due to insufficient effectiveness. Screening with annual transvaginal ultrasound in combination with the sensitive tumor marker CA125 has not been shown to reduce mortality in high-risk groups nor in the general population, including in studies with over 200’000 women [B11]. In high-risk families, genetic counseling should always take place with subsequent testing if indicated. If a BRCA1/2 mutation is detected, prophylactic surgery should be carried out for healthy carriers as per current guidelines (e.g. NCCN). [B11]

Prevention is only indicated for carriers of BRCA1 or BRCA2 mutations. Bilateral adnexectomy should be recommended if the patient does not want (more) children or at the latest at 40 years. If the patient wants to preserve fertility, taking an ovulation inhibitor can significantly reduce the risk of developing ovarian cancer.

Diagnosis

Ovarian cancer generally presents with few symptoms and is mostly only diagnosed at an advanced stage. Epithelial serous high-grade cancer is generally at FIGO stage III or IV at the time of diagnosis. Some patients are referred to gynecologists from subspecialties like internal medicine and gastroenterology following unremarkable findings.

The following are nonspecific symptoms:

- Increased abdominal circumference in case of ascites and/or tumor spread into the abdomen
- Bloating, constipation, weight gain due to ascites
- Nausea and vomiting in case of subileus/ileus
- Breathlessness in case of pleural effusion or metastatic involvement of the diaphragm
- Weight gain
- Thrombosis (more common with clear-cell carcinoma) or lymphedema from vascular compression in the lower abdomen

Definitive diagnosis requires surgical clarification with histological confirmation by means of laparoscopy or directly with laparotomy (staging laparotomy). Preoperative histological examination by means of fine-needle aspiration or punch biopsy of a finding limited to the ovary should not be carried out due to the risk of intraabdominal tumor leakage. If laparoscopic diagnosis is successful, the trocar wound sites should generally be excised during the definitive surgery.

A preoperative suspected diagnosis of ovarian cancer is established on the basis of the following:

1. Clinical examination: ascites, palpable abdominal tumor
2. Gynecological status: palpable tumor in lesser pelvis, breast exam
3. Transvaginal ultrasound: enlarged suspicious cystic ovarian tumor with free fluid (Figures 1 and 2)
4. Elevated tumor markers
5. Pelvic CT: lower abdominal tumor, ascites, infiltration of the greater omentum (omental cake), retroperitoneal lymph node involvement, liver parenchyma, pleural carcinomatosis, effusion
6. In case of suspected bowel cancer: colonoscopy
7. In case of suspected stomach cancer (Krukenberg tumor): gastroscopy

The probability of the presence of ovarian cancer can be confirmed with preoperative signs and treatment with primary surgery initiated. In the case of advanced findings (stage IV) and poor performance status, in exceptional cases pleural/ascites puncture or peritoneal biopsy can be carried out to confirm the diagnosis, and preoperative chemotherapy initiated. The risk of malignancy index, for example, can be used for triage and deciding on primary debulking/staging surgery. This is calculated using menopause status, ultrasound findings and CA125 level.

Triage index: risk of malignancy index [B12]

RMI = menopause status x ultrasound findings x absolute CA125 value

Points:
Premenopausal: 1
Postmenopausal: 3
Simple cyst: 1
Complex mass: 2

In the classical definition of the RMI, specific sonographic features (e.g. multilocular cyst, solid component, bilateral lesion, ascites or metastases) are each assigned one point. If one of these features is present, the ultrasound score is 1; if two or more features are present, a score of 3 is assigned.

The Risk of Malignancy Index itself is a dimensionless index and has no unit of its own, even though the CA-125 value, including its unit, is incorporated into the formula.

RMI > 200 Primary surgery in gynecological center [B12]

Example 1:

- Menopause status postmenopausal: 3
- Ultrasound findings: 3
- CA125: 100 U/ml
- → RMI = 3 × 3 × 100 = 900

Exemple 2:

- Menopausal status premenopausal: 1
- Ultrasound findings: 2

- CA125: 200 U/ml
- → RMI = 1 × 2 × 200 = 400

The O-RADS Score can also be used. In this case, the morphological anomalies of the ovary are also assessed, in addition to other findings such as ascites and abnormal lymph nodes.

Both O-RADS and RMI have high sensitivity. Decisions on further treatment should always be discussed at a multidisciplinary tumor board with gynecologic oncologists, pathologists and internists.

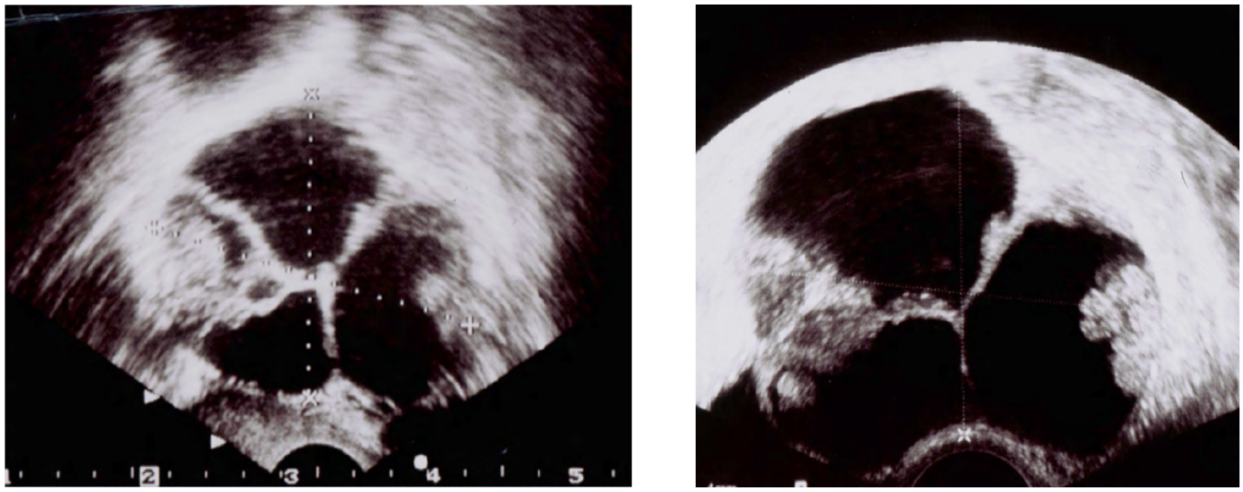

Figure 1: Transvaginal ultrasound of a serous ovarian tumor.
Left: with cystic-solid components, thickened septa and papillary projections in the cyst epithelium.
Right: notable papillary structures to the right of the image.

Reliable preoperative imaging for staging does not exist. Unlike other cancers, the pattern of metastasis is predominantly characterized by peritoneal spread and lymphatic metastasis in the retroperitoneal lymph nodes. The sites of predilection are the peritoneum, lesser pelvis, diaphragm, paracolic gutters and greater omentum (figure 2).

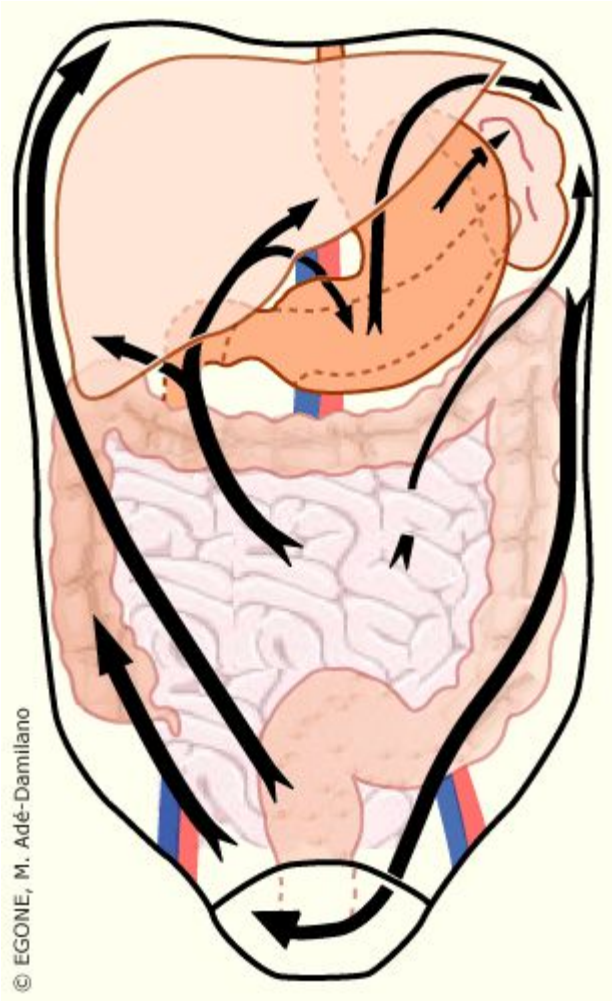

Figure 2: Pattern of metastasis.

Tumor markers

CA125 (Cancer Antigen 125)

This glycoprotein is expressed on the surface of most ovarian cancer cells and secreted in the blood. Elevated CA125 levels have high specificity but low sensitivity for ovarian cancer. Other malignant tumors such as endometrial cancer, breast cancer and gastrointestinal cancer also cause elevated CA125 levels. But benign processes involving the peritoneum (peritonitis, hepatitis, pancreatitis and endometriosis) can also do so.
A major GCIG validation study with over 50 markers showed that CA125 remains the best marker for follow-up testing. CA125 is also well-suited to check-ups during treatment (chemotherapy) with high sensitivity. However, it should be remembered that falsely high or low CA125 values can occur, and ascites puncture or pleural puncture can reduce the marker.

Regular CA125 testing in follow-up can be discussed. In the course of the disease, a biochemical recurrence (i.e. doubling of CA125 over the normal value) generally occurs before CT changes or clinical symptoms. A publication by Rustin et al. (MRC Ov05 Trial) [P07] showed that the early use of chemotherapy in cases of marker recurrence did not improve overall prognosis. The extent to which the marker allows early detection of an operable recurrence and that this improves the prognosis has not been investigated. However, this would be beneficial for patients, as operable recurrences have a better overall prognosis according to the randomized Desktop-III study [P08].

The KELIM score (Elimination of Constant K) is a new kinetic marker that is a good predictor of response to primary chemotherapy (chemotherapy sensitivity). It evaluates CA125 clearance. Patients with a KELIM score <1 have poor chemotherapy sensitivity and will probably not benefit especially well from chemotherapy. The KELIM score is calculated using at least three CA125 values measured within 50 to 100 days of starting treatment and during chemotherapy. KELIM should ideally be measured during each chemotherapy cycle [B13] (Almufti et al, Ann Oncol 2014).
[B13][P07][P08]

Estradiol

Certain stromal tumors (in particular granulosa cell tumors) can produce estradiol. This can be used for diagnostic purposes in postmenopausal women.

AFP (Alpha Feto Protein)

AFP is a very specific tumor marker for the detection and follow-up of germ cell tumors and hepatocellular carcinoma. This protein cannot be interpreted during pregnancy or in rare cases with benign liver conditions (hepatitis, cirrhosis) due to false positives.

HCG (Human Chorionic Gonadotropin)

HCG is formed in the syncytiotrophoblast cells during pregnancy and is often elevated with germ cell tumors (dysgerminoma).

Inhibin A/B

Inhibin is formed in ovarian granulosa cells and serum levels are elevated with granulosa cell tumors.

Staging and prognosis

Reference: AJCC Cancer Staging Manual 8th edition (2017) Springer international publishing

Table 3: Staging and descriptions (overview)

TNM	FIGO	Description
T1	I	Tumor limited to ovaries or fallopian tubes
T2	II	Tumor involves one or both ovaries or fallopian tubes with pelvic extension or primary peritoneal cancer
T3 or N1	III	Tumor involves one or both ovaries or tubes or primary peritoneal cancer with microscopically confirmed peritoneal metastasis outside the pelvis and/or retroperitoneal lymph node involvement
M1	IV	Distant metastasis (excluding peritoneal metastases)

Table 3: Staging and descriptions (details, EGONEplus)

TNM	FIGO	Description
T1a	IA	Tumor limited to one ovary or fallopian tube; capsule intact; no tumor on ovarian surface
T1b	IB	Tumor limited to both ovaries or fallopian tubes; capsule intact; no tumor on ovarian surface
T1c	IC	Tumor limited to one or both ovaries or fallopian tubes with: IC1: Surgical spill IC2: Capsule ruptured before surgery or tumor on ovarian or fallopian tube surface IC3: Malignant cells in ascites or peritoneal washings
T2a	IIA	Extension and/or implants on the uterus and/or ovaries (one or both) or tube(s)
T2b	IIB	Extension to other pelvic tissues

TNM	FIGO	Description
T3a	IIIA1	Each retroperitoneal N1 IIIA1(i): Lymph node metastasis max. 10 mm IIIA1(ii): Lymph node metastasis > 10 mm
	IIIA2	Microscopic extrapelvic peritoneal involvement with or without lymph node metastasis
T3b	IIIB	Macroscopic peritoneal metastasis beyond the pelvis up to 2 cm in greatest dimension, with or without metastasis to the retroperitoneal lymph nodes.
T3c or N1	IIIC	Peritoneal metastasis beyond the pelvis more than 2 cm in greatest dimension, with or without metastasis to the regional lymph nodes.
M1	IVA	Malignant pleural effusion
M1	IVB	Parenchymal metastases (e.g. liver/spleen) and metastases to extra-abdominal organs

Table 4: Staging and prognosis of high-grade serous ovarian cancer

TNM	FIGO	5 year survival
T1	I	80–85 %
T2	II	70 %
T3 or N1	III	40–50 %
M1	IV	20 %

In general, the morphological subtype of ovarian cancer and the molecular changes play an important role in establishing the prognosis. The five most common subtypes of epithelial ovarian cancer are: Serous high-grade cancer, serous low-grade cancer, clear-cell carcinoma, mucinous carcinoma and endometrioid ovarian cancer. Serous high-grade cancer has, for all stages, the poorest prognosis with a 5-year survival rate of 40 %, followed by clear-cell carcinoma (60 %), endometrioid ovarian cancer (66 %) and mucinous ovarian cancer (87 %) [B14].

However, the most important prognostic factor remains surgical complete staging/ debulking. Patients with complete tumor resection (R0) have a much better prognosis than patients with residual tumor. The more residual tumor remains, the poorer the prognosis [B15].

A meta-analysis has already been carried out to investigate the question of whether treatment with new substances such as PARP inhibitors compensates for incomplete debulking in terms of prognosis. This showed a better prognosis if patients underwent complete tumor debulking with a R0 result. PARP inhibitors could not compensate for the incomplete surgery [B16]. [B14][B15][B16]

Treatment

For optimal gynecologic oncology treatment, preoperative testing should be used to assess the probability of the presence of a malignant ovarian tumor. To do this, there are diagnostic indices such as the RMI, which predict the presence of ovarian cancer with high sensitivity. A definitive diagnosis is then established with intraoperative frozen section analysis. If ovarian cancer is discovered incidentally, either during surgery or during histological processing, without complete surgical staging being planned and carried out, this should be repeated as quickly as possible (7 to 10 days) to prevent a poorer prognosis. If the primary surgery is laparoscopic, the trocar wound sites should be excised.

Surgery

Surgery, in the sense of complete tumor resection/debulking, remains one of the most important prognostic criteria for ovarian cancer. Even drug treatment cannot compensate for insufficient primary debulking. The main objective of surgical treatment is complete tumor resection (= optimal cytoreductive surgery).

At the end of the surgery, the abdominal cavity should ideally be macroscopically completely tumor-free (= R0 resection). Leaving behind residual tumor means a poorer prognosis. As a result, ultraradical debulking surgeries to ultimately improve the prognosis are not rare, although general status and fragility remain important factors when selecting patients. Perioperative mortality can be higher for fragile patients, so a balance must be struck between radicality and mortality. Nevertheless, these patients should not be undertreated. Special geriatric assessments can help with preoperative decision-making.

Surgical staging includes:

1. Palpation of the whole abdomen, including dome of the diaphragm
2. Hysterectomy with bilateral adnexectomy (figure 3)
3. Pelvic + para-aortic lymphadenectomy in early stages for staging purposes. According to data from the LION study, there is no benefit to systematic lymphadenectomy in advanced stages (from FIGO IIB).
4. Omentectomy
5. Appendectomy (obligatory in case of mucinous ovarian cancer)
6. Complete resection of macroscopic masses (including bowel resection, splenectomy, partial hepatectomy, etc. if required)

Figure 3: Advanced epithelial ovarian cancer with involvement of both ovaries and uterus.

Neoadjuvant chemotherapy can be considered, but is not standard, in cases of very advanced ovarian cancer, for example if primary macroscopic complete resection is impossible due to tumor location or spread, or if the required level of radicality is not clinically reasonable given the age, general condition or comorbidities of the patient. Laparoscopic scores (such as the Fagotti score) can help evaluate the primary operability in terms of feasibility of a R0 resection before primary debulking surgery. With early chemotherapy, there is the danger of resistance developing on a biological level. Several randomized studies have investigated neoadjuvant chemotherapy with carboplatin and paclitaxel. It has not yet been possible to show a benefit for this approach. However, a study has shown lower preoperative mortality.

Another field for treatment optimization is intraoperative HIPEC chemotherapy or intraperitoneal chemotherapy. The rationale behind this is that direct contact between the chemotherapy and the tumor can increase cytotoxicity. This approach has not yet been established in clinical routine, at least not at a global level. A randomized study published in 2018 showed that, under study conditions, patients who received HIPEC treatment with interval debulking (in case of R0 resection), i.e. after three cycles of chemotherapy, had a better prognosis for progression-free survival and overall survival versus intravenous chemotherapy alone [B17]. [B17]

In primary non-operable patients with extensive distant metastasis or comorbidities, neoadjuvant chemotherapy prior to staging surgery can be considered.

Laparoscopy is not suitable for staging surgery in ovarian cancer.

For younger patients who still wish to have children, fertility-sparing treatment (unilateral adnexectomy) can be discussed, only in early stages (T1a) and with good additional criteria. Specifically, the cancer should be limited to one ovary (T1a), histologically well defined (G1) with favorable histology (serous, endometrioid or mucinous). Nevertheless, the increased risk of recurrence must be evoked.

Borderline tumors should be treated similarly to ovarian cancer by means of a staging laparotomy. Larger series with a central pathology review have shown a recurrence in approx. 3,7 to 7,6 % of cases on follow-up. In general, the procedure should be the same as for invasive ovarian cancer, as in isolated cases there may be upstaging with invasion. Surgical staging should include comprehensive inspection and palpation of the whole abdomen with complete tumor resection (adnexectomy, hysterectomy, wash cytology, omentectomy and peritoneal biopsy sampling) [B18, B19].
Due to the unclear prognostic and therapeutic impact of lymphadenectomy with clinically unremarkable retroperitoneal lymph nodes, this is not part of the standard procedure for borderline tumors. It has not yet been possible to prove the benefits of adjuvant therapy for borderline tumors, but this can be discussed in case of invasive tumor implants. Fertility-sparing management is also possible with borderline tumors in low-risk situations, and complete surgery can be planned for when the patient no longer wishes to have children. [B18][B19]

Adjuvant chemotherapy

After optimal surgical treatment, adjuvant chemotherapy is generally carried out with the aim of eliminating microscopic residual tumor and preventing recurrence. Today, around 40 % of all epithelial ovarian cancers can generally be cured. The highest response rate is achieved with platinum-based combination chemotherapy. Since 2004, the common standard is treatment with six cycles of carboplatin AUC5-6 in combination with paclitaxel 175 mg/m2 every 3 weeks. Despite positive results in a Japanese study, dose-dense and weekly treatment plans have not gained traction due to subsequent neutral European and American studies. According to current guidelines, patients with stage IA G1 cancer do not require adjuvant chemotherapy and have an excellent prognosis with surgery alone. Patients with higher-grade cancers should receive platinum-based chemotherapy [B20].

Maintenance therapy in primary treatment

Due to the poor prognosis of ovarian cancer, maintenance strategies have been being researched for several decades, particularly for the common serous high-grade subtype. For example, extended chemotherapy over one year with taxane and radiotherapy approaches with whole abdomen radiotherapy have been investigated, without success. Systemic bevacizumab was the first targeted therapy to be recorded as a success. Bevacizumab is a monoclonal antibody against vascular endothelial growth factor (VEGF). VEGF plays an important role in the formation of new blood vessels, particularly in tumors, where it supports tumor growth and metastasis. Bevacizumab inhibits the binding of VEGF to its receptors, thus blocking the formation of new blood vessels in the tumor. This reduces the blood supply and reverses tumor growth [B21].
With regard to ovarian cancer, several studies have been carried out to investigate the efficacy of bevacizumab in combination with chemotherapy. In the well-known GOG-0218 study, it was demonstrated that the addition of bevacizumab to standard chemotherapy significantly improved the progression-free survival of patients with advanced ovarian cancer. Similar results have been observed in other studies such as ICON7 [B22, B23].
Furthermore, there are indications that bevacizumab could have a role to play in platinum-refractory ovarian cancer. In the AURELIA study, combination therapy with bevacizumab and chemotherapy showed significantly longer progression-free survival than chemotherapy alone.
Despite these promising results, further studies are required to better understand the optimal dosage, treatment duration and potential adverse effects of bevacizumab in ovarian cancer. Nevertheless, bevacizumab has the potential to expand the treatment options for patients with ovarian cancer and improve their prognosis.

The second major breakthrough was the development of PARP inhibitors. One of the first studies (Studie19) published several years ago showed a considerable benefit for patients with a recurrence of serous high-grade cancer. In this study, olaparib after platinum-based chemotherapy in recurrence was tested against placebo and showed clear superiority in PFS [B24]. In a later biomarker analysis, the effect was demonstrated above all in patients with a BRCA1 or BRCA2 mutation. Since then it has been shown that patients with a BRCA1 or BRCA2 mutation in particular clearly benefit from treatment with PARP inhibitors. Studies like SOLO1 have shown that PARP inhibitors like olaparib can significantly increase disease-free survival in patients with BRCA-mutated ovarian cancer. Furthermore, other clinical studies such as PAOLA-1 suggest that the combination of PARP inhibitors with bevacizumab can improve progression-free survival in advanced ovarian cancer. Here too, the benefit

was seen in particular for patients with a BRCA1 or BRCA2 mutation, and in patients with tumors with impaired DNA repair (HRD deficiency).
After the approval of olaparib, a second PARP inhibitor, niraparib, was approved in Switzerland. This also led to a rapid development. First, a clear benefit versus placebo could be shown in recurrence of HRD+/BRCA+, as well as BRCAwt serous high-grade cancer (PFS benefit).
In the PRIMA study, patients were included after initial treatment with surgery and chemotherapy. Of the 733 randomized patients, 373 (50.9 %) had tumors with HRD deficiency. Among patients in this category, progression-free survival was significantly longer in the niraparib group than in the placebo group (21.9 months vs. 10.4 months; hazard ratio [HR] for disease progression or death: 0.43; 95 % confidence interval [CI]: 0.31 to 0.59; P < 0.001). In the overall population, the corresponding progression-free survival was 13.8 months and 8.2 months (HR: 0.62; 95 % CI: 0.50 to 0.76; P < 0.001). The most common adverse events of grade 3 or higher were anemia (in 31,0 % of patients), thrombocytopenia (in 28,7 %) and neutropenia (in 12,8 %). No treatment-related deaths occurred.
Development with these drugs is progressing rapidly. Other 2nd generation PARP inhibitors are currently in development. This aims above all to effectively block PARP-1 or PARP-2 activity, and/or selectively inhibit PARP-1 to minimize adverse effects such as anemia. [B21][B22][B23]

Carboplatin (AUC 5-6) in combination with paclitaxel (175 mg/m2) at three-weekly intervals for six cycles remains the standard treatment. Longer treatment (e.g. 7 to 8 cycles) or the addition of a third drug does not give any further benefit with regard to disease control and should only be tested within studies.
The addition of a targeted anti-VEGF antibody (bevacizumab) gives a slight improvement in disease-free and overall survival in advanced ovarian cancer (stage IIIB to IV) and is the standard in high-risk situations in Switzerland. For BRCA+ patients and HRD+ tumors, PARP inhibitors are now standard as maintenance in first-line and second-line treatment.

Recurrence

The majority (approx. 60 %) of patients with serous high-grade ovarian cancer with complete remission after surgical treatment and adjuvant chemotherapy experience recurrence within the first five years. Prognostic factors have been covered above. Classically the dogma of platinum resistance applies, defined with the platinum-free interval. The management of recurrence has changed fundamentally in recent years. The AGO DESKTOP III trial prospectively evaluated secondary surgery with chemotherapy and showed an improved prognosis for complete secondary resection (R0) versus chemotherapy alone. All cases of recurrence after primary treatment should therefore be discussed at a multidisciplinary tumor board. With regard to the use of platinum-based chemotherapy, the terms “platinum-eligible” and “platinum-ineligible” are today widely used in the literature. The longer the platinum-free interval, the more likely a patient is to respond again to platinum-based chemotherapy. However, other factors are relevant to decision-making: Benefit of maintenance therapy with a PARP inhibitor, CA125 kinetics, benefit in treatment response in first-line therapy etc. Ultimately it is always an individual decision that can vary from case to case.

Antibody-drug conjugates (ADC) are a newer treatment option that will become routine in the coming months and years. They combine an antibody against a specific tumor antigen such as HER2, Trop2, folate receptor etc., a linker that binds the antibody to the cytotoxic chemotherapy and a chemotherapy molecule. The Pan-HER2-DESTINY study included patients with a gynecological tumor disease including ovarian cancer that was HER2-expressing (immunohistochemistry [IHC] 3+/2+). Patients with ovarian cancer had a response rate of up to 50 %.
In another study (SORAYA) investigating the ADC mirvetuximab soravtansine in folate receptor-alpha (FRα) positive ovarian cancer. Patients with platinum-refractory ovarian cancer who had already received treatment (51 % 3 lines or more) including PARP inhibitors. Among the 105 patients, a response rate of 32.4 % was reported, including 29 partial responses. The most common adverse events were blurred vision, keratopathy and nausea [B25].

Conventional chemotherapy such as paclitaxel weekly, PLD and topotecan are inferior to the new substance in terms of response rate and progression-free survival. However, they continue to have their place in the chain of treatment.

Patients who develop a late recurrence have a high probability of responding to second-line chemotherapy with complete remission and therefore also have a much better prognosis. Unlike primary therapy, which is intended to cure, it is rare for

treatment to cure recurring ovarian cancer completely. With favorable risk profiles (low risk Desktop score: no ascites, longer remission and low tumor burden), however, long-term prognoses are now possible [B26]. [B25][B26]

Literature

Nr.	Title	Author	Journal	Volume	Pages
[B01]	Cancer of the ovary	Cannistra SA	The New England journal of medicine	351(24)	2519-2
[B02]	Ovarian cancer	Cho KR, Shih Ie M	Annual review of pathology	4	287-31
[B03]	Role of surgical outcome as prognostic factor in advanced epithelial ovarian cancer: a combined exploratory analysis of 3 prospectively randomized phase 3 multicenter trials: by the Arbeitsgemeinschaft Gynaekologische Onkologie Studiengruppe Ovarialkarzinom (AGO-OVAR) and the Groupe d'Investigateurs Nationaux Pour les Etudes des Cancers de l'Ovaire (GINECO)	du Bois A, Reuss A, Pujade-Lauraine E, Harter P, Ray-Coquard I, Pfisterer J	Cancer	115(6)	1234-1
[B04]	The cell of origin of ovarian epithelial tumours	Dubeau L	The lancet oncology	9(12)	1191-1

Nr.	Title	Author	Journal	Volume	Pages
[B05]	The origin and pathogenesis of epithelial ovarian cancer: a proposed unifying theory	Kurman RJ, Shih Ie M	The American journal of surgical pathology	34(3)	433-44
[B06]	Statement by the Kommission Ovar of the AGO: The New FIGO and WHO Classifications of Ovarian, Fallopian Tube and Primary Peritoneal Cancer	Meinhold-Heerlein I, Fotopoulou C, Harter P, Kurzeder C, Mustea A, Wimberger P, Hauptmann S, Sehouli J	Kommission Ovar of the AGO. Geburtshilfe Frauenheilkd	75(10)	1021-1

Nr.	Title	Author	Journal	Volume	Pages
[B07]	Surgical staging and prognosis in serous borderline ovarian tumours (BOT): a subanalysis of the AGO ROBOT study	Trillsch F, Mahner S, Vettorazzi E, Woelber L, Reuss A, Baumann K, Keyver-Paik MD, Canzler U, Wollschlaeger K, Forner D, Pfisterer J, Schroeder W, Muenstedt K, Richter B, Fotopoulou C, Schmalfeldt B, Burges A, Ewald-Riegler N, de Gregorio N, Hilpert F, Fehm T, Meier W, Hillemanns P, Hanker L, Hasenburg A, Strauss HG, Hellriegel M, Wimberger P, Kommoss S, Kommoss F, Hauptmann S, du Bois A	Br J Cancer	112(4)	660-66
[B08]	The Dualistic Model of Ovarian Carcinogenesis: Revisited, Revised, and Expanded	Kurman RJ, Shih Ie M	Am J Pathol	186(4)	733-74

Nr.	Title	Author	Journal	Volume	Pages
[B09]	The fallopian tube as the origin of high grade serous ovarian cancer: review of a paradigm shift	Reade CJ, McVey RM, Tone AA, Finlayson SJ, McAlpine JN, Fung-Kee-Fung M, Ferguson SE	J Obstet Gynaecol Can	36(2)	133-14
[B10]	Opportunistic Salpingectomy Between 2017 and 2020: A Descriptive Analysis	Kaur P, Rufin K, Finlayson SJ, Huntsman DG, Kwon JS, McAlpine JN, Miller DM, Hanley GE	J Obstet Gynaecol Can		
[B11]	Ovarian cancer population screening and mortality after long-term follow-up in the UK Collaborative Trial of Ovarian Cancer Screening (UKCTOCS): a randomised controlled trial	Menon U, Gentry-Maharaj A, Burnell M, Singh N, Ryan A, Karpinskyj C et al.	The Lancet	397	2182-2
[B12]	A risk of malignancy index incorporating CA 125, ultrasound and menopausal status for the accurate preoperative diagnosis of ovarian cancer	Jacobs I et al.	Br J Obstet Gynaecol	97(10)	922-92

Nr.	Title	Author	Journal	Volume	Pages
[B13]	Survival and modelled cancer antigen-125 ELIMination rate constant K score in ovarian cancer patients in first-line before poly(ADP-ribose) polymerase inhibitor era: A Gynaecologic Cancer Intergroup meta-analysis	Corbaux P, You B, Glasspool RM, Yanaihara N, Tinker AV, Lindemann K, Ray-Coquard IL, Mirza MR, Subtil F, Colomban O, Péron J, Karamouza E, McNeish I, Kelly C, Kagimura T, Welch S, Lewsley LA, Paoletti X, Cook A	Eur J Cancer	191	11296
[B14]	Survival Outcomes for Different Subtypes of Epithelial Ovarian Cancer Tarinee	Manchana T, Kobwitaya K	Medicine		
[B15]	Influence of residual tumor on outcome in ovarian cancer patients with FIGO stage IV disease: an exploratory analysis of the AGO-OVAR (Arbeitsgemeinschaft Gynaekologische Onkologie Ovarian Cancer Study Group)	Wimberger P, Wehling M, Lehmann N, Kimmig R, Schmalfeldt B, Burges A, Harter P, Pfisterer J, du Bois A	Ann Surg Oncol	17(6)	1642-1
[B16]	Cytoreductive surgery for advanced epithelial ovarian cancer in the poly(ADP-ribose) polymerase inhibitors era-Is it time for a new paradigm shift? A systematic review and meta-analysis	Peters ITA, Marchetti C, De Palma A, Giannarelli D, Carcagnì A, Scambia G, Fagotti A	Eur J Cancer	187	77-86

Nr.	Title	Author	Journal	Volume	Pages
[B17]	Hyperthermic Intraperitoneal Chemotherapy in Ovarian Cancer	van Driel WJ, Koole SN, Sikorska K, Schagen van Leeuwen JH, Schreuder HWR, Hermans RHM, de Hingh IHJT, van der Velden J, Arts HJ, Massuger LFAG, Aalbers AGJ, Verwaal VJ, Kieffer JM, Van de Vijver KK, van Tinteren H, Aaronson NK, Sonke GS	N Engl J Med	378(3)	230-24

Nr.	Title	Author	Journal	Volume	Pages
[B18]	Borderline tumours of the ovary: A cohort study of the Arbeitsgmeinschaft Gynäkologische Onkologie (AGO) Study Group	du Bois A, Ewald-Riegler N, de Gregorio N, Reuss A, Mahner S, Fotopoulou C, Kommoss F, Schmalfeldt B, Hilpert F, Fehm T, Burges A, Meier W, Hillemanns P, Hanker L, Hasenburg A, Strauss HG, Hellriegel M, Wimberger P, Keyver-Paik MD, Baumann K, Canzler U, Wollschlaeger K, Forner D, Pfisterer J, Schröder W, Münstedt K, Richter B, Kommoss S, Hauptmann S; Arbeitsgmeinschaft Gynäkologische Onkologie (AGO) Study Group	Eur J Cancer	49(8)	1905-1
[B19]	Relapse and disease specific survival in 1143 Danish women diagnosed with borderline ovarian tumours (BOT)	Karlsen NMS, Karlsen MA, Høgdall E, Nedergaard L, Christensen IJ, Høgdall C	Gynecol Oncol	142(1)	50-53

Nr.	Title	Author	Journal	Volume	Pages
[B20]	NCCN Guidelines® Insights: Ovarian Cancer, Version 3.2022	Armstrong DK, Alvarez RD, Backes FJ, Bakkum-Gamez JN, Barroilhet L, Behbakht K, Berchuck A, Chen LM, Chitiyo VC, Cristea M, DeRosa M, Eisenhauer EL, Gershenson DM, Gray HJ, Grisham R, Hakam A, Jain A, Karam A, Konecny GE, Leath CA III, Leiserowitz G, Liu J, Martin L, Matei D, McHale M, McLean K, Miller DS, Percac-Lima S, Remmenga SW, Schorge J, Stewart D, Thaker PH, Vargas R, Hendrickson AW, Werner TL, Zsiros E, Dwyer MA, Hang L	J Natl Compr Canc Netw	20(9)	972-98
[B21]	The roles and limitations of bevacizumab in the treatment of ovarian cancer	Nakai H, Matsumura N	Int J Clin Oncol	27(7)	1120-1

Nr.	Title	Author	Journal	Volume	Pages
[B22]	A phase 3 trial of bevacizumab in ovarian cancer	Perren TJ, Swart AM, Pfisterer J, Ledermann JA, Pujade-Lauraine E, Kristensen G, Carey MS, Beale P, Cervantes A, Kurzeder C, du Bois A, Sehouli J, Kimmig R, Stähle A, Collinson F, Essapen S, Gourley C, Lortholary A, Selle F, Mirza MR, Leminen A, Plante M, Stark D, Qian W, Parmar MK, Oza AM; ICON7 Investigators	N Engl J Med	365(26)	2484-2

Nr.	Title	Author	Journal	Volume	Pages
[B23]	Final Overall Survival of a Randomized Trial of Bevacizumab for Primary Treatment of Ovarian Cancer	Tewari KS, Burger RA, Enserro D, Norquist BM, Swisher EM, Brady MF, Bookman MA, Fleming GF, Huang H, Homesley HD, Fowler JM, Greer BE, Boente M, Liang SX, Ye C, Bais C, Randall LM, Chan JK, Ferriss JS, Coleman RL, Aghajanian C, Herzog TJ, DiSaia PJ, Copeland LJ, Mannel RS, Birrer MJ, Monk BJ	J Clin Oncol	37(26)	2317-2
[B24]	A phase II study of regional 2-weekly 5-fluorouracil infusion with intravenous folinic acid in the treatment of colorectal liver metastases	Howell JD, McArdle CS, Kerr DJ, Buckles J, Ledermann JA, Taylor I, Gallagher HJ, Budden J	Br J Cancer	76(10)	1390-1

Nr.	Title	Author	Journal	Volume	Pages
[B25]	Efficacy and Safety of Mirvetuximab Soravtansine in Patients With Platinum-Resistant Ovarian Cancer With High Folate Receptor Alpha Expression: Results From the SORAYA Study	Matulonis UA, Lorusso D, Oaknin A, Pignata S, Dean A, Denys H, Colombo N, Van Gorp T, Konner JA, Marin MR, Harter P, Murphy CG, Wang J, Noble E, Esteves B, Method M, Coleman RL	J Clin Oncol	41(13)	2436-2
[B26]	Randomized Trial of Cytoreductive Surgery for Relapsed Ovarian Cancer	Harter P, Sehouli J, Vergote I, Ferron G, Reuss A, Meier W, Greggi S, Mosgaard BJ, Selle F, Guyon F, Pomel C, Lécuru F, Zang R, Avall-Lundqvist E, Kim JW, Ponce J, Raspagliesi F, Kristensen G, Classe JM, Hillemanns P, Jensen P, Hasenburg A, Ghaem-Maghami S, Mirza MR, Lund B, Reinthaller A, Santaballa A, Olaitan A, Hilpert F, du Bois A, DESKTOP III Investigators	N Engl J Med	385(23)	2123-2

Nr.	Title	Author	Journal	Volume	Pages	Year
[P01]	Effect of screening on ovarian cancer mortality: the Prostate, Lung, Colorectal and Ovarian (PLCO) Cancer Screening Randomized Controlled Trial	Buys SS, Partridge E, Black A, Johnson CC, Lamerato L, Isaacs C et al.	JAMA: the journal of the American Medical Association	305(22)	2295-2303	2011
[P02]	Neoadjuvant chemotherapy or primary surgery in stage IIIC or IV ovarian cancer	Vergote I, Trope CG, Amant F, Kristensen GB, Ehlen T, Johnson N et al	The New England journal of medicine	363(10)	943-953	2010

Nr.	Title	Author	Journal	Volume	Pages	Year
[P03]	Rethinking ovarian cancer II: reducing mortality from high-grade serous ovarian cancer	Bowtell DD, Böhm S, Ahmed AA, Aspuria PJ, Bast RC Jr, Beral V, Berek JS, Birrer MJ, Blagden S, Bookman MA, Brenton JD, Chiappinelli KB, Martins FC, Coukos G, Drapkin R, Edmondson R, Fotopoulou C, Gabra H, Galon J, Gourley C, Heong V, Huntsman DG, Iwanicki M, Karlan BY, Kaye A, Lengyel E, Levine DA, Lu KH, McNeish IA, Menon U, Narod SA, Nelson BH, Nephew KP, Pharoah P,	Nat Rev Cancer	15(11)	668-679	2015

Nr.	Title	Author	Journal	Volume	Pages	Year
		Powell DJ Jr, Ramos P, Romero IL, Scott CL, Sood AK, Stronach EA, Balkwill FR				
[P04]	Evolution of surgical treatment paradigms for advanced-stage ovarian cancer: Redefining 'optimal' residual disease	Changa SJ, Bristow RE	Gynecologic Oncology	125(2)	483–492	2012
[P05]	Molecular pathogenesis and extraovarian origin of epithelial ovarian cancer—Shifting the paradigm	Kurman RJ, Shih IM	Human Pathology	42(7)	918-931	2011

Nr.	Title	Author	Journal	Volume	Pages	Year
[P06]	ICON7 trial investigators. Standard chemotherapy with or without bevacizumab for women with newly diagnosed ovarian cancer (ICON7): overall survival results of a phase 3 randomised trial	Oza AM, Cook AD, Pfisterer J, Embleton A, Ledermann JA, Pujade-Lauraine E, Kristensen G, Carey MS, Beale P, Cervantes A, Park-Simon TW, Rustin G, Joly F, Mirza MR, Plante M, Quinn M, Poveda A, Jayson GC, Stark D, Swart AM, Farrelly L, Kaplan R, Parmar MK, Perren TJ	Lancet Oncol	16(8)	928-936	2015

Nr.	Title	Author	Journal	Volume	Pages	Year
[P07]	Early versus delayed treatment of relapsed ovarian cancer (MRC OV05/EORTC 55955): a randomised trial	Rustin GJ, van der Burg ME, Griffin CL, Guthrie D, Lamont A, Jayson GC, Kristensen G, Mediola C, Coens C, Qian W, Parmar MK, Swart AM; MRC OV05; EORTC 55955 investigators	Lancet	376(9747)	1155-1163	2010
[P08]	Randomized Trial of Cytoreductive Surgery for Relapsed Ovarian Cancer	Harter P et al.	N Engl J Med	385	2123-2131	2021