Last update: April 2024

Precancerous lesions of the vulva and vagina

Author: Prof. Dr. med. Mathias Fehr

Chefarzt Gynäkologie & Geburtshilfe, Ärztliche Leitung Brustzentrum Thurgau, Kantonsspital Frauenfeld, Spital Thurgau AG

Vulvar intraepithelial neoplasia

Classification

Squamous intraepithelial neoplasia are to be distinguished from non-squamous intraepithelial neoplasia.

Squamous form of vulvar intraepithelial neoplasia

According to the current 2014 WHO classification, the term VIN I-III (vulvar intraepithelial neoplasia) has been replaced by the following nomenclature [B01]:

- Vulvar LSIL (low-grade squamous intraepithelial lesion) replaces the term VIN I and is the clinical and histological correlation of an HPV infection with low risk of concomitant or future invasive neoplasia.
- Vulvar HSIL (high-grade squamous intraepithelial lesion) replaces the terms VIN II and III (usual type) and is an expression of an HPV infection with increased risk of developing an invasive carcinoma.
- Differentiated VIN (d-VIN) refers to an HPV-negative VIN on the basis of chronic dermatosis such as lichen sclerosus and lichen planus.
- Terms that used to be common, such as vulvar intraepithelial neoplasia (VIN), Bowen's disease, bowenoid papulosis, erythroplasia of Queyrat, are all replaced by the terms vulvar LSIL/HSIL or d-VIN.
  [B01]

CAVE: Doctors must always be aware of whether HSIL is cytological (cell smear) or histological. Cytological diagnostics should not play any role in vulvar conditions, so vulvar LSIL/HSIL always refer to histological diagnoses.

Non-squamous forms of vulvar intraepithelial neoplasia

- Vulvar Paget's disease (intraepithelial adenocarcinoma)
- Melanoma in situ (preinvasive melanoma)

Occurrence and incidence

Vulvar squamous intraepithelial lesions

The incidence of vulvar HSIL cannot be reliably determined, as only very few cancer registries have recorded these precancerous conditions to date. In the canton of Waadt (Switzerland), the incidence is given as 2,9/100’000 women per year, which is certainly too low. In a large prospective study of women under 25 years old, the cumulative incidence of vulvar HSIL was 0,6 % within four years, corresponding to 150/100’000 [P06].

Vulvar HSIL is some 10 times more common than lesions of the vagina, but 10 times rarer than high grade cervical intraepithelial neoplasia. The incidence has increased by over 400 % in the last 30 years, particularly in younger women. This increase is probably caused by the increase in HPV infections, which are responsible for vulvar HSIL. The average age of onset in Switzerland is 47 years [P01]. [P06][P01]

In terms of etiopathology, a distinction is made between:

- the common squamous intraepithelial lesion (SIL) associated with HPV (histologically basaloid or condylomatous)
- the rarer (< 10 %) differentiated VIN (d-VIN), which shows no association with HPV (generally p53 mutation). Lichen sclerosus or other chronic dermatosis of the vulvar skin (lichen ruber) is often present.

Low-grade squamous intraepithelial lesions (LSIL)

- Low-grade cell changes caused by infection with HPV, high and low risk.
- Low risk of progression to invasive neoplasia.

High-grade squamous intraepithelial lesions (HSIL)

- With this HPV high-risk associated intraepithelial neoplasia, HPV 16 is found in 76 % of cases. The lesion is often multifocal.
- The progression rate to invasive vulvar carcinoma is difficult to determine.. In a study, it was 12 % for HSIL that went untreated for one year.
- Up to 50 % of women with vulvar HSIL also have, at the same time or in their personal history, squamous cell carcinoma or intraepithelial neoplasia of the cervix or anus.
  [P02][P03]
- Approx. 6 % of patients with a history of cervical HSIL develop vulvar or vaginal HSIL years later. Another study with 3030 women with treated CIN 2+ or microinvasive cervical carcinoma reports that 7,4 % of these women developed a vaginal intraepithelial neoplasm (grade 2 or higher) within 45 months on

average. Regular colposcopic check-ups are therefore recommended for women who have undergone hysterectomy due to cervical HSIL.
- Conversely, up to 47 % of patients who were treated for vulvar HSIL later developed an anal intraepithelial neoplasm (AIN). The anal skin should therefore also be checked during each colposcopy after CIN or VIN and at least with HPV persistence an anoscopy to the dentate line is recommended. [P04][P09][P10]

Spontaneous regression of vulvar HSIL occurs in young patients, as does the regression of HSIL after pregnancy. However, there are no reliable predictive factors for spontaneous regression [P05]. [P05]

Differentiated VIN (d-VIN)

- The invasive potential of differentiated VIN seems to be much higher than that of vulvar HSIL. A 'wait-and-see' approach is therefore not recommended.
- Spontaneous regression has not been reported.
- Differentiated VIN occurs in older patients (usually > 60 years old) and against a background of chronic vulvar skin disorders (lichen sclerosus and planus).

Extramammary Paget's disease of the vulva

- This affects women of peri and postmenopausal age, most often aged 60 to 70 years old.
- Extramammary Paget's disease accounts for approximately 1 % of all vulvar neoplasms.
- In 4 to 17 % of cases, invasive adenocarcinomas are found within or below the surface lesion - the invasive Paget's carcinoma. These often originate from skin appendages.

Preferred locations include the vulvar and perineal skin, although Paget's disease can also occur on the axilla, areola (--> G10A), buttocks and eyelids.

Histology

High-grade Squamous intraepithelial lesions (HSIL)

No further information will be given here on LSIL, as they are HPV infections of the vulvar skin (see Condyloma chapter).

HSIL are characterized by:

- Increasing loss of normal epithelial maturation
- Increasing nuclear-cytoplasmic ratio in favor of nucleus

- Polymorphism
- Hyperchromasia
- Chromatin clumping
- Polynuclearism
- Single cell keratinization
- Mitotic nuclear activity
- p16 positive (overexpressed)

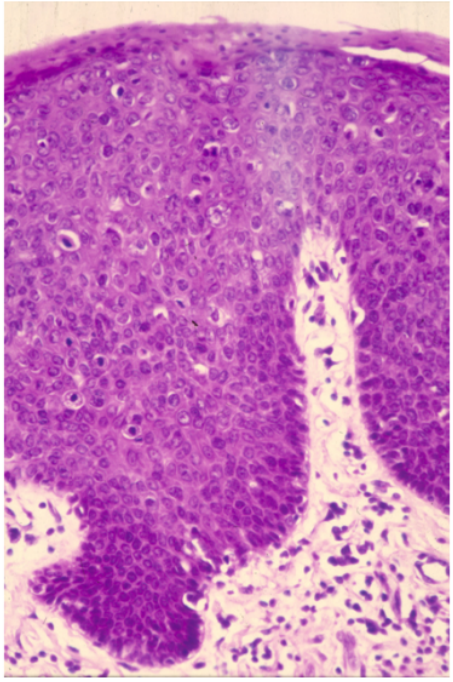

Figure 1: HPV associated vulvar HSIL.

Differentiated VIN (d-VIN)

- They are characterized by basal cell atypia with hyperchromasia, karyomegaly and atypical mitosis of the basal cell layer.
- There is often normal terminal differentiation, but with dykeratosis and hyperkeratosis.
- P16 negative (not overexpressed).
- Differentiated VIN is occasionally difficult to distinguish from benign hyperplasia and hypertrophic variants of lichen sclerosus.

Paget’s disease

- Paget’s disease of the vulva shows large adenocarcinoma cells, individually or in clusters throughout all layers of the epidermis.
- Hair shafts and excretory ducts of sweat glands are also affected.
- Paget’s disease is also referred to as “adenocarcinoma in situ limited to the epidermis”.

DD: Cells of a melanoma in situ can look very similar to Paget's disease in terms of morphology and distribution pattern. Additional immunohistochemical tests are often indispensable (Paget's disease = positive for CK 7 and CEA; melanoma in situ = positive for S-100 and HMB-45).

Signs and symptoms

HSIL/Differentiated VIN (d-VIN)

Diagnosis often takes place during a routine check-up.

- There are often no symptoms (20 %).
- The main symptoms of vulvar HSIL and d-VIN are pruritus, burning and papules.

Paget's disease

Symptoms mainly consist of pruritus and scaling redness. The latency between symptoms and diagnosis is long, on average 2 years.

Figure 2: Paget's disease of the vulva with mixed red and scaling white skin changes.

Diagnosis

Careful inspection of the vulvar skin with a colposcope (vulvoscopy) is required for diagnosis. The region from the groin covering the mons pubis to the perianal skin must be inspected.

HSIL/Differentiated VIN (d-VIN)

The use of 2 to 5 % acetic acid clarifies the extent of the HPV-associated neoplasia by causing the thickened epithelium to swell up and scatter light, hence appearing white. Differentiated VIN shows no reaction to acetic acid.

Figure 3: HSIL: Swelling of thickened epithelium scattering light after application of acetic acid 5 %(keratosis).

Although the vulva offers favorable conditions for diagnosis, vulvar carcinoma continue to be diagnosed at later stages. This is because many patients only consult a doctor late, and because the clinical picture of vulvar HSIL varies (and misdiagnoses therefore occur). D-VIN is found in lesions of chronic dermatosis (e.g. lichen sclerosus or lichen planus), which also complicates its diagnosis due to alterated surrounding skin.

Figure 4: Pronounced d-VIN with surrounding lichen sclerosus.

In addition to visual inspection, colposcopy is key to diagnosis, as is histological testing of all suspicious findings (using punch biopsy). Depending on the extent of the lesion, multiple punch biopsies may be required, as microinvasive areas within lesions clinically diagnosed as HSIL occur in up to 20 % of cases.

Paget’s disease

Invasiveness and thus transition into a Paget's carcinoma is rare. However, it is important to note that Paget's disease is associated with other malignancies, particularly urogenital and rectal carcinoma, in 10 to 15 % of cases. This must therefore be ruled out. In addition, extensive verification of other organs must be carried out. Generally, in addition to gynecological investigations this involves lung, abdominal and pelvis CT, mammography, cystoscopy and colonoscopy.

Treatment

HSIL/differentiated VIN (d-VIN)

The vaccination available against HPV 16 and 18 prevents vulvar SIL to a large extent. Treatment of HSIL (like for early invasive vulvar carcinoma) should, particularly in young patients, spare as many vulvar structures as possible [P06].
[P06]

There is no single superior treatment method. Even radical surgeries like vulvectomy and skinning vulvectomy with split skin graft show similarly high recurrence rates to local excision with a safety margin or biopsy and laser ablation (21 to 30 %).

- With less extensive cases, excision of the affected skin is ideal. The size of the safety margin is unclear.
- For more extensive lesions, laser ablation can be used to conserve structures (although multiple punch biopsies or excisions must be taken for histological testing, so that any invasiveness is not overlooked).

Laser ablation is successful for the hairless skin of the vulva due to the lack of skin appendages. The skin, together with the papillary dermis, must be ablated; i.e. until the collagen fibers of the dermis are visible (level III as per Reid). For skin with hair, the skin must be ablated to the hair follicle, which requires a very long recovery period of 4 to 6 weeks and is therefore to be avoided where possible. Excision is therefore preferred for skin with hair.

Immunostimulation with imiquimod 5 % (Aldara®, 3 times per week with application in the evening and washing off in the morning) has shown complete response in 35 % and 81 % of patients in two small randomized trials. However, in the follow-up period of just one year, invasive vulvar carcinoma occurred in one of the 26 patients. This drug treatment, which works on the basis of immunological elimination of HSIL, should therefore only be used with close follow-up [P03][P07][P11].

The issue of recurrence! More than 1/3 of patients treated using this method experience a recurrence locally or in another part of the lower genital tract. [P03][P07][P11]

50 % of recurrences occur at the previous treatment location, and the other 50 % in other, sometimes distant, locations. Distant recurrences are referred to as field cancerization, i.e. the recurrence of HSIL occurs years later in the vagina or anus. This is the expression of the multifocal malignant transformation after an oncogenic HPV infection of the anogenital skin.

The risk of developing an invasive carcinoma of the vulva, vagina or anus after treated vulvar HSIL is 6 %. 14 % of patients experience a recurrence after more than five years from first diagnosis, highlighting the importance of regular, long-term follow-up [P08]. [P08]

Paget's disease

Vulvar Paget's disease is difficult to treat. An excision in healthy subjects is seldom successful. If a safety margin is respected, the recurrence rate is approx. 10 %, otherwise it is 50 %. Immunomodulatory treatment with imiquimod cream has also been used successfully for Paget's disease of the vulva. Due to the rarity of the disease, however, there are no large case series. However, in large lesions Imiquimod 5 % three times a week is an option: A study with 24 patients treated over 16 weeks showed a response rate of 80 % with a complete histological response in 50 % [B03].

Radiotherapy and photodynamic therapy may be treatment options, although no large studies are available here either. [B03]

Vaginal intraepithelial neoplasia

According to the current 2014 WHO classification, the term VaIN I-III (vaginal intraepithelial neoplasia) has been replaced by the following nomenclature:

- Vaginal LSIL (low-grade squamous intraepithelial lesion) replaces the term VaIN I and is the clinical and histological expression of a HPV infection with low risk of concomitant or future invasive neoplasia.
- Vaginal HSIL (high-grade squamous intraepithelial lesion) replaces the terms VaIN II and III (usual type) and is an expression of a HPV infection with increased risk of developing an invasive carcinoma.
  [B01]

Occurrence and incidence

Vaginal HSIL is generally HPV-positive (> 75 % HPV-16) and mostly located in the upper or lower third of the vagina. Multifocality in 60 % of cases. The incidence of HSIL is low with 0,2-0,4 cases per 100'000 women per year. However, in women who have undergone hysterectomy due to cervical HSIL, the risk of later developing vaginal HSIL is 3,7 to 7,4 %. Overall, vaginal HSIL is probably often overlooked. However, as vaginal carcinoma is a rare disease, the significance remains unclear [P10]. [P10]

Diagnosis

- Colposcopy (use of 2 to 5 % acetic acid and Lugol's iodine - Schiller's Iodine test) and targeted biopsy.
- The frequency of occult invasion after biopsy-based diagnosis of vaginal HSIL is up to 30 %.

Treatment

- CO2-Laser evaporation of vaginal HSIL is an established treatment modality with few side effects and conservation of the function of the vagina.
- Intravaginal treatment with imiquimod 5 % is the second established treatment option with a complete pathological response rate of 76% in a metaanalysis of observational studies [B04].
- Cranial colpectomy for vaginal HSIL should be limited to severe cases and is not standard of care anymore.
- The frequency of recurrence seems to depend on treatment (almost 0 % after colpectomy and approx. 40 % after laser treatment).

- In treated patients, the progression rate to invasive vaginal carcinoma is 3 %. [B04][P07]

Literature

Nr.	Title	Author	Journal	Volume	Pages	Year
[B01]	WHO Classification of Tumours of Femal Reproductive Organs	Kurman R. J., Carcangiu M.L., Herrington C. S., Yound R. H. (eds.)	International Agency for Research on Cancer (IARC)			2014
[B02]	n.a.	Garland SM et al.	Obstet Gynecol	132	261	2018
[B03]	n.n.	Van der Linden M et al.	Am J Obstet Gynecol	227	250	2022
[B04]	n.n.	Inayama Y et al.	Gynecol Oncol	160	140-147	2021

Nr.	Title	Author	Journal	Volume	Pages	Year
[P01]	Trends in the incidence of invasive and in situ vulvar carcinoma	Judson PL, Habermann EB, Baxter NN, Durham SB, Virnig BA	Obstet Gynecol	107	1018-1022	2006

Nr.	Title	Author	Journal	Volume	Pages	Year
[P02]	Prevalence and type distribution of human papillomavirus in carcinoma and intraepithelial neoplasia of the vulva, vagina and anus: a meta-analysis	De Vuyst H, Clifford GM, Nascimento MC, Madeleine MM, Franceschi S	Int J Cancer	124	1626-1636	2009
[P03]	Is the assumed natural history of vulvar intraepithelial neoplasia III based on enough evidence? A systematic review of 3322 published patients.	van Seters M, van Beurden M, de Craen AJ	Gynecol Oncol	97	645-651	2005
[P04]	Risk of anogenital cancer after diagnosis of cervical intraepithelial neoplasia: a prospective population-based study	Edgren G, Sapren P.	Lancet Oncol	8	311-316	2007
[P05]	Vulvar intraepithelial neoplasia, III: A clinical study of the outcome in 113 cases with relation to the later development of invasive vulvar carcinoma	Jones RW, Rowan DM	Obstet Gynecol	84	741-574	1994

Nr.	Title	Author	Journal	Volume	Pages	Year
[P06]	Efficacy of a quadrivalent prophylactic human papillomavirus (types 6, 11, 16, and 18) L1 virus-like-particle vaccine against high-grade vulval and vaginal lesions: a combined analysis of three randomised clinical trials	Joura EA, Leodolter S, Hernandez-Avila M, Wheeler CM, Perez G, Koutsky LA, Garland SM, Harper DM, Tang GW, Ferris DG, Steben M, Jones RW, Bryan J, Taddeo FJ, Bautista OM, Esser MT, Sings HL, Nelson M, Boslego JW, Sattler C, Barr E, Paavonen J	Lancet	369	1693-1702	2007

Nr.	Title	Author	Journal	Volume	Pages	Year
[P07]	Treatment of vulvar intraepithelial neoplasia with topical imiquimod: seven years median follow-up of a randomized clinical trial	Terlou A, van Seters M, Ewing PC, Aaronson NK, Gundy CM, Heijmans-Antonissen C, Quint WG, Blok LJ, van Beurden M, Helmerhorst TJ	Gynecol Oncol	121	157-162	2011
[P08]	Disease progression and recurrence in women treated for vulvovaginal intraepithelial neoplasia	Fehr M, Baumann M, Mueller M, Fink D, Heinzl S, Imesch P, Dedes K	J Gynecol Oncol	24	235-240	2013
[P09]	n.a.	El Naggar et al.	Obstet Gynecol	122		2013
[P10]	n.a.	Schockaert S et al	Am J Obstet Gynecol	199	113-114	2008
[P11]	n.a.	Mathiesen O, Buus SK, Cramers M.	Gynecol Oncol	107	219-222	2007
[P12]	n.a.	Van Seeters M, van Beurden M et al.	New Engl J Med	358	1465-1473	2008