Last update: august 2022

Breast cancer: symptoms, diagnosis & prognosis

Co-Author(s): Prof. Dr. med. Rolf Kreienberg, Prof. Dr. med. Rolf A. Steiner, Prof. Dr. med. Mathias Fehr, Prof. Dr. med. Walter Jonat, Dr méd. Jean-François Delaloye

Author: Dr. med. Nadia Maggi

Oberärztin Brustchirurgie, Universitätsspital Basel

Symptoms

Cardinal symptom

The cardinal symptom is a palpable, rough, painless node. With small breasts and large tumors, there may be a change in breast size or asymmetry with the opposite side. Tumors close to the skin can cause skin or nipple retraction - and occasionally bulging of the breast contour.
Locally advanced stages can present skin edema (with noticeably large pores - peau d'orange) or ulcerations. Occasionally, there may also be nodules in the skin due to cutaneous tumor spreading. These may spread over the whole chest wall to the sternum, clavicle and past the axilla to the shoulder blade (Carcinoma en cuirasse).

Inflammatory carcinoma (2 %)

The diagnosis of inflammatory carcinoma is based on the clinical picture of pronounced skin edema with swelling, reddening and overheating of the breast skin, as found with mastitis. In 80 % of cases, histopathology confirms a lymphatic invasion of the skin (lymphatic system invasion).

Axillary lymph nodes

The axillary and/or supraclavicular lymph nodes may be easily palpable, even in early stages, and cancerous (differential diagnosis: reactive lymph node changes, particularly after previous interventional measures (fine needle puncture, punch biopsy) or vaccinations). Any abnormal lymph nodes must be biopsied before surgery (histological investigation). Axillary lymph node involvement can also manifest as lymphedema of the arms.

Changes to the nipple

Bloody secretion from the nipple

This may be from papilloma or an early intraductal cancer. The cause of the secretion must always be investigated.

Eczema-like changes to the skin of the nipple

Paget's disease should be considered in cases of itching, burning or eczema-like flaking changes to the skin. A biopsy should be carried out to investigate.

Indications of distant metastasis

"Banal" skeletal pain in association with breast tumors may be caused by early bone metastasis and must be investigated as part of staging. Depending on the location of distant metastases, various clinical symptoms may occur:

- Skeleton: Skeletal or back pain, pathological fractures of the spine, pelvis or long bones, (rarely hypercalcemia)
- Liver: Jaundice, signs of liver failure
- Lungs: Dyspnea (due to malignant pleural effusion), cough
- CNS: neurological failures

Diagnosis

Diagnosing breast tumors requires an interdisciplinary approach.

Basic examination

The necessary basic examination includes:

- Careful clinical history-taking, which is essential for the interpretation of physical examination findings. It also provides important information for the individual risk evaluation (personal history, gynecological history, family history, hormone/drug use, evaluation of risk factors etc.)
- Clinical breast examination (bilateral): medical inspection, palpation of breast and pathways
- Mammography
- Additional diagnostics if applicable (ultrasound, MRI)

If the clinical breast examination reveals abnormal findings, diagnostic imaging should be carried out. For women under 40, ultrasound is the first-line imaging method. Depending on findings and breast density, additional mammography and/or breast MRI may be required.
For women over 40, mammography and ultrasound are the first-line imaging methods (MRI may be used in some rare cases, see below “Imaging”).

The effects of endogenous and exogenous hormones must be taken into account when carrying out and analyzing any diagnostic methods (pre menopause: not before or during menstruation (optimal timing is days 8 to 14 of cycle, particularly relevant to MRI). Post menopause: if necessary after interruption of hormone replacement therapy).

Imaging

Mammography

Mammography is currently the only method for identifying precancerous lesions (e.g. microcalcifications as in ductal carcinoma in situ). It is also recognized as an effective method for early tumor stages. Even lesions measuring < 3 mm can be seen.

Implementation: Craniocaudal and mediolateral views as standard, if necessary enlarged images or 3D mammography (tomosynthesis).

Evaluation: Description of findings (asymmetrical, suspicious densification and/or grouped malignant microcalcifications), homogeneity and density of breast parenchyma (ACR category), overall assessment (BI-RADS category). High density on mammography (ACR c and d) is, in addition to BRCA1/2 mutation, the highest risk factor. In these cases, the limited sensitivity of mammography should be raised with an additional ultrasound (combination of both methods).

Reference for standardized classification of breast imaging

Table 1: ACR classifications (American College of Radiology)

ACR a	Breast tissue involution (< 25 % glandular tissue)
ACR b	25–50 % glandular tissue
ACR c	50–75 % glandular tissue
ACR d	> 75 % glandular tissue

Table 2: BIRADS classifications (Breast Imaging Reporting and Data System) © American College of Radiology

Category	Assessment	Description	Likelihood of malignancy	Recommendation
0	–	Incomplete		Additional imaging needed
1	Negative	Normal presentation	0 %	Routine screening

Category	Assessment	Description	Likelihood of malignancy	Recommendation
2	Benign	Changes on mammography with no indication of malignant change (fibroadenoma, cysts)	0 %	Routine screening
3	Probably benign	Very probably benign change	2 %	Follow-up after a short interval, if necessary biopsy
4	Suspicious	Possible, not characteristic, indication of malignancy	2–95 %	Biopsy should be considered
5	Highly suggestive of malignancy	High probability of presence of malignancy	> 95 %	Indication for biopsy
6	Known malignancy	Histologically confirmed breast cancer		

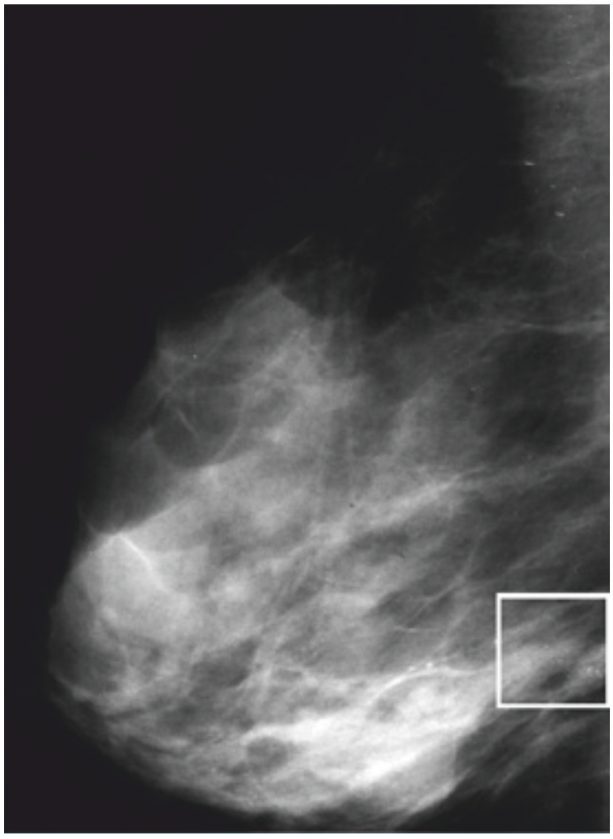

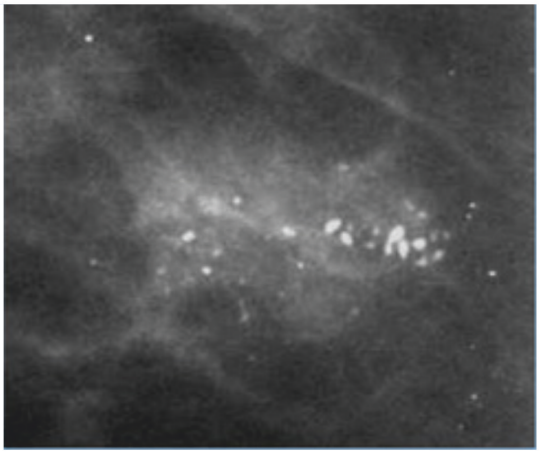

Shape: irregular
Margins: spiculated
Density: equal density
Calcification: pleomorphic
< 0,5 mm
Diagnosis: Invasive ductal breast cancer (NST) with DCIS

Figure 1: Mammography with calcification

Breast ultrasound

Ultrasound is an additional examination for clarifying unclear findings. Standard diagnostic method for palpable findings in women under 40. It should be used to investigate mammography findings that are not clinically palpable.

The objective of standardized breast ultrasound is the systematic, reproducible investigation of both breasts and the axilla (suspicious lymph nodes?).

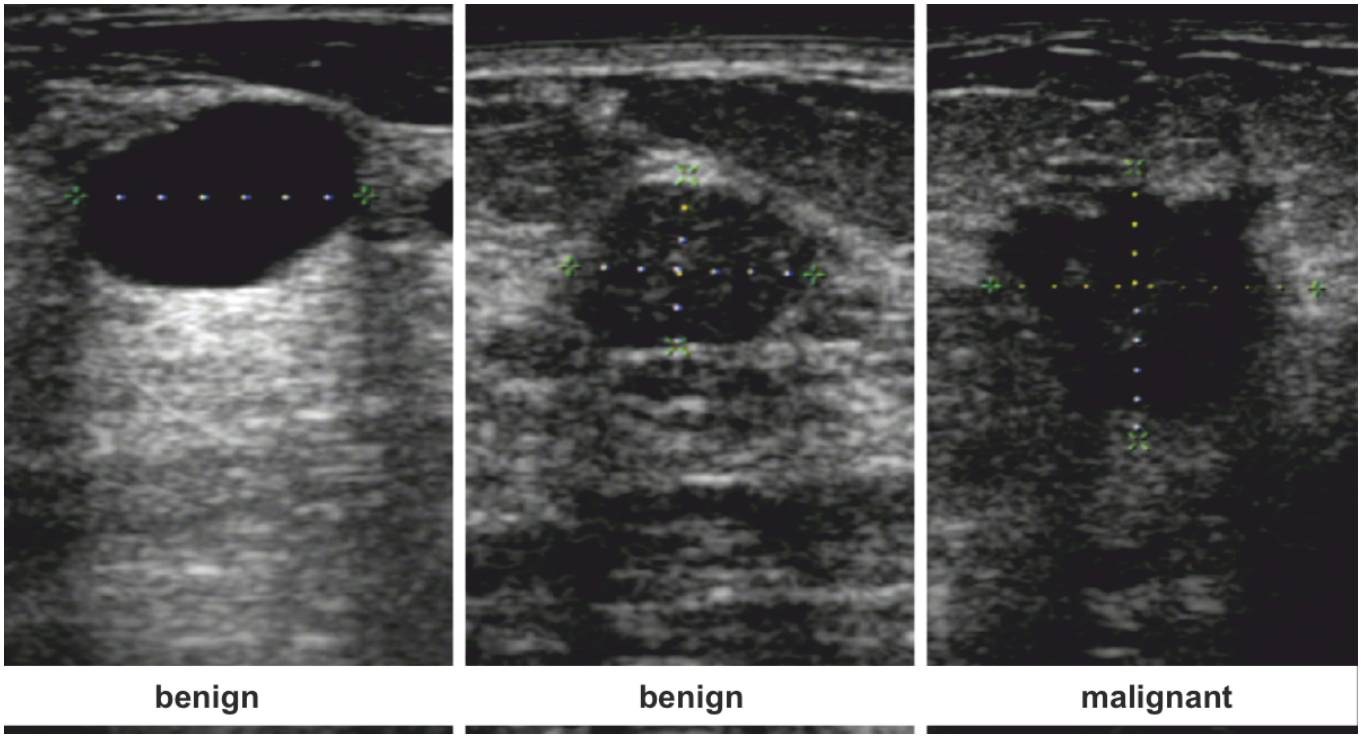

Figure 2: Ultrasound of breast lesions

Breast MRI

Breast MRI shows the breast using magnetic resonance imaging with contrast and is a possible additional test to be used with mammography and ultrasound.

Possible indications for breast MRI include increased precaution in high-risk situations (e. g. younger women with high family risk of breast cancer), symptoms after placement of silicone breast implants, monitoring of neoadjuvant chemotherapy, postoperative follow-up after primary breast cancer to differentiate between scarring and recurrence.

In addition:

- preoperative assessment with evidence of multifocality and multicentricity or to assess excision margins with lobular breast cancer
- Women with dense glandular tissue that is difficult to assess
- Spread of findings with inflammatory breast cancer

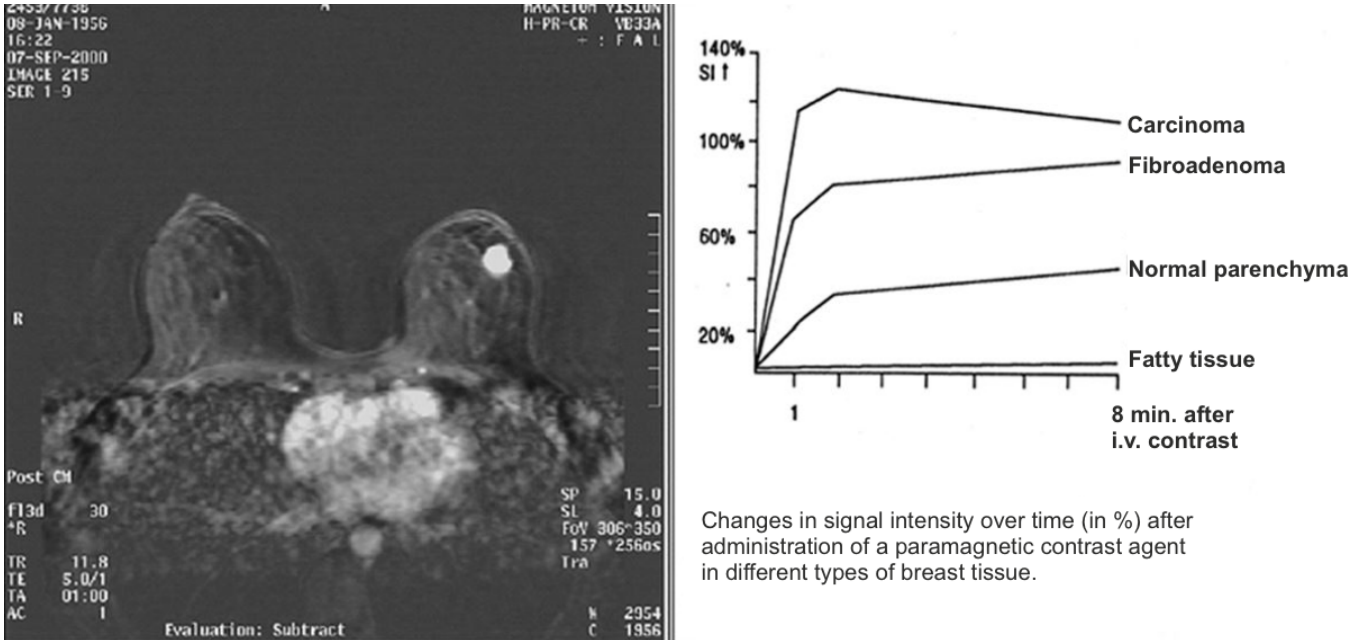

Changes in signal intensity over time (in %) after administration of a paramagnetic contrast agent in different types of breast tissue.

Figure 3: Breast MRI with finding on left (Breast MRI only for specific indications)

Diagnostic confirmation

The objective of imaging-guided minimally invasive biopsy is to provide histological confirmation of all findings requiring clarification. This can be carried out as a punch biopsy, vacuum-assisted biopsy or open biopsy.

- Punch biopsy: ≥ 3 samples with ≤ 14 G needle
- Vacuum-assisted biopsy: (≥ 12 samples with 10 G needle)

Fine-needle aspiration should no longer be used as the standard method. Interventional guided tissue sampling for histological diagnosis confirmation and treatment planning must take place for mammography findings of BIRADS 4 and BIRADS 5 and/or ultrasound findings of ultrasound BIRADS 4 or 5. Comparable MRI findings and MRI BIRADS 4 or 5.

- Punch biopsy (freehand) is used for palpable findings.
- For ultrasound findings (non-palpable), ultrasound-guided punch biopsy or vacuum-assisted punch biopsy
- For mammography findings (non-palpable), mammography-guided stereotactic vacuum-assisted punch biopsy
- For MRI-confirmed findings (non-palpable), MRI-guided tissue sampling.

After minimally invasive imaging-guided tissue sampling, the results should be evaluated to assess the correlation between the imaging diagnosis and the histopathological finding. In addition to morphology, biopsy provides other important information (hormone receptor status and HER2 status). For histopathologically benign findings, follow-up using appropriate tests may be required after six months (false-negative finding!).

Open excision biopsy: Today, the open diagnostic excision of lesions detected on mammography should only take place in isolated cases, where the suspected area cannot be accessed by mammography-guided vacuum-assisted biopsy (e.g. close to chest wall). Preoperative marking and postoperative imaging to confirm adequate resection should always be carried out.

Staging

Staging should be carried out on evidence of a malignant breast tumor. The most commonly used classification is the TNM classification. Tumor marker investigations are not required for primary diagnosis.

The aforementioned diagnostic methods are used to assess the size of the primary tumor (T). For patients with locally advanced tumors, the signs of local tumor growth must be described precisely (inflammatory components, ulceration, satellite skin metastases, chest wall involvement). A mammography of the opposite side should also take place as part of the preoperative diagnostic procedure.

Lymph node (N) assessment takes place clinically through palpation of the axilla and, if necessary, with additional imaging (ultrasound, MRI). If this gives rise to abnormal findings, histological confirmation via biopsy is required.

The assessment of distant metastasis (M) is above all indicated for patients at increased risk of metastasis:

- Clinical signs and symptoms
- Advanced local tumor stage (large tumor, lymph node involvement)
- Breast cancer recurrence
- Before starting systemic primary treatment/aggressive tumor biology

Suitable tests for assessing M status are

- Blood tests
- Chest imaging: lung metastases, pleural effusion?

- Bone scintigraphy: bone metastases?
- Upper abdomen ultrasound: liver metastases?

Further clarification for suspicious findings if required:

- Abdominal CT
- Chest CT
- Brain CT for specific symptoms (PET-CT)

Diagnostic confirmation of distant metastasis

Suspected distant metastasis should be confirmed histologically (e. g. pleural effusion or lymph node biopsy). Today, it is usual, wherever possible, to determine the current hormone receptor status and HER2/neu status when new distantmetastasis occur (liver, lungs, bone etc.). There may be a change in hormone receptor status and HER2/neu status versus the primary tumor, in which case different treatment appropriate to the current receptor status in the metastasis must be selected.

Prognosis

The prognosis of breast cancer depends on the tumor stage at diagnosis and the molecular subtype. Screening programs and better multimodal treatments mean that breast cancer prognoses in Switzerland and Europe have improved considerably in recent decades.

Table 3: Swiss National Cancer Registry: Relative 5-year survival rate for breast cancer in Switzerland from 2003-2012 (resp. *2013-2017)

Stage	Relative 5-year survival
Stage I	99 %
Stage II	91 %
Stage III	72 %
Stage IV	27 %
All stage	86 % (88 %*)

A reliable evaluation of the individual risk of each patient with breast cancer is an important requirement for planning systemic treatment and allowing personalized systemic treatment. Both overtreatment and undertreatment should be avoided. The most reliable prognosis criteria and predictive factors for response to specific treatment forms possible are therefore absolutely necessary for appropriate treatment. This applies to both patients with breast cancer and those with recurrence or metastasis.

Prognosis criteria for invasive breast cancer

pTNM status

- Tumor size (max. tumor diameter)
- Axillary lymph node status (post surgical exploration) with number of histologically involved lymph nodes. Most important prognostic factor for operable breast cancer. The higher the number of involved axillary lymph nodes, the higher the risk of recurrence and metastasis and the lower the recovery rate.
- Distant metastasis at time of primary treatment (M1 status): may require different treatment methods to M0 tumors (e.g. no primary surgery, primary chemotherapy).

Resection margin (R classification) and safety margins

- Resection margin status (involved versus tumor-free)
- Minimal safety margin in case of tumor-free resection margin (in mm)

Histopathological testing must state how close the invasive tumor front is to the surgical resection margin. A distinction is drawn between "adjacent tumor" and "tumor not immediately adjacent to resection margin" (measurement of smallest margin in mm, separately for invasive and intraductal tumor components). This is particularly important for assessing the prognosis for local recurrence and may affect the postoperative radiotherapy dose (boost).

Morphology

Histological subtype (WHO classification)

- Invasive ductal carcinoma (NST = No Special Type), 40 to 75 % of breast cancers and invasive lobular carcinoma, approx. 5 to 15 % of invasive breast cancers, both with similar prognosis.
- Invasive lobular carcinomas are different identified as invasive ductal carcinomas, due to multifocality of up to 30 %, bilaterality of up to 45 % and a different metastasis pattern.
- Tubular, mucinous, papillary and medullar carcinomas have a better prognosis than invasive ductal and invasive lobular carcinomas.

Histopathological tumor grading: The histological level of tumor differentiation is an important prognosis factor, even for very small breast tumors. To determine the grading, tubular differentiation, extent of nuclear atypia and mitotic index are summarized in a score.

- G1: well differentiated tumors
- G2: moderately differentiated tumors
- G3: poorly differentiated tumors with high potential for metastasis

Vascular invasion (peritumoral and/or perinodal lymphatic or vascular system invasion): Peritumoral lymph/vascular invasion (LVI) presents a significantly high and independent risk for the formation of local tumor recurrences. Evidence of LVI means that a patient’s risk of recurrence or development of distantmetastasis is significantly higher (frequency of LVI between 8 and 33 %).

Steroid hormone receptors and HER2 gene amplification

Estrogen receptor (ER) and/or progesterone receptor (PR) hormone receptor status: These only have relatively low prognostic relevance, but are the strongest predictive factors for response to endocrine therapy. Of 100 patients with breast cancer, 50 are estrogen and progesterone receptor positive, 25 patients are only estrogen receptor positive, 3 patients are only progesterone receptor positive, and 22 patients are negative for both hormone receptors.

Overexpression (=amplification) of HER2 gene / HER2 status: Today, determining HER2 status is an obligatory part of the primary diagnosis of breast cancer. Human epithelial growth factor receptor 2 (HER2) is overexpressed in 10 to 20 % of breast cancers, generally with underlying gene amplification. HER2 overexpression and/or gene amplification are associated with more aggressive tumor growth.

Proliferation and gene expression

Ki-67 antigen (in %): Proliferative tumor activity can be established using immunohistochemistry with evidence of a proliferation-associated antigen (Ki-67). A higher proportion of Ki-67 (>/= 30 %) shows a highly proliferative aggressive tumor with a poor prognosis.

Gene expression analysis (multigene testing): The development of techniques for gene expression analysis in breast tumors on a gene chip has led to improvements in risk assessment.

Molecular genetic subtypes: In recent years, the analysis of gene expression profiles has identified molecular subtypes of breast cancer that differ considerably in their clinical progression and response to treatment:

- Luminal A
- Luminal B
- HER2 positive
- Basal-like

As the use of array analyses is not currently feasible in routine practice, a simplified classification has been proposed as a replacement, based on immunohistochemical tests:

- Luminal A: ER+ and/or PgR+ and HER2- and low Ki-67 (< 30 %)
- Luminal B: HER2-, ER+ and/or PgR+ and high Ki-67 (>/= 30 %) / HER2+, ER+ and/or PgR+ and high or low Ki-67

- HER2 positive: ER- and PgR- and HER2+
- Triple negative: ER-, PgR- and HER2-

With luminal-A-type tumors, only adjuvant endocrine therapy is only considered necessary, while for the other subtypes chemotherapy is recommended.

Predictive treatment-relevant factors for invasive breast cancer

For clinical practice, it is important to know which treatment is appropriate for improving the patient's prognosis. This has led to the investigation of predictive factors taking on increasing importance.

The following are predictive factors (predicting treatment response)

- Age and menopause status
- Hormone receptor status
- HER2/neu status
- Proliferation rate (Ki-67)
- Gene expression analysis

Age and menopause status

For adjuvant chemotherapy, there is a clear age-dependency. For younger women under 40, chemotherapy leads to a treatment response in almost 40 % of cases. This figure is only 20 % for patients aged 60 to 69.

Hormone receptor status

The first predictive factor for breast cancer to be discovered was hormone receptor status. In 60 to 80 % of cases, tumors from patients with positive estrogen receptor status show sensitivity to a form of endocrine therapy (antiestrogen therapy, aromatase inhibitors) (--> G10E).

HER2/neu status

Positive HER2/neu status is a strong predictive factor for response to treatment with the humanized antibody trastuzumab/pertuzumab, which targets the HER2/neu protein on the cell surface (--> G10E).

Ki-67

Proof of a high proliferation rate in the tumor tissue, i.e. a high proportion of Ki-67, is most associated with sensitivity to chemotherapy (--> G10E).

Gene expression analysis

Gene expression analysis is used for risk group classification of patients with locally limited (pT1-2, pN0-1), HR positive, HER2 negative cancer, for whom the prognosis factors (in particular Ki-67) give no clear indication for or against adjuvant chemotherapy.

Standardized commercial tests are now available for certain gene signatures. For both the 70 gene assay (Mammaprint®) and the 21 gene chip (Oncotype DX®), prospective randomized studies have shown that patients with a low-risk score have a very good prognosis and would therefore probably gain no or only minor benefit from adjuvant chemotherapy, while patients with high-risk scores improve their prognosis with chemotherapy.

Literature

Nr.	Title	Author	Journal	Volume	Pages
[B01]	Interdisziplinäre S3-Leitlinie für die Früherkennung, Diagnostik, Therapie und Nachsorge des Mammakarzinoms (Langversion 4.4)	Leitlinienprogramm Onkologie			
[B02]	Therapieempfehlungen der AGO/Kommission Mamma	AGO/Kommission Mamma			
[B03]	Panelists of the St Gallen Consensus Conference. Customizing local and systemic therapies for women with early breast cancer: the St. Gallen International Consensus Guidelines for treatment of early breast cancer 2021	Burstein HJ, Curigliano G, Thürlimann B, Weber WP, Poortmans P, Regan MM, Senn HJ, Winer EP, Gnant M	Ann Oncol	32(10)	1216-12

Nr.	Title	Author	Journal	Volume	Pages
[B04]	Trastuzumab after adjuvant chemotherapy in HER2-positive breast cancer	Piccart-Gebhart M. J., Procter M., Leyland-Jones B., Goldhirsch A., Untch M., Smith I., Gianni L., Baselga J., Bell R., Jackisch C., Cameron D., Dowsett M., Barrios C. H., Steger G., Huang C. S., Andersson M., Inbar M., Lichinitser M., Lang I., Nitz U., Iwata H., Thomssen C., Lohrisch C., Suter T. M., Ruschoff J., Suto T., Greatorex V., Ward C., Straehle C., McFadden E., Dolci M. S., Gelber R. D.	N Engl J Med	353(16)	1659-16
[B05]	Relevance of breast cancer hormone receptors and other factors to the efficacy of adjuvant tamoxifen: patient-level meta-analysis of randomised trials	n.n.	Lancet	378(9793)	771-784

Nr.	Title	Author	Journal	V

Nr.	Title	Author	Journal	V
[P01]	Biomarker und Risikoabschätzung beim Mammakarzinom: Genexpressionssignaturen auf dem Weg in die Routine	Schmidt M, Maass N	Gynäkologe	4
[P02]	Pathological prognostic factors in breast cancer. I. The value of histological grade in breast cancer: experience from a large study with long-term follow-up	Elston C. W., Ellis I. O.	Histopathology	1
[P03]	Gene expression and benefit of chemotherapy in women with node-negative, estrogen receptor-positive breast cancer	Paik S., Tang G., Shak S., Kim C., Baker J., Kim W., Cronin M., Baehner F. L., Watson D., Bryant J., Costantino J. P., Geyer C. E., Jr., Wickerham D. L., Wolmark N.	J Clin Oncol	2
[P04]	Predicting the risk for additional axillary metastases in patients with breast carcinoma and positive sentinel lymph node biopsy	Viale G., Maiorano E., Pruneri G., Mastropasqua M. G., Valentini S., Galimberti V., Zurrida S., Maisonneuve P., Paganelli G., Mazzarol G.	Ann Surg	2

Nr.	Title	Author	Journal	V
[P05]	Assessment of ki67 in breast cancer: recommendations from the international ki67 in breast cancer working group	Dowsett M, Nielsen TO, A'hern R, Bartlett J, Coombes RC, Cuzick J, Ellis M, Henry NL, Hugh JC, Lively T, McShane L, Paik S, Penault-Llorca F, Prudkin L, Regan M, Salter J, Sotiriou C, Smith IE, Viale G, Zujewski JA, Hayes DF.	J Natl Cancer Inst	1
[P06]	Recommendations from the EGAPP Working Group: can tumor gene expression profiling improve outcomes in patients with breast cancer?	Evaluation of Genomic Applications in Practice and Prevention (EGAPP) Working Group (2009)	Genet Med	
[P07]	HER2 discordance between primary breast cancer and its paired metastasis: tumor biology or test artefact? Insights through meta-analysis	Houssami N, Macaskill P, Balleine RL, Bilous M, Pegram MD.	Breast Cancer Res Treat	1
[P08]	Margins in breast cancer: How much is enough?	Pilewskie M, Morrow M.	Cancer	1

Nr.	Title	Author	Journal	V
[P09]	Molecular portraits of human breast tumours	Perou CM, Sørlie T, Eisen MB, van de Rijn M, Jeffrey SS, Rees CA, Pollack JR, Ross DT, Johnsen H, Akslen LA, Fluge O, Pergamenschikov A, Williams C, Zhu SX, Lønning PE, Børresen-Dale AL, Brown PO, Botstein D.	Nature	4
[P10]	Clinical Outcomes in Early Breast Cancer With a High 21-Gene Recurrence Score of 26 to 100 Assigned to Adjuvant Chemotherapy Plus Endocrine Therapy: A Secondary Analysis of the TAILORx Randomized Clinical Trial	Sparano JA, Gray RJ, Makower DF et al.	JAMA Oncol	6
[P11]	70-gene signature as an aid for treatment decisions in early breast cancer: updated results of the phase 3 randomised MINDACT trial with an exploratory analysis by age	Piccart M, van't Veer LJ, Poncet C et al.	Lancet Oncol	2

Nr.	Title	Author	Journal	V
[P12]	Survival of women with cancers of breast and genital organs in Europe 1999-2007: results of the EUROCARE-5 study	Sant M, Chirlaque Lopez M.D., Agresti R, Sánchez Pérez M.J, Holleczek B, Bielska-Lasota B, Dimitrova N, Innos K, Katalinic A, Langseth H, Larrañaga N, Rossi S, Siesling S, Minicozzi P	Eur. J. Cancer	5
[P13]	Effects of age and stage on breast cancer survival in Switzerland	Bouchardy C, Lorez M, Arndt V and the NICER Working Group	Schweizer Krebsbulletin	
[P14]	Krebsüberleben – Statistiken zu nationalen Überlebensraten bei Krebs	Krebsepidemiologische Forschung (NICER)		