Last update: 2015/2016

Anatomical and physiological principles

Co-

Author: PD Dr. med. Daniele Perucchini

Inhaber/Leiter Blasenzentrum AG, Konsiliararzt Klinik für Gynäkologie, UniversitätsSpital Zürich

Author(s): Prof. Dr. med. Urs Haller

The control of the storing and emptying function of the urinary bladder are complex. It involves regulatory circuits, receptors, and neurotransmitters of the somatic and autonomous nervous system. A mixture of inhibiting and stimulating impulses is formed. The physiological, situation-appropriate balance of these impulses can be disrupted by pathological processes. The balance can be regenerated by means of training or medical intervention.

Continence Factors

- “Relaxed” (i.e., adaptable) bladder muscles
- Expandable bladder (no adhesions or fibrosis)
- Efficient urethral closure (by autonomous closure reflexes as well as voluntary contraction)
- Healthy pelvic floor with intact anatomical support

Only when the bladder muscles, the sphincter apparatus and pelvic floor react physiologically, are humans able to:

- Store urine that is continuously produced in the kidneys and
- Precipitate situation-appropriate micturition

Reservoir Function – Continuous

With increasing bladder filling, the bladder expands and the bladder muscles adapt, which keeps the pressure inside the bladder constant. This is noticed at a filling of approximately 150 to 200mL! At this point, it depends on the voluntary desire of the individual whether the bladder is filled up further or micturition occurs. Normal bladder capacity varies between approx. 300 to approx. 600mL.

Micturition – Periodic

Coordinated start impulses ensure that the pelvic floor relaxes and the urethral sphincter starts to relax. The detrusor muscle contracts increasingly to push out the entire bladder content through pressure. Once consciously started, the bladder is emptied largely reflexively (voluntary interruption is almost impossible). Voluntary activation of the abdominal prelum can increase urinary flow.

Urinary Bladder

The main tasks of the bladder are storing urine on the one hand, and voluntarily emptying the bladder on the other hand. Learning normal bladder function is an important part of childhood development.

The urinary bladder is a musculomembranous low pressure storage for urine. It is located in the lesser pelvis posterior to the symphysis and anterior to the uterus and vagina. Depending on its filling volume, it occupies a varying portion of the pelvis. Normal bladder capacity (so-called maximum bladder capacity) is approximately 300-600 ml. Greater “normal bladder filling” without urinary urgency are probably trained. The inside of the urinary bladder is lined with a hormone-sensitive urothelium. The urothelium is not simply a passive membrane, but plays an active role in controlling bladder function.

Therefore, the urothelium has specialized surface proteins and ion pumps with proteoglycans and glycoproteins. All these structures combined contribute to impermeability. The same mechanisms provide protection from bacterial infection.

This part has not been translated into English.
Figure 1

Figure 1
The bladder wall is a flexible mesh consisting of smooth muscle. These are called “detrusor muscle”.

The inner lining of the bladder is densely supplied with nerve endings. The firm, connective tissue trigonum maintains the funnel shape of the bladder neck.

Urethra

The adult female urethra is approx. 3 cm in length. The non-keratinizing squamous epithelium in the distal part is dependent on estrogens. Cyclical and/or senile trophic changes influence continence. The muscular wall structures and their innervation are crucial (see below):

- On the inside, smooth muscles run lengthwise and circularly. These are called the autonomous urethral sphincter (innervation: sympathetic nerve; hypogastric nerves).
- A (circular) striated layer of muscles called voluntary urethral sphincter (innervation: pudendal nerves) is located on the outside.

Clinical note: Age-related muscle loss and births (local denervation and direct tissue damage) reduce the performance of the sphincter structures.

Pelvic Floor (cf. G01B)

The pelvic floor is a highly complex structure that consists of several components located between the peritoneum and perineum. The M. levator ani is a crucial part of the pelvic floor.
As a striated muscle, it is subject to voluntary and reflexive control. It arises laterally at the pubic bone and tendinous arch and ends medially in the external sphincter muscle and is attached to a connective tissue ridge between the rectum and coccyx. The tendinous arch is a firm strand of connective tissue running from posterior to the symphysis to the iliac spine. It serves to suspend the aforementioned M. levator ani and the endopelvic fascia.

For this reason, in the distal part, near the symphysis, anatomists distinguish a tendinous arch of the pelvic fascia and a tendinous arch of the levator ani muscle. The levator ani muscle consists of four parts: M. pubococcygeus, M. puborectalis, M. iliococcygeus, and M. coccygeus.
The pelvic floor closes off the osseous pelvis caudally.

The opening limited by the levator ani is called the “urogenital hiatus”. The pelvic floor is able to compress the hollow organs that pass through it. At the beginning of micturition, the pelvic floor relaxes and the urogenital hiatus opens. After micturition, the levator ani muscle and the bladder neck resume their original position and muscle tone allows the urogenital hiatus to close again. Because of human’s upright posture, the pelvic floor is subject to constant pressure. This pressure on the pelvic floor can increase briefly through excessive stress (e.g., coughing, lifting heavy loads).

Only intact structures of the complex functional pelvic floor system can guarantee optimal function. Damage to the pelvic floor structures and M. levator ani can lead to weakening and consequently relaxation of the pelvic floor, causing a visible lowering of the perineum (“descending perineum syndrome”) with a gaping introitus seen on gynecological exam.

The term “endopelvic fascia” is a collective term for the connective tissue supporting apparatus and connective tissue bonding substance between the bladder, urethra, and M. levator ani. The cervix and vagina are secured through the endopelvic fascia to the lateral wall of the pelvis.

The endopelvic connective tissue consists of collagen, elastin, smooth muscle, vessels, and nerves. The tissue composition of the endopelvic fascia reflects the function of this tissue: On the one hand, it contains vessels and nerves to supply the organs; on the other hand, it has a support function.

Neurophysiology of Bladder Control

Various centers of different hierarchies in the central nervous system and various peripheral nerves control bladder function in a complex interaction and ensure that both smooth and striated muscles function together.
The primary reflex level with the micturition center (S2 to S5) located in the sacral spinal cord is controlled by a pontine center above it. All processes in this reflex system occur below the level of perception.

The afferent innervation of the urinary bladder consists of both the pelvic nerve (parasympathetic system) and the hypogastric nerve (sympathetic system) and somatic motor nerve fibers.

Because the fibers of the hypogastric nerve arise partially from up to the level of T10, it is understandable that in paraplegia below T10, the motor control of the urinary bladder is indeed lost, but not the sensory perception of bladder function status.

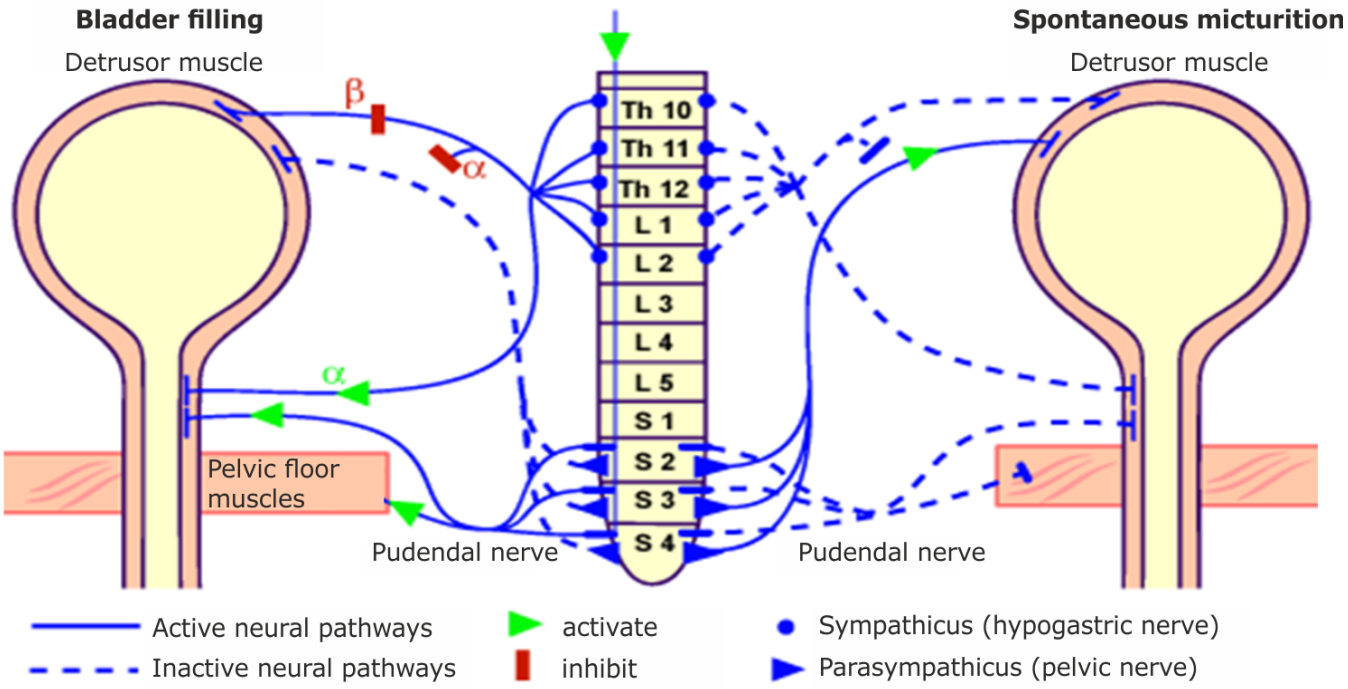

Figure 2
Bladder filling (left): During the filling phase, when the bladder wall slowly expands, an afferent stimulus occurs, which controls the sympathetically innervated bladder opening.
At the same time, the external urethral sphincter and pelvic floor muscles are stimulated via the pudendal nerve and direct motor nerves of segments S2-S5. As a result, the tone of these structures increases, ensuring closure of the urinary bladder even with increasing bladder volume (guarding reflex). Sympathetic activation of the detrusor increases simultaneously, helping communicate accommodation of the smooth muscles.
Spontaneous micturition (right): During spontaneous micturition, maximal parasympathetic innervation of the detrusor occurs, which can be measured as an intravesical pressure increase. Concomitantly, the sympathetic structures on the bladder opening are inhibited, and the striated sphincter and pelvic floor muscles relax. The latter can be measured in a decrease of pelvic floor EMG activity. This ensures that the urinary bladder can empty without any significant infravesical resistance.

Table 1

Parasympathicus (sacral spinal cord)	Contraction of detrusor muscle	Autonomous micturition behavior
Sympathicus (thoracolumbar spine)	3 effects: Directly relaxes detrusor Antagonizes parasympathicus Activates the tone of the autonomous urethral sphincter	Autonomous reservoir function

Somatic nervous system	2 effects: Modulates parasympathicus Runs as the pudendal nerve to the voluntary urethral sphincter	Cerebral control (voluntary control)

Diagram of innervation of continence and micturition control:

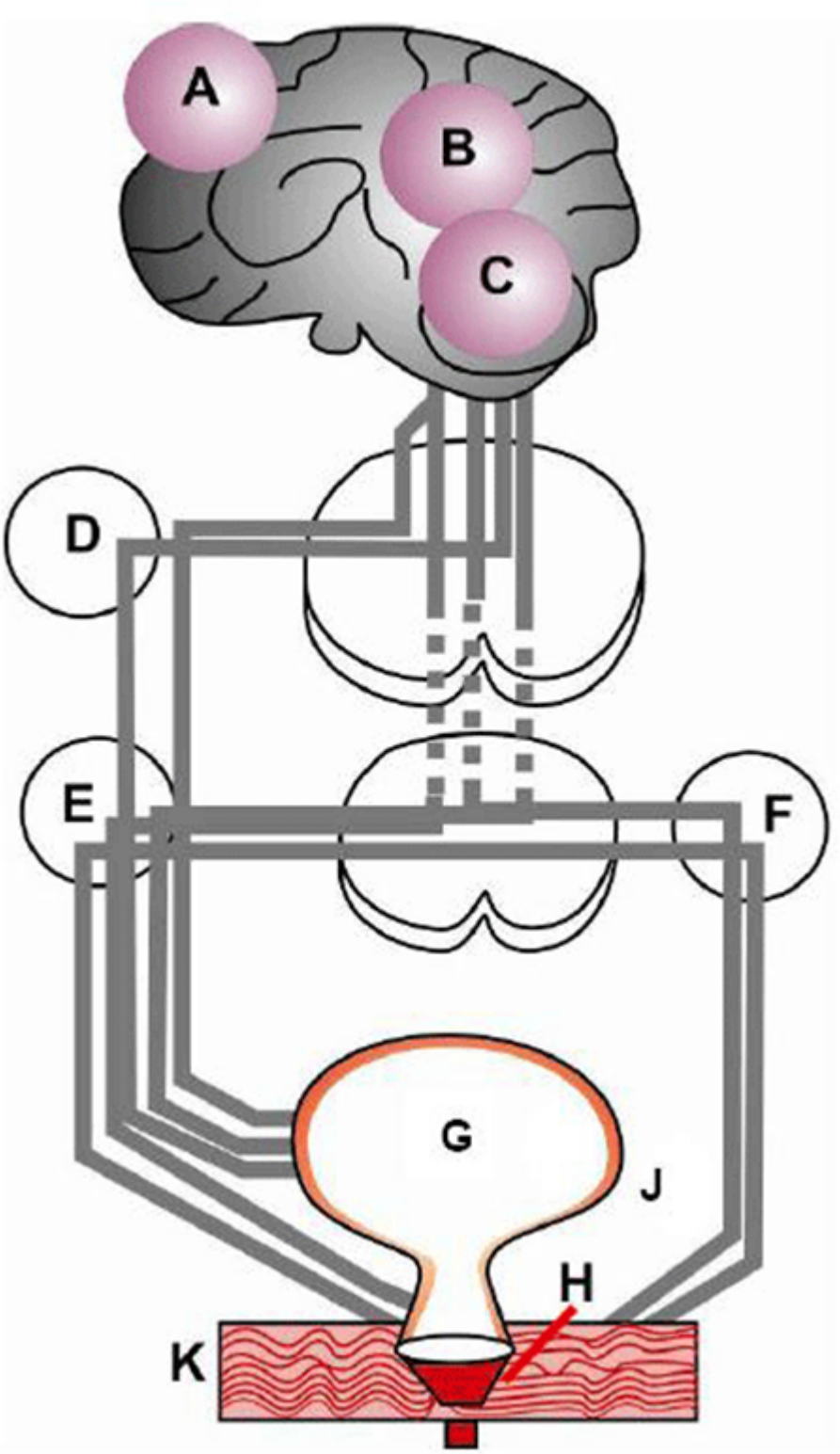

Figure 3: Diagram of innervation of continence and micturition control.

Cortical centers involved: A – Cerebrum (cortex); B – Basal ganglia; C Pons

Peripheral nerves involved, linked to spinal cord segments T10-11 or S2-4: D – Hypogastric nerve; E – Pelvic nerve; F – Pudendal nerve (autonomic efferents, autonomic afferents); G – Bladder; H – Urethral sphincter; J – Smooth detrusor muscles; K – Pelvic floor

- Cerebrum: Perception of bladder filling. Voluntary inhibition or activation of micturition.
- Basal ganglia: Unconscious inhibition of the parasympathetic micturition center.
- Pons: The pontine micturition and storage center is controlled by the cerebrum, so it can be controlled voluntarily.
- Hypogastric nerves: These nerves transmit sympathetic impulses from segments T10 to L2 to the bladder and pelvic floor and to the parasympathetic ganglia of the pelvic nerves. Alpha-adrenergic impulses stimulate contraction in the sphincter area (reservoir function). Beta-adrenergic impulses decrease detrusor muscle tone (reservoir function).
- Pudendal nerves: These nerves transmit cerebral impulses to the external urethral sphincter (and pelvic floor), leading to voluntary contraction (which to some extent can be conditioned by training).
- Pelvic nerves: The parasympathetic (cholinergic) impulses from the sacral micturition center (segments S2-S4) activate the tone of the smooth detrusor muscles.
- Urothelium: Recent studies show that the bladder wall itself plays a crucial role in filling and micturition.
  [P05]

- Pons: This also explains why after a lesion in the cortical area (e.g., stroke), patients can no longer intervene in reflex activities and thus lose cortical control of bladder function. For example, in response to the urge to urinate, patients are no longer able to delay micturition until they reach the toilet. In contrast, in lesions below the pontine centers and above the sacral micturition center, not only is there a loss of voluntary control but fine control of urine storage and micturition are also lost.
- Urothel: There is now enough evidence to show that in the bladder wall between smooth musculature, urothelium and afferent nerve endings together with various neurotransmitter substances there is an intensive information network for the central nervous system, which may at least better explain the

phenomenon of bladder wall compliance than the known reflex arcs alone.
[P05]

Bibliography

Nr.	Title	Author	Journal	Volume	Pages	Year
[B01]	Functional anatomy of the female pelvic floor	Ashton-Miller JA, DeLancey JO	Ann N Y Acad Sci	Apr;1101	266-296	2007

Nr.	Title	Author	Journal	Volume	Pages	Ye
[P01]	Pelvic floor anatomy and applied physiology	Raizada V, Mittal RK	Gastroenterol Clin North Am	Sep;37(3)	493-509	20
[P02]	Urinary bladder contraction and relaxation: physiology and pathophysiology	Andersson KE, Arner A	Physiol Rev	84	935-986	20
[P03]	Stress urinary incontinence: relative importance of urethral support and urethral closure pressure	DeLancey JO, Trowbridge ER, Miller JM, Morgan DM, Guire K, Fenner DE, Weadock WJ, Ashton-Miller JA	J Urol	Jun;179(6)	2286-2290	20

Nr.	Title	Author	Journal	Volume	Pages	Ye
[P04]	A decade of functional brain imaging applied to bladder control	Fowler CJ, Griffiths DJ	Neurourol Urodyn	29(1)	49-55	20
[P05]	Urothelial signaling	Birder L, Andersson KE	Physiol Rev	Apr;93(2)	653-680	20
[P06]	Anatomy of the pubovisceral muscle origin: Macroscopic and microscopic findings within the injury zone	Kim J, Betschart C, Ramanah R, Ashton-Miller JA, DeLancey JO	Neurourol Urodyn	Nov;34(8)	774-780	20