Last update: April 2024

Pelvic organ descensus and prolapse: classification

Author: Prof. Dr méd. Chahin Achtari

Médecin-chef au Service de gynécologie, Centres interdisciplinaires d'oncologie CHUV

Co-Author(s): Prof. Dr méd. Chahin Achtari, Prof. Dr. méd. Patrick Dällenbach

Authors of former script versions: G. Schär

Introduction

The internal genital organs rest on connective tissue and muscular structures that hold them in position and in place within the lesser pelvis. Downward displacement is a change in the position of the internal genitals in the craniocaudal axis, or within the sagittal or frontal planes (cf. G01A).

The vagina comprises three compartments:

- Anterior compartment: related to the urethra (distal third) and the bladder (proximal third)
- Apical compartment: comprising the cervix or vaginal apex after hysterectomy
- Posterior compartment: related to the anal canal (distal third), rectum (middle third), and rectouterine pouch (proximal part)

Prolapse always refers to the descent of a pelvic organ in relation to its normal position. Descent of the front vaginal wall is called cystocele and/or urethrocele. Descent of the uterus is called uterine prolapse, and descent of the vaginal apex (after hysterectomy) is called vaginal vault prolapse. Descent of the rear vaginal wall is called rectocele. Enterocele refers to the descent of the rectouterine pouch, whereby the small intestine descends between the posterior vaginal wall and the rectum.

A connective tissue/muscle defect of the supporting structures is responsible for the slackening of the vaginal wall, causing further descent.

The pelvic organs are naturally supported by the pelvic floor muscles and the supporting connective tissue of the endopelvic fascia (EPF), which covers the interior side of the levator ani muscle (cf. G01B).

The pelvic floor muscles form a dynamic “plate” on which the pelvic floor organs rest. The pelvic floor muscles comprise the puboviscerralis muscle, which forms a U-shaped sling around the rectum, bladder and urethra, as well as the pubococcygeus and posteriorly the iliococcygeus muscles (cf. G01B).

The pelvic organs are also anchored to the lateral pelvic wall by the EPF. The EPF is a layer of connective tissue that stretches across the lesser pelvis while incorporating a section of the anterior vaginal wall. The EPF also contains a network of nerves and blood vessels that supply the pelvic organs. The anterior section of the EPF is also called the pubocervical (Halban’s) fascia. It supports the bladder and anchors the vagina to the lateral pelvic wall. The dorsal section is known as Denonvilliers' fascia, running from the dorsal vaginal wall to the rectum (cf. G01B).

Surgical prolapse treatment aims to strengthen these fascial structures. The cardinal and uterosacral ligaments are a condensed part of the endopelvic fascia. They attach the cervix and the cranial third of the vagina to the posterior and lateral pelvic walls. The cardinal ligaments, which stabilize the cervix and cranial vagina, are also called the parametrium and paracolpium respectively.

The levator muscles are mainly responsible for supporting the pelvic organs. They act as a sort of ‘floor’ on which the pelvic organs rest. Laterally, they are attached to the arcus tendineus levator ani, which is a connective tissue thickening found along the lateral pelvic wall. An impairment of the levator muscles, for example due to direct muscle trauma, a tear, or an innervation disorder, increases the stress on the EPF. This increasing pressure causes the EPF to decompensate to a progressive extent, becoming overstretched or ruptured, causing the vaginal wall and pelvic organs to prolapse.

A prolapse can manifest as the descent of individual organs or as a combination of several descended compartments. This is why it is paramount that the different compartments are being tested and evaluated individually.

Definition

The true extent of organ prolapse is often only seen when the patient is in upright position or when pressure manoeuvers (Valsalva) are applied.

> The suffix “-cele” is added to the name of the organ to express descensus. This can affect both the anterior vaginal wall (cystocele = bladder descent) and the posterior vaginal wall (rectocele = intestinal descent).

There are various classification systems for genital prolapse. Baden and Walker (1972) based their system on the hymen as the reference level, and classify the prolapse of the various compartments from 1 to 4.

Figure 1

- Uterine prolapse = uterine descent (midline compartment)
- Total prolapse = complete prolapse of the uterus and anterior and posterior vaginal walls

Table 1: Baden Walker classification (the halfway classification)

Grade 1	Halfway to the hymen
Grade 2	Level of the hymen/introitus
Grade 3	Halfway past the hymen
Grade 4 (total prolapse)	Whole uterus protrudes in front of the vulva (vaginal wall inside out!)

Clinical assessment of classification: as the patient applies pressure (Valsalva)! In some cases, it is necessary to assess the patient in a standing position.

A more recent classification system was suggested by a panel of specialists and introduced as the standard (POP-Q). This system measures specific points of the compartments in relation to the hymen. This classification is mainly useful for clinical trials and enables a more objective assessment of prolapse.

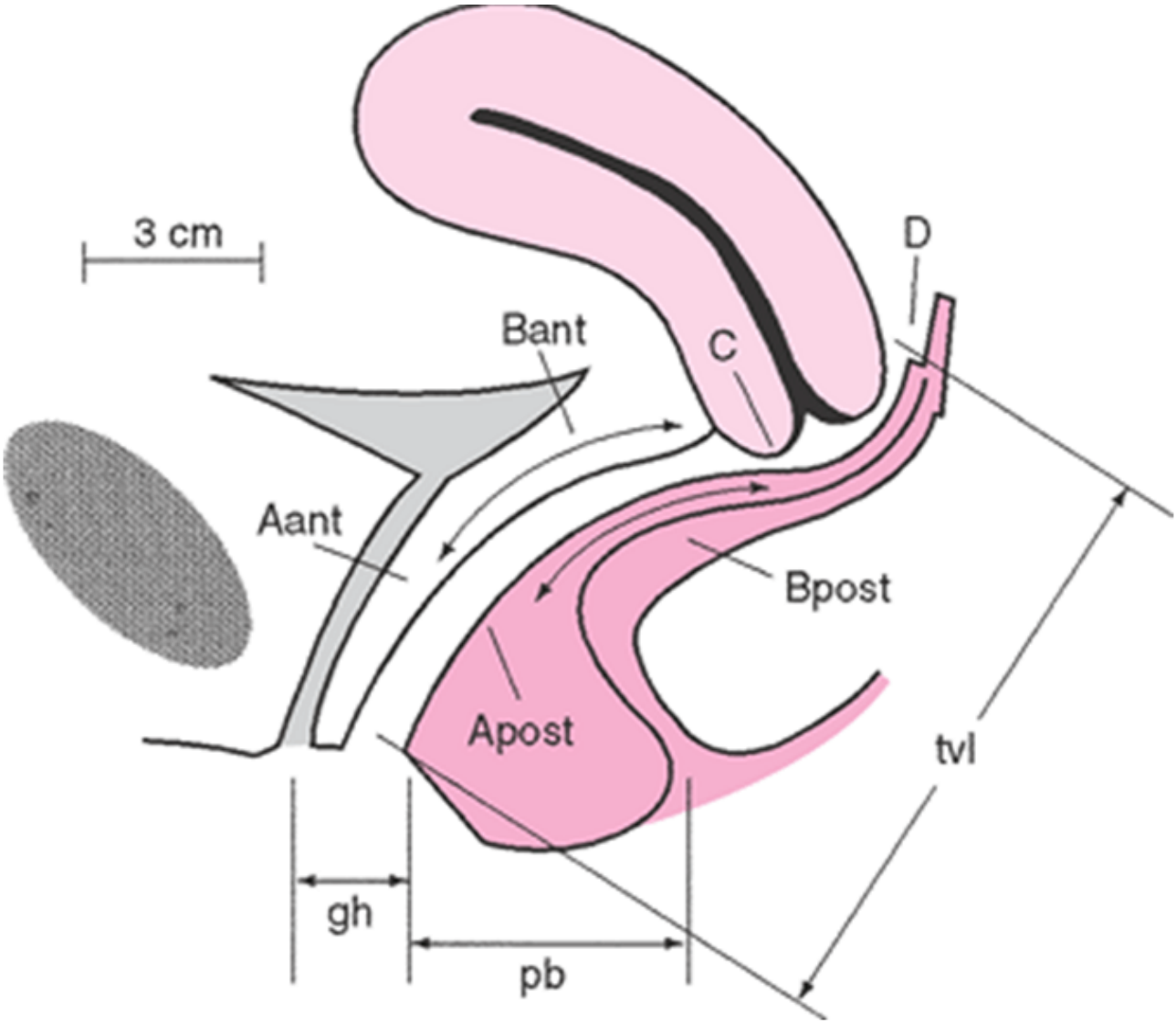

Figure 2: POP-Q classification.

With uterine descent, the neighboring structures always descend to some extent - this can cause additional symptoms and should be regarded as a pathology in itself, making treatment necessary.

Neighboring organ prolapse (-cele)

Neighboring organ prolapse is also classified (Grade I to IV):

Figure 3: Cystocele and rectocele.

Cystocele (anterior prolapse) Sections of the urinary bladder follow the downward movement of the uterus and curve the anterior vaginal wall outwards. If the urethra also descends, this is called cystourethrocele. Rectocele (posterior prolapse) Sections of the rectum follow the downward movement of the uterus and curve the posterior vaginal wall outwards. Combined findings are common.

Enterocele is the only form of pelvic organ prolapse that is a true hernia of the peritoneal cavity (originating in the rectouterine pouch), with a hernial orifice, hernia sac and hernia contents (intestinal loops!). It manifests as a posterior prolapse of the upper third of the vagina. It can sometimes be difficult to distinguish rectocele from enterocele.

Figure 4: Enterocele.

Pathophysiology

The factors and pathogenetic mechanisms that lead to downward displacement are complex and multiple, all leading to a defect in the supporting connective tissue.

1. Weakness of the supporting connective tissue (mostly constitutional).
2. Severe trauma to the pelvic floor during childbirth, as a result of traumatic vaginal delivery, due to instrumental delivery, or because of high fetal birth weight, for example.
3. In terms of prophylaxis, the pelvic floor can be protected during pregnancy with pelvic floor exercises, prepartum perineal massage (improves pelvic floor elasticity and “compliance” during delivery) and postpartum pelvic floor training. Episiotomy does not exhibit any advantages for the pelvic floor.
4. Repetitive or chronically activated abdominal pressure (heavy physical work, COPD, etc. also contribute to a vicious circle of promoting a rectocele with stool retention [strong pressure to defecate encourages further manifestations of descent]).
5. Other: Pronounced obesity. Chronic glucocorticoid treatment. Pelvic floor innervation disorders (spinal cord disorders, spina bifida occulta).
6. All these factors exert an even greater effect in the presence of postmenopausal atrophy (due to estrogen deficiency).

Imaging

Certain imaging procedures provide a better understanding of the development of prolapse. Ultrasound and MRI are the techniques most commonly employed. Urogynecological ultrasound has been established as the standard imaging procedure for evaluating pelvic organ prolapse.

Urogynecological ultrasound is carried out using an abdominal or vaginal probe placed at the vaginal introitus, and provides a sagittal cross section of the pelvic floor in the median plane. Furthermore, 3D and 4D probes can similarly be used. They capture a tissue block that can be analyzed later, enabling the pelvic floor to be shown in various planes, in particular an axial plane. This plane allows the levator muscles (puborectalis) and its lateral outline to be examined. Overdistension of the urogenital hiatus is thought to be one of the pathophysiological causes resulting in prolapse issues. In addition, an extensive lateral defect of the pubovisceralis muscle is thought to be an increased risk factor for postoperative prolapse recurrence. With urogynecological ultrasound, it is additionally possible to view the three compartments and a prolapse, thus obtaining further information for clinical diagnosis.

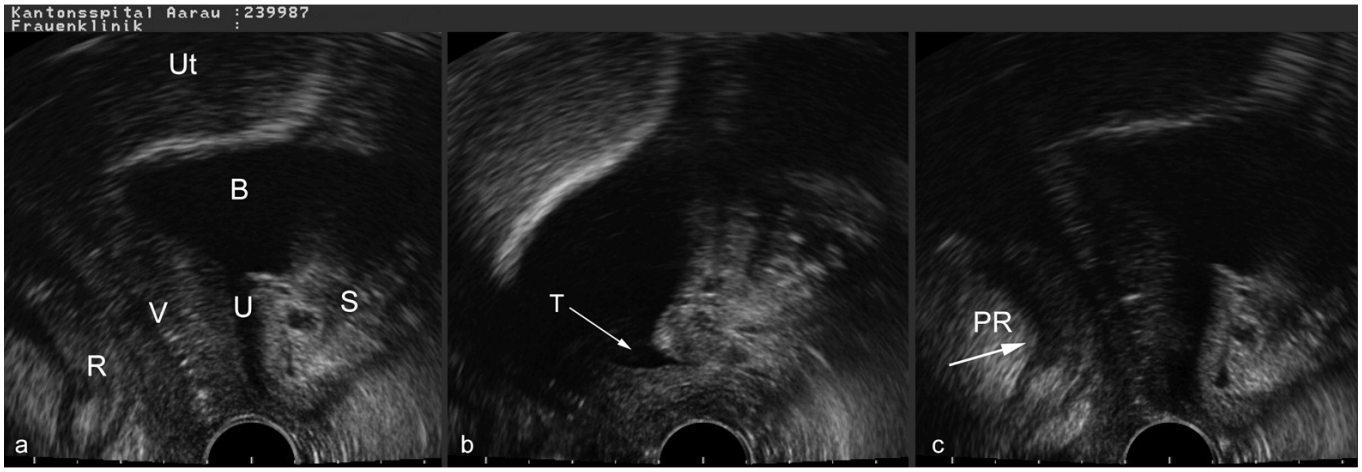

Figure 5: Urogynecological ultrasound of a woman with stress incontinence. When relaxed (a), the urethra (U) is positioned vertically. B = bladder, S = pubic symphysis, V = vagina, R = rectum, Ut = uterus. Under pressure (b), the urethra rotates and descends, opening in a funnel shape (T). Upon pelvic floor contraction (c), the contraction of the puborectalis sling (PR) causes the rectum, vagina, and urethra to lift and move into a more ventral position.

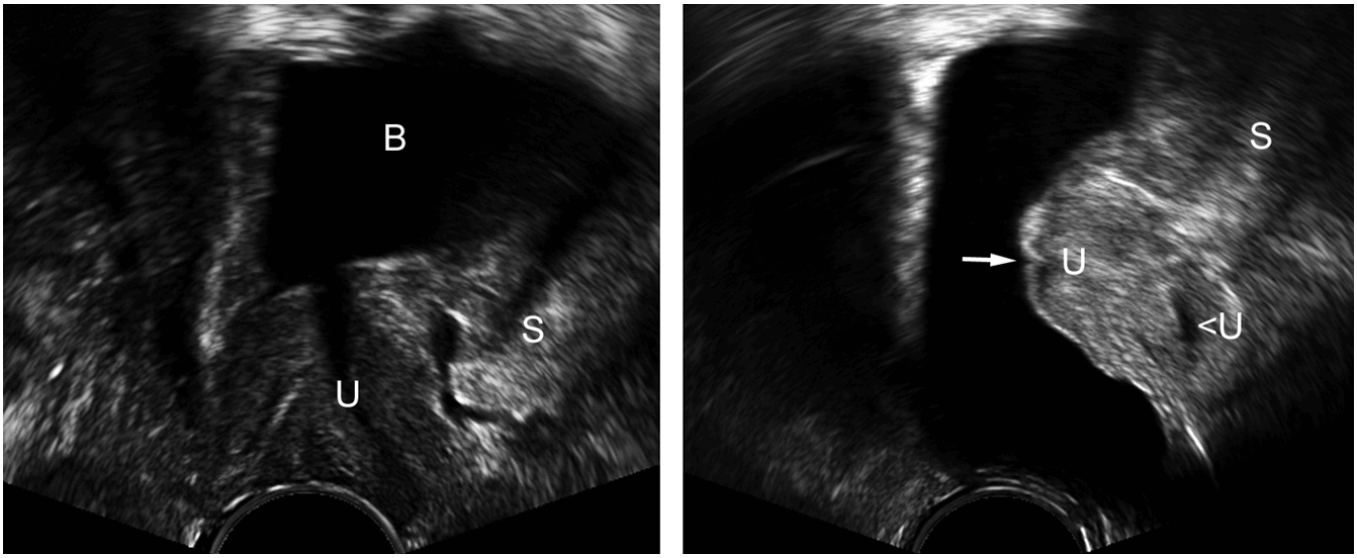

Figure 6: Perineal ultrasound of a woman with major cystocele with midline defect: When relaxed (a), vertical urethra and normal bladder floor position. Under pressure (b), the bladder floor significantly descends in a caudal direction. The external urethral orifice descends slightly (arrow) and the urethra shows a kinking in the middle section.

Pelvic MRI has been established to solve specific issues. MR defecography has become increasingly popular, given that it can provide information that potentially influences treatment, in particular surgery. Rectocele with defecation disorder alone can be corrected with colpoperineoplasty, while an intussusception detected on MRI requires additional fixation of the sigma-rectum. Intussusception is the protrusion of the intestinal wall into itself, resulting in a valve that complicates defecation.

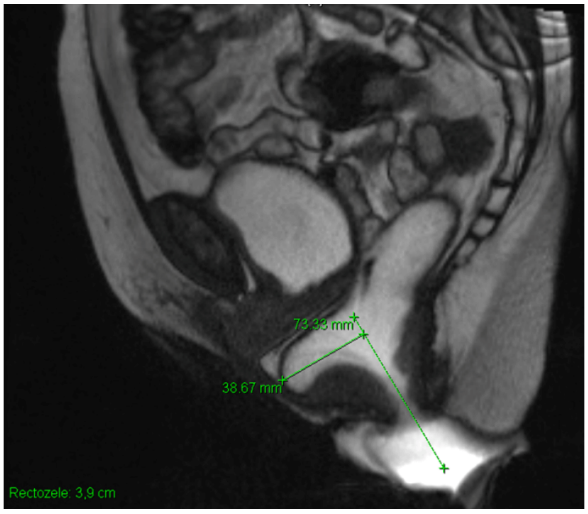

Figure 7: MRI of an anterior rectocele measuring 39mm in depth. Measured under MRI contrast gel.

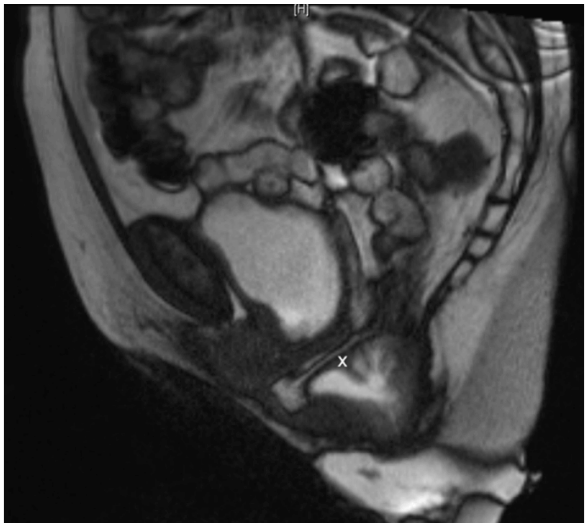

Figure 8: MRI of intussusception. X shows a folding of the intestinal wall which can cause a valve effect.

Clinical presentation

Symptoms often do not correlate with anatomical severity. They depend to a large extent on the sensitivity and basic aesthetic needs of the patient.

Anterior prolapse (cystocele)

- Urinary incontinence
- Voiding disorders (including urinary retention)
- Recurrent urinary tract infection
- Urodynamics can help distinguish the underlying issue. Major cystocele can mask urinary incontinence due to urethral kinking. Testing should therefore include a cough test with reduced prolapse.

Anterior prolapse (cystocele)

- Urinary incontinence
- Voiding disorders (including urinary retention)
- Recurrent urinary tract infection
- Urodynamics can help distinguish the underlying issue. Major cystocele can mask urinary incontinence due to urethral kinking. Testing should therefore include a cough test with reduced prolapse.

Posterior prolapse (rectocele)

- This can be accompanied by a bowel voiding disorder or fecal incontinence.
- Reducing the rectocele when defecating can help women to empty the bowels without complication (digital evacuation).

Particularly in postmenopausal women affected by estrogen deficiency, prolapse is often accompanied by epithelial damage. Mechanical irritation leads to erosion or ulceration of the external cervix and atrophied vaginal wall. Superinfections of this epithelial damage are possible and cause symptoms that must be treated, particularly prior to surgery, through vaginal application of estrogen. Estriol cream may be applied vaginally once or twice per week in the evening. The creams are supplied with an acrylic tube. This is filled with the cream and inserted vaginally. The stamp is then pressed to introduce the correct dose of the cream into the vagina.

Complications

Erosion and ulceration of the vaginal wall or cervix occur due to:

- Estrogen deficiency, resulting from a pessary, mechanical irritation from underwear, or incontinence pads.
- Rectocele with voiding disorder: the chronic pressure can lead to the formation of hemorrhoids.

Diagnosis

A gynecological speculum examination under strain and coughs shows the extent and type of descent.

Cystocele is identified by a bulging of the anterior vaginal wall, particularly during speculum examination when coughing or straining or on bimanual palpation.

Rectocele is considered when the posterior vaginal wall bulges outwards (speculum examination).

Rectal palpation (see below) is employed to distinguish between enterocele and rectocele.

Imaging diagnostics supplement the clinical examination with additional information, such as urethral hypermobility, presence of enterocele, and extent of cystocele and rectocele.

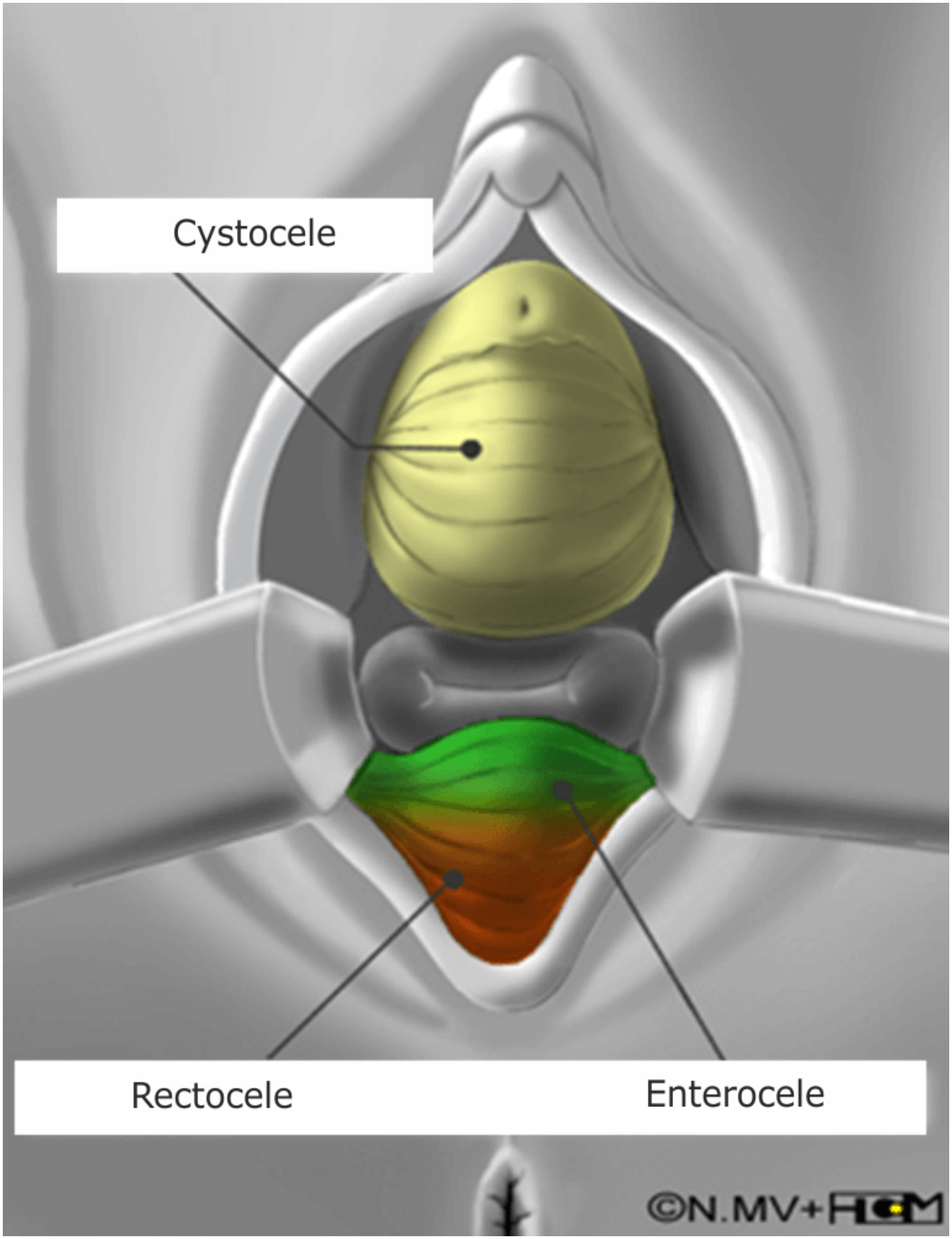

Figure 9: Prolapse of the anterior and posterior vaginal wall.

Differential diagnosis

Rectal palpation for distinguishing between rectocele and enterocele:

- Rectocele (a gap in the connective tissue of the anterior rectal wall) can be palpated during a rectal examination.
- Enterocele can be well determined on ultrasound, as it is difficult to palpate.
- The simultaneous occurrence of recto-enterocele is possible.

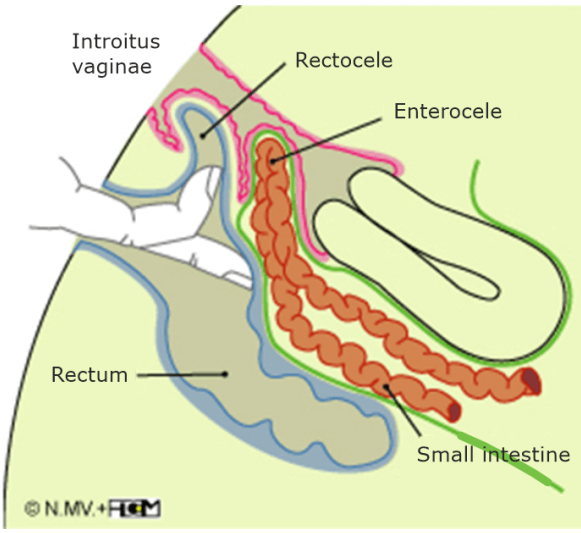

Figure 10: Rectal examination to distinguish between rectocele and enterocele.

Literature

Nr.	Title	Author	Journal	Volume	Pages	Year
[B01]	sis of the vaginal profile: a correlated classification of vaginal relaxation	Baden WF, Walker TA	Clin Obstet Gynecol	15(4)	1048-1054	1972
[B02]	Anatomic aspects of vaginal eversion after hysterectomy	DeLancey JO	Am J Obstet Gynecol	166(6 Pt 1)	1717-1724	1992
[B03]	RI diagnosis of pelvic organ prolapse compared with clinical examination	Pannu HK, Scatarige JC, Eng J	Acad Radiol	18(10)	1245-1251	2011
[B04]	Correlation of symptoms with degree of pelvic organ support in a general population of women: what is pelvic organ prolapse?	Swift SE, Tate SB, Nicholas J	Am J Obstet Gynecol	189(2)	372-377	2003
[B05]	Pathophysiology of pelvic organ prolapse	Word RA, Pathi S, Schaffer JI	Gynecol Clin North Am	36(3)	521-539	2009

Nr.	Title	Author	Journal	Volume	Pages	Y

Nr.	Title	Author	Journal	Volume	Pages	Y
[P01]	Der Beckenboden während Schwangerschaft und nach der Geburt: Empfehlungen des AUG Vorstandes	Expertenbrief Nr. 29 der gynécologie suisse				2
[P02]	Levator trauma is associated with pelvic organ prolapse	Dietz H, Simpson J	BJOG	115	979–984	2
[P03]	The standardization of terminology of female pelvic organ prolapse and pelvic floor dysfunction	Bump RC, Mattiasson A, Bø K, Brubaker LP, DeLancey JO, Klarskov P, Shull BL, Smith AR	Am J Obstet Gynecol	175(1)	10-17	1
[P04]	Remodeling of vaginal connective tissue in patients with prolapse	Alperin M, Moalli PA	Curr Opin Obstet Gynecol	18(5)	544-550	2
[P05]	Pelvic floor ultrasound in prolapse: what's in it for the surgeon?	Dietz HP	International urogynecology journal	22(10)	1221-1232	2
[P06]	Segmentations of MRI images of the female pelvic floor: a study of inter- and intra-reader reliability	Hoyte L et al.	J Magn Reson Imaging	33(3)	684-691	2

Nr.	Title	Author	Journal	Volume	Pages	Y
[P07]	Magnetic resonance imaging-based three-dimensional model of anterior vaginal wall position at rest and maximal strain in women with and without prolapse	Larson KA, Hsu Y, Chen L, Ashton-Miller JA, DeLancey JO et al.	International urogynecology journal	21(9)	1103-1109	2