Last update: April 2024

Pelvic organ descensus and prolapse: treatment

Author: Prof. Dr méd. Chahin Achtari

Médecin-chef au Service de gynécologie, Centres interdisciplinaires d'oncologie CHUV

Co-Author(s): Prof. Dr méd. Chahin Achtari, Prof. Dr. méd. Patrick Dällenbach

Authors of former script versions: G. Schär

Introduction

The aim of prolapse surgery is to restore anatomy and remedy pelvic organ descensus symptoms while maintaining the function of the vagina and neighboring organs.

Conditions for correct treatment:

- The goals and wishes of the patient are known. What does she expect from the treatment?
- The anatomy of the defect is known and the symptoms and functional impairment can be put in the correct context.
- The patient's expectations and treatment options are compatible (excessive expectations).
- The patient has been informed of sequelae and side effects of treatment.
- Patient consent.

Individual treatment options

Vaginal estrogen treatment

Localized estrogen treatment with vaginal estriol cream or vaginal pessaries can have a positive effect on the symptoms of pelvic organ prolapse. The stretched and displaced vaginal skin becomes less dry and thus causes less pruritis. Any dysuria is improved or even disappears. The skin is stronger and more resistant to pressure preventing the consequences of erosion and hemorrhage. For pessary treatment or displacement surgery, well estrogenized vaginal skin is beneficial.

Pessary treatment

Previously, long-term pessaries in form of a dish or ring pessary were inserted to treat patients who could not or declined to be operated on. Today, this application is only appropriate in very rare situations. Vaginal infections with pressure ulcers may occur over time. Medical progress means that even elderly and multimorbid patients can now be operated on satisfactorily.

Pessaries for self-administration



Figure 1: Cube pessary for self-administration.

If the patient prefers conservative treatment, she will be informed of pessary treatment with a cube pessary, and the pessary will be adjusted and given to her to take home. The figure 1 shows a silicone cube pessary. The patient inserts the pessary with estrogen cream daily, or for specific stress situations such as exercise, and removes it by pulling on the threads. In active, healthy patients with good life expectancy, pessary treatment is generally not a long-term treatment.

Surgery

Conditions for successful pelvic organ prolapse surgery:

- Holistic preoperative planning.
- Surgical procedure based on the specific defect.

Recurrence and complications cannot be avoided, but can be reduced.

Indication

The patient is impaired by the pelvic organ prolapse and has a reduced quality of life due to limitations in everyday routine or the aforementioned functional impairments. Medical secondary problems as a result of the pelvic organ prolapse are an urgent indication for surgical intervention. These include chronic recurrent urinary tract infections with residual urine and above all pronounced symptoms such as renal congestion and pyelonephritis. Pressure ulcers are practically impossible to remedy without correcting the descensus.

There are vaginal, abdominal and laparoscopic interventions that are described for correcting prolapse.

Vaginal surgical procedures are less invasive than abdominal procedures. Laparoscopic operations provide lower peri- and postoperative morbidity, but entail higher intraoperative cardiopulmonary stress. For patients in reduced general condition, vaginal operations are therefore recommended. Abdominal procedures such as sacrocolpopexy are associated with lower rates of recurrence than vaginal procedures.

Surgical concept

Requirements in terms of quality of life and function, anatomical defects and life expectancy must be included when deciding on surgery. Table 1 shows the surgical concept for prolapse.

An apical prolapse of the uterus or vaginal cuff requires an apical fixation, by means of either vaginal sacrospinal fixation or abdominal sacrocolpopexy. Cystocele with a midline defect can be treated with diaphragmplasty (anterior repair), while cystocele with a paravaginal defect requires lateral anchoring (lateral repair). Rectocele can be corrected with colpoperineoplasty. Vaginal mesh should be used with caution.

Mesh has a lower rate of recurrence but higher rate of complications, particularly with regard to healing disorders with erosion of the mesh and corresponding symptoms such as vaginal bleeding, infection, spontaneous pain and dyspareunia. The use of vaginal mesh is recommended above all in recurrent cases. Sacrocolpopexy always requires the placement of a mesh to bridge the distance from the sacrum to the vagina.

Table 1: Surgical concept based on anatomical defect and quality of life requirements

Apical prolapse	Apical prolapse	Cystocele	Cystocele	Rectocele
* Long life expectancy * High physical activity * Sexual activity * Recurrence status * Short vagina	* Advanced age * Low physical activity * No sexual activity * Primary case * Sufficient vaginal length	* Midline defect in primary case	* Paravaginal defect and/or recurrence	* Primary or relapsed rectoc
* Abd. operation laparaoscopic or abdominal sacropexy	* Vag. operation sacrospinal fixation + poss. colpoperineoplasty + poss. diaphragmplasty	* Diaphragmplasty	* lateral vaginal suspension anchoring	* Colpoperineopla

Risk constellations such as a very large prolapse, chronic bronchitis, overweight, constipation and high physical stress through work or exercise make it necessary to carry out an intervention with the lowest possible rate of recurrence. This applies to sacrocolpopexy with mesh insertion. In 2011, a warning published by the FDA (US Food and Drug Administration) concerning the use of vaginal mesh alarmed the urogynecological world. Worries relating to the side effects and complications of vaginal mesh implants have led to more critical scrutiny of the indication of vaginal mesh.

For legal reasons, USA-based companies in particular have removed vaginal meshes from the market as a result. Mesh implants require a strong indication. Not every cystocele or rectocele requires a vaginal mesh. Table 1 above shows the evidence-based indications for mesh, including after the FDA's warning and results of various recently published, well-conducted, randomized trials.

The value of hysterectomy for treating prolapse does not outweigh the practical aspects.

If there is no uterine pathology, uterus-preserving techniques are a valuable option. If an apical fixation of a uterine prolapse must be carried out, either a hysteropexy with fixation of the cervix to the sacrospinal ligament or a hysterectomy with fixation of the vaginal apex to the sacrospinal ligament can be carried out (Richter's procedure).

Uterine or vaginal cuff prolapse surgery

The hysterectomy is carried out to provide access to the vaginal apex and thus improves the implementation of the suspension. With vaginal correction, a vaginal hysterectomy, with sacrocolpopexy a subtotal hysterectomy, leaving the cervix in place, is carried out. The cervix is left in place in order to avoid the opening of the vagina. This is crucial as the placement of a mesh to the cervix and vagina is one of the important fixation steps to perform a sacrocolpopexy, while the risk of wound healing disorders and mesh exposition to the vagina is lower if the vagina is not opened.

Sacrocolpopexy (abdominal, laparoscopic, robotic)

Apical prolapse can be remedied with sacrocolpopexy in 85 to 90 % of cases. In addition, this technique displays a lower rate of dyspareunia than vaginal interventions. Considering that sacrocolpopexy exhibits the best success rates with low complication rates, it was defined as the gold standard by Maher in a Cochrane Review [B01].

Alternatively to sacrocolpopexy, other techniques have emerged avoiding dissection of the sacral promontory. The lateral suspension and the pectopexy are two recent techniques involving mesh placement to suspend the apical compartment. In the lateral suspension operation the mesh is inserted through the abdominal wall and attached to the uterine isthmus or vaginal cuff. In the pectopexy technique the mesh is attached to the pectineal (Cooper's) ligament. [B01]

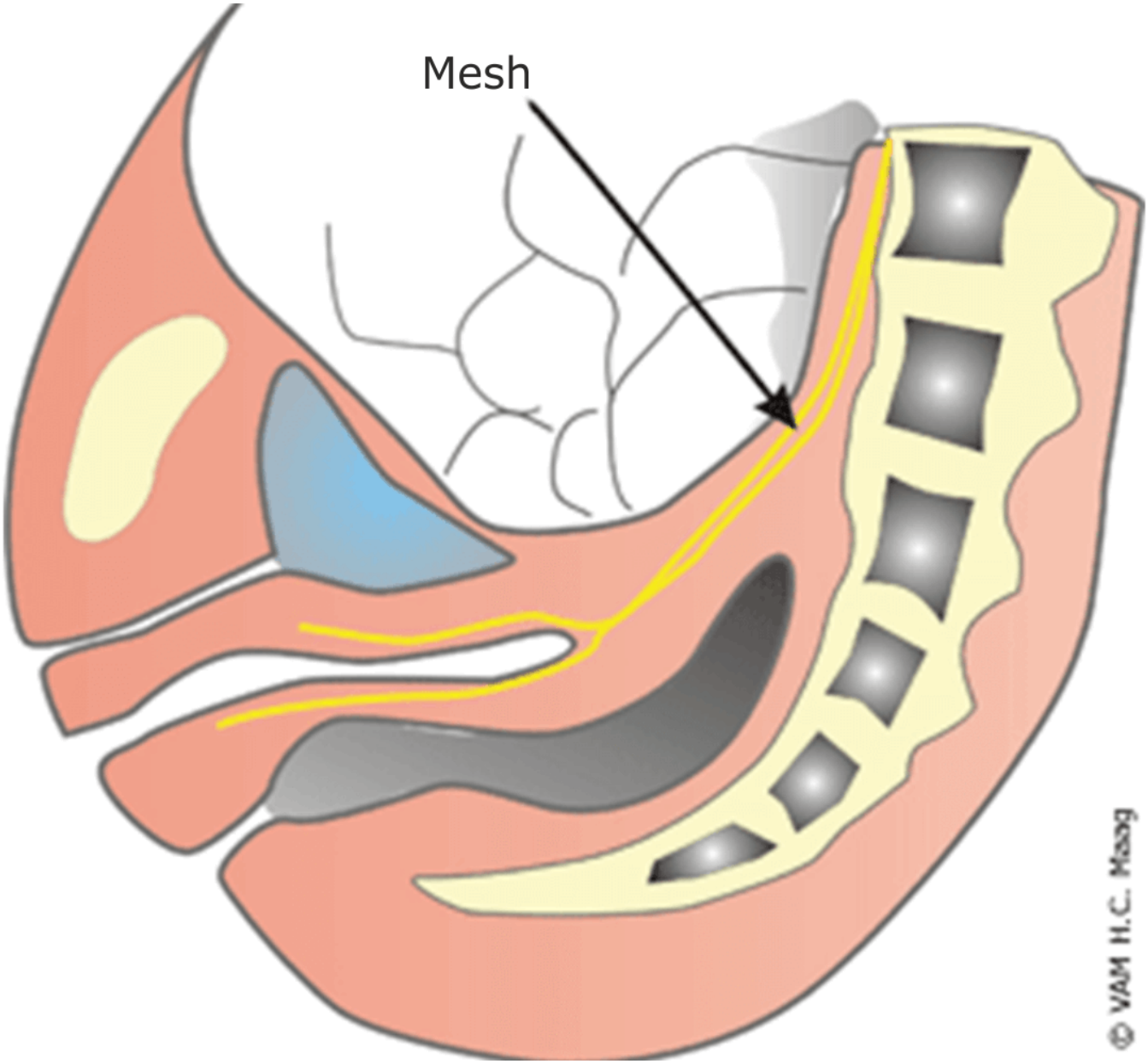

Figure 2: With sacrocolpopexy, the vagina is anchored to the sacrum with a y-shaped mesh, which is sutured in place along the ventral and dorsal vagina.

Vaginal sacrospinal fixation (Amreich-Richter)

The most prevalent technique for vaginal fixation of the vaginal apex is sacrospinal fixation using the Amreich-Richter technique. This can only be carried out if the vagina is long enough to be able to fix the apex of the vagina to the sacrospinal ligament. If this is not the case, abdominal sacrocolpopexy remains a possibility.

In case of vaginal apex or uterine prolapse, the vaginal apex is adapted to the sacrospinal ligament. Care must be taken, however, as nerves and vessels (pudendal blood vessels) run closely behind the ligament.

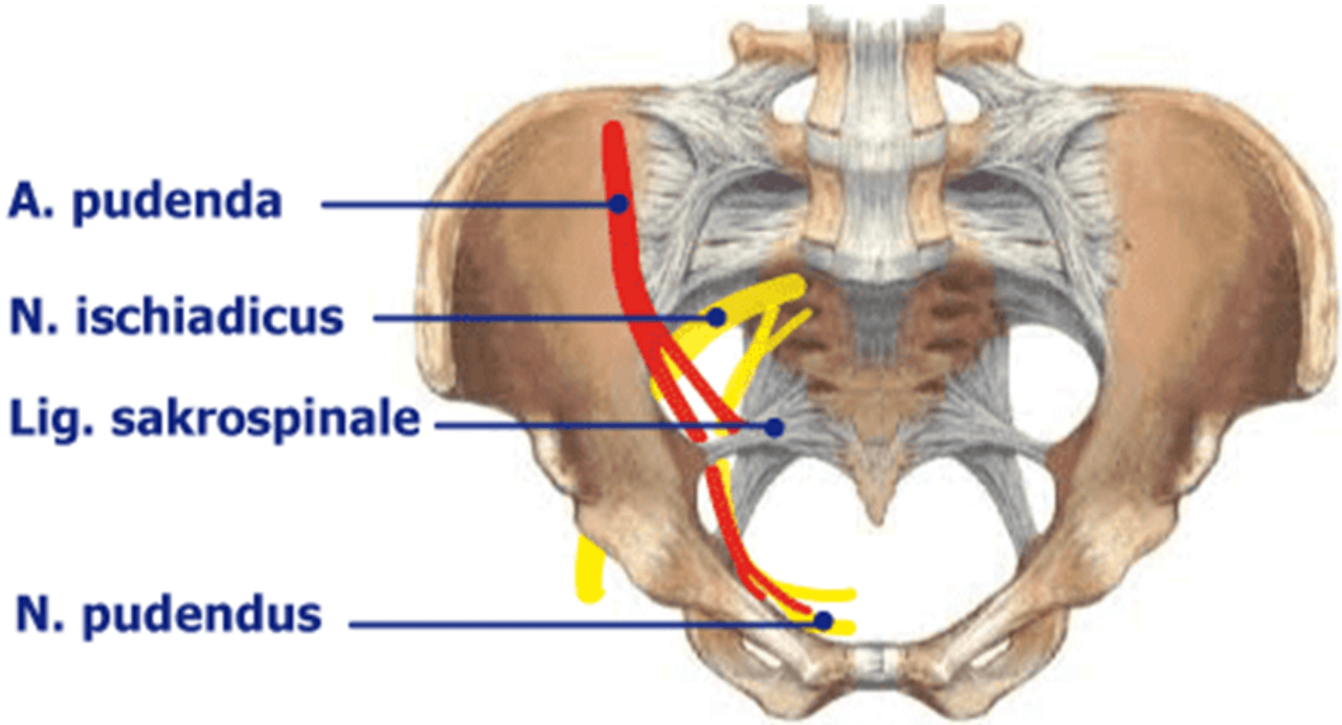

Figure 3

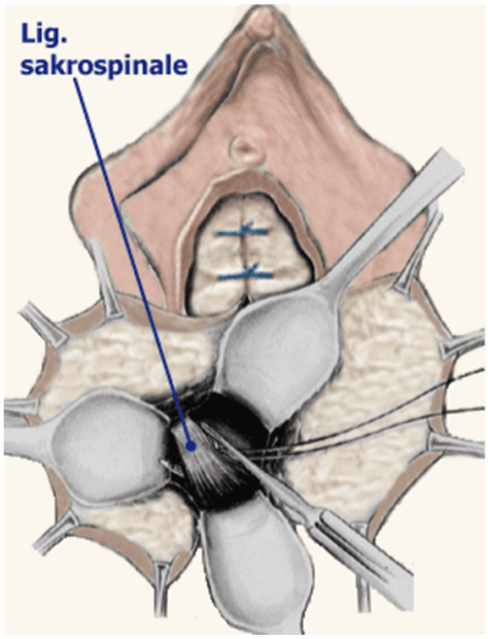

Figure 4: Vaginal sacrospinal fixation (Amreich-Richter).

Cystocele

Diaphragmplasty (anterior fascia repair) is indicated for a midline defect of the endopelvic fascia.

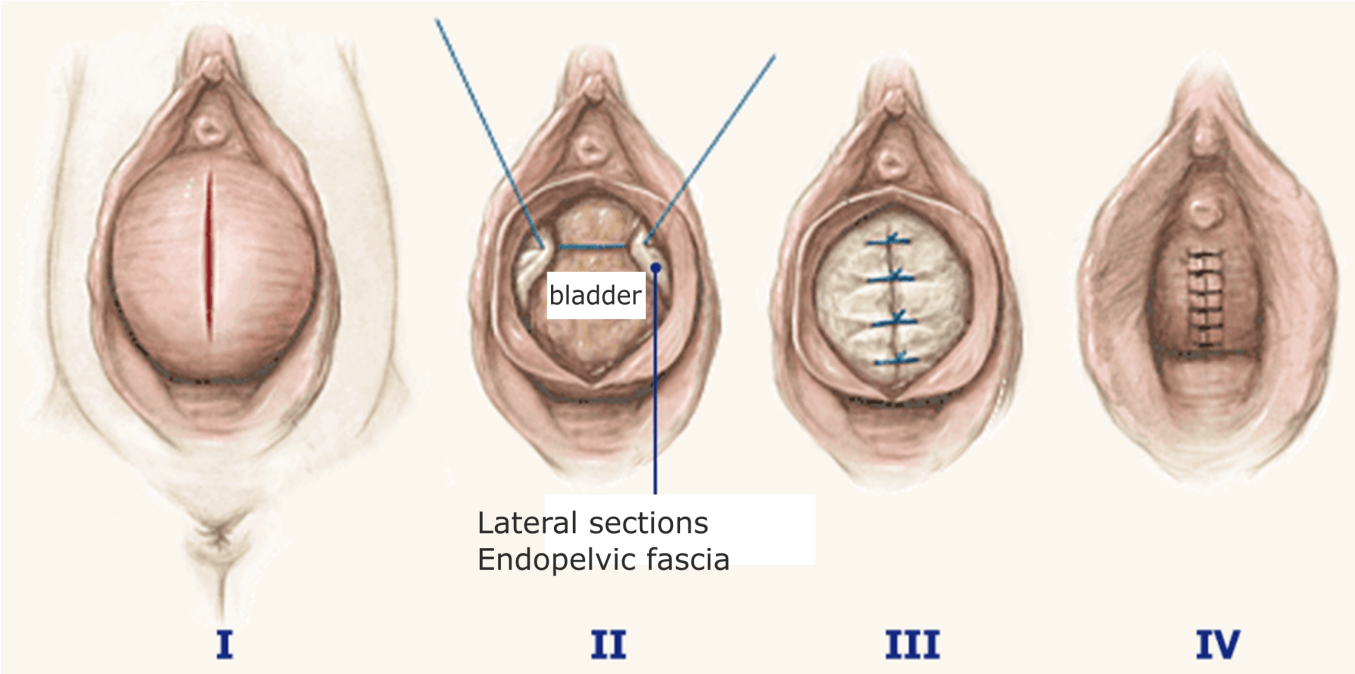

Figure 5: The vaginal skin is opened in the midline and dissected from the endopelvic fascia located under the bladder (I). Stitches are placed in the lateral sections of the endopelvic fascia (II) with resorbable or late-resorbable threads and knotted in the midline (III). The bladder is elevated cranially and supported by a reinforced layer of connective tissue. The vaginal skin in closed again (IV).

If a cystocele with a paravaginal defect (tear on the side of the endopelvic fascia) is present, a lateral fixation of the fascia is required.

Rectocele

Rectocele is corrected with colpoperineoplasty (posterior fascia repair). To this end, the perirectal fascia is brought together in the midline and employed for stabilizing the preractal fascia against the vagina.

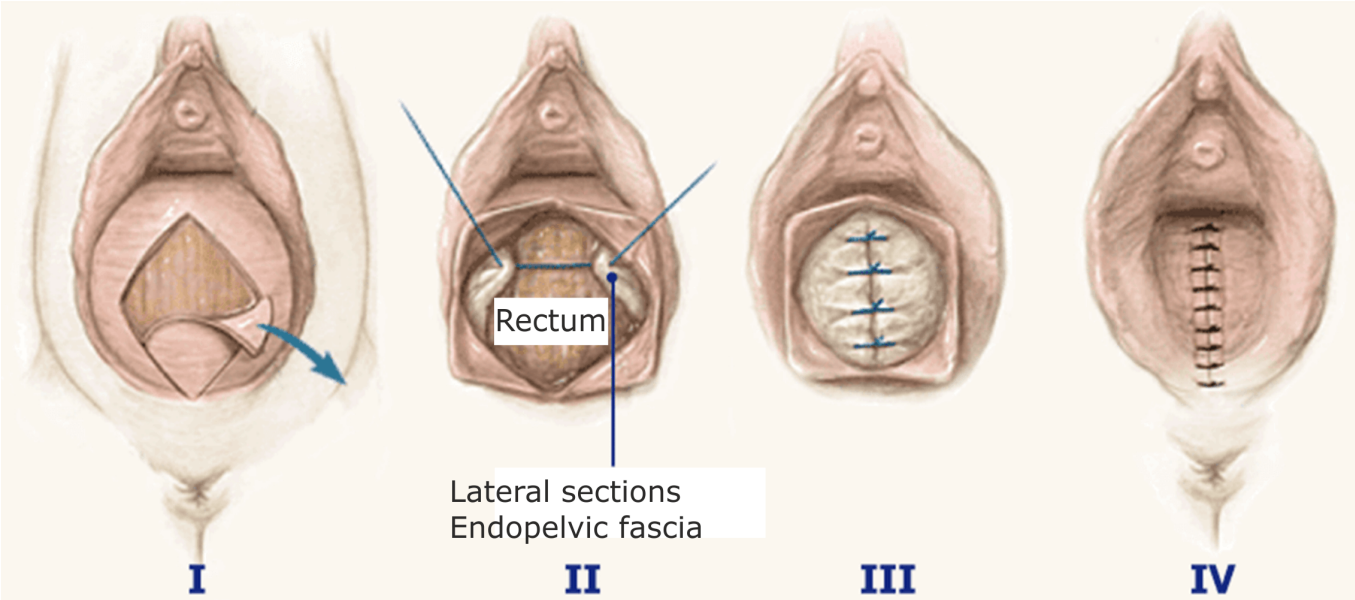

Figure 7: Colpoperineoplasty.
I: The vaginal skin is incised at the midline and dissected from the endopelvic fascia located under the rectum. II: The perirectal fasciae are brought together with resorbable sutures, with placing the stitches laterally and knotted in the midline (III), so that the rectum is covered and stabilized by the reinforced prerectal fascia. IV: The perineum is also brought together with a single suture in the midline in order to close a widened genital hiatus.

While diaphragmaplasty (anterior repair) is associated with a high rate of recurrence, attention has to be paid to the rectocele correction. Dyspareunia, in particular, must be mentioned. The rate of dyspareunia appears to be directly connected to the chosen method of surgery. Numerous authors accuse in particular the midline fusion of the levator ani muscle performed during levatorplasty of being a cause of dyspareunia. The rate of recurrence of posterior repair with aligning the fascia in the midline is low (between 7 and 12 %).

Postoperative incontinence

About 25 % of patients likely develop stress urinary incontinence following prolapse surgery (occult stress incontinence). A preoperative cough test with prolapse reposition helps to evaluate the risk and advise the patient accordingly. If occult stress urinary incontinence is diagnosed, a continence operation can be carried out during the prolapse surgery (e.g., tension-free sling).

A wait-and-see approach may likewise be taken. To this end, the patient must be carefully informed and prepared for the fact that stress urinary incontinence can occur secondarily, namely in cases where no concomitant sling surgery is performed. Though, occult urinary incontinence is not becoming overt in all cases after POP surgery, so a two-step procedure is also advisable in order to prevent unnecessary incontinence interventions.

Vaginal mesh implantation

The fact that cystocele recurrence occurs in approx. 30 to 50 % of vaginal prolapse operations has not only led to operative modification of vaginal surgeries, but also to the search for ways to strengthen the tissue in order to lower the rate of recurrence [P03, P04].

This has provoked a significant increase in interest in mesh applications. Mesh provides lower anatomic recurrence rates but higher complication rates with defective healing, mesh shrinkage, infection, dyspareunia, and organ damage. Studies have shown that subjective results of fascia operations are as good as operations with vaginal mesh insertion. Therefore use of mesh is not only potentially damageable for the patient but brings no subjective advantage. Use of vaginal mesh has been progressively abandoned and even banned in many countries. [P03][P02]

Literature

Nr.	Title	Author	Journal	Volume	Pages	Year
[B01]	Laparoscopic sacral colpopexy versus total vaginal mesh for vaginal vault prolapse: a randomized trial	Maher CF, Feiner B, DeCuyper EM, Nichlos CJ, Hickey KV, O'Rourke P	Am J Obstet Gynecol	204(4)	360 e1-7	2011
[B02]	Uterine preservation vs hysterectomy in pelvic organ prolapse surgery: a systematic review with meta-analysis and clinical practice guidelines	Meriwether KV, Antosh DD, Olivera CK, Kim-Fine S, Balk EM, Murphy M, Grimes C L, Sleemi A, Singh R, Dieter AA, Crisp CC, Rahn DD	American journal of obstetrics and gynecology	219(2)	129–146.e2	2018

Nr.	Title	Author	Journal	Volume	Pages	Y
[P01]	Should we use meshes in the management of vaginal prolapse?	De Ridder D	Curr Opin Urol	18	377-382	2

Nr.	Title	Author	Journal	Volume	Pages	Y
[P02]	Anterior colporrhaphy: a randomized trial of three surgical techniques	Weber AM, Walters MD, Piedmonte MR, Ballard LA	Am J Obstet Gynecol	185	1299-1304	2
[P03]	Risk factors for exposure, pain and dyspareunia after tension-free vaginal mesh procedure	Withagen MI, Vierhout ME, Hendriks JC, KB Kluivers, Milani AL	Obstet Gynecol	118	629-632	2
[P04]	Patient preferences for uterine preservation and hysterectomy in women with pelvic organ prolapse	Korbly N.B, Kassis N.C, Good M.M, Richardson M.L, Book N.M, Yip S, Saguan D, Gross C, Evans J, Lopes V.V, Harvie H.S, Sung V.W.	American journal of obstetrics and gynecology	209(5)	470.e1–470.e4706	2

Nr.	Title	Author	Journal	Volume	Pages	Y
[P05]	Summary: 2017 International Consultation on Incontinence Evidence-Based Surgical Pathway for Pelvic Organ Prolapse	Maher C.F, Baessler K.K, Barber M.D, Cheon C, Consten E.C.J, Cooper K.G, Deffieux X, Dietz V, Gutman R.E, van Iersel J.J, Nager C.W, Sung V.W, de Tayrac R	Female pelvic medicine & reconstructive surgery	26(1)	30–36	2
[P06]	Posterior Vaginal Compartment Anatomy: Implications for Surgical Repair	Maldonado P.A, Carrick K.S, Montoya T.I, Corton M.M	Female pelvic medicine & reconstructive surgery	26(12)	751–757	2
[P07]	Pelvic organ prolapse surgery with and without tension-free vaginal tape in women with occult or asymptomatic urodynamic stress incontinence: a randomised controlled trial	Schierlitz L, Dwyer P.L, Rosamilia A, De Souza A, Murray C, Thomas E, Hiscock R, Achtari C	International urogynecology journal	25(1)	33–40	2

Nr.	Title	Author	Journal	Volume	Pages	Y
[P08]	Laparoscopic Lateral Suspension (LLS) for the Treatment of Apical Prolapse: A New Gold Standard?	Dällenbach P	Frontiers in surgery	9	898392	2
[P09]	Surgery for women with anterior compartment prolapse	Maher C, Feiner B, Baessler K, Christmann-Schmid C, Haya N, Brown J	Cochrane Database of Systematic Reviews	Issue 11. Art. No.: CD004014		2
[P10]	Surgery for women with apical vaginal prolapse	Maher C, Yeung E, Haya N, Christmann-Schmid C, Mowat A, Chen Z, Baessler K.	Cochrane Database of Systematic Reviews	Issue 7. Art. No.: CD012376		2
[P11]	Surgery for women with posterior compartment prolapse	Mowat A, Maher D, Baessler K, Christmann-Schmid C, Haya N, Maher C	Cochrane Database of Systematic Reviews	Issue 3. Art. No.: CD012975		2