Neuroanatomy — Gross Brain

🧠 Neuroanatomy — Gross Brain

> *The cerebral cortex is the most superficial layer of the cerebrum. It and the underlying white matter accounts for the largest part of the human brain. — Radiopaedia*

🎯 Core Concept

The brain has **4 cerebral lobes**, each responsible for different functions. The surface is folded into **gyri** (ridges) and **sulci** (grooves) to maximize surface area within the skull.

🖼️ Approved Images

Fig 1. Lobes of the Cerebrum

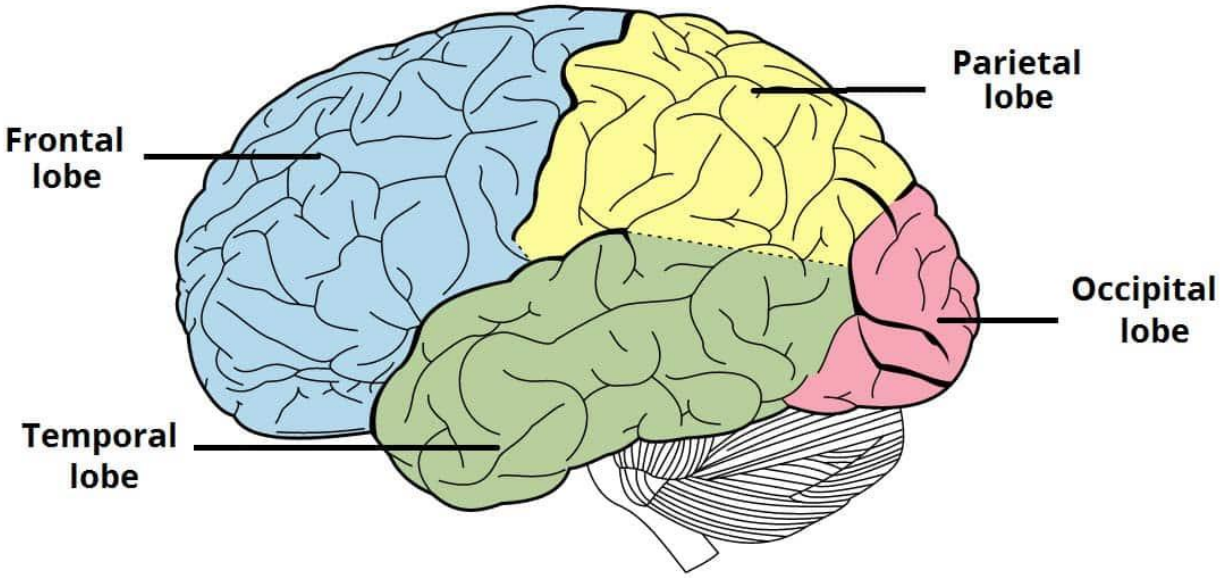

> **Source:** TeachMeAnatomy — Neuroanatomy: Structures > **Alt:** “Illustration of the lobes of the cerebral cortex, highlighting their anatomical regions.”

Fig 2. Basal Ganglia Components

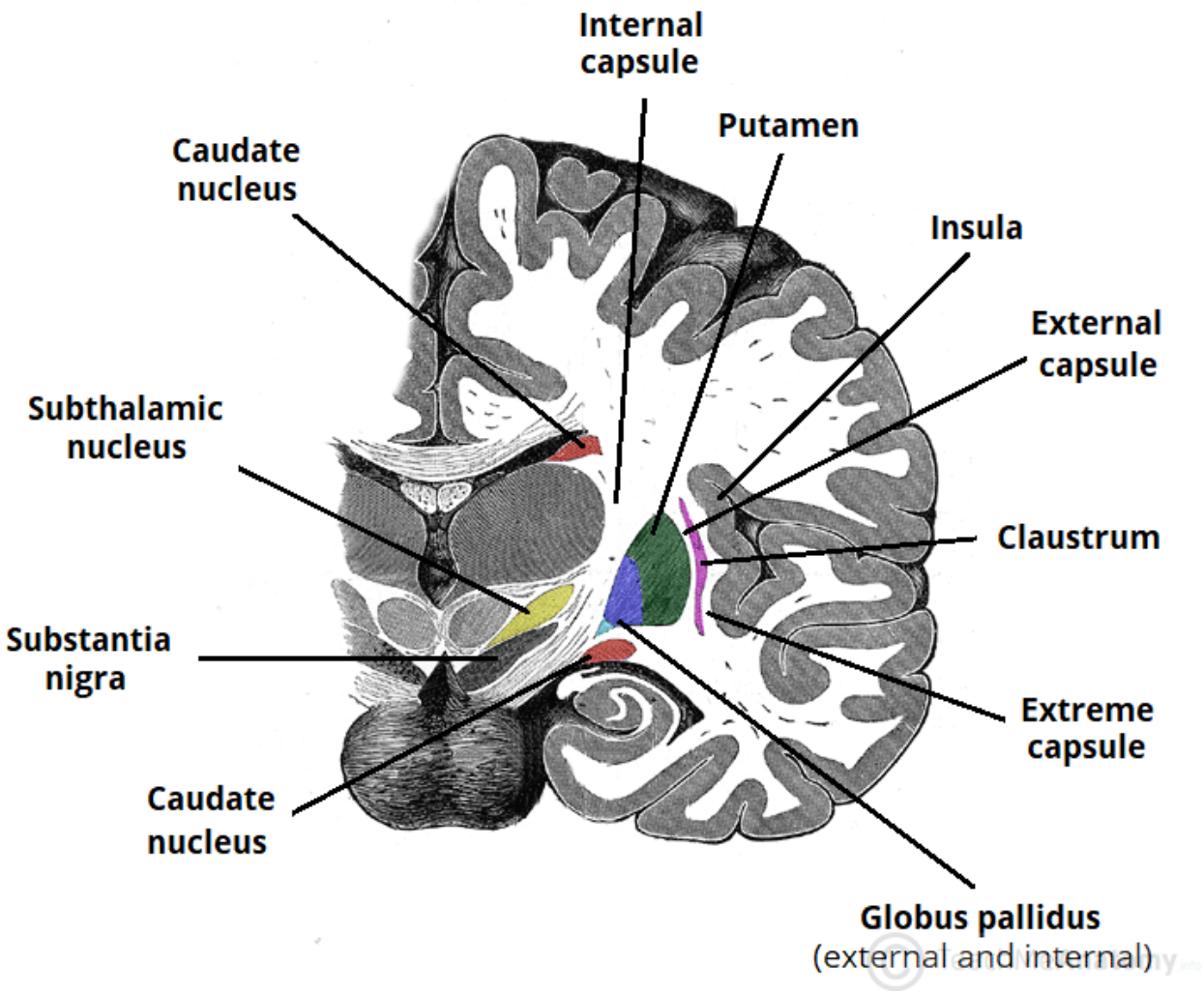

> **Source:** TeachMeAnatomy — Neuroanatomy: Structures > **Alt:** "Illustration of the components of the basal ganglia and their anatomical relations."

🧠 The 4 Cerebral Lobes

Lobe	Location	Key Functions	Clinical Correlation
Frontal	Anterior to central sulcus, above lateral sulcus	Motor function, speech (Broca), executive planning, personality, decision-making, working memory	Broca aphasia, frontal lobe syndrome, personality changes
Parietal	Behind central sulcus, above lateral sulcus	Sensory integration, spatial awareness, Wernicke area (language	Wernicke aphasia, Gerstmann syndrome (angular gyrus lesion)

Lobe	Location	Key Functions	Clinical Correlation
		comprehension), calculation	
Temporal	Below lateral sulcus	Auditory processing, memory (hippocampus), emotion (amygdala), language (Wernicke)	Wernicke aphasia, Kluver-Bucy syndrome, memory deficits
Occipital	Posterior to parietal-occipital sulcus	Primary visual cortex, visual processing, color recognition	Visual field defects, cortical blindness

---

🔑 Key Sulci That Define Lobe Boundaries

Sulcus	Separates
Central sulcus (Rolando)	Frontal ⍰ Parietal
Lateral sulcus (Sylvian)	Frontal/Parietal ⍰ Temporal
Parieto-occipital sulcus	Parietal ⍰ Occipital
Calcarine sulcus	Divides occipital lobe (visual cortex location)

🧩 Deep Gray Nuclei (Deep Brain Structures)

These are collections of neurons **deep within the cerebrum**, not in the cortex.

The Basal Ganglia Circuit

```
Cortex → Striatum (Caudate + Putamen) → GPi/SNr → Thalamus → Cortex
                ↑                                ↓
                ←←←←←←←← (Direct/Indirect pathways) ←←←←←←←←
```

Structure	Role	Clinical Note
Caudate nucleus	Part of striatum; involved in motor planning	Huntington disease — caudate atrophy

Structure	Role	Clinical Note
Putamen	Part of striatum; motor, cognitive	Parkinson — putaminal changes
Globus pallidus internus (GPi)	Output nucleus; inhibits thalamus	DBS target for Parkinson
Subthalamic nucleus (STN)	Part of indirect pathway	Lesion → hemiballismus
Substantia nigra	Dopamine production; motor facilitation	Parkinson — depigmentation

Other Deep Gray Nuclei

Structure	Function
Thalamus	Relay station — sensory, motor, cognitive signals to cortex
Amygdala	Emotion processing, fear response
Hippocampus	Memory consolidation (episodic, spatial)

🧬 Cerebral Cortex — Microscopic Structure

Neocortex (6 Layers) vs Allocortex (3 Layers)

- **Neocortex:** ~90% of human cortex — 6 layers (I–VI), responsible for higher functions
- **Allocortex:** ~10% — 3 layers (hippocampus, olfactory cortex)

The 6 Layers of Neocortex

Layer	Name	Function
I	Molecular	Dendritic connections, integration
II	External granular	Small pyramidal cells, inputs

Layer	Name	Function
III	External pyramidal	Association corticocortical connections
IV	Internal granular	Thalamic inputs (sensory)
V	Internal pyramidal	Corticofugal outputs (motor to brainstem/spinal cord)
VI	Multiform	Outputs to thalamus

> ***Board Pearl:*** *Layer IV = thalamic input layer — prominent in primary sensory cortices. Layer V = corticofugal output — prominent in primary motor cortex (Betz cells).*

💡 Gyri — Key Functional Landmarks

Gyrus	Lobe	Function
Precentral gyrus	Frontal	**Primary motor cortex** (M1) — controls voluntary movement
Postcentral gyrus	Parietal	**Primary somatosensory cortex** (S1) — receives sensory input
Superior temporal gyrus	Temporal	Wernicke area (language comprehension) — usually LEFT hemisphere
Inferior frontal gyrus	Frontal	Broca area — speech production — usually LEFT hemisphere
Angular gyrus	Parietal	Language, calculation, conceptual processing
Parahippocampal gyrus	Temporal	Memory encoding

🔬 Surface Area — Why Folding Matters

- The cerebral cortex contains **~16 billion neurons**
- **Two-thirds** of the cortex lies within sulci (hidden in the grooves)

- **One-third** is exposed on gyri (visible on the surface)
- This folding allows ~2,200 cm^2 of cortical surface to fit inside the skull

---

📋 Clinical Pearls

Scenario	Lesion Localization
Expressive (non-fluent) aphasia with intact comprehension	**Broca area** — left inferior frontal gyrus
Receptive (fluent) aphasia with poor comprehension	**Wernicke area** — left superior temporal gyrus
Inability to recognize objects (visual)	**Occipital lobe** (inferior visual association cortex)
Personality changes + disinhibition	**Frontal lobe** (especially orbitofrontal)
Loss of sensation on one side of body	**Postcentral gyrus** (contralateral)
Weakness of one side of body	**Precentral gyrus** (contralateral)

🎯 Brodmann Areas — High Yield

Area	Location	Function
Brodmann 4	Precentral gyrus	Primary motor cortex
Brodmann 3,1,2	Postcentral gyrus	Primary somatosensory cortex
Brodmann 44,45	Inferior frontal gyrus	Broca area (speech production)
Brodmann 22	Superior temporal gyrus	Wernicke area (speech comprehension)
Brodmann 17	Calcarine sulcus (occipital)	Primary visual cortex
Brodmann 41,42	Transverse temporal gyrus	Primary auditory cortex

---

🗺️ Functional Organization

```
ANTERIOR (Frontal)          →          →          →    POSTERIOR (Occipit

Prefrontal     Motor        Sensory       Parietal      Visual
Cortex         Cortex       Cortex        Association   Cortex
(Executive)     (M1)         (S1)          Cortex        (V1)
```

📚 Sources

- **Alberstone et al.** — *Anatomic Basis of Neurologic Diagnosis* (2nd ed, 2023)
- **Bradley** — *Neurology in Clinical Practice* (8th ed)
- **Adams & Victor** — *Principles of Neurology* (12th ed, 2023)
- **Radiopaedia** — Cerebral cortex
- **TeachMeAnatomy** — Neuroanatomy: Structures

🔗 Related Topics

- [[wiki/foundation/NEUROANATOMY_BLOOD_SUPPLY|Blood Supply — Cerebral Circulation]]
- [[wiki/foundation/NEUROANATOMY_LIMBIC|Limbic System — Memory & Emotion]]
- [[wiki/foundation/NEUROANATOMY_BASAL_GANGLIA|Basal Ganglia — Motor Circuits]]
- [[wiki/foundation/CRANIAL_NERVES|Cranial Nerves Overview]]

🃏 Anki Prompts

Front	Back
What separates the frontal from parietal lobe?	Central sulcus (Rolando)
What separates the frontal from temporal lobe?	Lateral sulcus (Sylvian)
Broca area is in which gyrus and lobe?	Inferior frontal gyrus, Frontal lobe
Wernicke area is in which gyrus and lobe?	Superior temporal gyrus, Temporal lobe

Front	Back
What are the 4 cerebral lobes?	Frontal, Parietal, Temporal, Occipital
What are the components of the basal ganglia?	Caudate, Putamen, Globus pallidus, Subthalamic nucleus, Substantia nigra
Which layer of neocortex receives thalamic input?	Layer IV (internal granular)
Which layer contains Betz cells (corticofugal output)?	Layer V (internal pyramidal)
Lesion of the dominant hemisphere angular gyrus causes?	Gerstmann syndrome (agraphia, acalculia, finger agnosia, L-R confusion)

Last updated: 2026-04-24 | Phase 1 — Foundation | Status: 🔄 In Progress