UNIVERSITY OF LUSAKA

ANATOMY PRACTICAL EXAMINATION BMHA 221

MIDSEMESTER EXAMINATION

Wednesday 11th March 2026

EXAM RULES

These Picture Slides accompany and should be used to answer the Practical online examination

A

QUESTION 1

What structure of the Nervous System is shown and what is A?

A. The Pons and A is the Red Nucleus

B. The Midbrain and A is the Substansia Nigra

C. The Cerebellum and A are the Purkinje Cells

D. The Cerebrum and A are the Cells of Betz

E. The Diancephalon and A is the Substansia Nigra

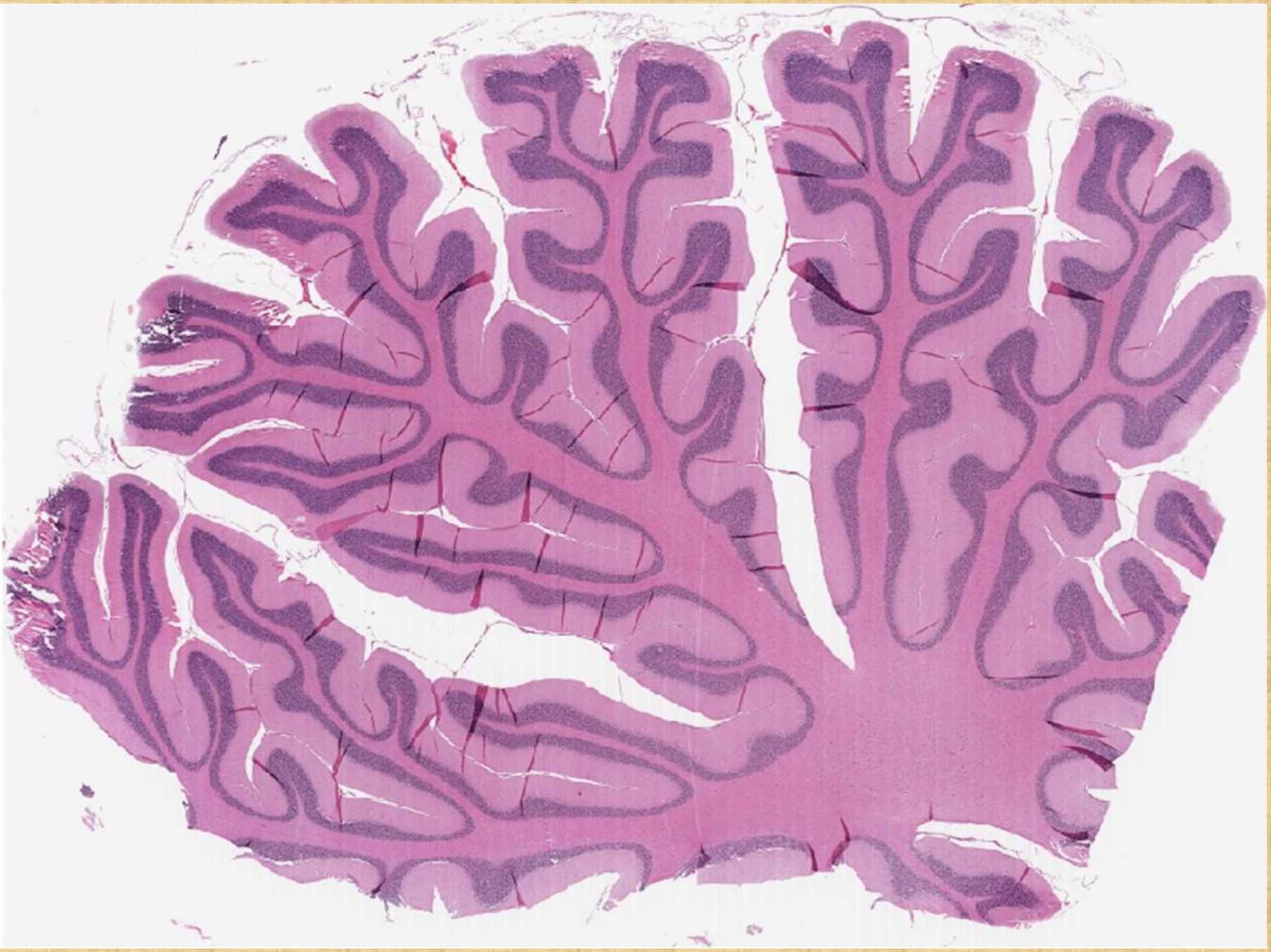

QUESTION 2

2.What is shown in slide 2

A. This is an H & E stained histology slide of the Cerebellum

B. This a histology slide of the Cerebral Cortex

C. This is an Toluidine histology slide pf the Cerebullum

D. This an H & E slide of the Cerebrum

E. This a Toluidine slide of the Cerebellum

QUESTION 3

3.What is the Cranial Nerve injury in slide 3?

A. This a Trochlear Nerve Palsy

B. This is the Abducent Nerve Palsy

C. This is the Right Occulomotor Nerve Palsy

D. This is the Left Occulomotor Nerve Palsy

E. This is the Trochlear and Abducent Nerve palsy on the left Side

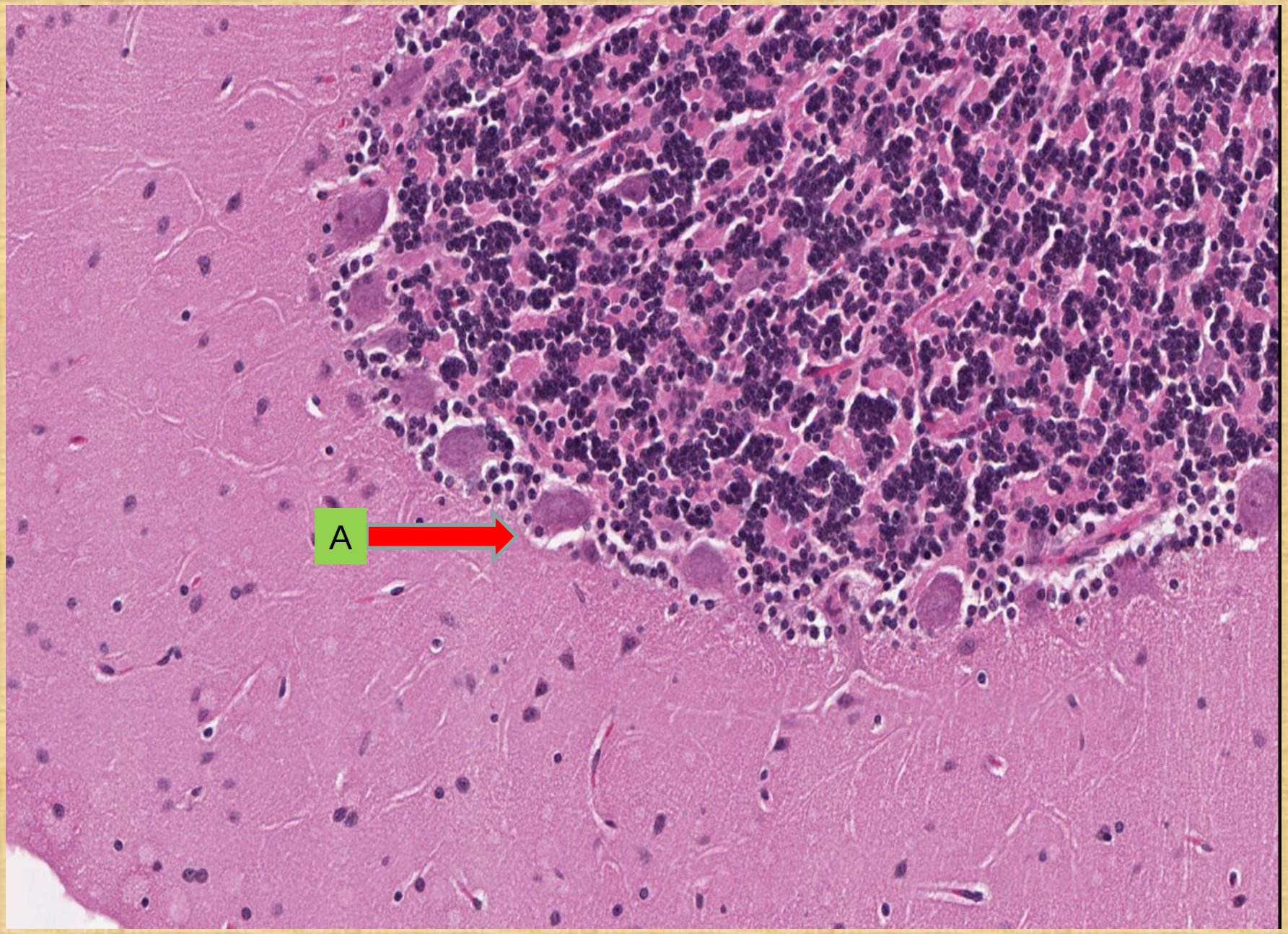
A

QUESTION 4

4.What is the cell Labelled A in slide 4 ?

A. This is the Pyramidal cell

B. This is the Cell of Betz

C. This is the Purkinje Cell

D. This is a Basket Cell

E. This a Dorsal Ganglia Cell

Slide 5

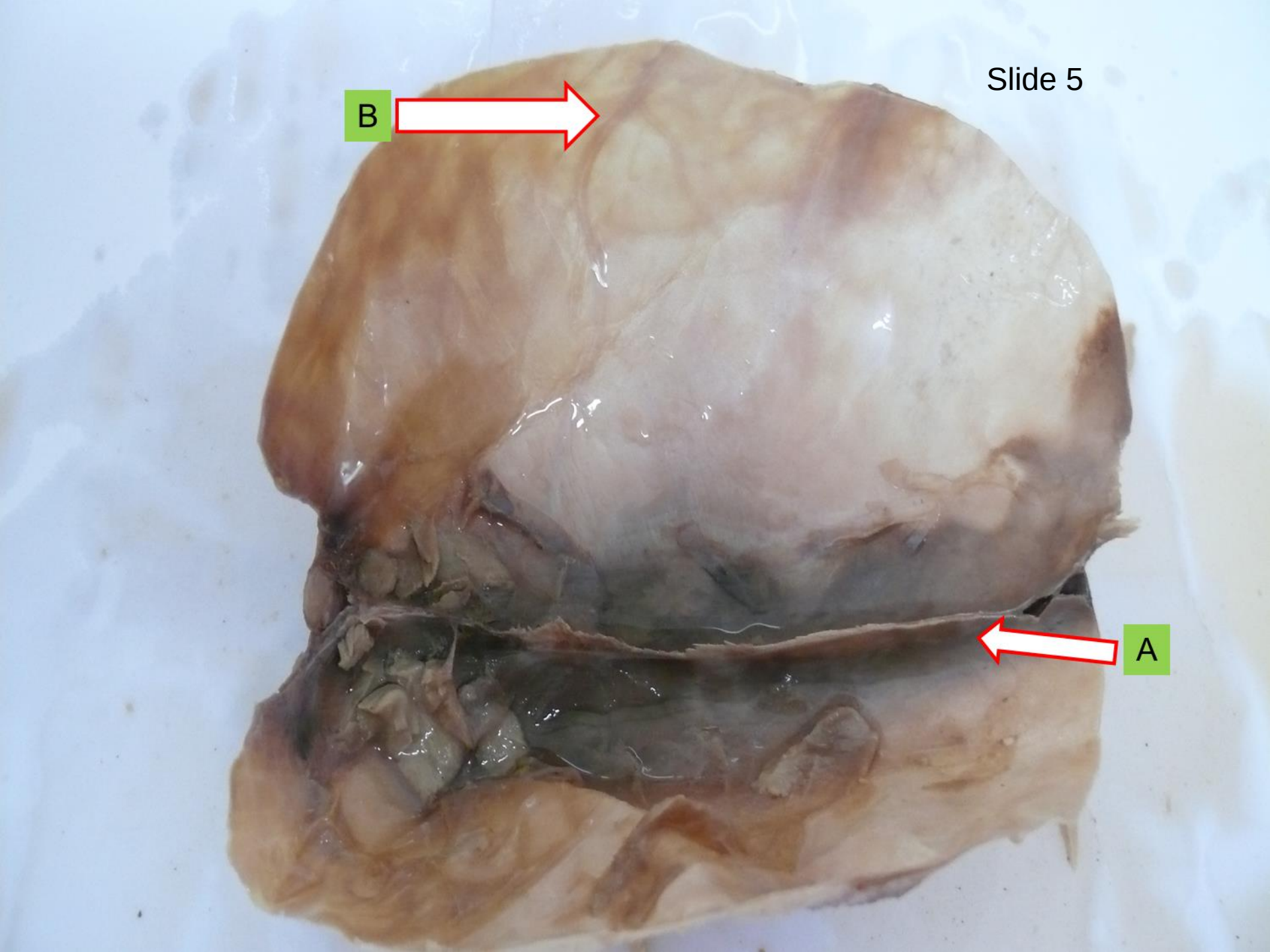

QUESTION 5

5.What is the Blood Vessel labelled B in slide 5?

A. Internal Carotid Artery

B. The Middle Cerebral artery

C. The Middle Meningeal Artery

D. The Anterior Cerebral artery

E. The Facial artery

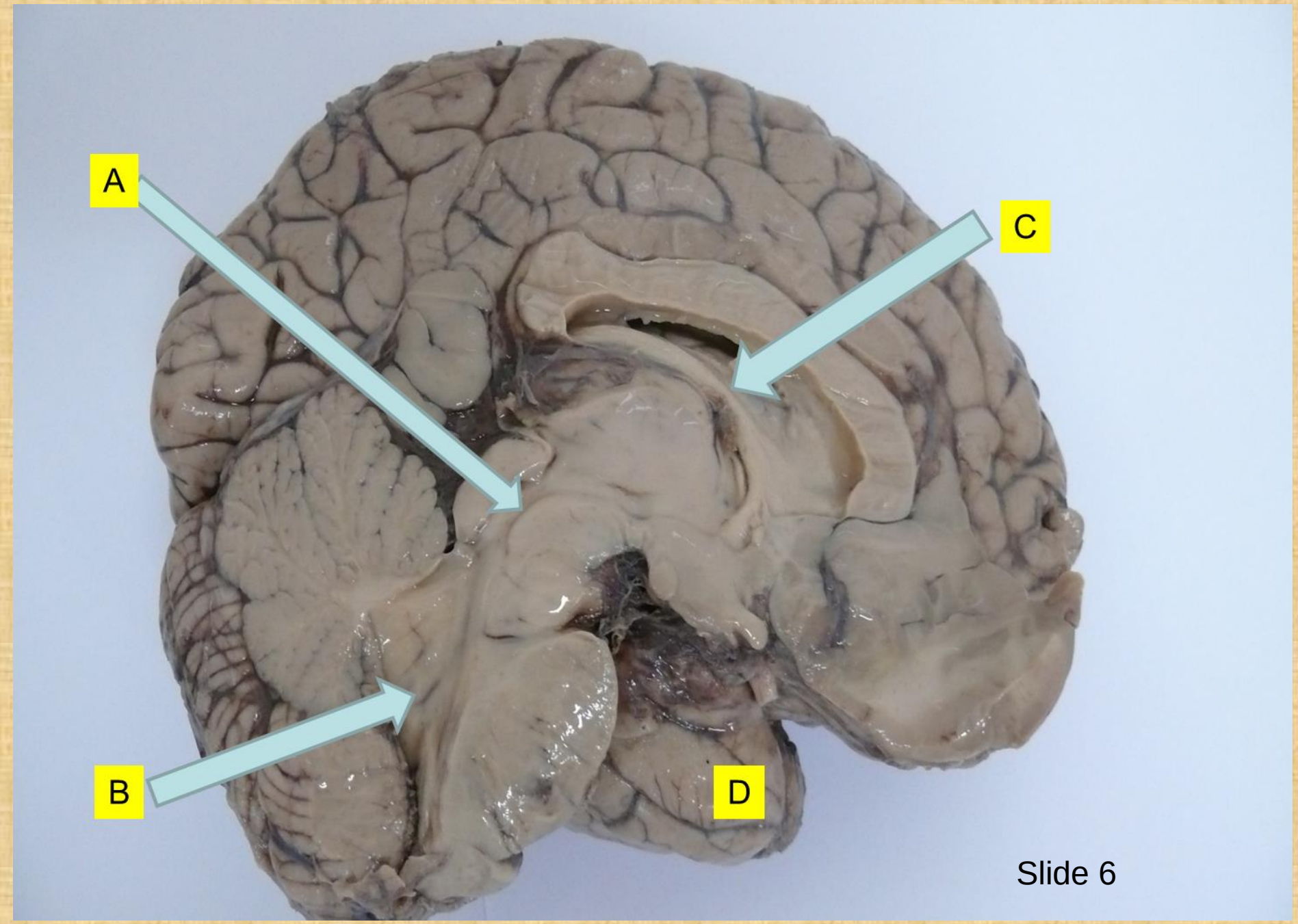

Slide 6

QUESTION 6

6.What is the Cavity labelled B in slide 6

A. The Midbrain
B. The Aqueduct of Sylvius
C. The 4th Ventricle
D. The Foramen of Monro
E. The 3rd Ventricle

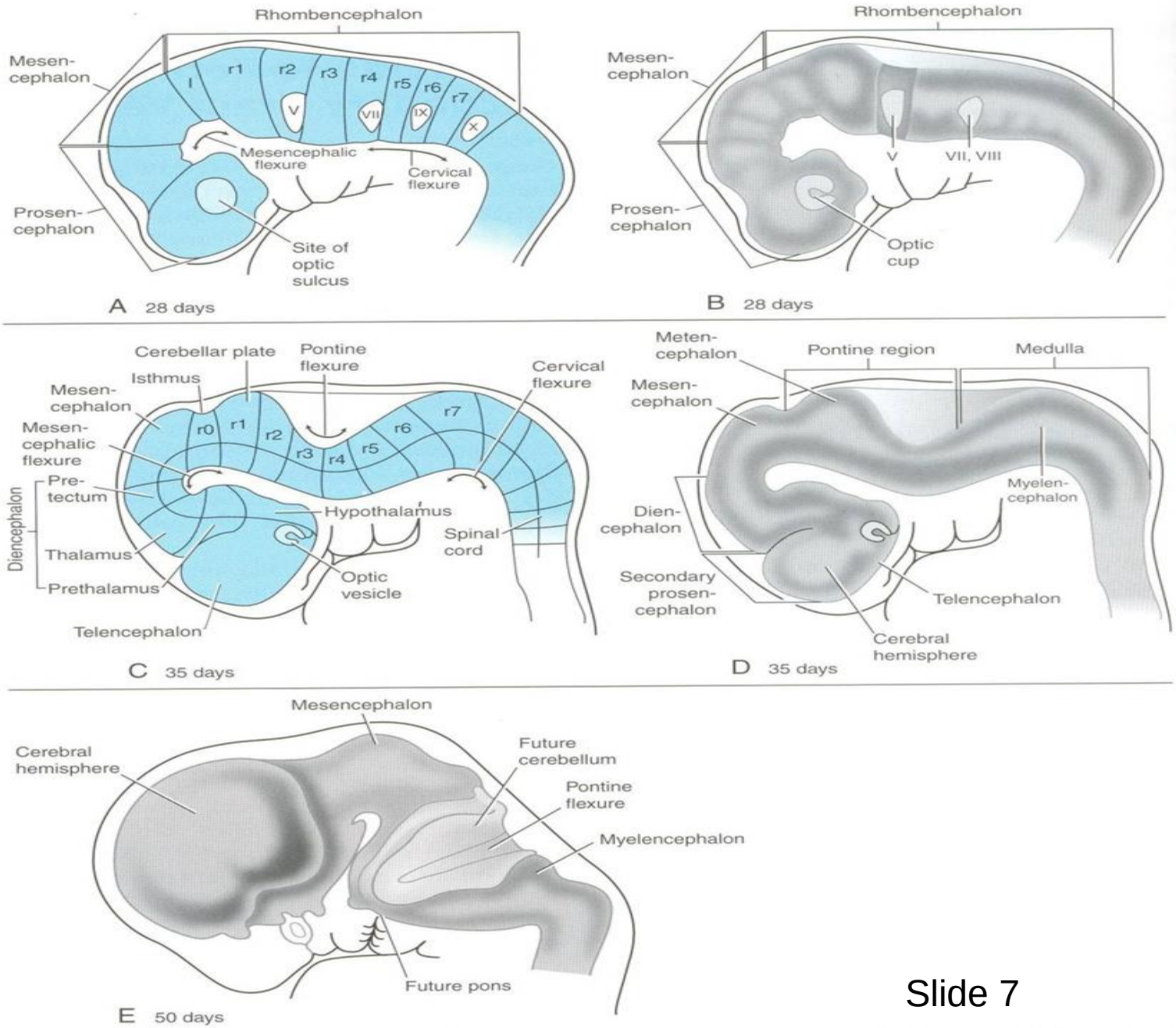

Slide 7

Figure 9-1. Early development of the brain. *A, B,* By day 28, the future brain consists of three primary brain vesicles (the prosencephalon, mesencephalon,

QUESTION 7

7.What is shown in slide 7

A. The External Development of the Brain

B. The Internal Development of the Brain

C. The formation of the Neural Tube

D. The Folding of Brain inside the Cranial Cavity

E. The Migration of the three internal layers of the Brain

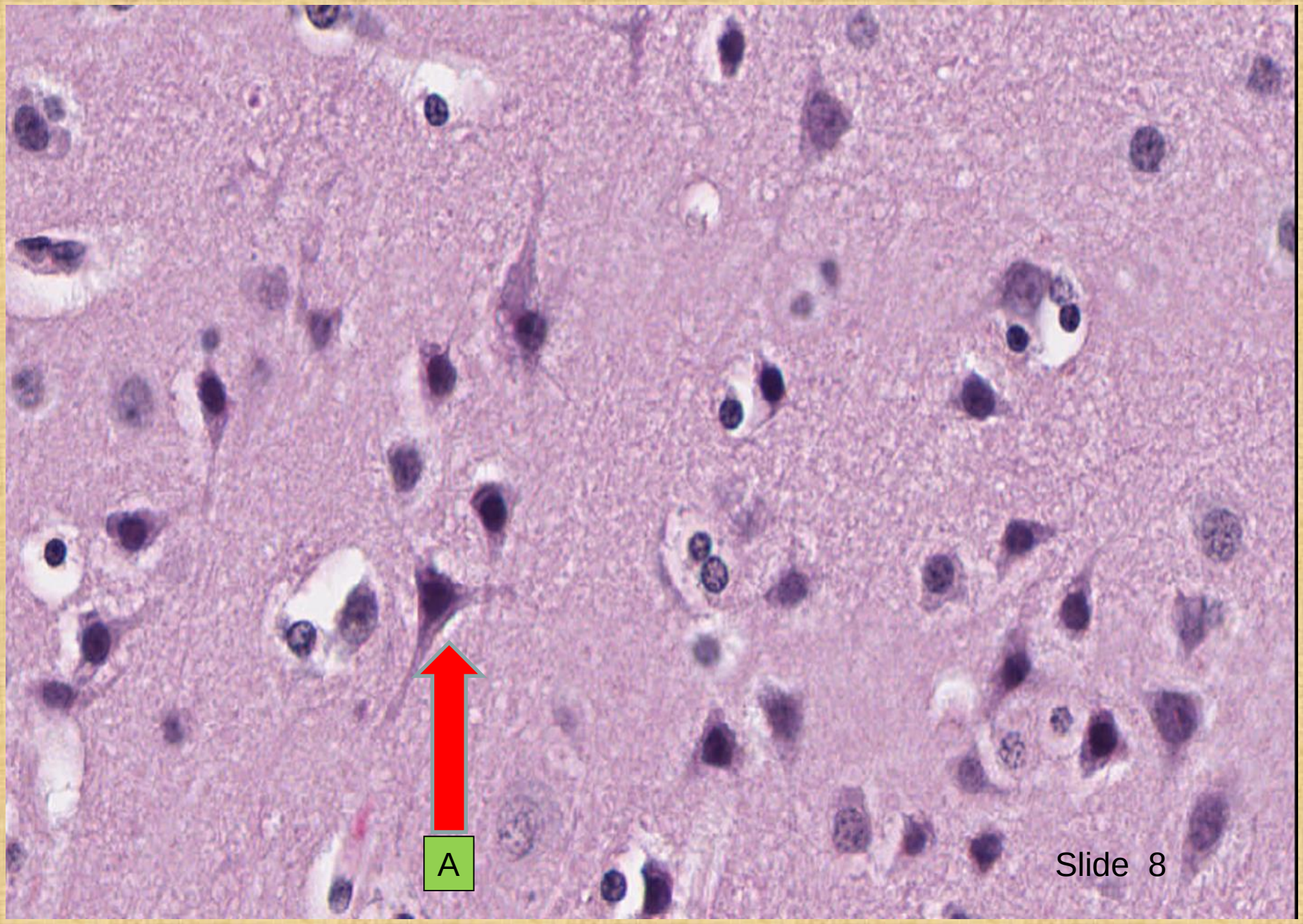
A
Slide 8

QUESTION 8

8.What is the cell labelled A in slide 8

A. Oligodendrocyte

B. Pyramidal cell

C. Betz Cell

D. Schwann Cell

E. Purkinje Cell

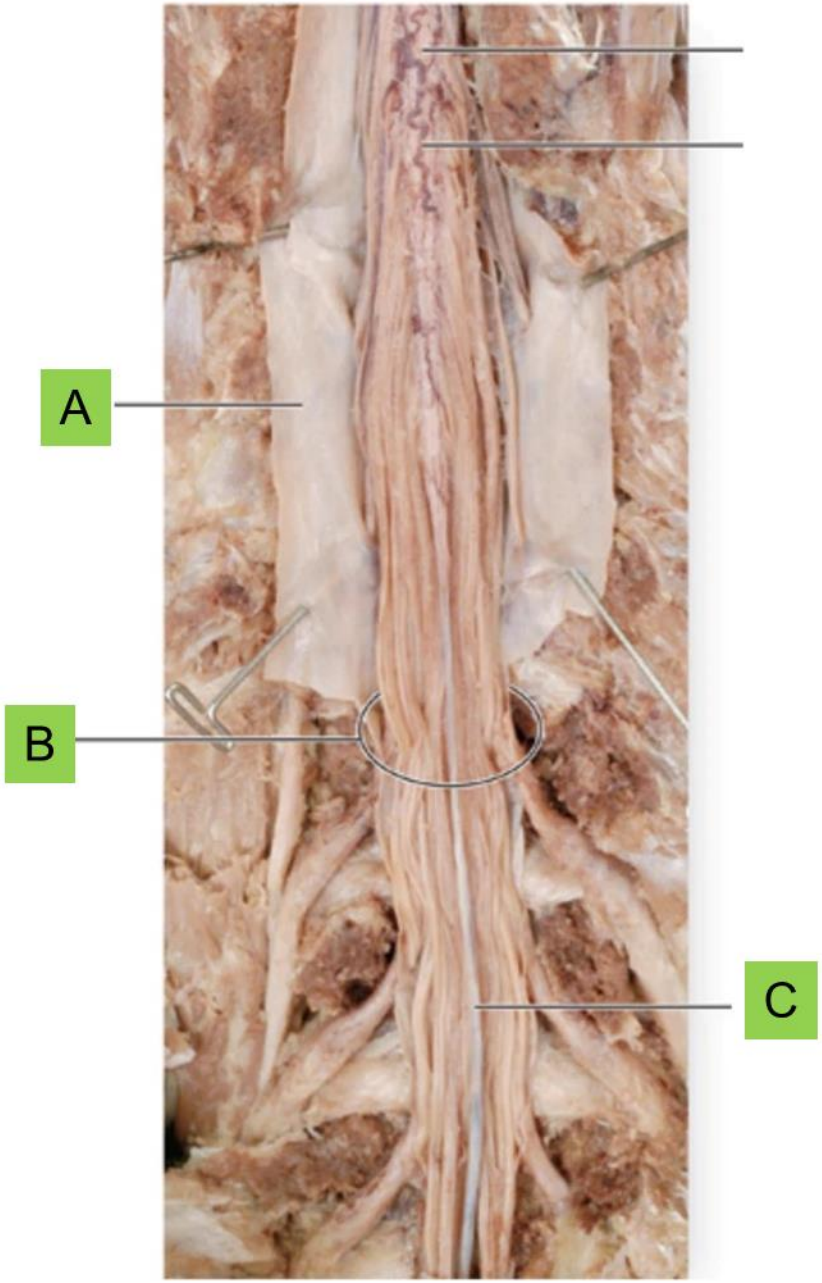

Slide 9

QUESTION 9

9.What are A, B and C in slide 9

A. A=Duramater B=Cauda Equina C =Filum Terminale

B. A=Piamater B=Cauda Equina C =Conus Medularis

C. A=Foramen Magnum B=Spinal Cord C =Termination of the Spinal Cord

D. A=Duramater B=Filum Terminale C =Conus Medularis

E. A=Duramater Cell B=Coccygeal membrance C =Piamater

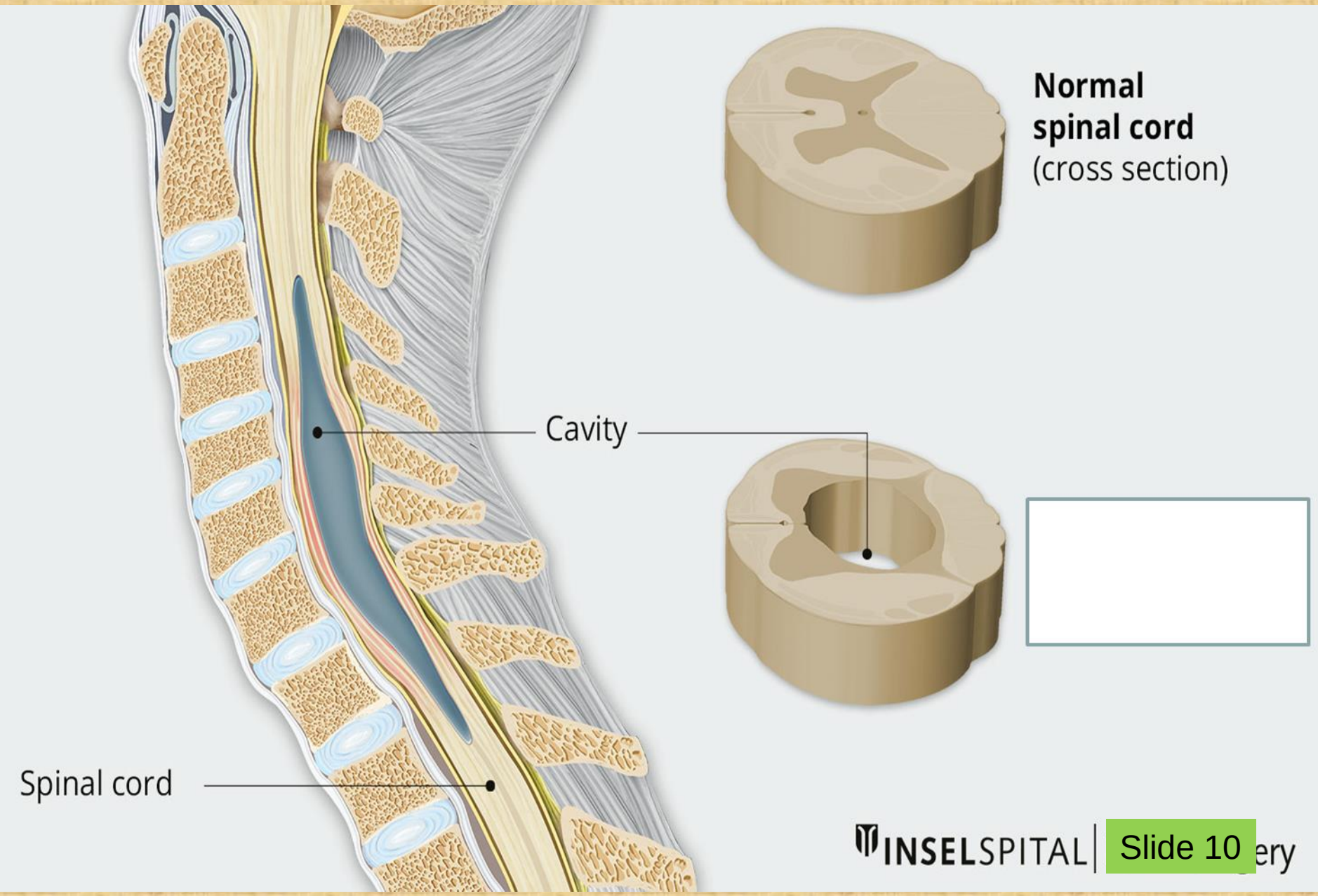
Normal
spinal cord
(cross section)
Cavity
Spinal cord
INSELSPITAL

Slide 10

QUESTION 10

10.What is shown in slide 10

A. Absence of the Grey Matter

B. Syringomyelia

C. Hydrocephalus of the Spinal cord

D. Spina Bifida

E. Dilated Central canal of the Spinal Cord

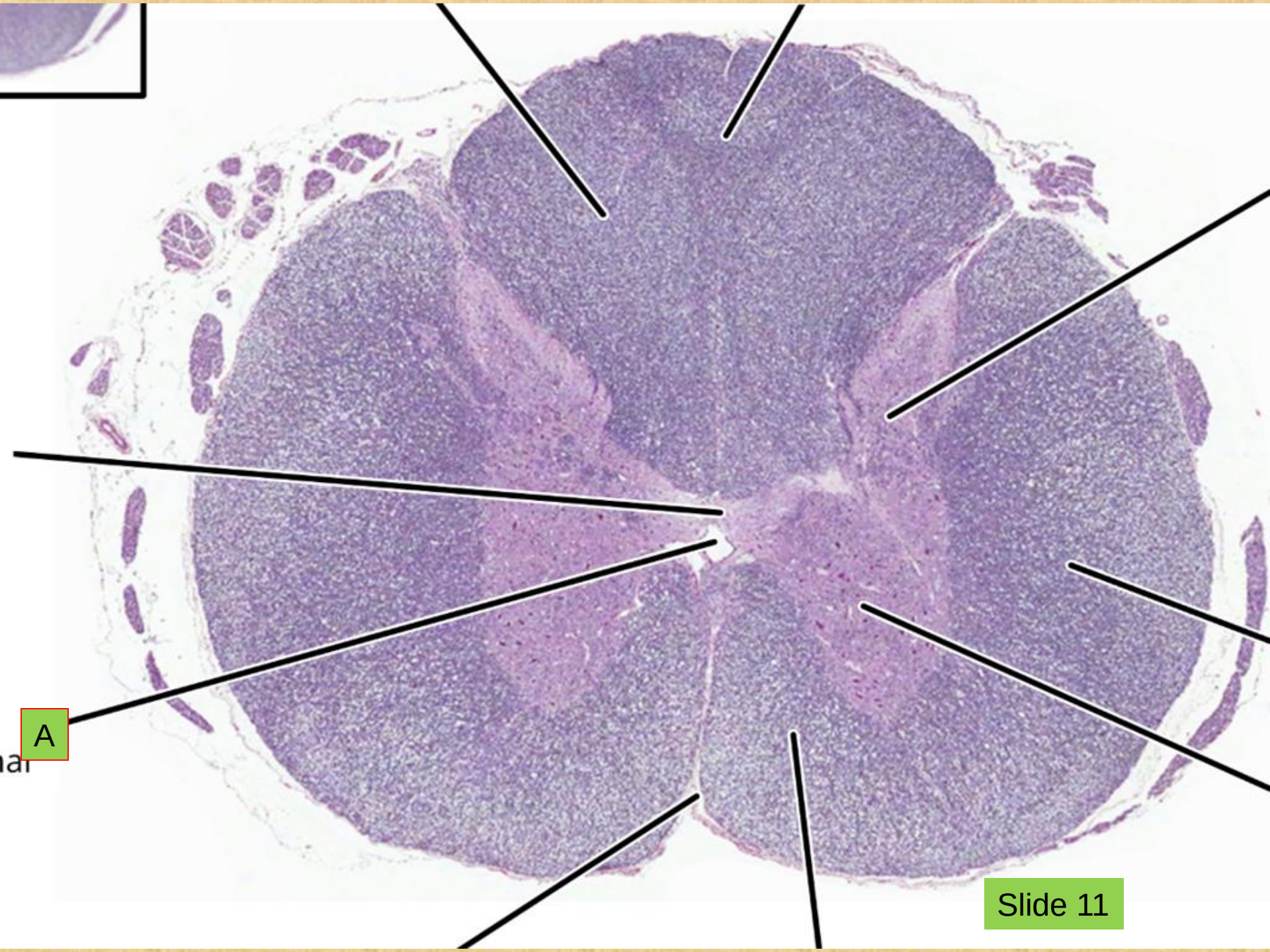
A
Slide 11

QUESTION 11

11.What does slide 11 show?

A. The Gross Anatomy of the Spinal Cord

B. The Columns of Rexed

C. The Histology of the Spinal Cord

D. The Central Canal

E. The Embryology of the Spinal Cord

Copyright © The McGraw-Hill Companies, Inc. Permission required for reproduction or display.

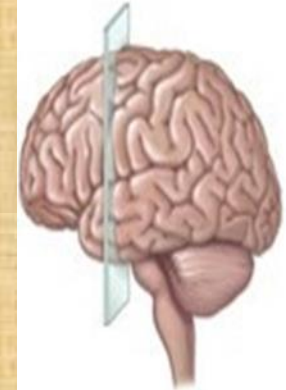

A

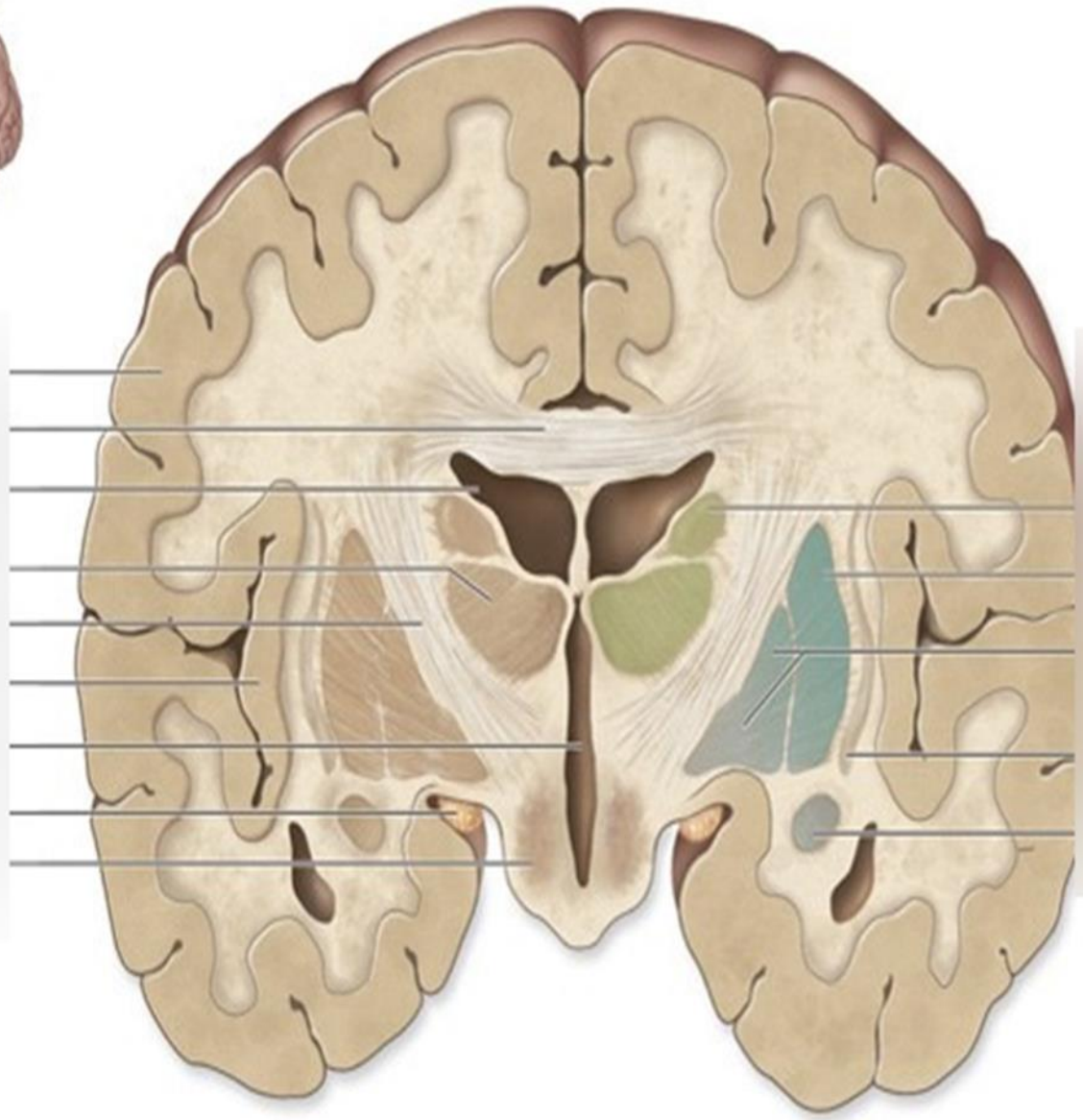

Slide 12

QUESTION 12

14.What is the blood supply to the area labelled A in the slide 14?

A. The Middle Cerebral Artery

B. The Internal Capsule

C. The Lenticulostriate Arteries

D. The Anterior Cerebral Artery

E. The Posterior Cerebral

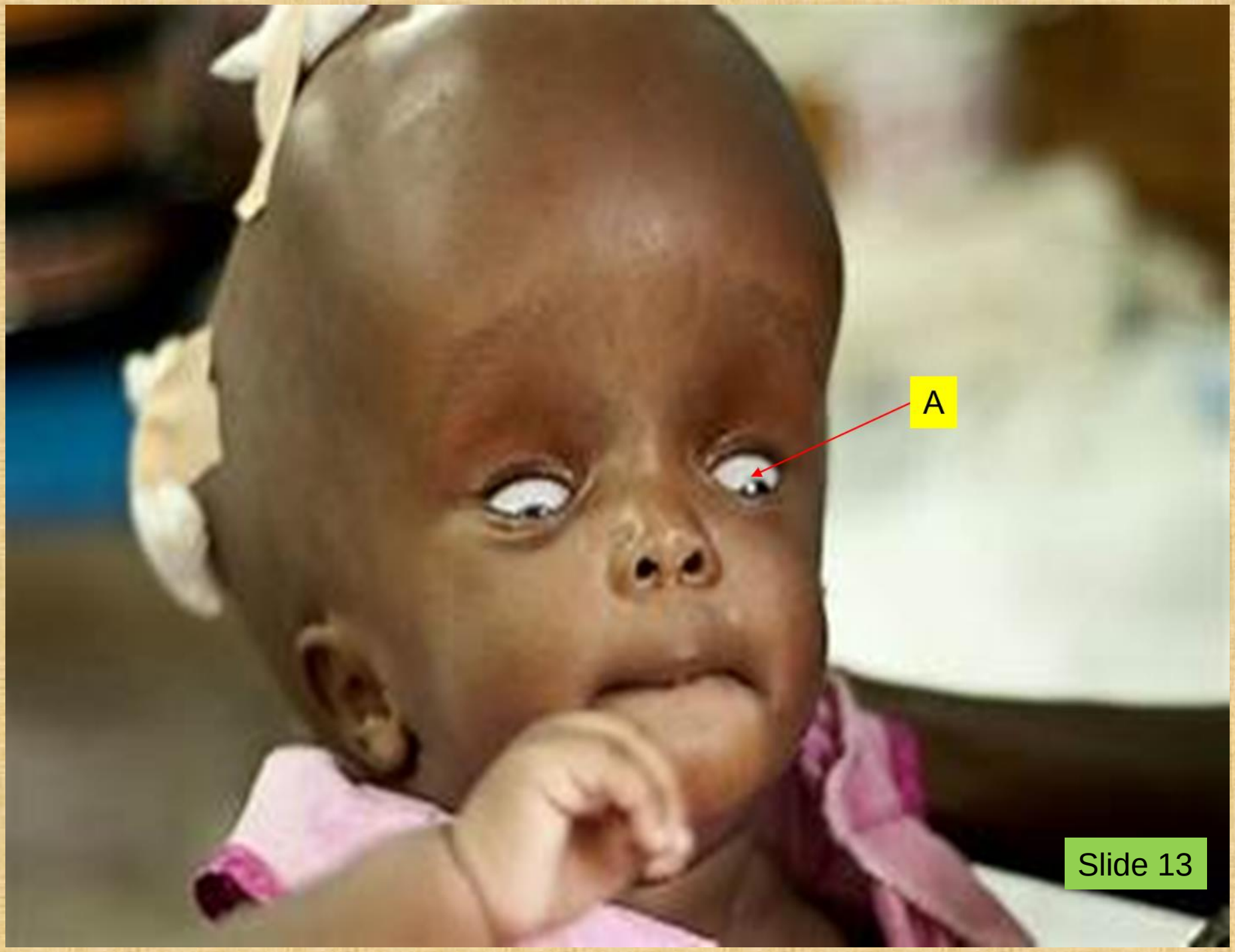

Slide 13

QUESTION 13

13.What is the sign shown as A in slide 13?

A. The Macewen sign

B. The Crack Pot Sign

C. The Sun setting Sign

D. The Down and out sign

E. The Cerebal Oedema sign

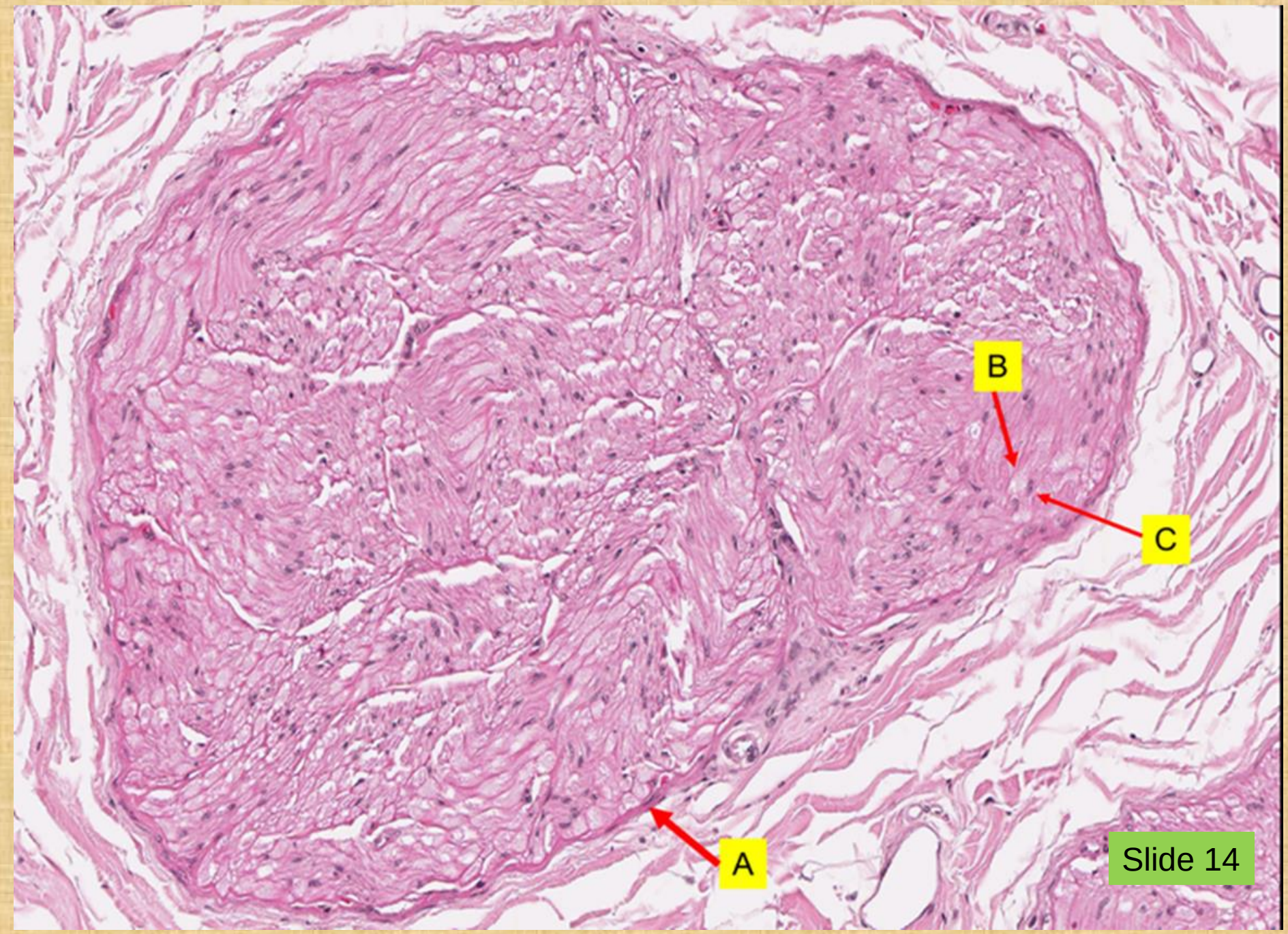
B
C
A
Slide 14

QUESTION 14

14.What is the histology of the Nervous System shown and what are A, B and C?

A. A=is the Epineurium, B Perineurium and C Schwann Cell

B. A=is the Perineurium, B Endonerium and C Oligodendrocyte Cell

C. A=is the Perineurium, B Endoneurium and C Schwann Cell

D. A=is the Perineurium, B Endoneurium and C Myelin Cell

E. A=is the Epineurium, B Endoneurium and C Schwann Cell

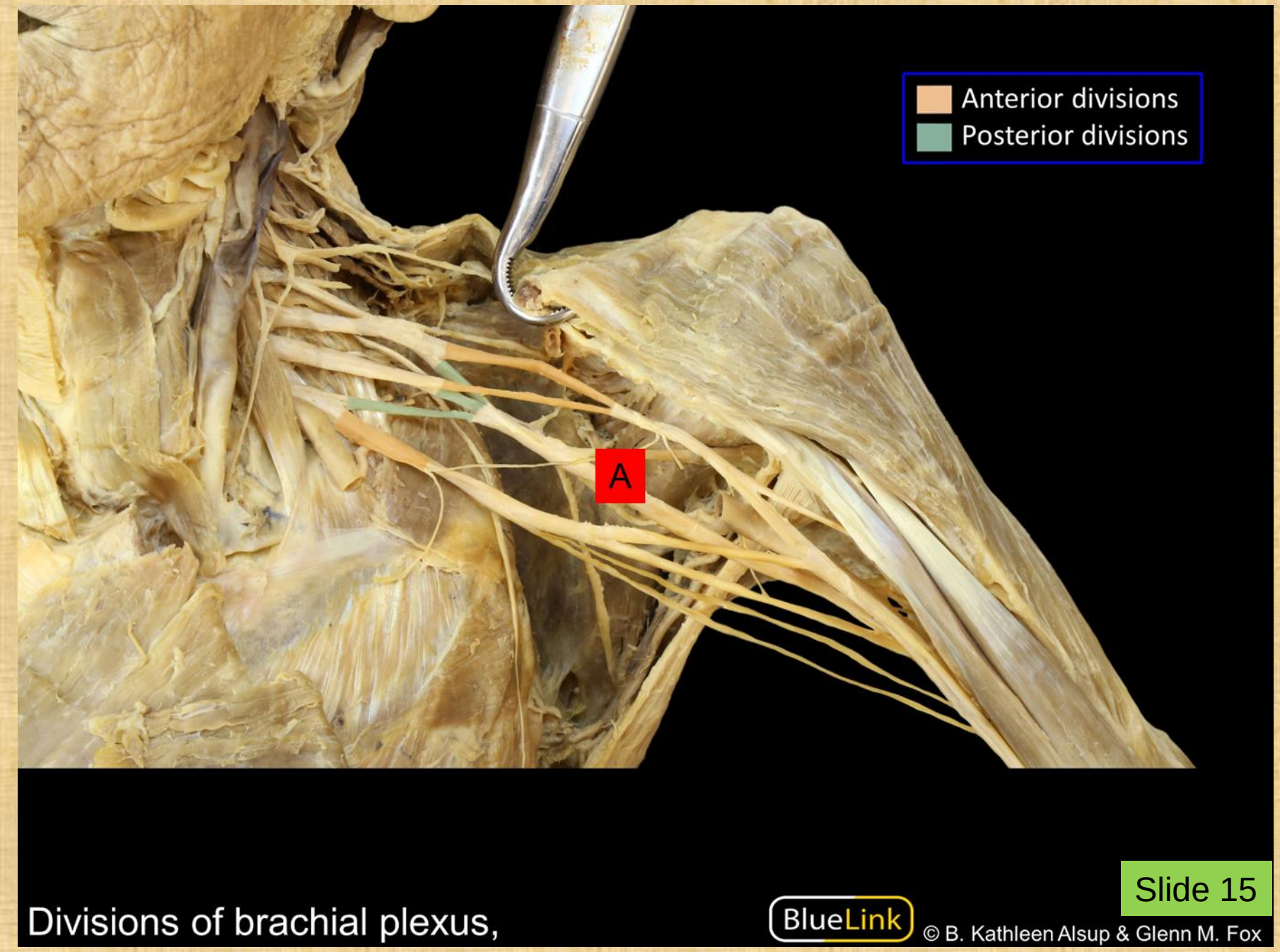

Divisions of brachial plexus,

QUESTION 15

15.What is the Gross Anatomy of the PNS shown and what is A?

A. This is showing the Upper Limb and A is the Median Nerve

B. This is showing the Cervical Plexus and A is the Posterior Cord

C. This is showing the Brachial Plexus and A is the Radial nerve

D. This is the Upper Limb and A is the Ulnar Nerve

E. This is the Brachial Plexus and A is the Thoracodorsal Nerve

THE END

Blank Quiz

Total points 50/50

The respondent's email (**pmbchb24128717@stud.unilus.ac.zm**) was recorded on submission of this form.

✓ Q1 The picture shows a patient with a disorder of the Brain which part of the Brain is diseased. 5/5



- ○ A.The Basal Ganglia
- ◉ B.The Substansia Nigra ✓
- ○ C.The Diaencephalom
- ○ D.The Limbic System
- ○ E.The Cerebral Cortex

✓ Q2 This is a cadaveric section of the Brain. What is the area labelled 2 and what does it do? 5/5

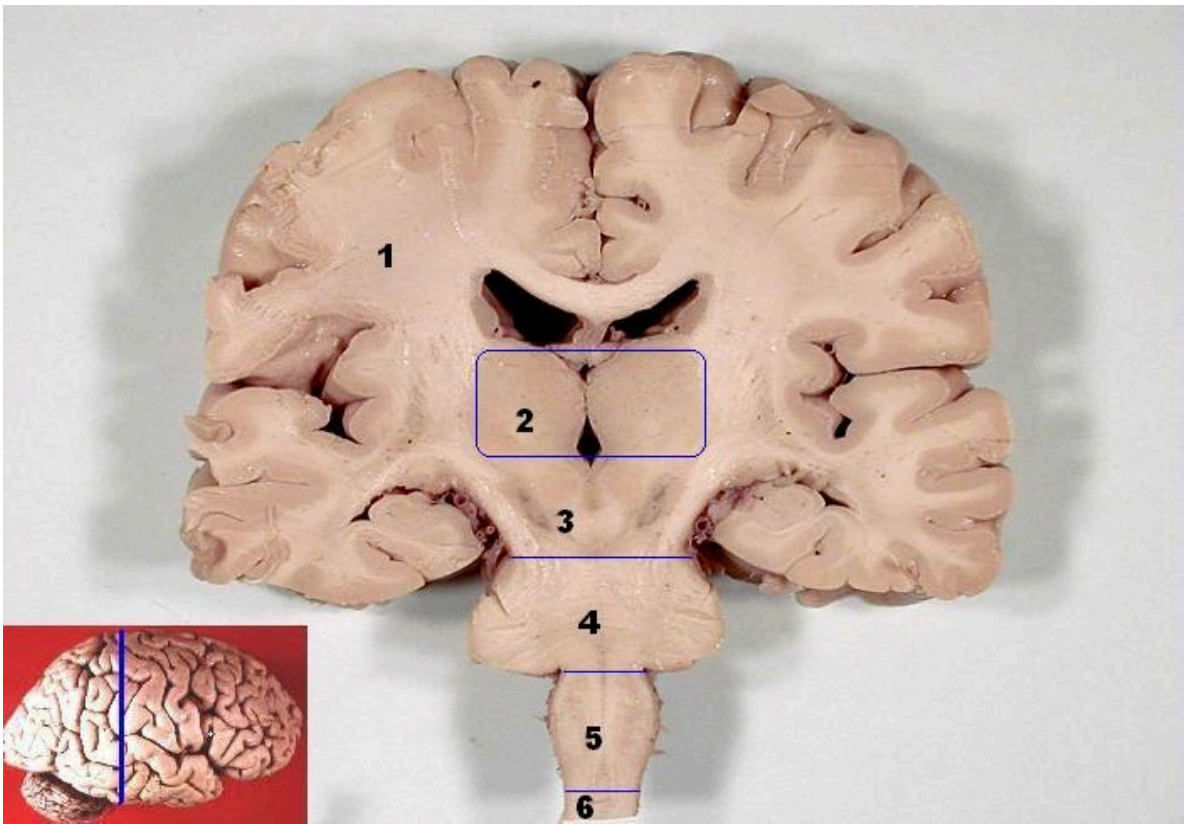

- ○ A.The Diaencephalon memory
- ○ B.The Internal capsule movement
- ◉ C.The Thalamus pain control ✓
- ○ D.The Hypothalamus endocrine control
- ○ E.The Caudate Nucleus fine movement

✓ Q3 The Anatomical Models shows the Ear. The area of the Ear label 1 is called 5/5

1
A

- (●) A.The Helix ✓
- ( ) B.The Anti Helix
- ( ) C.The Tragus
- ( ) D.The Lobule
- ( ) E.The Auricle

✓ Q4. What is the name of the Commissural fibre show in this Sagittal section of the Brain 5/5

- ( ) A.The Brain Stem
- ( ) B.The Internal Capsule
- ( ) C.The Claustrum
- ( ) D.The Hippocampus
- (●) E.The Corpus Callosum ✓

✓ Q5. From the image shown of the 12 cranial nerves the mnemonic which can helps us remember the ones that supply the eye is 5/5

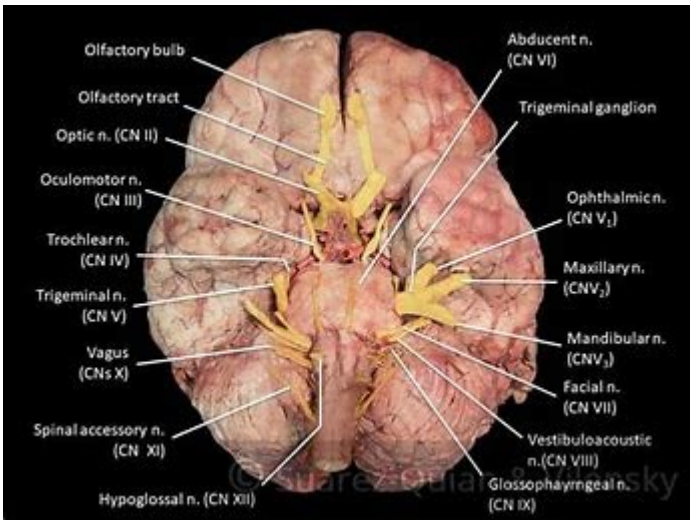

- A.SO4 RL6 OAll
- B.L4 SO6 OR
- C.SO4LR6OR ✓
- D.SO6RL4RO
- E.ALLO, SO6, LR4

✓ Q6. What is the largest cranial foramen shown in the middle cranial fossa and what passes through it 5/5

- ○ A.Foramen Rotundum- Mandibular nerve
- ◉ B.Foramen Ovale-Maxillary Nerve ✓
- ○ C.Foramen Lacerum-Cartilage
- ○ D.Foramen Magnum-Spinal Cord
- ○ E.Formen Spinosum-Middle Meningeal Artery

✓ Q7. What is the blood vessel shown in the Models of the vertebrae of the Neck 5/5

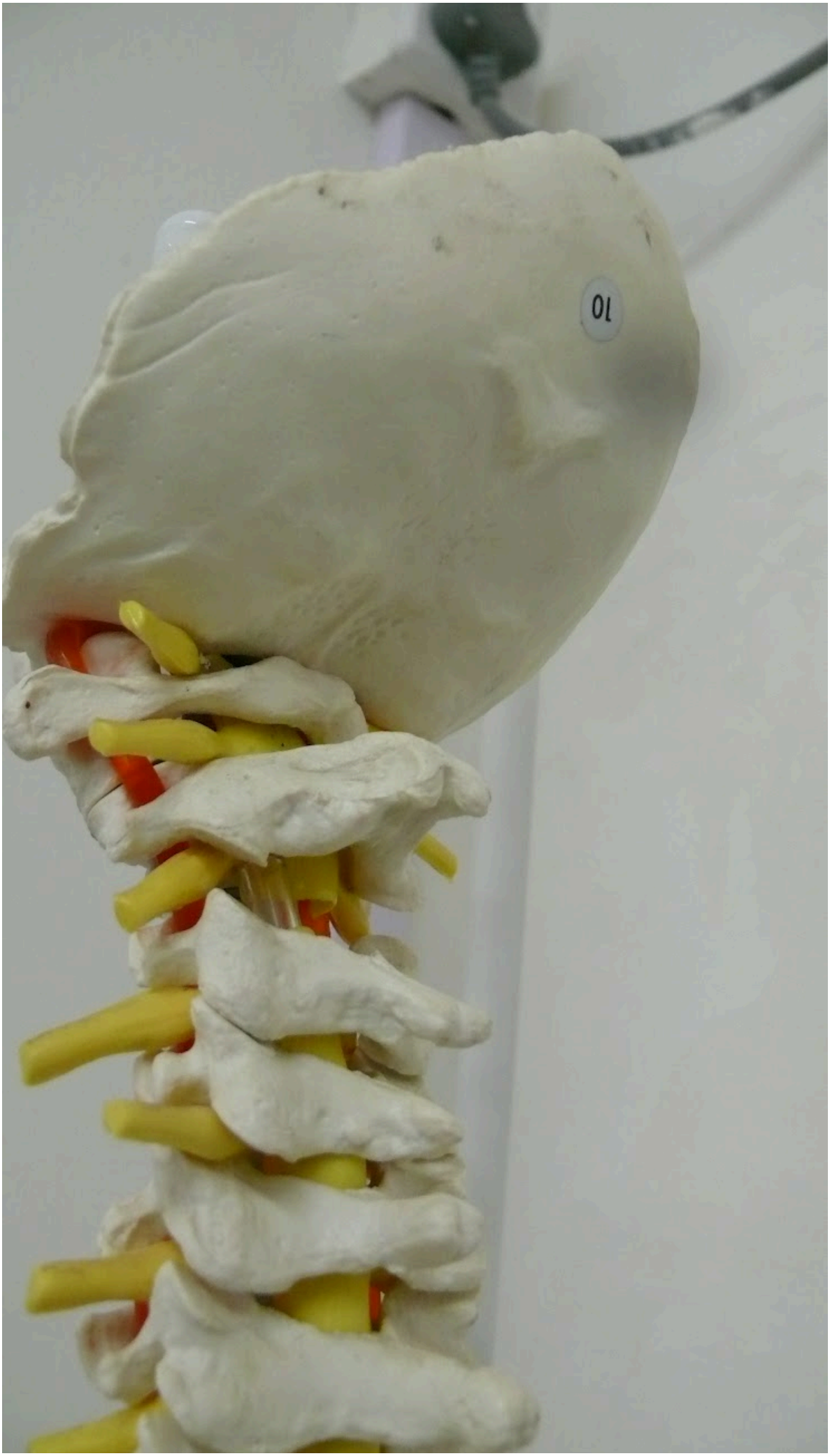
10

- A.The Internal Carotid
- B.The Basilar Artery
- C.The Vertebral artery ✓
- D.The Middle Cerebral artery
- E.The Anterior Superior Cerebellar Artery

✓ Q8. The image shows the mandible .The most commonly fractured site in this bone is 5/5

- A.The TMJ
- B.The Mandibular Notch
- C.The Angle ✓
- D.The Ramus
- E.The Body

✓ Q9.What is the nerve supply of the two big muscles of the Neck shown? 5/5

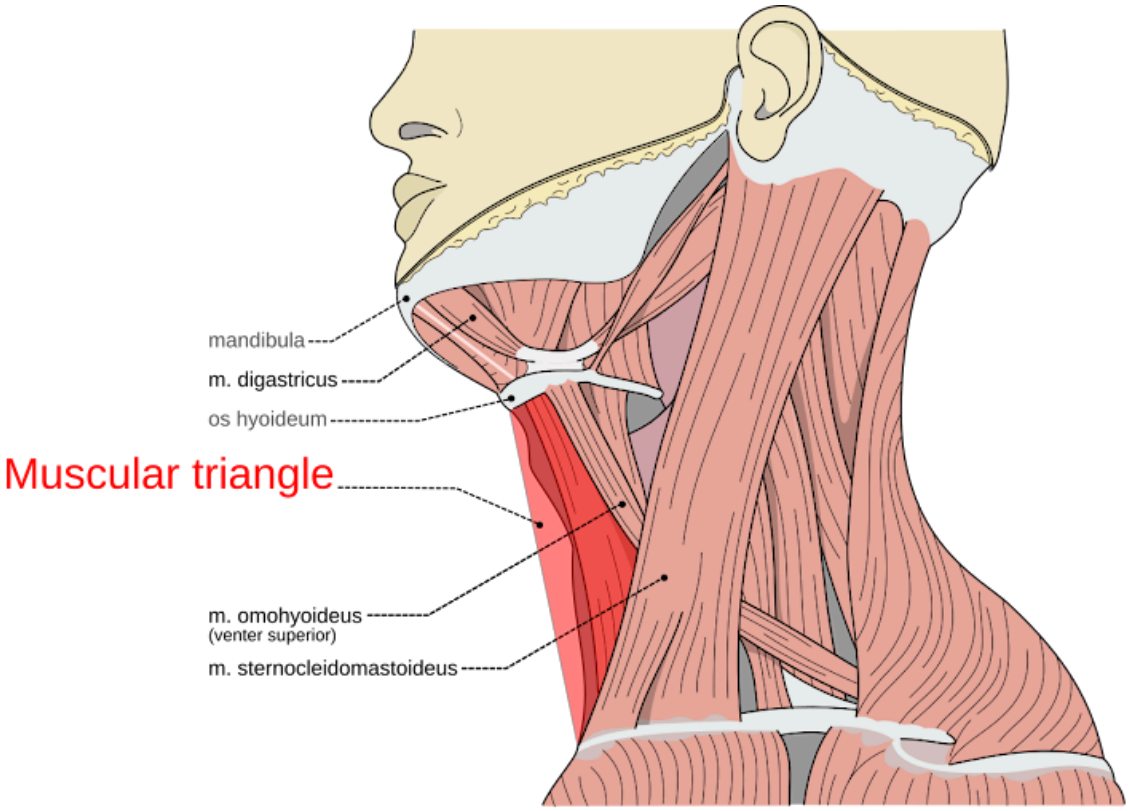

- ○ A.The Transverse cervical Nerve
- ○ B.The Greater Auricular Nerve
- ○ C.The Vagus Nerve
- ○ D.The Cranial Accessory Nerve
- ◉ E.The Spinal Accessory Nerve ✓

✓ Q10.The Picture shows one of the membranes covering the Brain. What is the name of the artery which is seen on the lateral surface 5/5

- ○ A.The Anterior Cerebral Artery
- ◉ B.The Middle Meningeal Artery ✓
- ○ C.The Middle Cerebral Artery
- ○ D.The Internal Carotid Artery
- ○ E.The Vertebral Artery

This form was created inside of The University of Lusaka. - Contact form owner

Does this form look suspicious? Report

Google Forms

CNS Anatomy & Histology Quiz — Correct Answers

Q1. The picture in slide 1 shows the histology of which organ

Q1 The picture in slide 1 shows the histology of which organ — 5 points

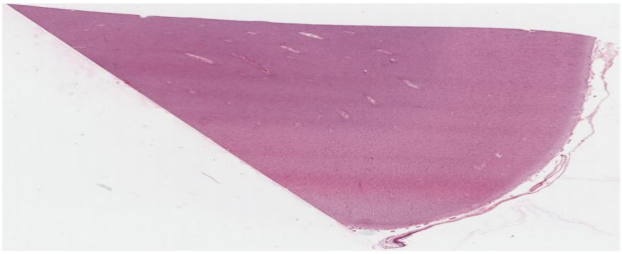

- A.The Cells of Betz
- B.The Cerebral Cortex
- C.The Cerebellum
- D.The Mid Brain
- E.The Diaencephalon

✔ Correct Answer: B. The Cerebral Cortex

Reason: The slide shows a solid triangular wedge of tissue at low magnification with a broad cortical band — characteristic of the cerebral cortex. Unlike the cerebellum, it lacks the tight finger-like folia pattern.

Q2. This is the histology of which CNS organ

Q2.This is the histology of which CNS organ — 5 points

- A.The Diaencephalon
- B.The Limbic System
- C.The Cerebellum
- D.The Purkinje Cells
- E.The Cerebrum

✔ Correct Answer: C. The Cerebellum

Reason: Highly folded folia with tree-like branching (arbor vitae) and uniform cortex-white matter pattern is unmistakably the cerebellum at low magnification.

Q3. The Slide in 3 shows

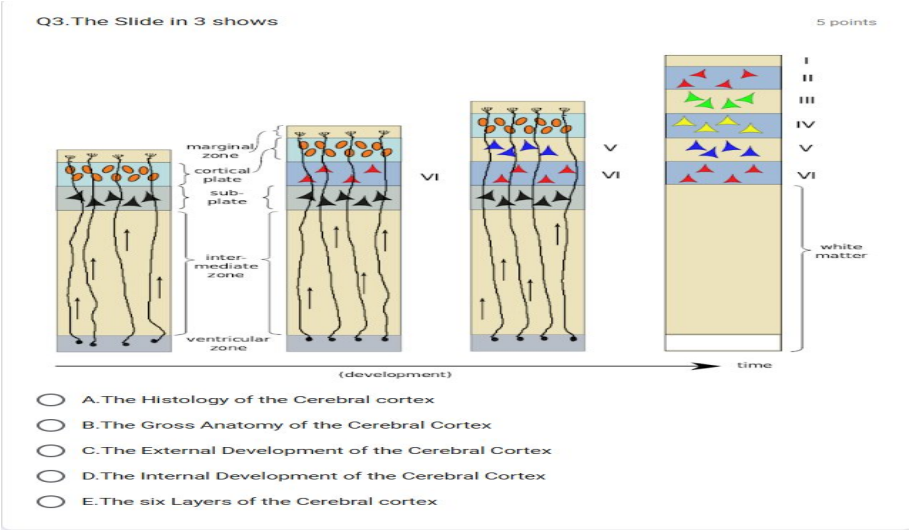

✔ Correct Answer: D. The Internal Development of the Cerebral Cortex

Reason: The diagram shows a developmental timeline with ventricular, intermediate, and marginal zones progressing to form cortical layers I–VI — depicting internal corticogenesis.

Q4. What is shown

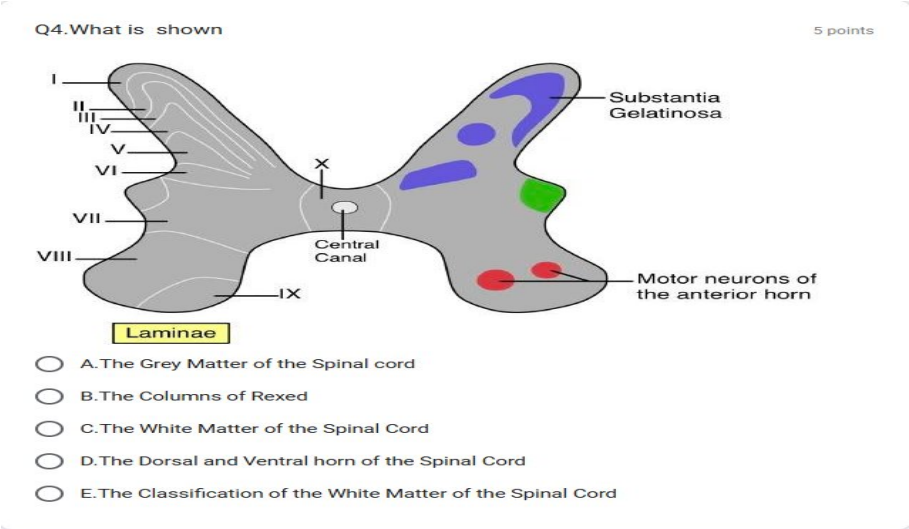

✔ Correct Answer: B. The Columns of Rexed

Reason: The diagram shows Laminae I–X of the spinal cord grey matter with Substantia Gelatinosa and motor neurons labelled — this is the Rexed Laminae classification.

Q5. The condition shown is a failure of which stage of development of the Neural Tube

Q5.The condition shown in the slides is a failure of which stage of development of the Neural Tube

5 points

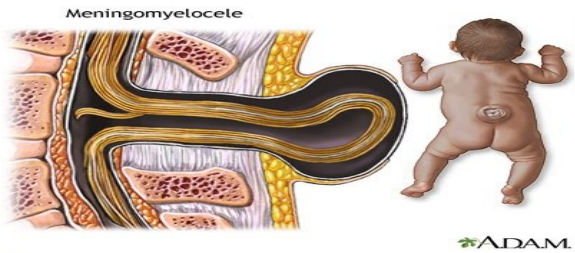

- (●) A. Formation of the Neural Plate
- ( ) B. Formation of the Neural Fold
- ( ) C. Formation od the Neural Groove
- ( ) D. Cranial Closure
- ( ) E. Caudal Closure

Clear selection

✔ Correct Answer: E. Caudal Closure

Reason: Meningomyelocele is a lumbar/sacral spinal defect. Failure of caudal neural tube closure causes spina bifida spectrum. Cranial closure failure causes anencephaly.

Q6. What is shown in the slide in 6

Q6.What is shown in the slide in 6

5 points

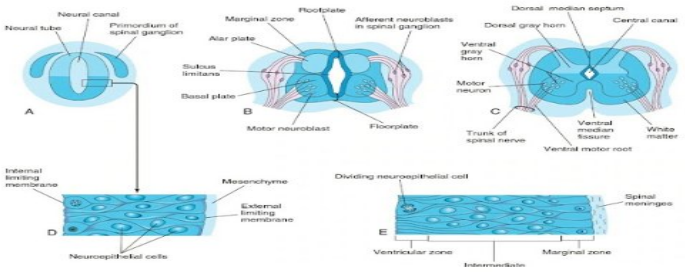

- ( ) A.The Internal development of the Spinal Cord
- ( ) B.The Three layer of the Internal Spinal Cord
- ( ) C.The External and Internal development of the Spinal Cord
- ( ) D.The formation of the Motor and Sensory parts of the Spinal Cord
- ( ) E.The Internal development (Grey ,White Matter & Ependymal lining) and also functional development into motor and sensory areas

✔ Correct Answer: C. The External and Internal development of the Spinal Cord

Reason: The multi-panel diagram shows both external morphological changes and internal zone development (ventricular, intermediate, marginal zones) alongside alar/basal plate functional division.

Q7. What is shown

Q7.What is shown

5 points

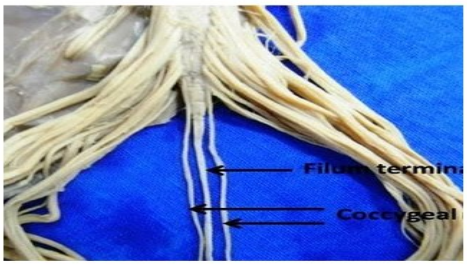

- A.The commencement of the Spinal Cord
- B.The Cauda Equina
- C.The Conus Medullaris
- D.The Gross anatomy of the Spinal Cord
- E.The termination of the Spinal Cord

Clear selection

✔ Correct Answer: E. The Termination of the Spinal Cord

Reason: The image shows the terminal end of the spinal cord with the filum terminale and coccygeal nerve roots visible — representing the termination of the spinal cord.

Q8. The Cells shown responsible for myelination in the Spinal Cord are

Q8.The Cells shown in the slide 8 responsible for myelination in the Spinal Cord are

5 points

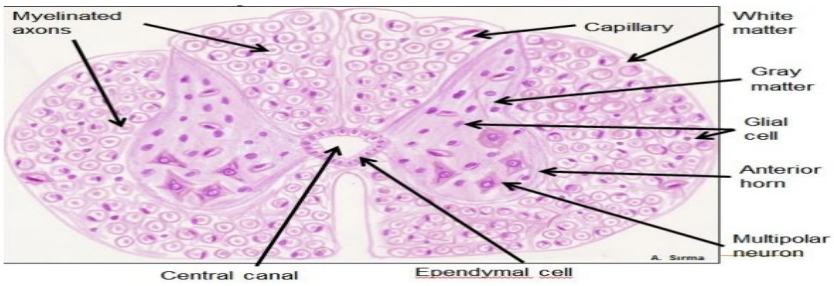

- A.The Glial Cells
- B.The Astrocytes
- C.The Oligodendrocytes
- D.The Ependymal Cells
- E.The Betz cells

Clear selection

✔ Correct Answer: C. The Oligodendrocytes

Reason: Oligodendrocytes are the CNS cells that produce myelin sheaths around axons. One oligodendrocyte can myelinate up to 50 axons. (Schwann cells myelinate the PNS.)

Q9. What is the name of the large foramen of the Skull shown?

Q9.What is the name of the large foramen of the Skull shown? 5 points

- A.The Foramen Rotundum
- B.The Foramen Lacerum
- C.The Foramen Magnum
- D.The Foramen Spinosum
- E.The Foramen Ovale

Clear selection

✔ Correct Answer: C. The Foramen Magnum

Reason: The largest foramen in the skull, located in the occipital bone, transmitting the brainstem-spinal cord transition and vertebral arteries.

Q10. The first ligament to be traversed in the procedure shown is

Q10.The first ligament to be traversed in the procedure shown is 5 points

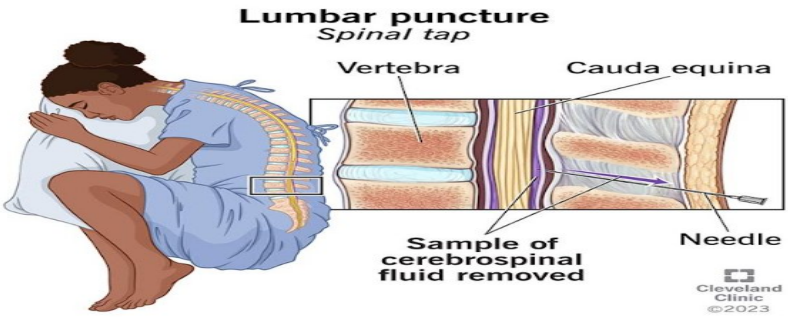

- A.The Ligamentum Flavum
- B.The Scarpa's fascia
- C.The Interspinous Ligament
- D.The Supraspinous Ligament
- E.The Posterior Longitudinal Ligament

✔ Correct Answer: D. The Supraspinous Ligament

Reason: In lumbar puncture, the needle passes: skin → subcutaneous fat → Supraspinous ligament (FIRST ligament) → Interspinous ligament → Ligamentum flavum → epidural space → dura → arachnoid → subarachnoid space (CSF).