Name: PRATYAKSH

Age: 25

Gender: Female

HR	: 194 bpm	P/QRS/T	: 46/32/-7°
PR	: 70 ms	RV5/SV1	: 3.389 mV/-3.497 mV
QRS	: 99 ms	RV5+SV1	: 6.887 mV
RR	: 309 ms	QTCF	: 198 ms
QT	: 180 ms	ST	: 0 ms
QTc	: 366 ms		

25.0 mm/s 0.5-150Hz AC : 50Hz 10.0 mm/mV

DECK MOUNT

Date: 2026-02-26

Time: 17:47:14

Org: Deckmount

Phone No: 5684768946

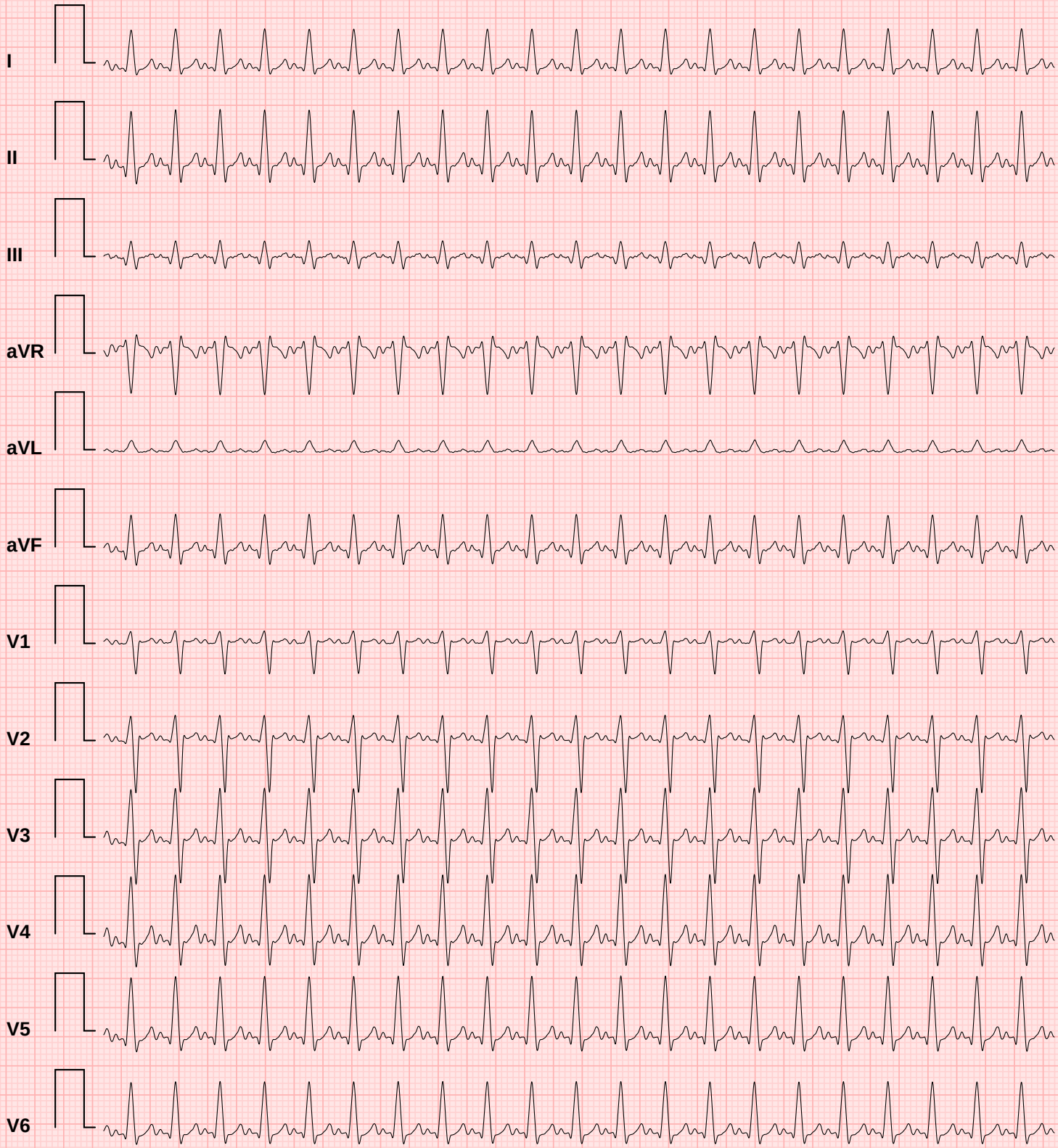

Doctor Name: RAM

Doctor Sign:

✦ CONCLUSION ✦

1. Extreme Tachycardia
2. Short PR interval
3. Normal QRS duration
4. Normal QTc interval
5. Low HRV