Name: PRATYAKSH

Age: 25

Gender: Female

HR	: 120 bpm	P/QRS/T	: 24/-133/-11°
PR	: 158 ms	RV5/SV1	: 0.643 mV/-0.020 mV
QRS	: 93 ms	RV5+SV1	: 0.663 mV
RR	: 500 ms	QTCF	: 318 ms
QT	: 283 ms	ST	: 0 ms
QTc	: 407 ms		

25.0 mm/s 0.5-150Hz AC : 50Hz 10.0 mm/mV

DECK MOUNT

Date: 2026-02-28

Time: 17:17:01

Org: Deckmount

Phone No: 5684768946

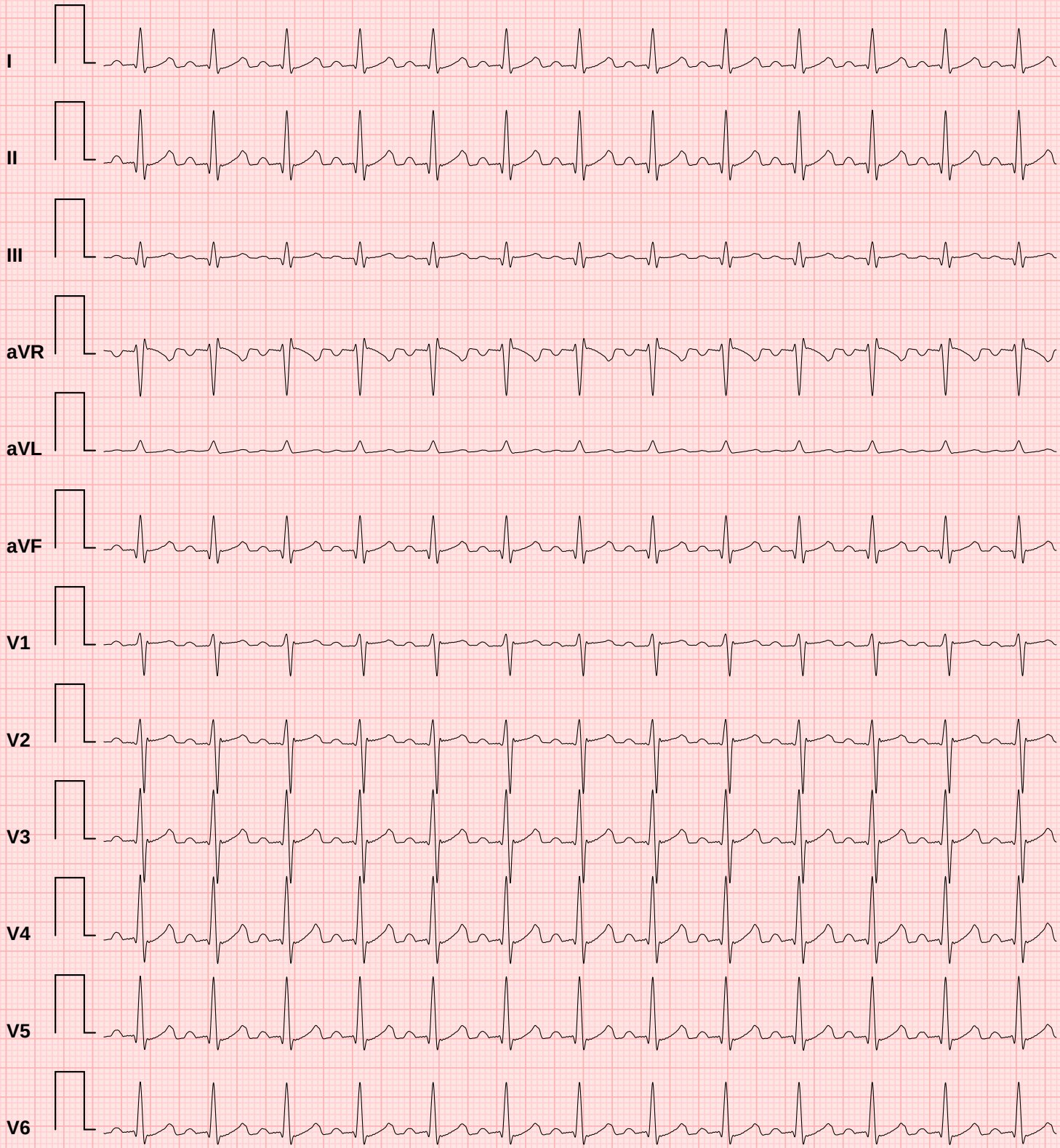

Doctor Name: RAM

Doctor Sign:

✦ CONCLUSION ✦

1. Tachycardia detected
2. Normal PR interval
3. Normal QRS duration
4. Normal QTc interval
5. Low HRV