Name: PRATYAKSH

Age: 25

Gender: Female

HR : 120 bpm
PR : 168 ms
QRS : 93 ms
RR : 500 ms
QT : 296 ms
QTc : 419 ms

P/QRS/T : 42/69/-143°
RV5/SV1 : 0.987 mV/-3.795 mV
RV5+SV1 : 4.782 mV
QTCF : 373 ms
ST : 0 ms
25.0 mm/s 0.5-150Hz AC : 50Hz 10.0 mm/mV

DECK MOUNT

Date: 2026-02-28
Time: 17:40:36
Org: Deckmount
Phone No: 5684768946

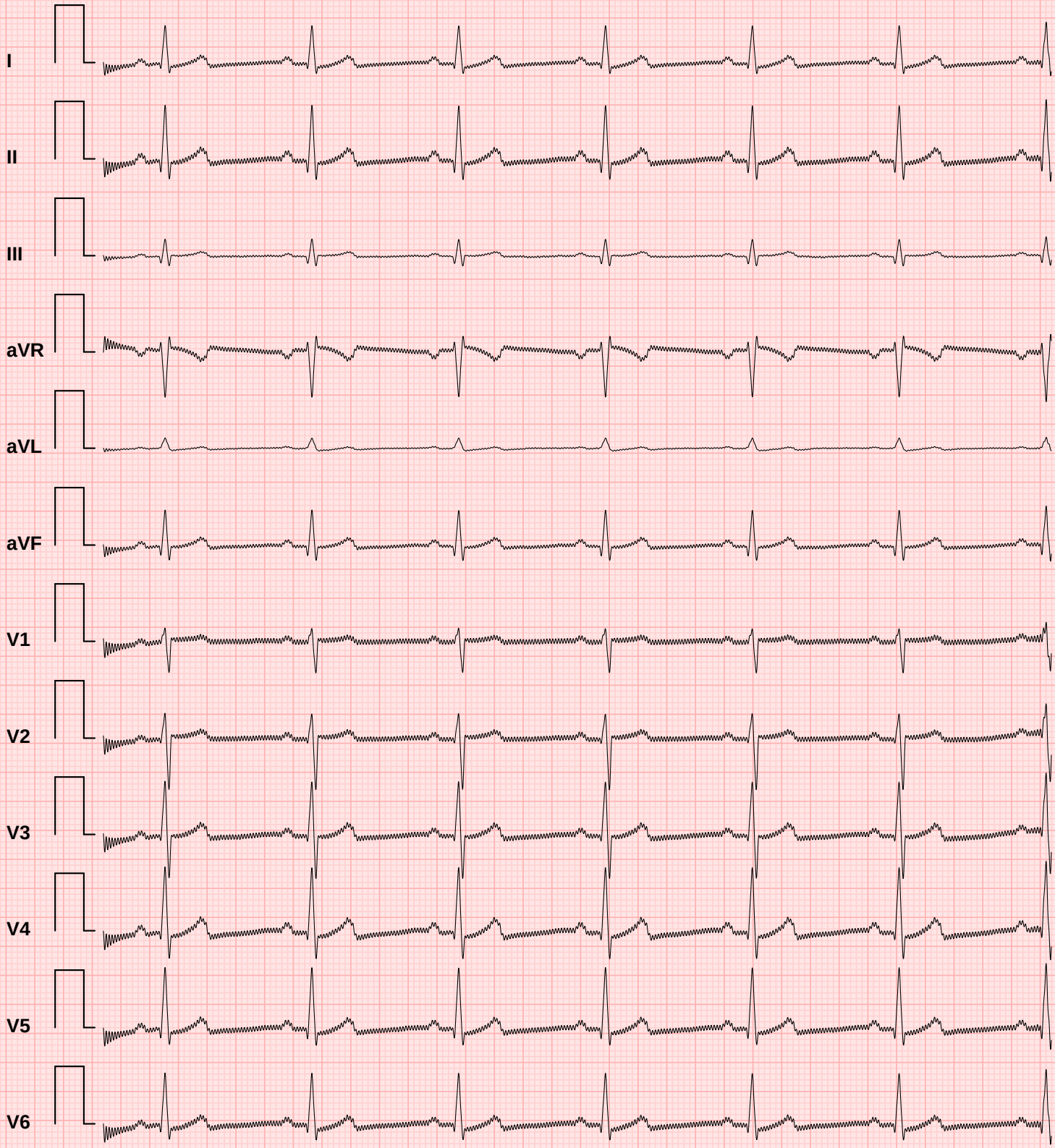

Doctor Name: RAM

Doctor Sign:

✦ CONCLUSION ✦

1. Tachycardia detected
2. Normal PR interval
3. Normal QRS duration
4. Normal QTc interval
5. Moderate HRV