Name: PRATYAKSH

Age: 25

Gender: Female

HR : 55 bpm
PR : 214 ms
QRS : 92 ms
RR : 1090 ms
QT : 438 ms
QTc : 420 ms

P/QRS/T : 43/69/-145°
RV5/SV1 : 0.899 mV/-2.748 mV
RV5+SV1 : 3.646 mV
QTCF : 438 ms
ST : 0 ms
25.0 mm/s 0.5-150Hz AC : 50Hz 10.0 mm/mV

DECK MOUNT

Date: 2026-02-28
Time: 18:24:53
Org: Deckmount
Phone No: 5684768946

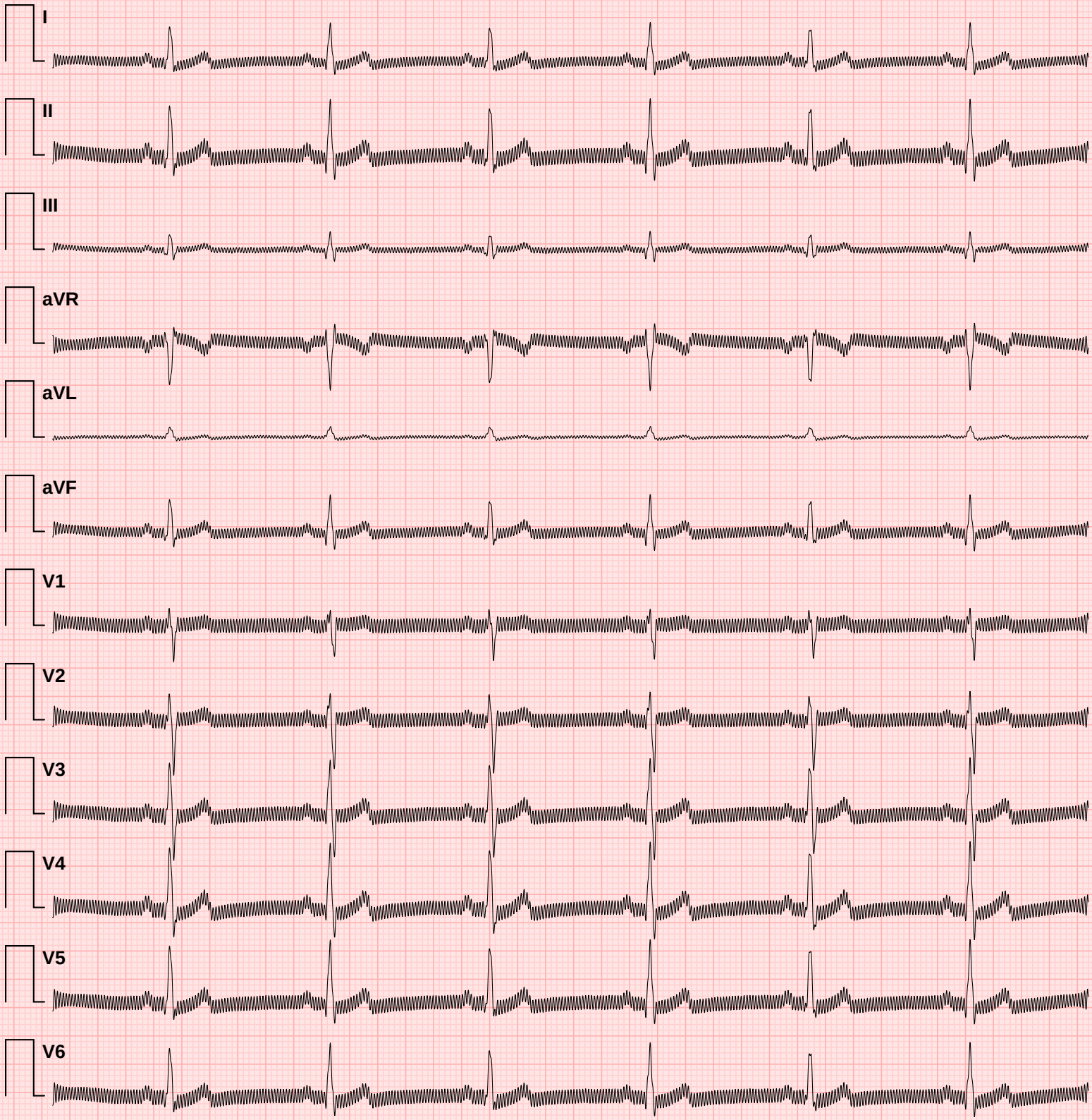

Doctor Name: RAM

Doctor Sign:

✦ CONCLUSION ✦

1. Bradycardia detected
2. Prolonged PR interval
3. Normal QRS duration
4. Normal QTc interval
5. Good heart rate variability