Name: PRATYAKSH

Age: 25

Gender: Female

HR	: 60 bpm	P/QRS/T	: 9/63/-142°
PR	: 167 ms	RV5/SV1	: 0.463 mV/-0.400 mV
QRS	: 79 ms	RV5+SV1	: 0.863 mV
RR	: 1000 ms	QTCF	: 421 ms
QT	: 419 ms	ST	: 0 ms
QTc	: 417 ms		

25.0 mm/s 0.5-150Hz AC : 50Hz 10.0 mm/mV

DECK MOUNT

Date: 2026-02-28

Time: 19:17:15

Org: Deckmount

Phone No: 5684768946

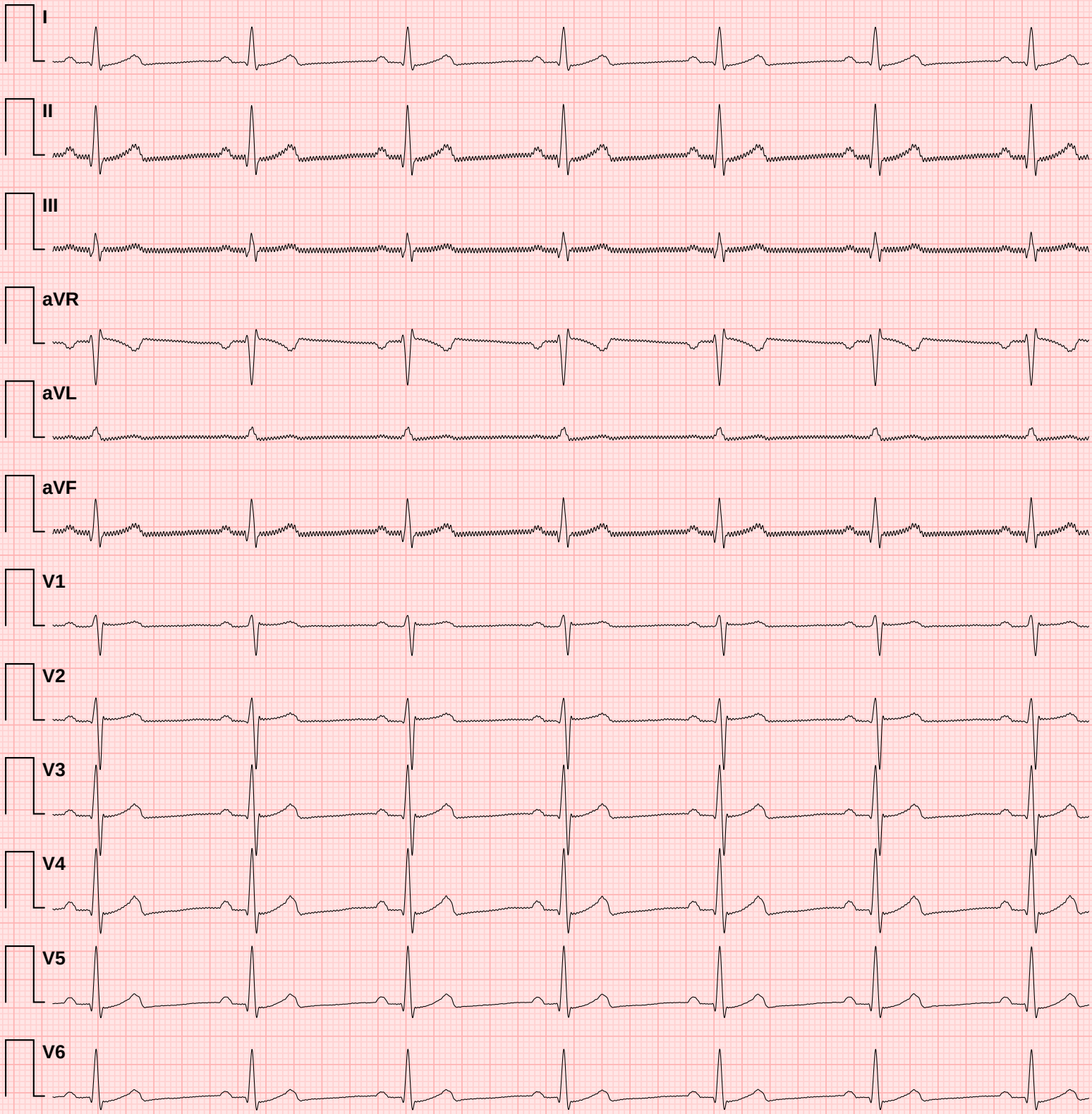

Doctor Name: RAM

Doctor Sign:

✦ CONCLUSION ✦

1. Bradycardia detected
2. Normal PR interval
3. Borderline QRS duration
4. Normal QTc interval
5. Good heart rate variability