Name: PRATYAKSH

Age: 25

Gender: Female

HR : 59 bpm

PR : 180 ms

QRS : 102 ms

RR : 1016 ms

QT : 421 ms

QTc : 416 ms

P/QRS/T : --/--/--°

RV5/SV1 : 1.031 mV/-0.554 mV

RV5+SV1 : 1.585 mV

QTCF : 421 ms (0.421 s)

ST : 0 ms

25.0 mm/s 0.5-150Hz AC : 50Hz 10.0 mm/mV

DECK MOUNT

Date: 28/02/2026

Time: 18:27:32

Org: Deckmount

Phone No: 5684768946

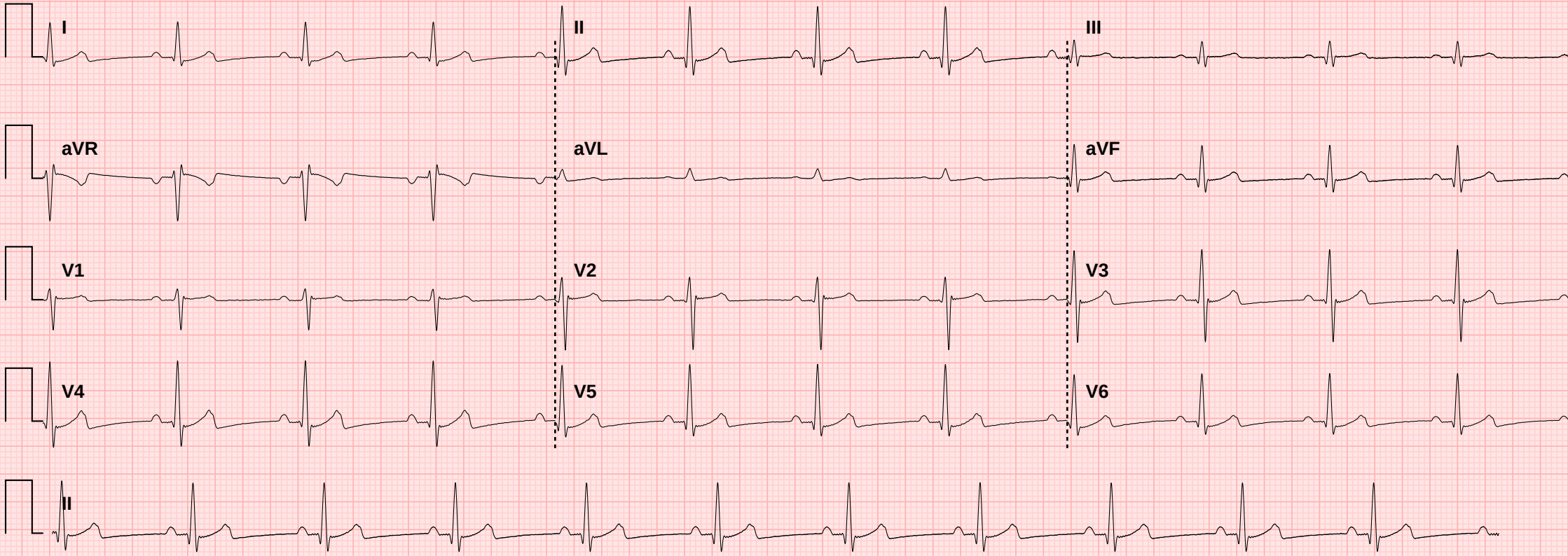

Doctor Name: RAM

Doctor Sign:

✦ CONCLUSION ✦

1. Bradycardia detected
2. Normal PR interval
3. Normal QRS duration
4. Normal QTc interval
5. Good heart rate variability