Name: PRATYAKSH

Age: 25

Gender: Female

HR	: 120 bpm	P/QRS/T	: --/--/--°
PR	: 155 ms	RV5/SV1	: 1.203 mV/-0.289 mV
QRS	: 83 ms	RV5+SV1	: 1.492 mV
RR	: 500 ms	QTCF	: 371 ms (0.371 s)
QT	: 295 ms	ST	: 0 ms
QTc	: 422 ms		

25.0 mm/s 0.5-150Hz AC : 50Hz 10.0 mm/mV

DECK MOUNT

Date: 28/02/2026

Time: 17:41:50

Org: Deckmount

Phone No: 5684768946

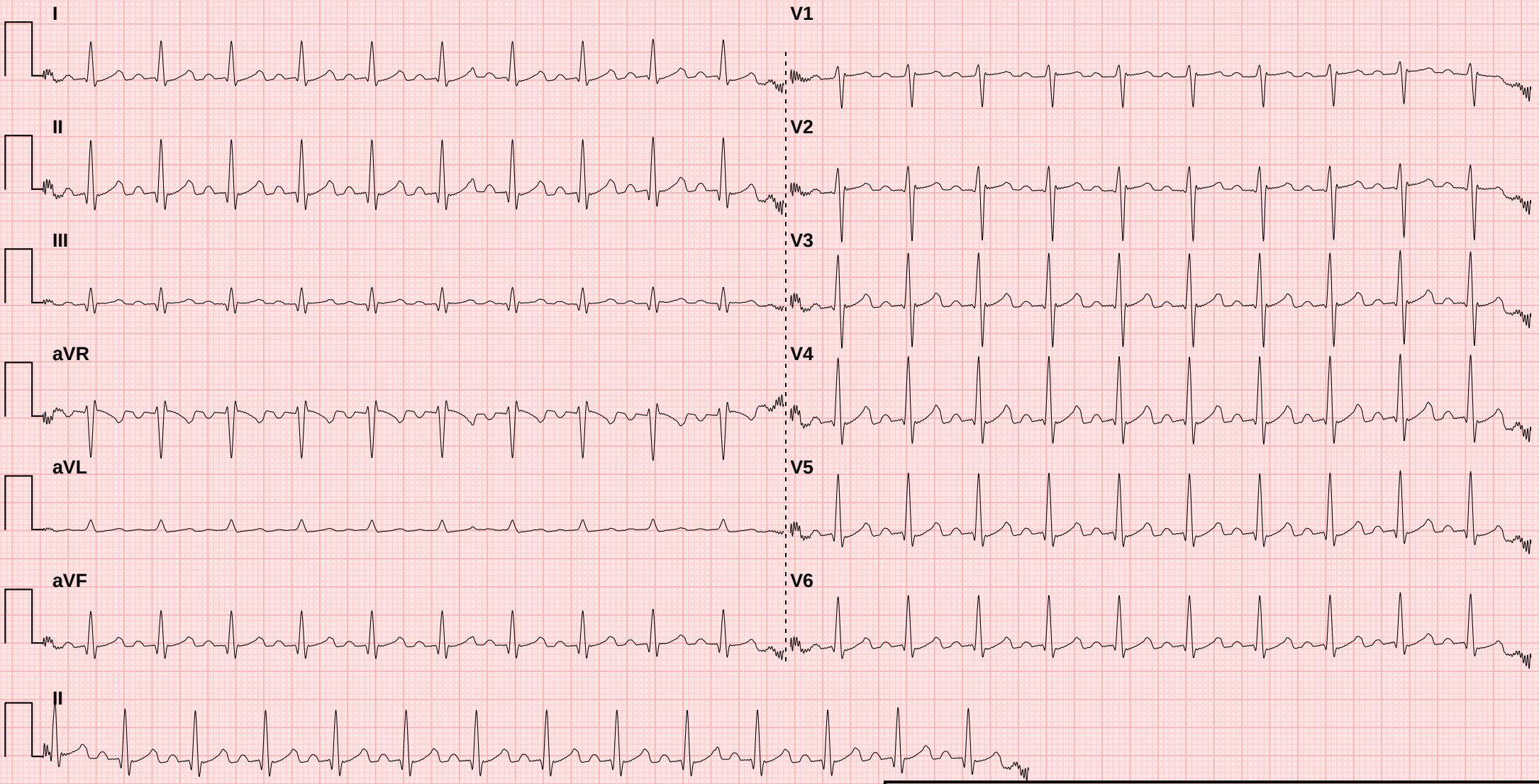

Doctor Name: RAM

Doctor Sign:

✦ CONCLUSION ✦

1. Tachycardia detected
2. Normal PR interval
3. Normal QRS duration
4. Normal QTc interval
5. Good heart rate variability