Name: PRATYAKSH

Age: 25

Gender: Female

HR : 149 bpm
PR : 130 ms
QRS : 91 ms
RR : 402 ms
QT : 266 ms
QTc : 420 ms

P/QRS/T : -75/-138/-141°
RV5/SV1 : 0.761 mV/-0.287 mV
RV5+SV1 : 1.048 mV
QTCF : 266 ms
ST : 0 ms
25.0 mm/s 0.5-150Hz AC : 50Hz 10.0 mm/mV

DECK MOUNT

Date: 2026-02-28
Time: 20:17:48
Org: Deckmount
Phone No: 5684768946

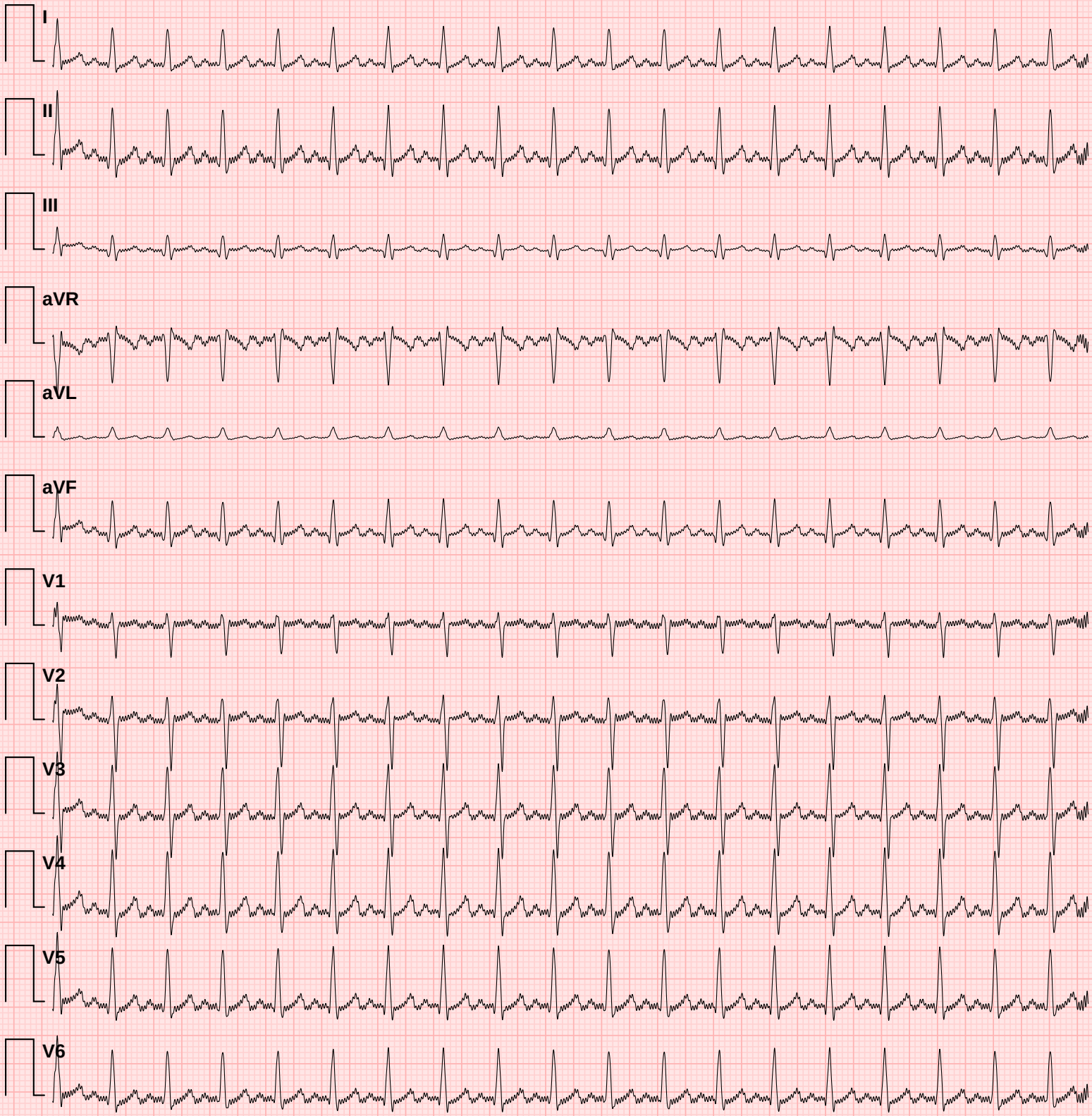

Doctor Name: RAM

Doctor Sign:

✦ CONCLUSION ✦

1. Tachycardia detected
2. Normal PR interval
3. Normal QRS duration
4. Normal QTc interval
5. Low HRV