Name: PRATYAKSH

Age: 25

Gender: Female

HR	: 131 bpm	P/QRS/T	: -56/170/36°
PR	: 109 ms	RV5/SV1	: 0.626 mV/-0.519 mV
QRS	: 90 ms	RV5+SV1	: 1.145 mV
RR	: 458 ms	QTCF	: 382 ms
QT	: 282 ms	ST	: 0 ms
QTc	: 340 ms		

25.0 mm/s 0.5-150Hz AC : 50Hz 10.0 mm/mV

DECK MOUNT

Date: 2026-02-28

Time: 20:20:01

Org: Deckmount

Phone No: 5684768946

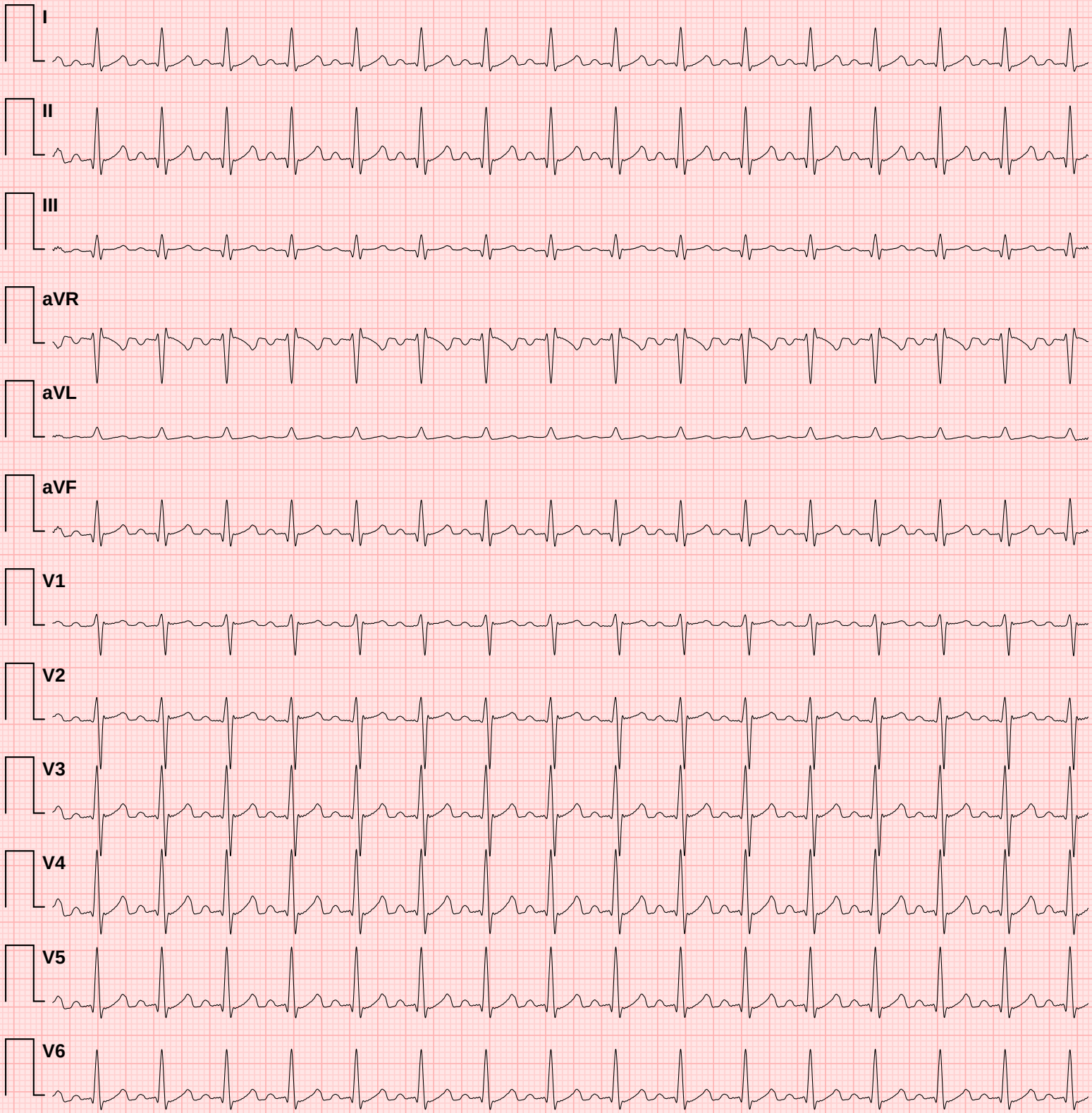

Doctor Name: RAM

Doctor Sign:

✦ CONCLUSION ✦

1. Tachycardia detected
2. Short PR interval
3. Normal QRS duration
4. Normal QTc interval
5. Low HRV