Name: PRATYAKSH

Age: 25

Gender: Female

HR	: 0 bpm	P/QRS/T	: -143/-153/37°
PR	: 59 ms	RV5/SV1	: 0.672 mV/-0.033 mV
QRS	: 97 ms	RV5+SV1	: 0.705 mV
RR	: 0 ms	QTCF	: 295 ms
QT	: 173 ms	ST	: 0 ms
QTc	: 362 ms		

25.0 mm/s 0.5-150Hz AC : 50Hz 10.0 mm/mV

DECK MOUNT

Date: 2026-02-28

Time: 20:32:07

Org: Deckmount

Phone No: 5684768946

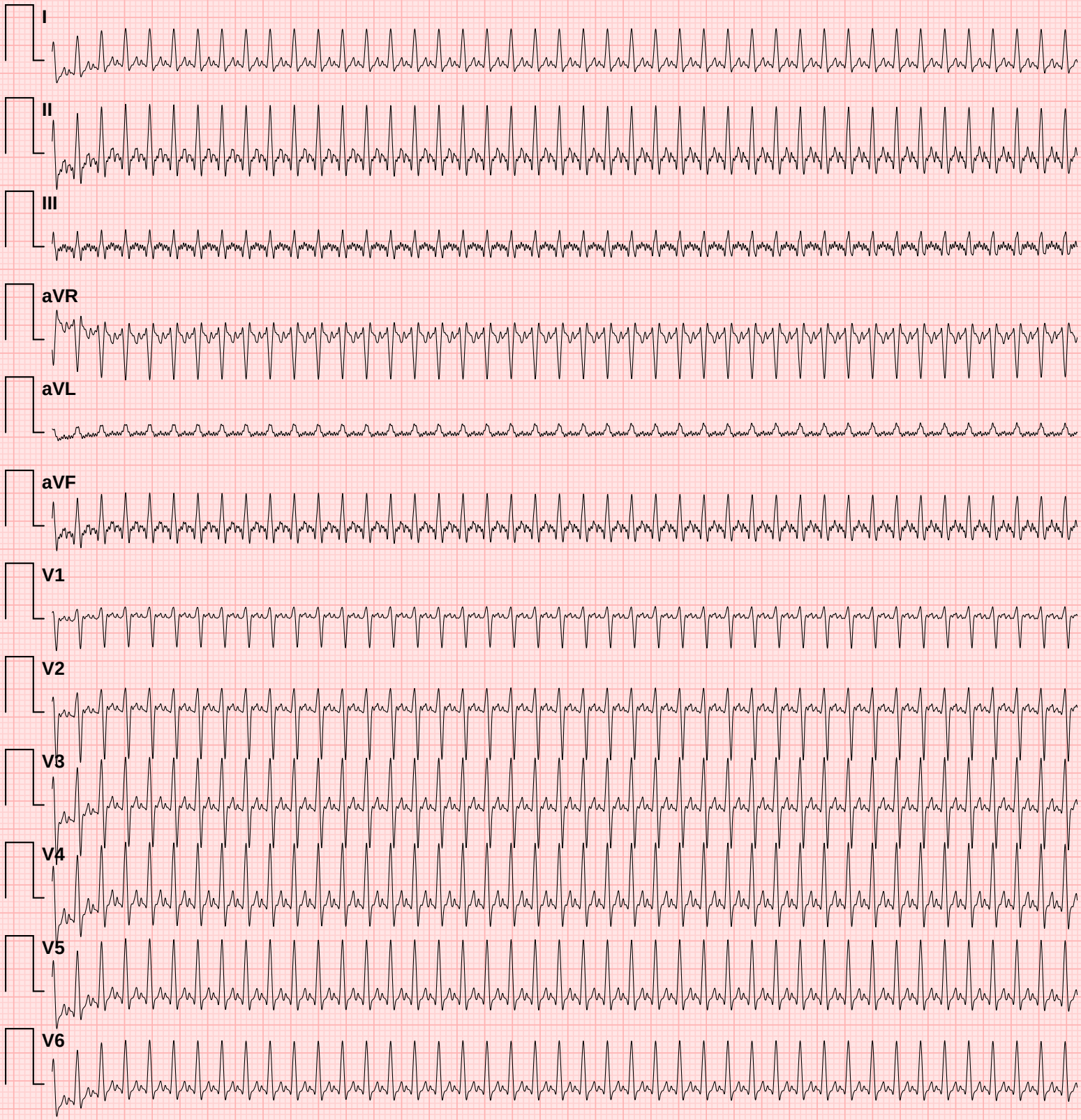

Doctor Name: RAM

Doctor Sign:

✦ CONCLUSION ✦

1. Extreme Tachycardia
2. Short PR interval
3. Normal QRS duration
4. Normal QTc interval
5. Low HRV