Name: PRATYAKSH

Age: 25

Gender: Female

HR	: 0 bpm	P/QRS/T	: 21/-150/-150°
PR	: 54 ms	RV5/SV1	: 0.663 mV/-0.038 mV
QRS	: 88 ms	RV5+SV1	: 0.700 mV
RR	: 0 ms	QTCF	: --
QT	: 157 ms	ST	: 0 ms
QTc	: 344 ms		

25.0 mm/s 0.5-150Hz AC : 50Hz 10.0 mm/mV

DECK MOUNT

Date: 2026-02-28

Time: 20:32:18

Org: Deckmount

Phone No: 5684768946

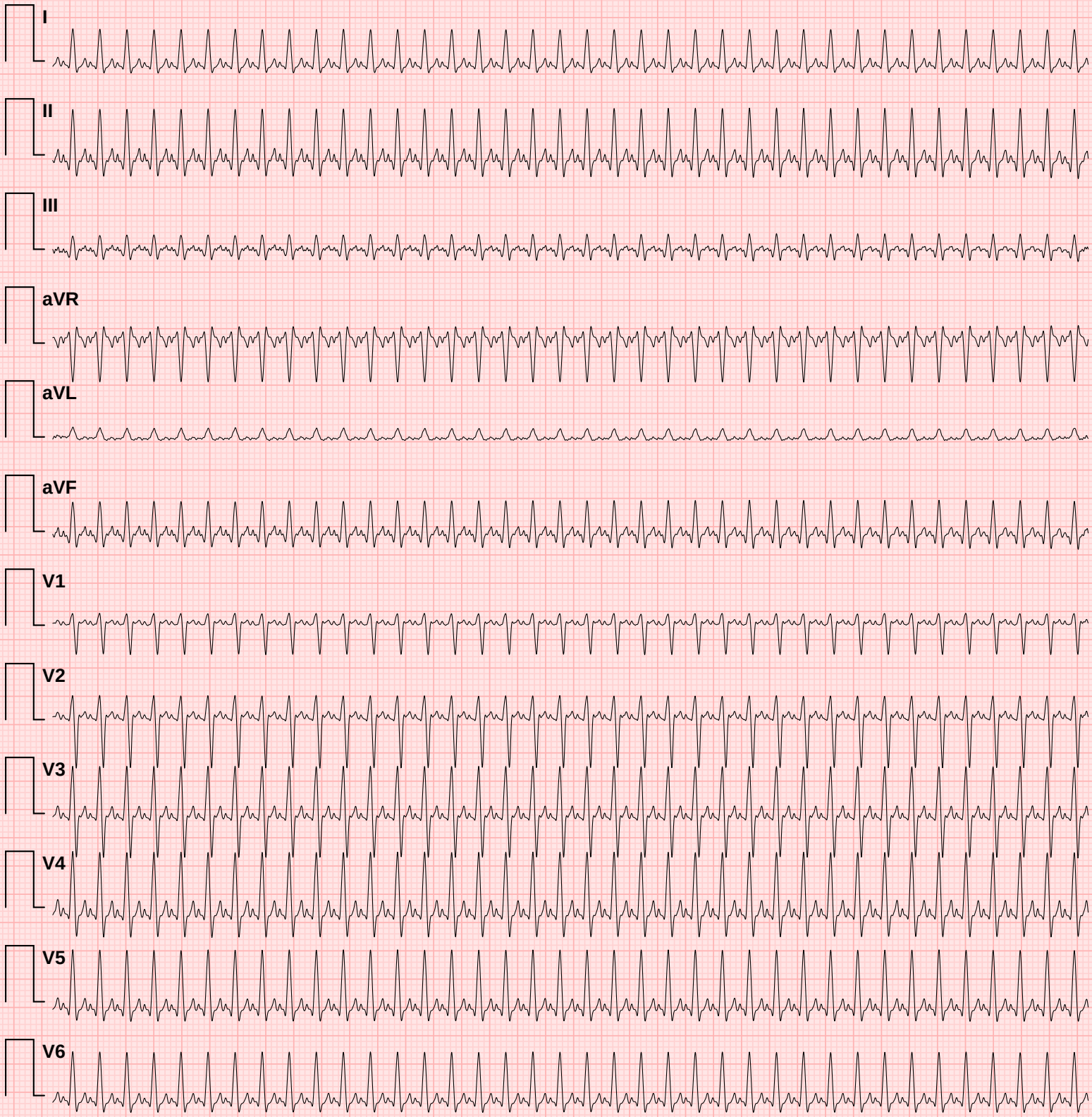

Doctor Name: RAM

Doctor Sign:

✦ CONCLUSION ✦

1. Extreme Tachycardia
2. Short PR interval
3. Normal QRS duration
4. Normal QTc interval
5. Low HRV