Name: PRATYAKSH

Age: 25

Gender: Female

HR : 299 bpm
PR : 54 ms
QRS : 93 ms
RR : 200 ms
QT : 154 ms
QTc : 336 ms

P/QRS/T : -159/-138/-140°
RV5/SV1 : 0.663 mV/-0.518 mV
RV5+SV1 : 1.181 mV
QTCF : 263 ms
ST : 0 ms
25.0 mm/s 0.5-150Hz AC : 50Hz 10.0 mm/mV

DECK MOUNT

Date: 2026-02-28
Time: 20:38:51
Org: Deckmount
Phone No: 5684768946

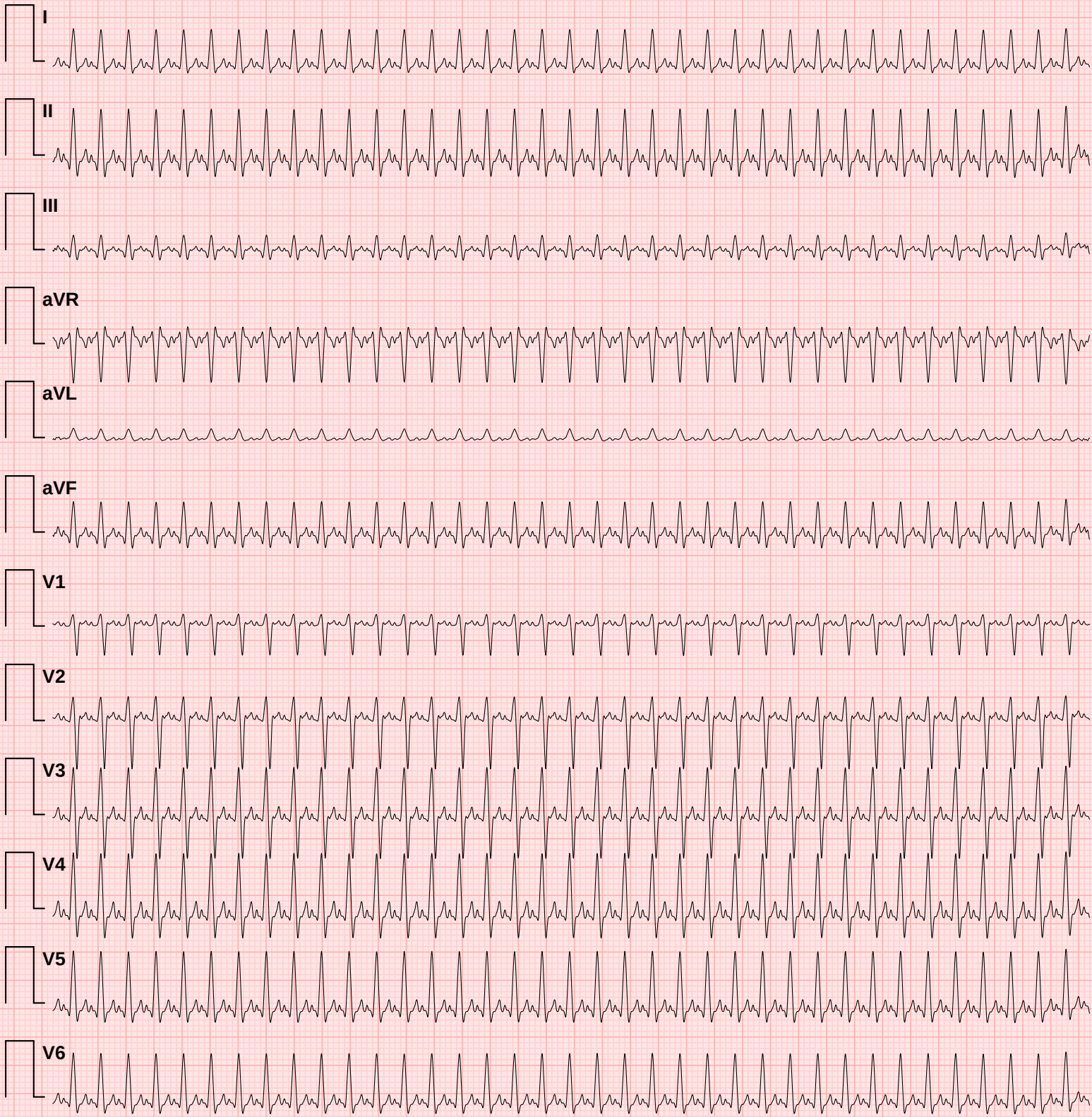

Doctor Name: RAM

Doctor Sign:

✦ CONCLUSION ✦

1. Extreme Tachycardia
2. Short PR interval
3. Normal QRS duration
4. Normal QTc interval