Name: PRATYAKSH

Age: 25

Gender: Female

HR : 30 bpm
PR : 262 ms
QRS : 95 ms
RR : 2000 ms
QT : 428 ms
QTc : 302 ms

P/QRS/T : -17/62/-141°
RV5/SV1 : 0.644 mV/-0.056 mV
RV5+SV1 : 0.700 mV
QTCF : 506 ms
ST : 0 ms
25.0 mm/s 0.5-150Hz AC : 50Hz 10.0 mm/mV

DECK MOUNT

Date: 2026-02-28
Time: 20:48:11
Org: Deckmount
Phone No: 5684768946

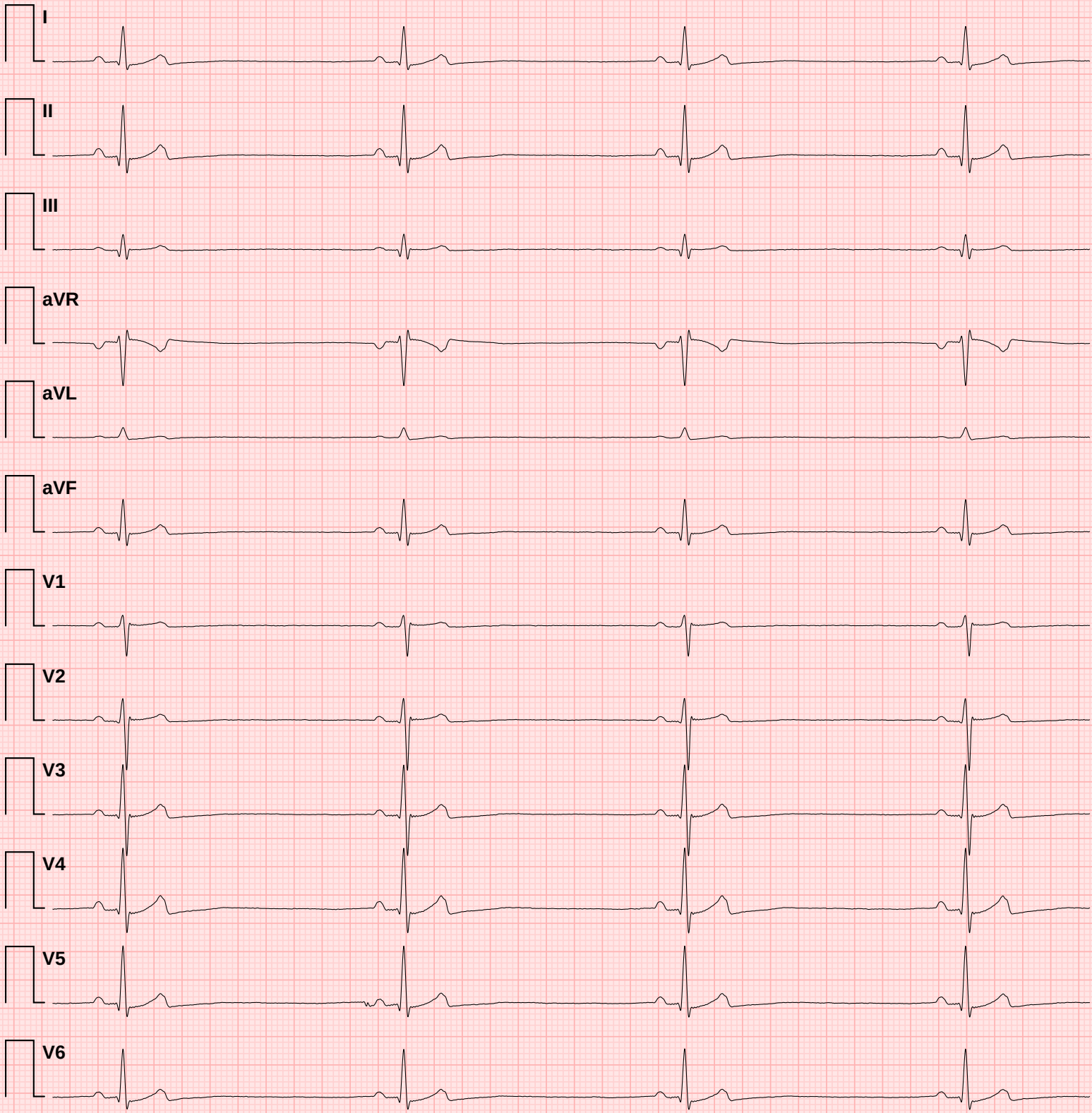

Doctor Name: RAM

Doctor Sign:

✦ CONCLUSION ✦

1. Severe Bradycardia
2. Prolonged PR interval
3. Normal QRS duration
4. Normal QTc interval
5. Good heart rate variability