Name: PRATYAKSH

Age: 25

Gender: Female

HR	: 46 bpm	P/QRS/T	: 13/88/-142°
PR	: 225 ms	RV5/SV1	: 0.642 mV/-0.493 mV
QRS	: 79 ms	RV5+SV1	: 1.135 mV
RR	: 1304 ms	QTCF	: 290 ms
QT	: 366 ms	ST	: 0 ms
QTc	: 318 ms		

25.0 mm/s 0.5-150Hz AC : 50Hz 10.0 mm/mV

DECK MOUNT

Date: 2026-02-28

Time: 20:50:43

Org: Deckmount

Phone No: 5684768946

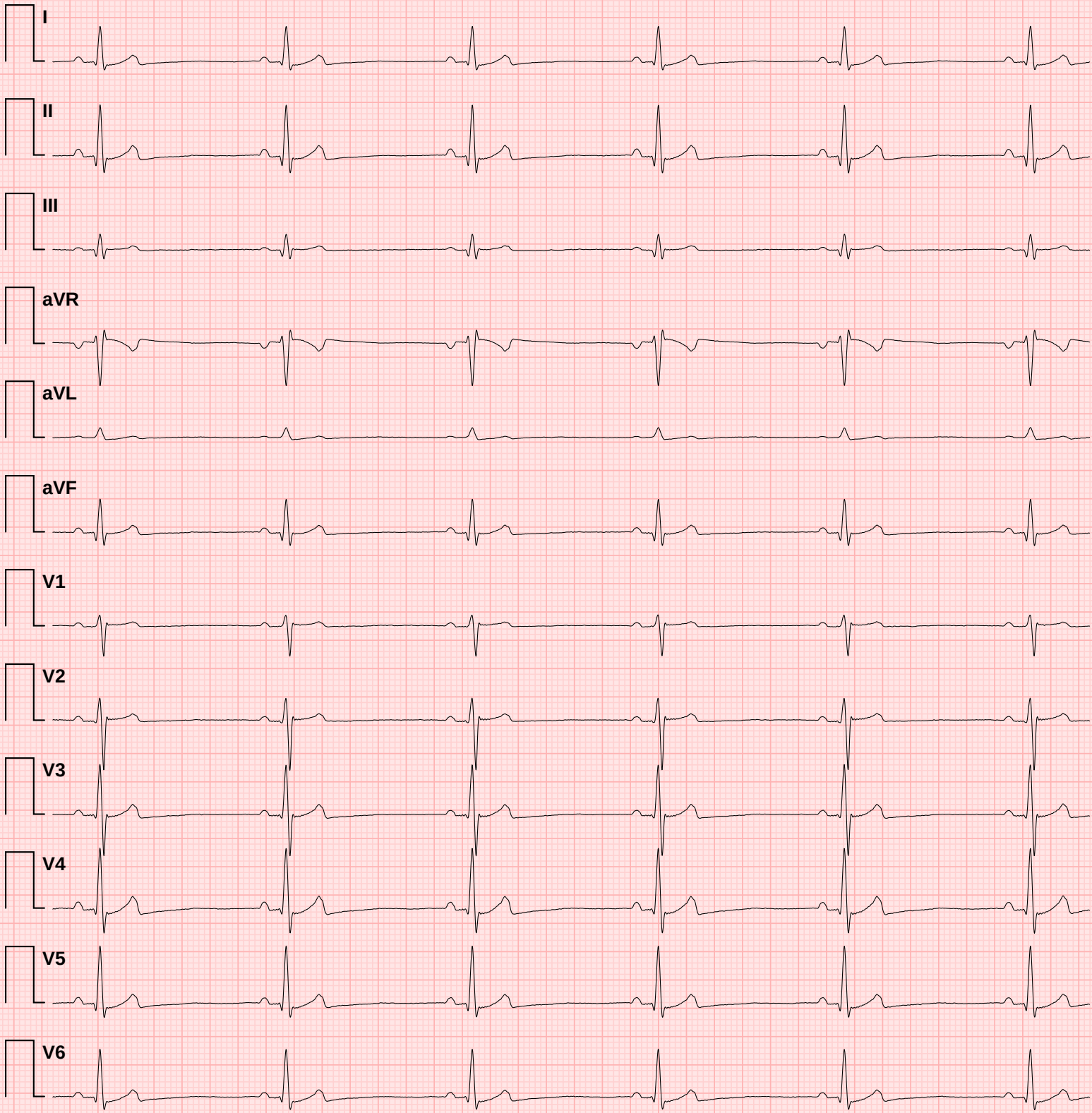

Doctor Name: RAM

Doctor Sign:

✦ CONCLUSION ✦

1. Bradycardia detected
2. Prolonged PR interval
3. Normal QRS duration
4. Normal QTc interval
5. Moderate HRV