Name: PRATYAKSH

Age: 25

Gender: Female

HR : 53 bpm
PR : 198 ms
QRS : 68 ms
RR : 1132 ms
QT : 318 ms
QTc : 302 ms

P/QRS/T : 32/91/-146°
RV5/SV1 : 0.646 mV/-0.492 mV
RV5+SV1 : 1.138 mV
QTCF : 291 ms
ST : 0 ms
25.0 mm/s 0.5-150Hz AC : 50Hz 10.0 mm/mV

DECK MOUNT

Date: 2026-02-28
Time: 20:50:59
Org: Deckmount
Phone No: 5684768946

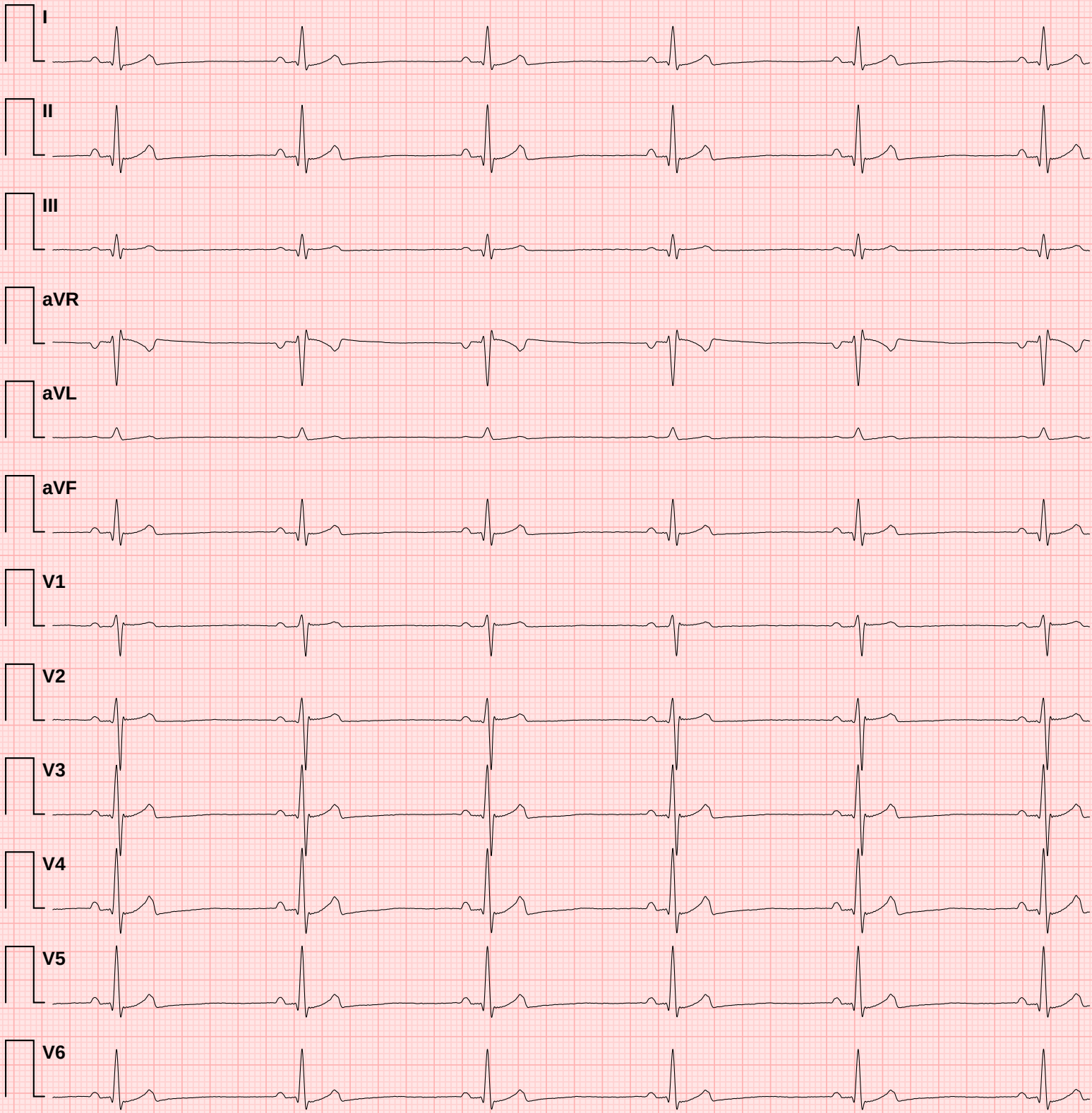

Doctor Name: RAM

Doctor Sign:

✦ CONCLUSION ✦

1. Bradycardia detected
2. Prolonged PR interval
3. Normal QRS duration
4. Normal QTc interval
5. Good heart rate variability