Name: PRATYAKSH

Age: 25

Gender: Female

HR : 46 bpm
PR : 264 ms
QRS : 96 ms
RR : 1304 ms
QT : 362 ms
QTc : 318 ms

P/QRS/T : 31/87/-142°
RV5/SV1 : 0.646 mV/-0.491 mV
RV5+SV1 : 1.138 mV
QTCF : 347 ms
ST : 0 ms
25.0 mm/s 0.5-150Hz AC : 50Hz 10.0 mm/mV

DECK MOUNT

Date: 2026-02-28
Time: 20:51:34
Org: Deckmount
Phone No: 5684768946

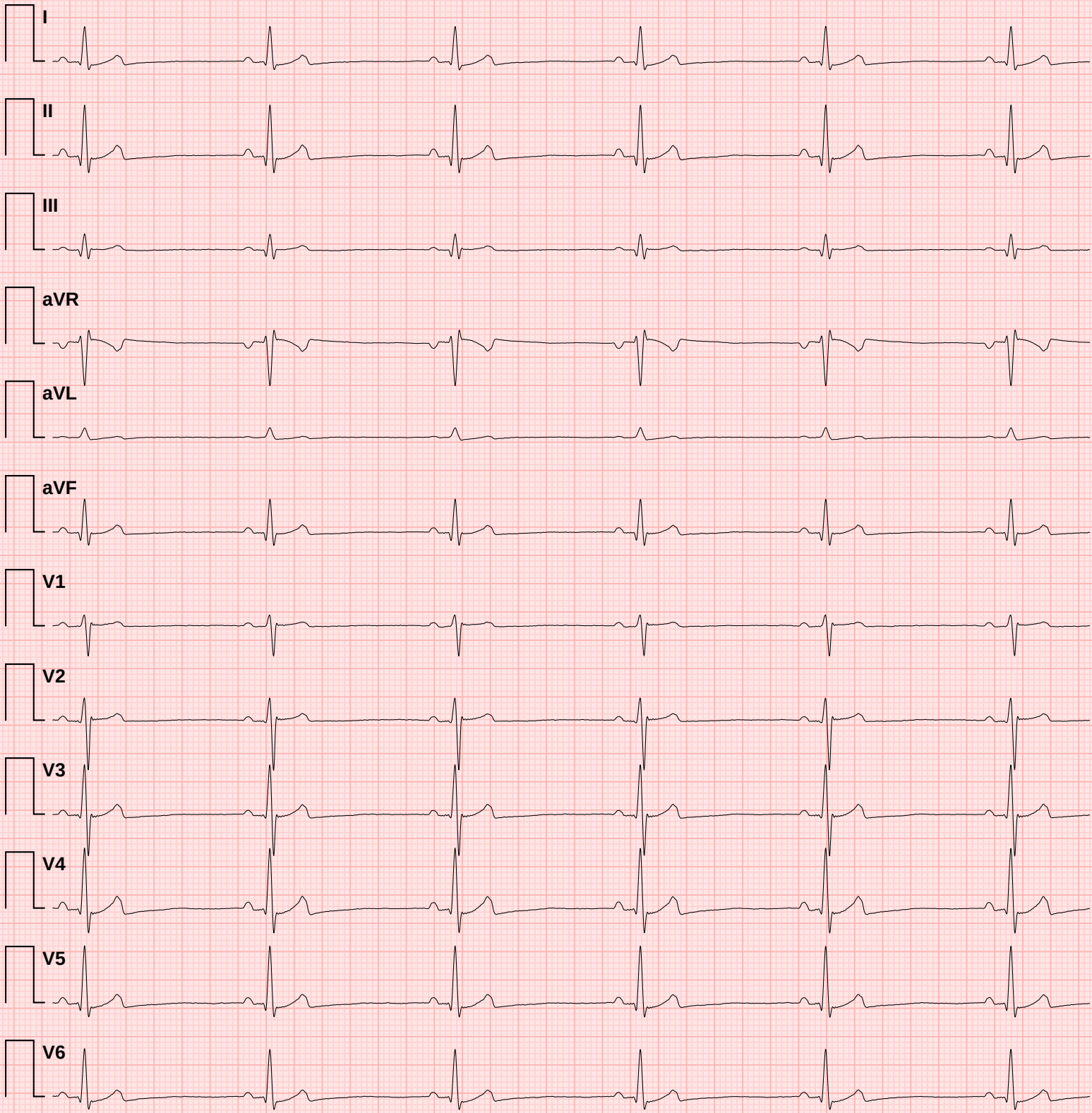

Doctor Name: RAM

Doctor Sign:

✦ CONCLUSION ✦

1. Bradycardia detected
2. Prolonged PR interval
3. Normal QRS duration
4. Normal QTc interval
5. Low HRV