Name: PRATYAKSH

Age: 25

Gender: Female

HR	: 51 bpm	P/QRS/T	: -47/100/-137°
PR	: 244 ms	RV5/SV1	: 0.646 mV/-0.491 mV
QRS	: 71 ms	RV5+SV1	: 1.137 mV
RR	: 1176 ms	QTCF	: 306 ms
QT	: 334 ms	ST	: 0 ms
QTc	: 311 ms		

25.0 mm/s 0.5-150Hz AC : 50Hz 10.0 mm/mV

DECK MOUNT

Date: 2026-02-28

Time: 20:51:49

Org: Deckmount

Phone No: 5684768946

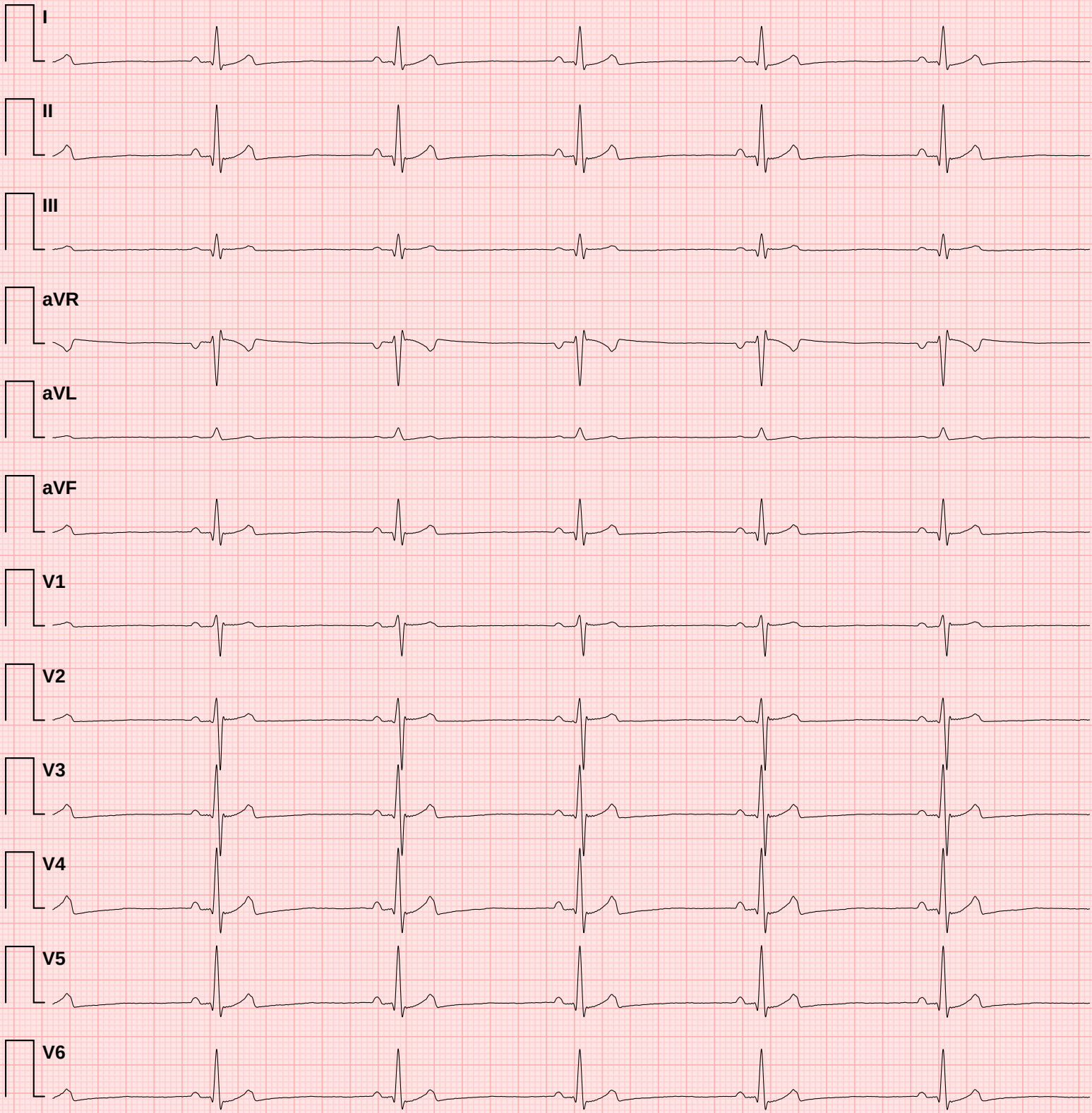

Doctor Name: RAM

Doctor Sign:

✦ CONCLUSION ✦

1. Bradycardia detected
2. Prolonged PR interval
3. Normal QRS duration
4. Normal QTc interval
5. Moderate HRV