Name: PRATYAKSH

Age: 25

Gender: Female

HR	: 46 bpm	P/QRS/T	: 32/95/-138°
PR	: 255 ms	RV5/SV1	: 0.644 mV/-0.495 mV
QRS	: 98 ms	RV5+SV1	: 1.139 mV
RR	: 1304 ms	QTCF	: 346 ms
QT	: 365 ms	ST	: 0 ms
QTc	: 318 ms		

25.0 mm/s 0.5-150Hz AC : 50Hz 10.0 mm/mV

DECK MOUNT

Date: 2026-02-28

Time: 20:52:18

Org: Deckmount

Phone No: 5684768946

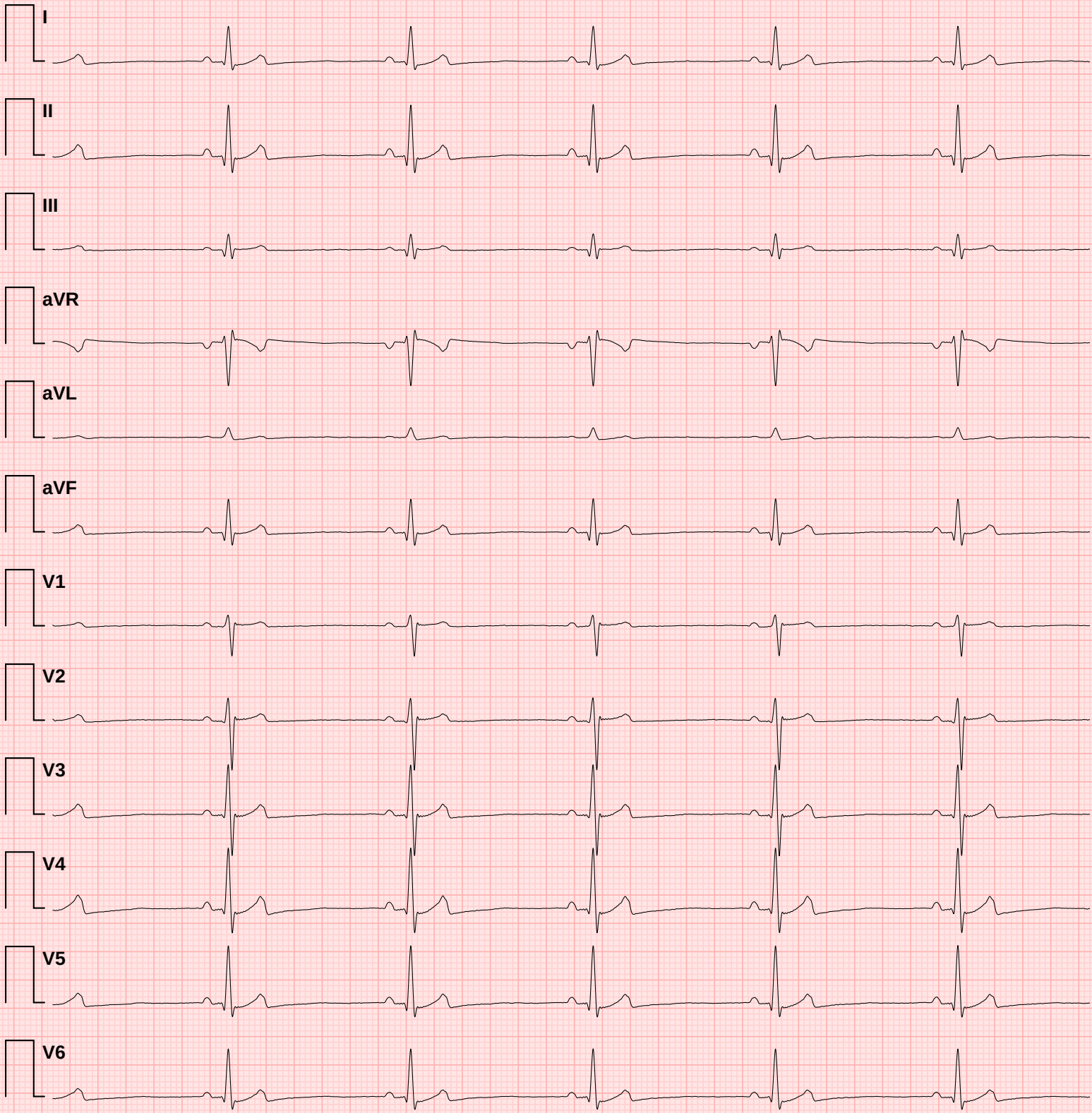

Doctor Name: RAM

Doctor Sign:

✦ CONCLUSION ✦

1. Bradycardia detected
2. Prolonged PR interval
3. Normal QRS duration
4. Normal QTc interval
5. Low HRV