(a) CT Axial Slice (z=96)

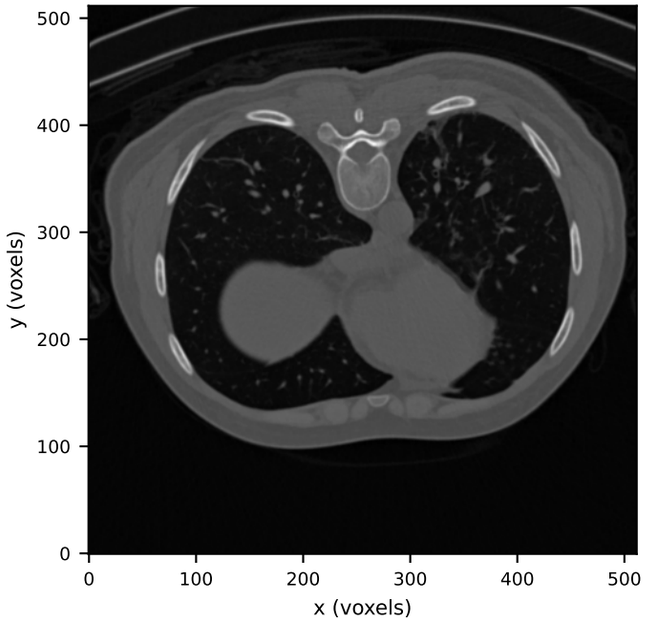

(b) Routed Tokens (k=8)

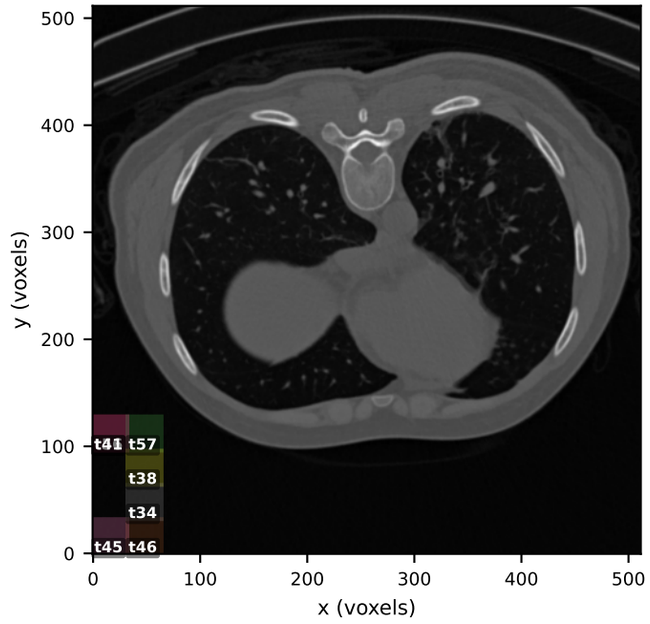

(c) Generated Output [Pass]

```
Generated Sentence:
──────────────────────────────────────
In the current examination, a pleural-
based, 20 mm diameter nodular density
increase area compatible with
consolidation was observed in the right
lung lower lobe superior segment.

──────────────────────────────────────
Anatomy: right lung
Token IDs: [56, 22, 57, 41, 38, 46, 45, 34]
Violations: None

Evidence Card:
  Cited tokens: 8
  Dominant side: right
  Same-side ratio: 1.00
  Laterality gate: right
  Depth gate: in_range
```

(d) CT Axial Slice (z=112)

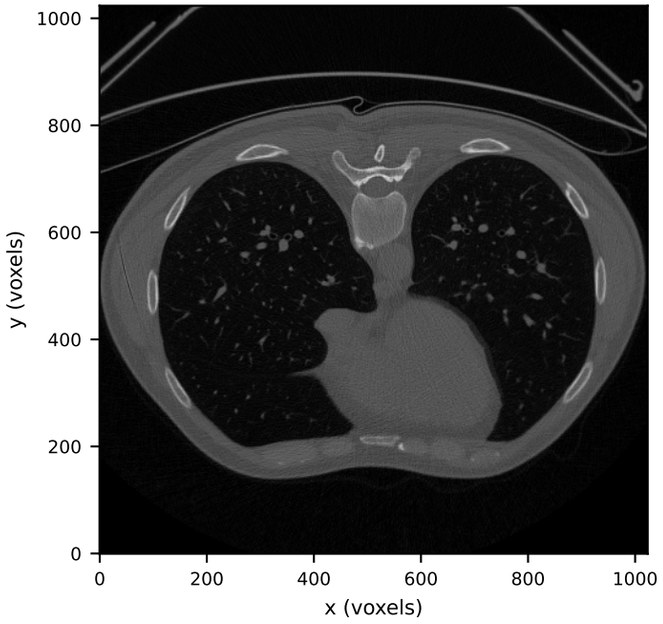

(e) Routed Tokens (k=8)

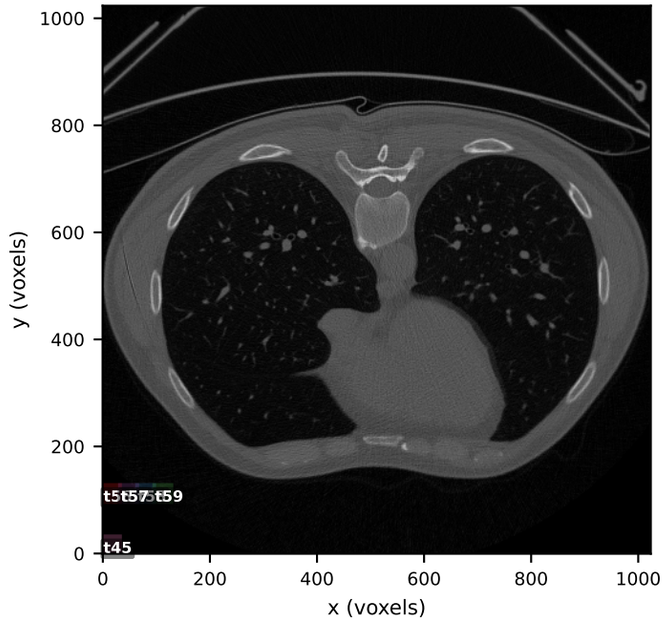

(f) Generated Output [Violation]

```
Generated Sentence:
──────────────────────────────────────
The left lung upper lobe contains a 6x9 mm
nodule.

──────────────────────────────────────
Anatomy: None
Token IDs: [56, 58, 59, 57, 11, 44, 45, 41]
Violations: R1_LATERALITY: Laterality mismatch with claim=left (same_side_ratio=0.375).

Evidence Card:
  Cited tokens: 8
  Dominant side: bilateral
  Same-side ratio: 0.62
  Laterality gate: bilateral
  Depth gate: in_range
```