Regional Cardiac Function By SQUEEZ From 4D CT In Acute Infarction: Validation Against Tagged MRI

Amir Pourmorteza[1], Noemie Keller[1], Richard Chen[2], Jesper van der Pals[2], Andrew E. Arai[2], Marcus Y. Chen[2], Elliot McVeigh[1]

[1]Departments of Biomedical Engineering, Johns Hopkins University, Baltimore, MD [2]Advanced Cardiovascular Imaging Laboratory, National Heart Lung and Blood Institute, Bethesda, MD

Introduction

Accurate identification of the extent of regional myocardial dysfunction is important in the diagnosis and management of patients with myocardial infarction. Tissue tagging MRI is currently the reference standard for noninvasive local cardiac function analysis; however, it has practical drawbacks: lengthy and complicated image acquisition and analysis, long breath-holds and implanted devices are a contra-indication for MRI. We have developed an algorithm for estimating regional cardiac function by tracking the LV endocardial surface called Stretch Quantification of Endocardial Engraved Zones (SQUEEZ)[1]. It produces high-resolution local function maps by tracking endocardial features such as papillary muscles and trabecular structures. The objective of this study was to investigate the correlation between SQUEEZ and myocardial strain from tMRI in acute myocardial infarction.

CT

Animals were scanned with electrocardiographic (EKG) monitoring using a 320-row detector scanner (Aquilion ONE ViSION; Toshiba Medical Systems Corporation).

First-pass contrast enhanced CT scans were acquired while respiration was suspended using a 3 to 5-beat retrospectively gated protocol with the following x-ray tube parameters: 80 kVp and 600 mA. Gantry rotation speed (275 ms - 350 ms) was set based on the animal's heart rate to ensure optimal temporal resolution (40-60 ms). Real-time bolus tracking was performed using Toshiba's SUREstart following a bolus injection.

CT volumes were then created using the 3D Adaptive Iterative Dose Reduction (AIDR3D) reconstruction algorithm at 0.5 mm slice thickness and 0.29 to 0.45 mm in-plane pixel size at 5% intervals of the R-R cycle.

MRI

LV geometry and function were evaluated with cine true fast imaging with steady state free precession (SSFP) . In addition, short axis tagged cine MRIs were acquired and used to derive circumferential myocardial strains (E_{cc}). The global ejection fraction (EF) was calculated from the cine MRI. Circumferential myocardial strain (E_{cc}) was estimated by manual segmentation and analysis of the tagged images using FindTags[2] and Tagged Tissue Tracking[3] software packages developed at the Johns Hopkins University.

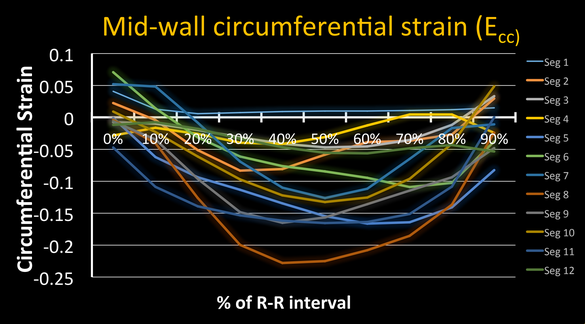

Animal Model

Nine dogs weighing 10 to 15 kg were studied with institutional approval. To make a model of acute myocardial infarction, the animals were intubated and surgical preparation included median sternotomy, venous catheters, arterial lines, and a snare around the left anterior descending (LAD) coronary artery, typically positioned distal to the first diagonal branch. The LAD was occluded for 2 hours followed by 2 hours of reperfusion prior to commencing imaging. Tagged and cine MRI scans were performed during the reperfusion phase.

The animals were then transported to the CT suite and the LAD was re-occluded. First-pass contrast enhanced CT scans were acquired after at least 2 hours of reperfusion and approximately 5 minutes after LAD re-occlusion. The average delay between the CT and MRI scans was less than 1 hour.

Global ejection fraction was calculated from both CT and MRI acquisitions. Animals with more than 10% difference in EF between the CT and MRI scans were excluded from the study due to the difference in the hemodynamic state of the hearts .

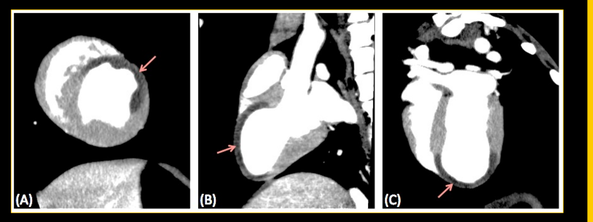

First-pass contrast enhanced CT images of a single animal after occlusion of the left anterior descending (LAD) coronary artery. The red arrows show hypointense area in the myocardium with perfusion deficit induced in the LAD territory. (A): short-axis view, (B,C): long-axis views.

Results

Three animals were excluded from further analysis due to the large difference between the EF values during the CT and MRI acquisitions. Another animal was excluded due to respiratory motion artifacts in the CT.

In the remaining 5 animals , SQUEEZ and E_{cc} were calculated at all systolic phases (Fig. A,B) and the peak contraction values were extracted from the time plots (Fig. C) in a total of 90 LV segments.

The peak contractions from SQUEEZ were then compared to the peak E_{cc} from MRI as the reference (Fig.D). The linear regression analysis showed good correlation between SQUEEZ and E_{cc}: r=0.79, p<0.001, slope=0.88, intercept= -0.03.

The Bland-Altman analysis of the results yielded bias of -0.015 and 95% confidence interval ±0.08 (Fig.E).

(A) Tagged MRI

(B) First-pass CT

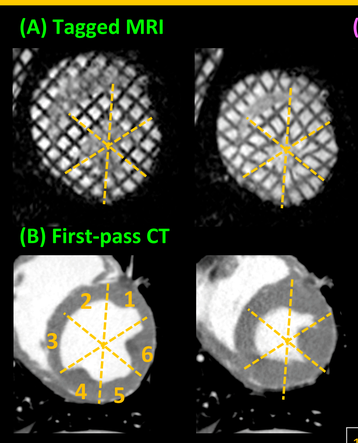

1: Anterior 2: Anteroseptal
3: Inferoseptal 4: Inferior
5: Inferolateral 6: Anterlateral

(C) Time Plots

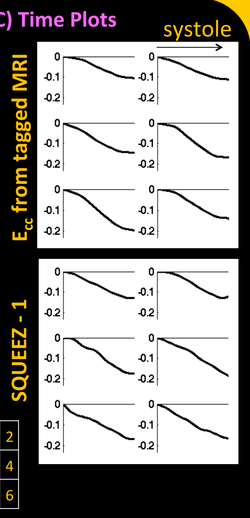

(D) Peak Systolic SQUEEZ vs. E_{cc}

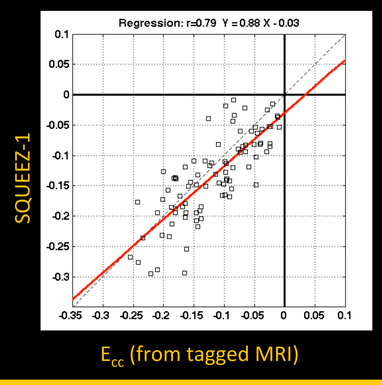

(E) Bland-Altman Analysis

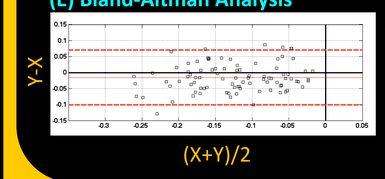

X: E_{cc} from tagged MRI
Y: SQUEEZ - 1 from CT

SQUEEZ

Stretch Quantifier of Endocardial Engraved Zones

For each systolic cardiac phase in the CT volumes, regional myocardial function was calculated as previously described in[1]; After automatic thresholding of the bright blood in the LV, an endocardial cast was extracted. The end-diastolic cast was used as a template to track the motion of the endocardium in the following phases. The quantification of the wall motion can be expressed as a number reflecting the amount of local stretch. We call this method *"Stretch QUantification of Endocardial Engraved Zones"* or SQUEEZ[1].

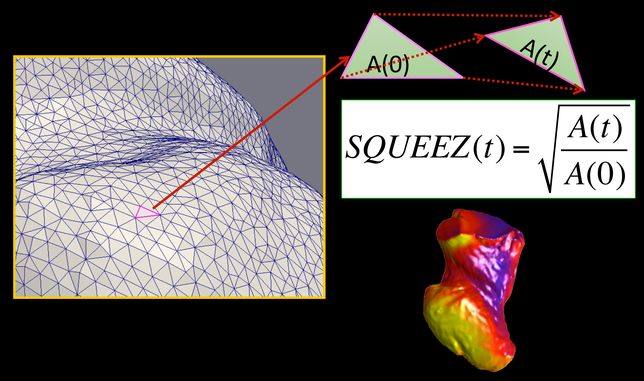

A SQUEEZ value of 0.75 means the tissue has contracted 25% (normal), a value of 1.0 means the tissue is akinetic, and a value of 1.25 means the tissue has stretched by 25% (dyskinetic). On the other hand, strain metrics derived from tagged MRI, such as circumferential shortening (E_{cc}) are represented as percentage of stretch (for example, E_{cc}=-0.25 in normal tissue, E_{cc}=0 in akinetic tissue, and E_{cc}=0.25 in dyskinetic tissue). Since there is an offset of 1 between the SQUEEZ and E_{cc} metrics, we compared Ecc to SQUEEZ-1 throughout this study.

Conclusion

There is very good agreement between the estimates of local myocardial deformation obtained from CT SQUEEZ and tagged MRI endocardial circumferential strain (E_{cc}) in a heart with variable end-systolic strain due to ischemia. For myocardial regions with E_{cc} values in [-0.3, 0] the line relating SQUEEZ-1 to E_{cc} was:

$$\text{SQUEEZ-1} = 0.88 \times E_{cc} - 0.03$$

Discussion

Radiation dose is always a concern with CT. Recent advances in CT technology have made it possible to take "snapshots" of the heart with effective dose of as low as 0.1 mSv for coronary angiography. The image quality necessary for wall motion tracking can be far lower than that for characterizing the coronary vessels. We have previously shown that by lowering the x-ray tube current and voltage (to ~30 mA and 80 kVp) and using advanced reconstruction algorithms it is possible to calculate reliable SQUEEZ values and reduce the radiation dose 5 to 10 folds[1,4].

Although both SQUEEZ and Ecc measure regional cardiac wall motion, they are different physical entities; Ecc is a measure of myocardial contraction in the circumferential direction, whereas SQUEEZ is a directionless measure of the geometric mean of contraction on the endocardial surface. We would anticipate SQUEEZ to measure a higher amount of contraction and this was observed.

Despite the fact that there are differences in regional function metrics obtained from MRI and SQUEEZ, the limits of agreement between the techniques were relatively small, indicating that the impact of these potential errors is likely to be modest.

Financial disclosure

Drs. Pourmorteza and McVeigh are inventors on a pending patent for SQUEEZ (WO Patent 2,013,056,082)

This research was Partially supported by Maryland Innovation Initiative (MII) grant "Diagnostic Method for rapid Detection of Significant Coronary Heart Disease".

References

1. Pourmorteza A, Schuleri KH, Herzka DA, Lardo AC, McVeigh ER. A New Method for Cardiac Computed Tomography Regional Function Assessment: Stretch Quantifier for Endocardial Engraved Zones (SQUEEZ). Circ. Cardiovasc. Imaging. 2012;5(2):243–250.
2. Guttman MA, Zerhouni EA, McVeigh ER. Analysis of Cardiac Function from MR Images. IEEE Comput. Graph. Appl. 1997;17(1):30–38.
3. Ozturk C, McVeigh ER. Four-dimensional B-spline based motion analysis of tagged MR images: introduction and in vivo validation. Phys. Med. Biol. 2000;45(6):1683–1702.
4. Pourmorteza A, Raihani N, Brown K, Zabic S, McVeigh ER. Regional Cardiac Function Estimation From Ultra-Low Dose CT Acquisitions Using Iterative Model-based Image Reconstruction: A Phantom Study. In: *Annual meeting of Radiology Society of North America (RSNA)*.; 2012.