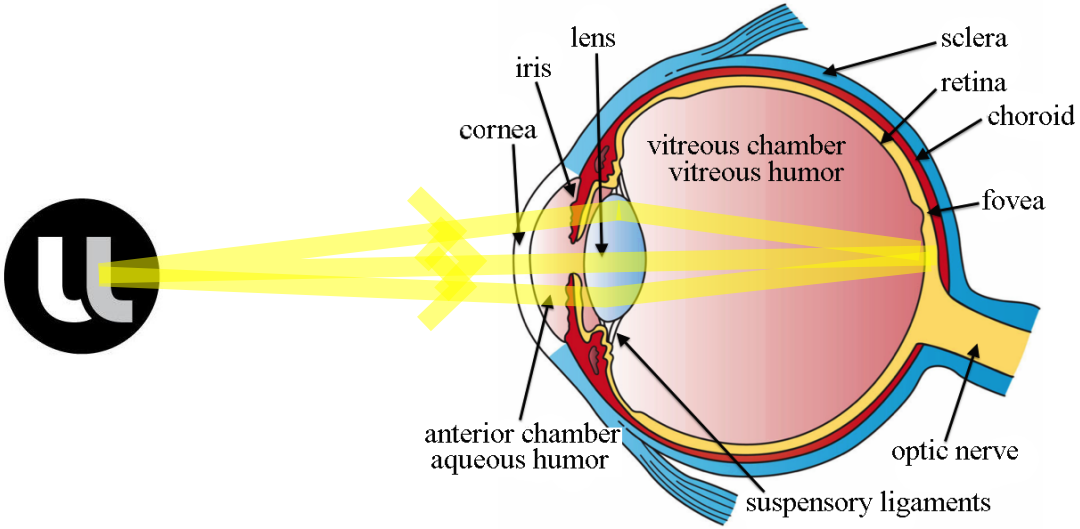
lens
iris
cornea
sclera
retina
choroid
vitreous chamber
vitreous humor
fovea
anterior chamber
aqueous humor
optic nerve
suspensory ligaments