ID: 1 [redacted]

Male 58Years

23-01-2026 09:08:44 AM

HR	: 72	bpm
P	: 118	ms
PR	: 158	ms
QRS	: 88	ms
QT/QTcBz	: 374/410	ms
P/QRS/T	: 78/77/74	°
RV5/SV1	: 1.208/0.897	mV

Diagnosis Information:

Sinus rhythm

Possible right atrial abnormality

Anterolateral ST elevation is nonspecific

Borderline ECG

Report Confirmed by:

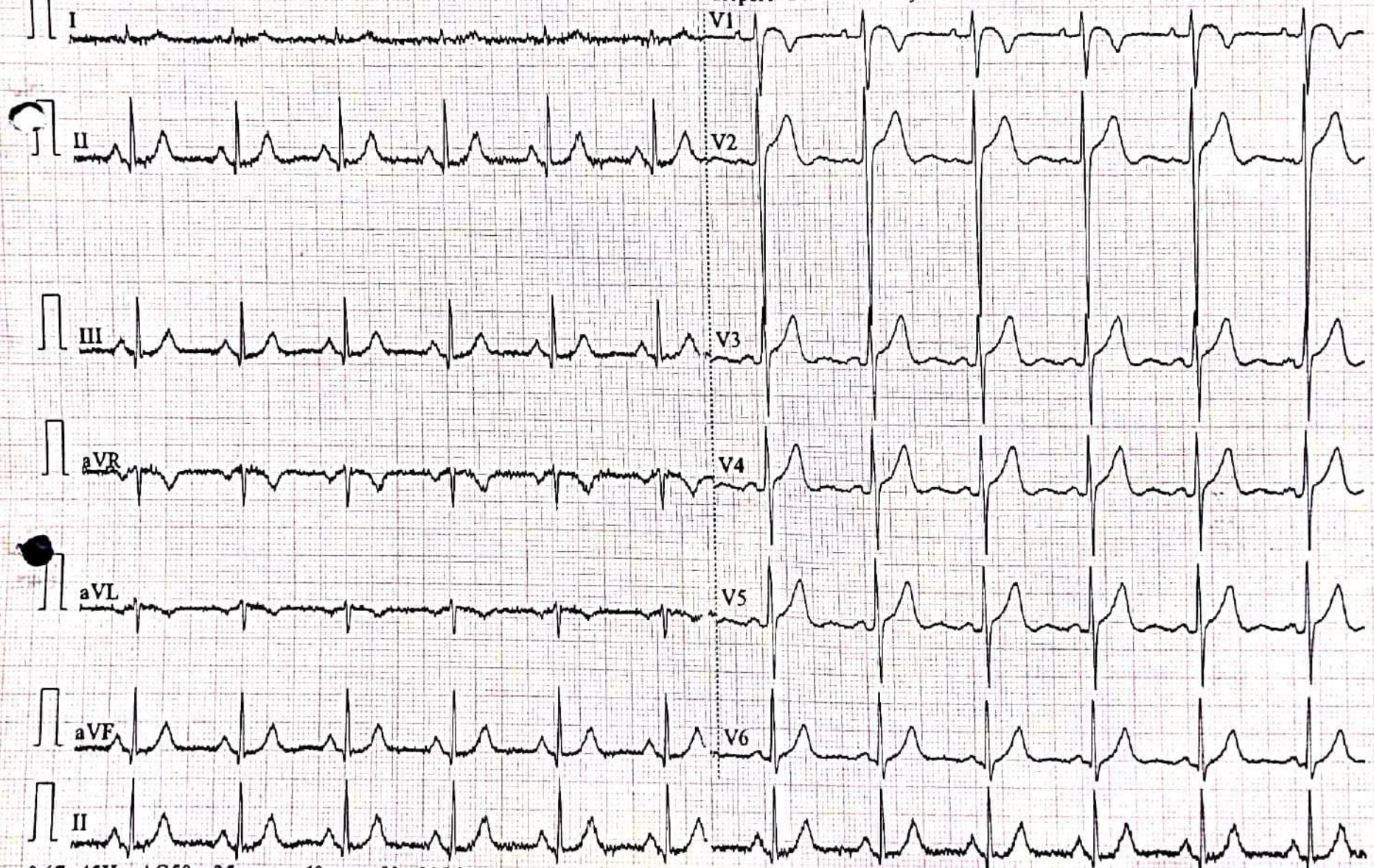

0.67~45Hz AC50 25mm/s 10mm/mV 2*5.0s+1r CARDIART 9108 [redacted] V1.47 Glasgow V28.6.7 [redacted]

[redacted]

Name	[redacted]	Patient ID	1767
Accession No		Age/Gender	56y/M
Referred By		Date	22/01/2026

X-RAY - CHEST PA VIEW

OBSERVATION:

- Right hila is prominent.
- The trachea is central.
- The mediastinal and cardiac silhouette are normal.
- Cardiothoracic ratio is normal.
- Cardiophrenic and costophrenic angles are normal.
- Left hila are normal.
- Lung zones are clear.
- Bones of the thoracic cage are normal.
- Soft tissues of the chest wall are normal

IMPRESSION:

Right hila is prominent.
Please clinical correlation.

[redacted]

(MBBS M.D Consultant Radiologist)
MCI/09-34285

Disclaimer-It Is an online interpretation of medical imaging based on clinical data. All modern machines/procedures have their own limitation. If there is any clinical discrepancy, this investigation may be repeated or reassessed by other tests. Patients' identification in online reporting is not established, so in no way can this report be utilized for any medico legal purpose. In case of any discrepancy due to typing error or machinery error please get it rectified immediately

[redacted]

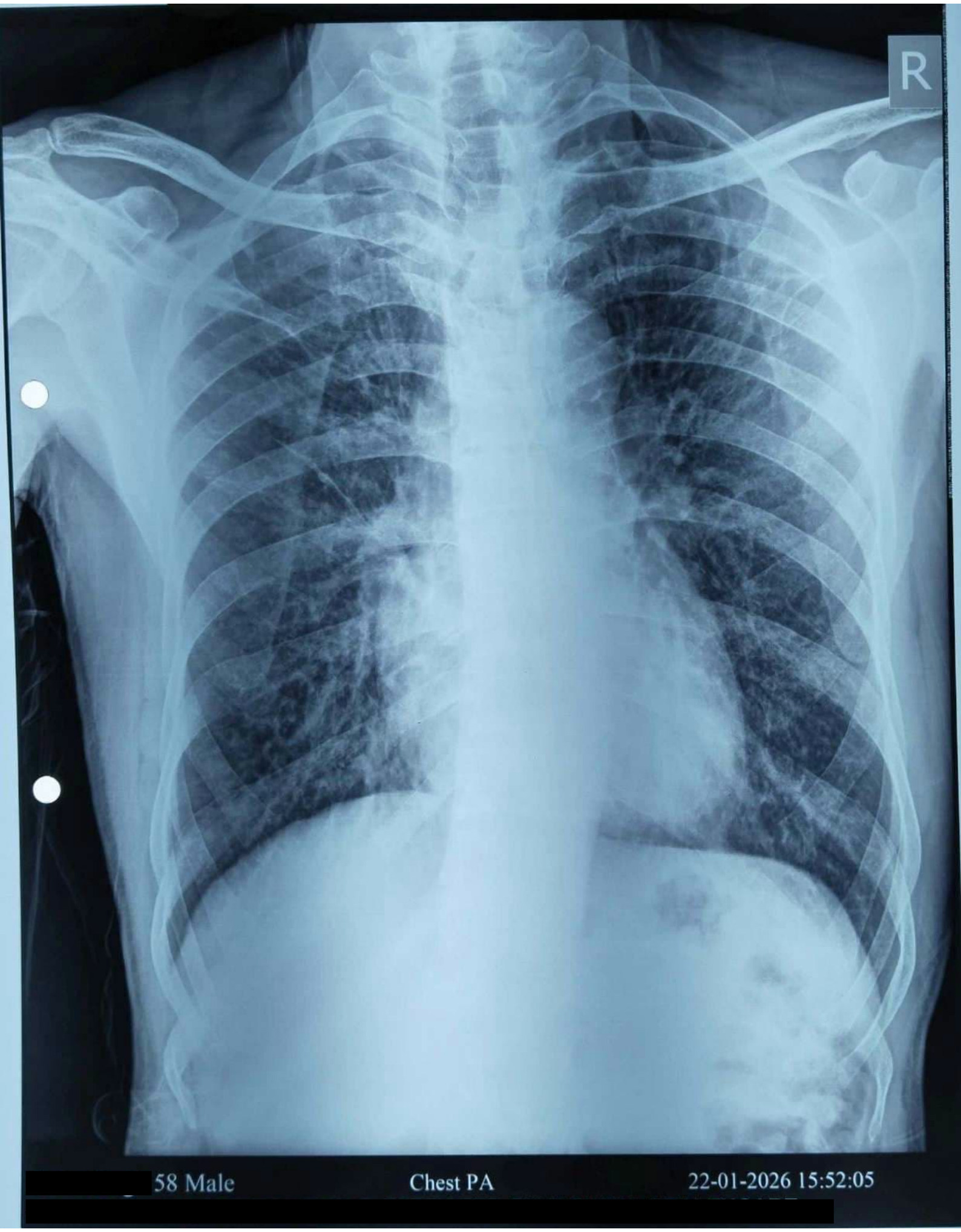
R
[redacted] 58 Male
Chest PA
22-01-2026 15:52:05
[redacted]